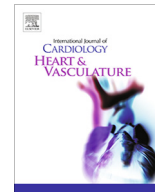




Contents lists available at ScienceDirect

IJC Heart & Vasculature

journal homepage: www.journals.elsevier.com/ijc-heart-and-vasculature

A novel method to demonstrate thrombus formation of the left atrial appendage in patients with persistent atrial fibrillation by cardiac computed tomography



Motohide Tanaka, Ryobun Yasuoka, Tomoya Nagano, Yasuhito Kotake, Masahiro Maruyama, Hiromi Yamamoto, Yoshitaka Iwanaga, Yutaka Hirano, Gaku Nakazawa, Takashi Kurita ^{*,1}

Division of Cardiology, Department of Medicine, Faculty of Medicine, Kindai University, 377-2 Onohigashi, Osaka-Sayama, Osaka 589-8511, Japan

ARTICLE INFO

Article history:

Received 9 August 2021

Accepted 24 August 2021

Keywords:

Persistent atrial fibrillation
Left atrial appendage
Thrombus
Cardiac computed tomography
Transesophageal echocardiography
Algorithm

ABSTRACT

Background: Transesophageal echocardiography (TEE) is currently the gold standard technique for diagnosing left atrial appendage (LAA) thrombi. Cardiac computed tomography (CT) has been expected to become an alternative method to TEE; however, a reliable quantitative evaluation method has not been established.

Methods and results: We enrolled 177 patients with persistent atrial fibrillation who underwent both cardiac CT and TEE before catheter ablation. The patients were classified into two groups according to the TEE results: the thrombus group (13 patients) and non-thrombus group (164 patients). The Hounsfield unit (HU) density at the proximal LAA (LAAp) and distal LAA (LAAd) was measured on cardiac CT images. The LAAd/LAAp HU ratio and standard deviation of HU density (HU-SD) at the LAAd were evaluated. We created an algorithm by decision tree analysis to predict LAA thrombus formation using the HU ratio and HU-SD. Definite absence of LAA thrombus (Category-I) was diagnosed for 139 patients by combining the first and second branching of the decision tree (Category-Ia: HU ratio of ≥ 0.26 , Category-Ib: HU ratio of < 0.26 , HU-SD of ≥ 26.94). Definite presence of LAA thrombus (Category-II) was diagnosed for 3 patients using the third branching of the decision tree (Category-II: HU ratio of < 0.26 and HU-SD of < 13.85). Highly possibility of LAA thrombus (Category-III), but not definite, was diagnosed for the remaining 35 patients; therefore, these patients required diagnostic TEE. The diagnostic accuracy of this algorithm was 0.95.

Conclusion: We have proposed a reliable algorithm to diagnose LAA thrombus formation using the HU ratio and HU-SD.

© 2021 Published by Elsevier B.V. This is an open access article under the CC BY-NC-ND license (<http://creativecommons.org/licenses/by-nc-nd/4.0/>).

1. Introduction

The most serious complication of atrial fibrillation (AF) is systemic embolism originating from a thrombus in the left atrium [1–5]. Fibrillatory wall motion and the morphological characteristics of the left atrial appendage (LAA) result in critically slow blood flow, which leads to thrombus formation within the LAA [6–8]. Although transesophageal echocardiography (TEE) is still the gold standard technique for diagnosing the presence of an LAA thrombus [9,10], physicians and patients have longed for a less invasive, safe and reproducible alternative examination technique because

TEE is relatively invasive examination [11–13]. Furthermore, in the present era of the ongoing COVID-19 pandemic, TEE is thought to carry a heightened risk of viral spread due to direct droplet transmission and/or viral aerosolization and inhalation during insertion/removal of the probe [14].

Cardiac computed tomography (CT) is generally performed before catheter ablation for AF because preoperative cardiac images are integrated with the locations of the electrode catheters on 3-dimensional mapping systems during the procedure [10]. Precise evaluation of LAA thrombus formation using routine preoperative cardiac CT may be clinically useful; however, no consensus has been established regarding the use of cardiac CT for assessment of the thrombus risk before catheter ablation [10].

Our study group previously reported that the ratio of Hounsfield unit (HU) values at the proximal and distal portions of the LAA (HU ratio) was correlated with the blood flow velocity in the

* Corresponding author.

E-mail address: kuritat@med.kindai.ac.jp (T. Kurita).

¹ This author takes responsibility for all aspects of the reliability and freedom from bias of the data presented and their discussed interpretation.

LAA [15]. Based on this data, we sought to devise a novel and simple method to accurately distinguish between a pre-thrombotic status and thrombus formation even in patients with a high risk of thrombosis. The purpose of this study was to create a novel diagnostic algorithm using cardiac CT imaging to improve the diagnostic accuracy of LAA thrombus formation in patients with AF.

2. Methods

2.1. Study design

This was a retrospective case-control study. The study protocol was approved by the Research Review Board of our University and conducted in accordance with the Declaration of Helsinki (Clinical Research Registration Number:27-238). Patients fulfilled the inclusion criteria were successively enrolled in this study. In our study, informed consent was obtained in the form of opt-out on the Kindai University hospital web site. Those who rejected were excluded.

2.2. Patients

We screened 481 patients who had undergone both TEE and cardiac CT as preoperative examinations for catheter ablation of AF from April 2014 to September 2018. Patients with paroxysmal AF were excluded because we evaluated only patients at high risk for LAA thrombus formation. Patients with sinus rhythm during TEE or cardiac CT examination were also excluded. Several studies have shown that the probability of finding LAA thrombus formation by preoperative TEE before pulmonary vein isolation (PVI) is quite low [16–19]. To collect requirement number of patients with an LAA thrombus (>10 patients) for appropriate statistical analysis in the present study, we initially planned to extend our study enrollment period only for the patients with LAA thrombus, because we had assumed that the incidence of LAA thrombus detection was extremely low.

The CHADS₂ score, CHA₂DS₂-VASc score, LA dimension and the left ventricular ejection fraction were evaluated to stratify the risk of thromboembolism [20–22].

2.3. TEE

TEE was performed using an iE33 ultrasound machine (Philips, Amsterdam, Netherlands) with a 5-MHz transducer. A thrombus was defined as a well-contoured homogeneous echogenic mass within the LAA cavity [8]. Patients with an LAA thrombus were assigned to the thrombus group, and patients without an LAA thrombus were assigned to the non-thrombus group.

2.4. Cardiac CT

A standard method for cardiac CT imaging and enhancement (coronary CT angiography) was used in the present study [15]. An electrocardiographic-gated 64-slice CT system (GE Healthcare, Chicago, IL, USA) was used to perform the cardiac CT examination with the test bolus tracking method. A 10-mL test bolus of the contrast agent iopamidol (Iopamiron 370; Bracco Diagnostics, Milan, Italy) was administered to estimate the scan timing. The main bolus of contrast agent (0.8 mL/kg of Iopamiron 370) was then injected. The scan was started at the time of maximum enhancement of the ascending aorta. The scan parameters were as follows: 120 kV, 500–700 mA, 0.16 helical pitches, 350-ms gantry rotation time, and 0.625- × 0.625-mm slice thickness by interval. We constructed a cardiac CT image at 75% of the R-R interval to reduce the influence of geometrical movement and blood flow in the LA/LAA throughout the cardiac cycle.

2.5. Measurement of HU density and calculation of HU ratio

To establish an easier method with which to detect thrombi in the LAA, we measured the HU density on cardiac CT images with medical recording systems (Synapse; Fujifilm, Tokyo, Japan and HOPE EGMAIN-GX; Fujitsu, Tokyo, Japan). The HU density was evaluated in a horizontal section with maximum depiction of the LAA cavity. Eight distinct points were determined at one proximal and seven distal sites of the LAA (LAAp and LAA d1–7, respectively), as shown in Fig. 1. The sampling point of LAAp was obtained at the center of the LAA orifice, and those of LAA d1–7 were obtained at the 1/8 to 7/8 distal points on a straight line drawn from the flexion point of the LAA posterior wall to the summit of the LAA apex. Because the shape, angulation and depth of LAA were various, in a case in whom simultaneous visualization of LAA-p and LAA d1–7 was impossible, we measured the HU values of LAA-p at a different horizontal section. The averaged HU density of each sampling point was measured within the region of interest (ROI), which was defined as a 10- to 11-mm² circle. Based on our experience, the length of 'the straight line' is approximately 30 mm or more, and 1/8 (3.8 mm) of 30 mm is equivalent to the diameter (3.6 mm) of the 10-mm² circular ROI, therefore, we divided 'the straight line' into eight equal parts and placed the ROI at each of the seven distal points. The LAA d/LAAp HU ratio was then calculated at each of the eight points.

The left panel of Fig. 1 shows images from a representative patient in the non-thrombus group (Patient 1). No thrombus was detected by TEE (upper row), and the peak emptying flow velocity was 38.2 cm/s (middle row). On the cardiac CT image (lower row), the length of the straight line was 44.8 mm, and the ROI of the LAA d was placed at the seven equally divided distal points on the straight line. In this case, the HU density of LAAp was 426.2, and that of each distal point (LAA d1–7) was 452.5, 426.7, 404.6, 407.0, 410.1, 411.3, and 385.4, respectively. The HU ratio at each point (LAA d1–7) was then calculated as 1.06, 1.00, 0.95, 0.95, 0.96, 0.96, and 0.90, respectively.

The right panel shows images from a representative patient in the thrombus group (Patient 2). An LAA thrombus was clearly observed by TEE (upper row), and the peak emptying flow velocity is 11.3 cm/s (middle row). The cardiac CT image showed a contrast defect in the distal site of LAA. The HU density of LAAp was 269.4, and each distal point (LAA d1–7) was 262.7, 262.4, 244.6, 189.8, 93.8, 96.1, and 67.7, respectively. The HU ratio at each point (LAA d1–7) was then calculated as 0.98, 0.97, 0.91, 0.70, 0.35, 0.36, and 0.25, respectively. The length of the straight line was 44.3 mm (lower row).

2.6. Evaluation of homogeneity in HU density

On cardiac CT images, LAA thrombi are characterized by homogeneity and a low HU density [23,24]. Therefore, we considered that evaluation of homogeneity in areas of low HU density as represented by the standard deviation of HU density (HU-SD) in the LAA would be useful to distinguish between an LAA thrombus and slow blood flow.

2.7. Method to create algorithm for diagnosis of thrombus formation

We created an algorithm by decision tree analysis using statistical analysis software (JMP version 10; SAS Institute Inc., Cary, NC, USA). The decision tree analysis recursively partitioned the data according to the relationship between the explanatory variable (presence of thrombus) and objective variables (HU ratio and HU-SD). The cut-off values of the objective variables to create a bifurcation in the decision tree were determined by receiver operating characteristic (ROC) curve analysis (with Youden index) and

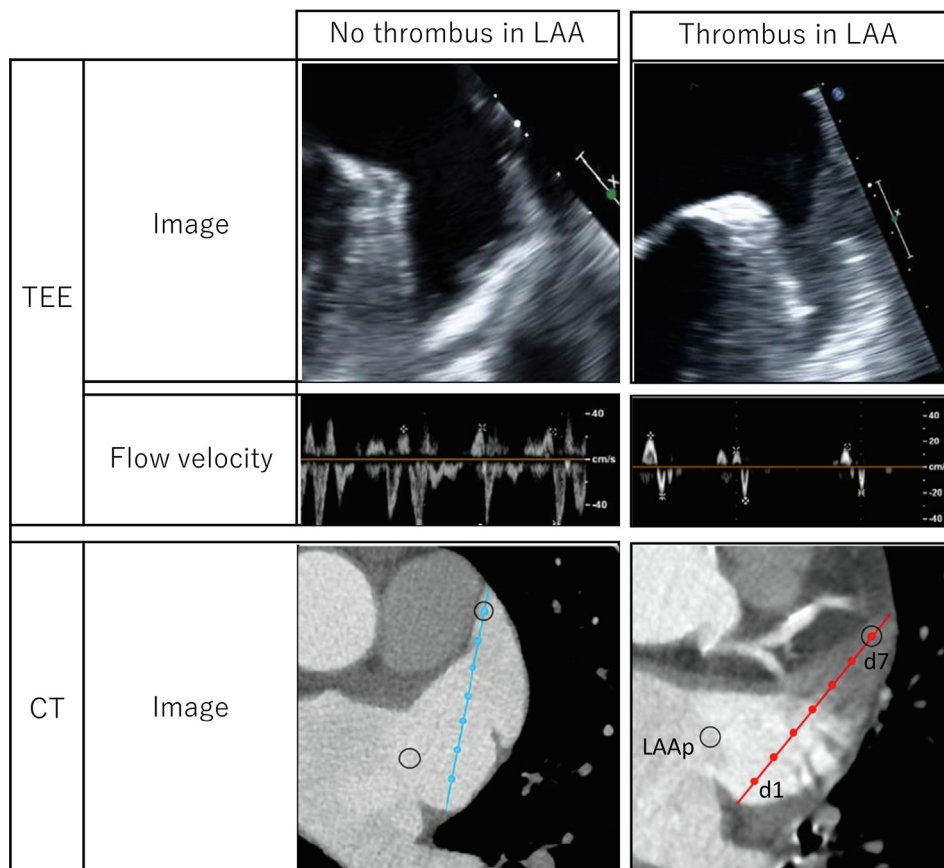


Fig. 1. Representative examples of presence and absence of LAA thrombus as observed by TEE and CT. A thrombus was defined as a well-contoured homogeneous echogenic mass within the LAA cavity by TEE (upper row). The patient with an LAA thrombus had a lower LAA blood flow velocity than the patient without an LAA thrombus (middle row). Cardiac CT of patients with an LAA thrombus showed a contrast-enhanced defect in the distal part of the LAA (lower row). The HU density was evaluated in a horizontal section with maximum depiction of the LAA cavity. Eight distinct points were determined at one proximal and seven distal sites of the LAA (LAAp and LAA1–7, respectively). CT indicates computed tomography; HU, Hounsfield unit; LAA, left atrial appendage; TEE, transesophageal echocardiogram.

maximal the likelihood estimation. To create a simple, reliable, and practical algorithm for thrombus diagnosis on cardiac CT, our algorithm was designed to be divided into three different categories as follows: Category-I; definite absence of LAA thrombus, Category-II; definite presence of LAA thrombus, and Category-III; high possibility of LAA thrombus (indistinguishable on cardiac CT). Category-I consists of Category-Ia and Ib, which are categorized by the HU ratio and HD-SD, respectively.

2.8. Statistical analysis

All data were measured and analyzed without knowledge of the patients' clinical backgrounds. The HU ratio and HU-SD at each point in the LAA (d1–7) were compared using repeated-measures analysis of variance and Tukey's post-hoc test. The HU ratio and HU-SD were compared between the thrombus group and non-thrombus group using Student's *t* test. Univariate and multivariate logistic regression analyses were performed to determine whether any variables were related to thrombus formation.

All statistical analyses with the exception of intraobserver and interobserver reliability were performed with JMP version 10 (SAS Institute Inc.). A 2-sided *p* value of <0.05 was considered statistically significant. To evaluate the intraclass correlation coefficients (ICCs), the HU density was measured twice by two independent cardiologists who were blinded to the TEE results.

3. Results

3.1. Patient characteristics

During the study period from April 2014 to September 2018, 481 patients underwent both cardiac CT and TEE before PVI. Of these, 175 patients with paroxysmal AF and 134 patients with non-AF rhythm during either TEE or cardiac CT were excluded. Finally, 172 patients were enrolled. Because the number of patients in the thrombus group was much smaller than that of patients in the non-thrombus group (8 [4.65%] vs. 164 [95.35%], respectively) until September 2018, the study period was extended to December 2019 only for patients with an LAA thrombus, and we thus registered an additional 5 patients with an LAA thrombus. Finally, 177 patients (13 in the thrombus group and 164 in the non-thrombus group) were analyzed (Fig. 2).

All patients had been treated with warfarin or direct oral anticoagulants for anticoagulation. The mean age in the thrombus group was higher than that in the non-thrombus group (70 ± 10 vs. 64 ± 9 years, respectively; *p* < 0.05).

The proportion of patients with diabetes was higher in the thrombus group than in the non-thrombus group (7 [53.85%] vs. 38 [23.17%], respectively; *p* < 0.05). The CHADS₂ score was significantly higher in thrombus group than in the non-thrombus group (2.2 ± 1.4 vs. 1.3 ± 1.1, respectively; *p* < 0.01), (Table 1).

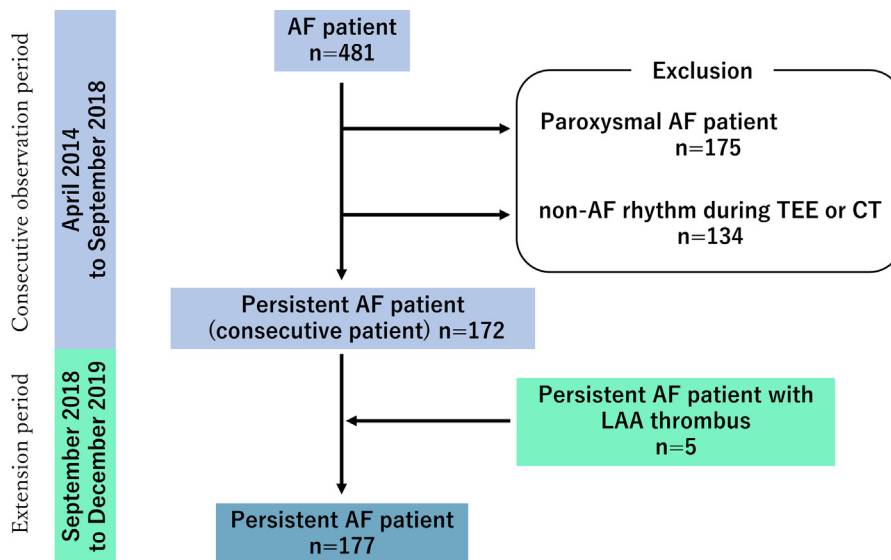


Fig. 2. Study's enrollment. AF indicates atrial fibrillation; CT, computed tomography; LAA, left atrial appendage; TEE, transesophageal echocardiogram.

Table 1 Patients' background data.

	All patients n = 177	Non-thrombus group n = 164	Thrombus group n = 13	P Value
Age (SD)	65 (10)	64 (9)	70 (10)	0.03
Sex, m/f	132/45	122/42	10/3	0.83
HT	108	98	10	0.21
DM	45	38	7	0.02
CHF	30	27	3	0.56
Stroke	18	16	2	0.54
CHADS ₂ (SD)	1.4 (1.1)	1.3 (1.1)	2.2 (1.4)	<0.01
CHA ₂ DS ₂ - VASc (SD)	2.3 (1.6)	2.3 (1.6)	3.2 (2.3)	0.07
EF, % (SD)	61 (11)	61 (11)	61 (12)	0.82
LAD, mm (SD)	45 (6)	44 (6)	47 (5)	0.1
Interval between CT and TEE, day (SD)	20.6 (33.9)	20.0(32.3)	28.2(50.7)	0.4
Anticoagulation, warfarin/DOAC	14/163	11/153	3/10	0.08
CT exposure dose, mGy· cm (SD)	2129.7 (467.1)	2143.7 (463.6)	1955.6 (495.2)	0.15
TEE				
Empty flow, cm/s (SD)	25.8 (14.3)	26.8 (14.4)	14.2 (3.8)	<0.01
Filling flow, cm/s (SD)	31.4 (15.1)	32.5 (15.1)	18.1 (5.5)	<0.01
SEC, 0/1/2	104/48/25	104/45/15	0/3/10	< 0.01
HU density				
d1 (SD)	363.4 (56.1)	362.5 (55.7)	374.2 (62.6)	0.47
d2 (SD)	352.3 (59.0)	351.7 (59.6)	359.6 (52.3)	0.64
d3 (SD)	331.8 (66.1)	333.2 (66.3)	313.6 (62.7)	0.31
d4 (SD)	293.0 (79.1)	299.7 (74.2)	209.3 (94.1)	<0.01
d5 (SD)	249.8 (100.6)	258.7 (94.9)	137.6 (106.8)	<0.01
d6 (SD)	215.6 (110.5)	226.7 (106.8)	76.8 (37.2)	<0.01
d7 (SD)	182.2 (103.8)	192.4 (100.9)	54.3 (24.7)	<0.01

Data are presented as n or mean ± standard deviation (SD).

CHADS₂ indicates congestive heart failure, hypertension, age (≥75), diabetes mellitus, previous stroke/transient ischemic attack; CHA₂DS₂-VASc, congestive heart failure, hypertension, age ≥75 years, diabetes mellitus, stroke or transient ischemic attack, vascular disease, age 65–74 years, sex category; CHF, congestive heart failure; CT, computerized tomography; DM, diabetes mellitus; DOAC, direct oral anticoagulant; EF, ejection fraction; HT, hypertension; HU, Hounsfield unit; LAD, left atrial dimension; SEC, spontaneous echo contrast; TEE, transesophageal echocardiography.

3.2. TEE and cardiac CT data

The blood flow velocity of the LAA was significantly lower in the thrombus group than in the non-thrombus group (14.2 ± 3.8 vs. 26.8 ± 14.4 cm/s, respectively; p < 0.01) (Table 1). The interval between the cardiac CT and TEE examinations was 20.6 ± 33.9 days. The amount of contrast agent used was 56.9 ± 9.4 mL, and the radiation dose was 2129.7 ± 467.1 mGy· cm (Table 1). Spontaneous echo contrast, which was classified into grade 0 to 2 (i.e.: 0 = none, 1 = mild to moderate and 2 = severe), was observed significantly

higher in the thrombus group than in the non-thrombus group (patient number in the grade 0, 1 and 2; 0/3/10 vs 104/45/15, respectively, p < 0.01), (Table 1).

3.3. HU ratio

Fig. 3 shows a comparison of the HU ratio at each sampling site (from d1 to d7) between the thrombus group and non-thrombus group [panel A1 and A2]. Both groups showed a gradual decrease in the HU ratio beyond the middle portion of the LAA (from d4

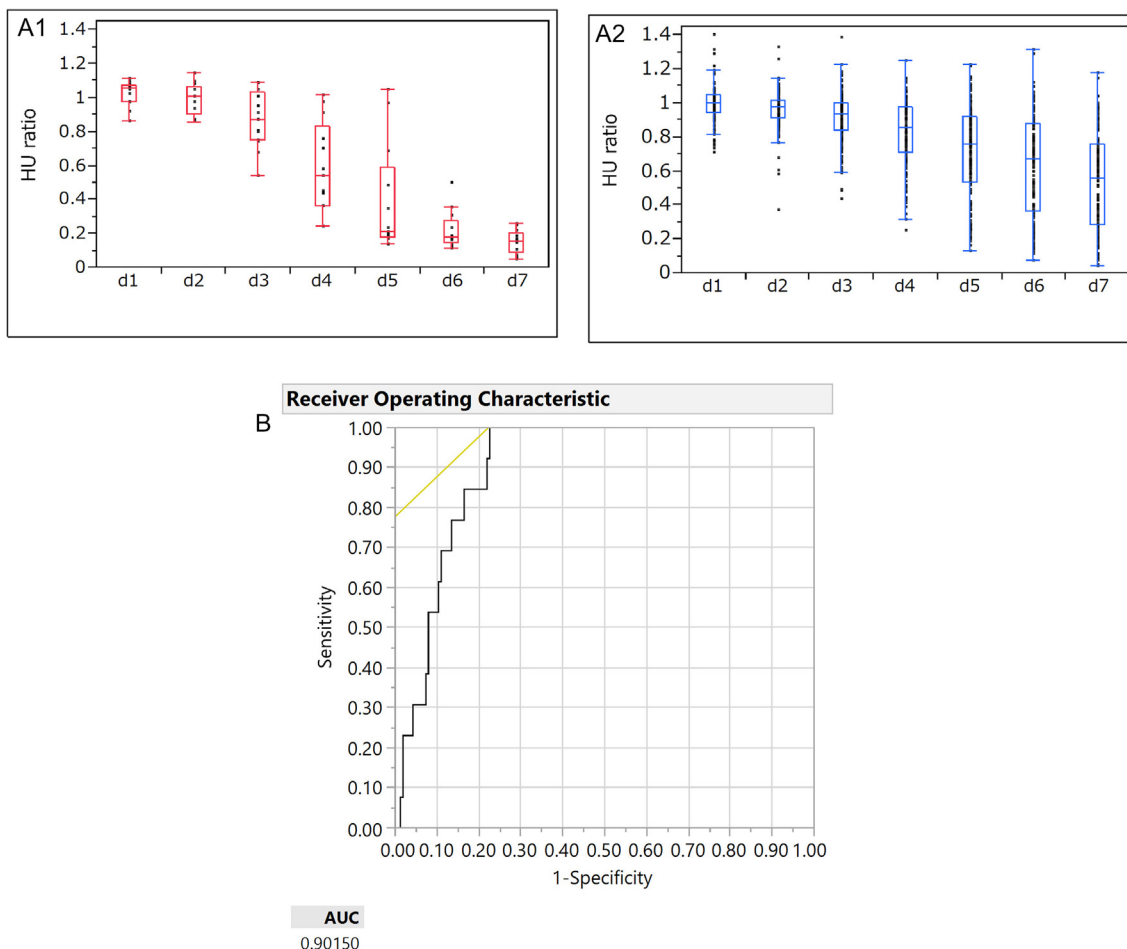


Fig. 3. Distribution of HU ratio in thrombus group and non-thrombus group at d1–7, and ROC analysis. A: The mean HU ratio in the thrombus group [A1] was significantly lower from d4 – 7 than that in the non-thrombus group [A2] (*t* test, *p* < 0.01). B: The ROC analysis for the relationship between the HU ratio at d7 and thrombus formation showed excellent discrimination for thrombus formation (AUC: 0.90). AUC indicates area under the curve; HU ratio, Hounsfield unit density ratio; ROC, receiver operating characteristic.

to d7). The thrombus group showed a significantly lower HU ratio than the non-thrombus group at the sites distal to d4 to d7 (d4: 0.58 ± 0.27 vs. 0.83 ± 0.19 , *p* < 0.0001; d5: 0.39 ± 0.32 vs. 0.72 ± 0.27 , *p* < 0.0001; d6: 0.22 ± 0.11 vs. 0.63 ± 0.29 , *p* < 0.0001; d7: 0.15 ± 0.07 vs. 0.53 ± 0.28 , *p* < 0.0001, respectively). The ROC analysis for the relationship between the HU ratio at d7 and thrombus formation showed excellent discrimination for thrombus formation (area under the curve 0.90) [panel B]. The optimal cut-off value (with Youden index) of the HU ratio for thrombus formation was 0.26 (sensitivity: 100%, specificity: 77.44%). In 127 patients with an HU ratio ≥ 0.26 , all patients were in non-thrombus group. In contrast, all of 13 patients with the thrombus group were included in 50 patients with an HU ratio of <0.26.

Intraobserver reliability (ICC [1,1]) showed almost perfect agreement (LAAp: *r* = 0.33, LAA d7: *r* = 0.96, HU ratio: *r* = 0.94), as did interobserver reliability (ICC [2,1]) (LAAp: *r* = 0.34, LAA d7: *r* = 0.95, HU ratio: *r* = 0.94).

3.4. HU-SD

We evaluated 50 patients with an HU ratio of <0.26 using the HU-SD because a certain percentage of patients still had no LAA thrombus in this subgroup.

Fig. 4 shows the difference in the HU-SD (i.e., heterogeneity of HU density) at d7 with and without a thrombus [panel A]. The

HU-SD (d7) was significantly lower in the thrombus group than in the non-thrombus group (17.73 ± 4.77 vs. 23.79 ± 5.91 , *p* < 0.01). The ROC curve, which was plotted with the HU-SD against the presence of an LAA thrombus, demonstrated that an HU-SD of 20.14 was the best cut-off value (with Youden index) to discriminate an LAA thrombus (area under the curve: 0.79, sensitivity: 84.62%, specificity: 52.18%) [panel B].

Intraobserver reliability (ICC [1,1]) showed substantial agreement (d7: *r* = 0.65), as did interobserver reliability (ICC [2,1]) (d7: *r* = 0.65).

Fig. 5 shows a logistic regression plot of the probability of thrombus formation against the HU ratio at d7 according to five quantiles of the HU-SD. As the HU ratio decreased, the probability of thrombus formation dramatically increased in subgroups with a low HU-SD (homogeneous density).

4. Novel algorithm to evaluate presence of LAA thrombus using cardiac CT imaging

Fig. 6 and Table 2 show a cardiac CT based algorithm to detect the thrombus in LAA by combining the values of HU ratio and HU-SD at d7.

First, to distinguish the patients without LAA thrombus formation, HU ratio (the cutoff value: 0.26) was applied to first branching of a decision tree. If patients had a HU ratio equal or more than

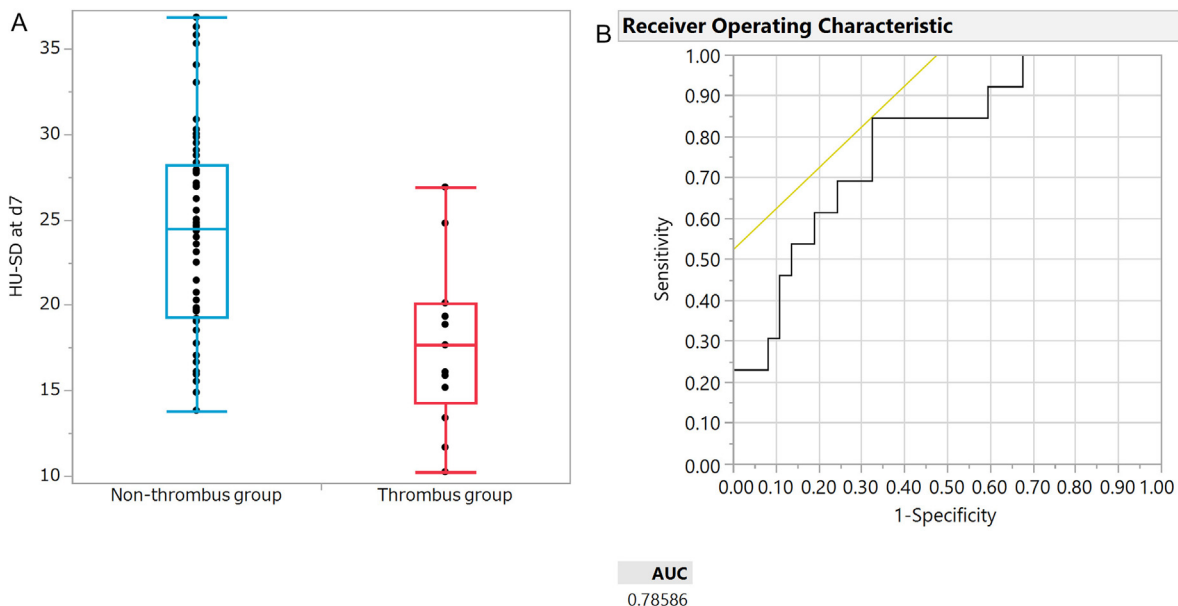


Fig. 4. Distribution of HU-SD at d7 and ROC analysis. A: The HU-SD at d7 was significantly lower in the thrombus group than in the non-thrombus group (*t* test, *p* < 0.01). B: The ROC curve, which was plotted with the HU-SD against the presence of an LAA thrombus, demonstrated that an HU-SD of 20.14 was the best cut-off value to discriminate an LAA thrombus (AUC: 0.79). AUC indicates area under the curve; HU-SD, the standard deviation of Hounsfield unit density; LAA, left atrial appendage; ROC, receiver operating characteristic.

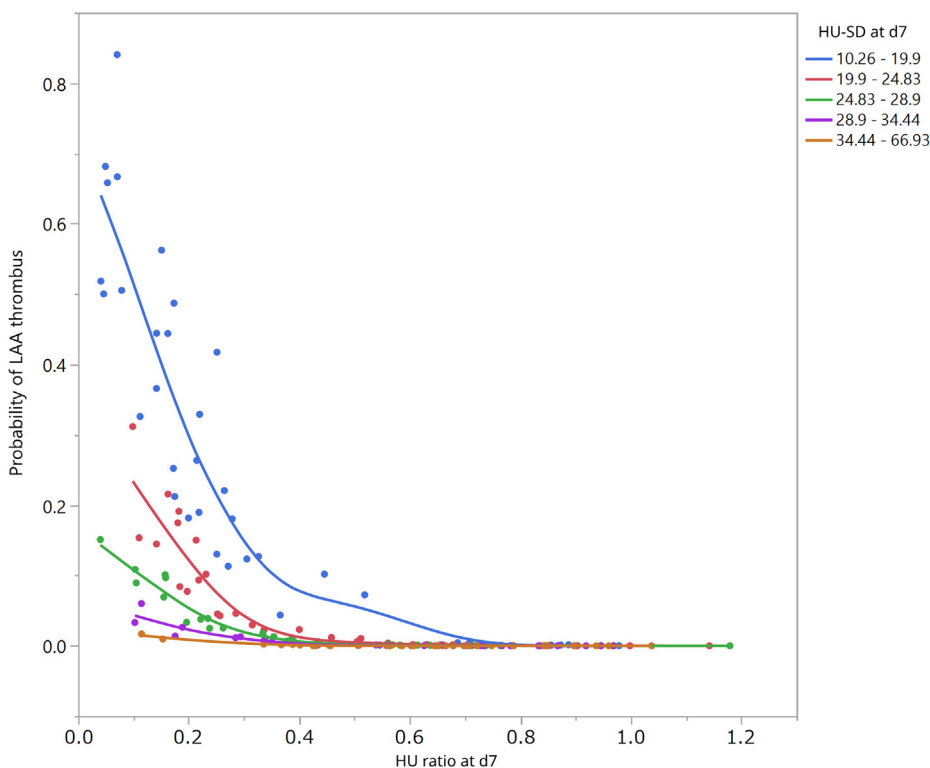


Fig. 5. Logistic regression plot of the probability of thrombus formation between subgroups. As the HU ratio decreased, the probability of thrombus formation dramatically increased in subgroups with a low HU-SD. HU ratio indicates Hounsfield unit density ratio; HU-SD, the standard deviation of Hounsfield unit density.

0.26, they were classified into “Category-Ia” (n = 127[71.75%], diagnostic accuracy 0.79 [Table 2A]).

For the next step, the cutoff value of HU-SD equal or more than 26.94 (with maximal likelihood estimation: probability of non-thrombus is 0.99) was applied to second branching of a decision tree. If patients had a HU ratio less than 0.26 and HU-SD equal or

more than 26.94 (i.e. low HU density but heterogeneous), they were classified into Category-Ib (n = 12). And then, cardiac CT imaging successfully excludes an LAA thrombus in 139 out of 177 (78.53%) up to the second step (Category-I; definite absence of LAA thrombus combined with Category-Ia and Category-Ib, diagnostic accuracy 0.86 [Table 2B]).

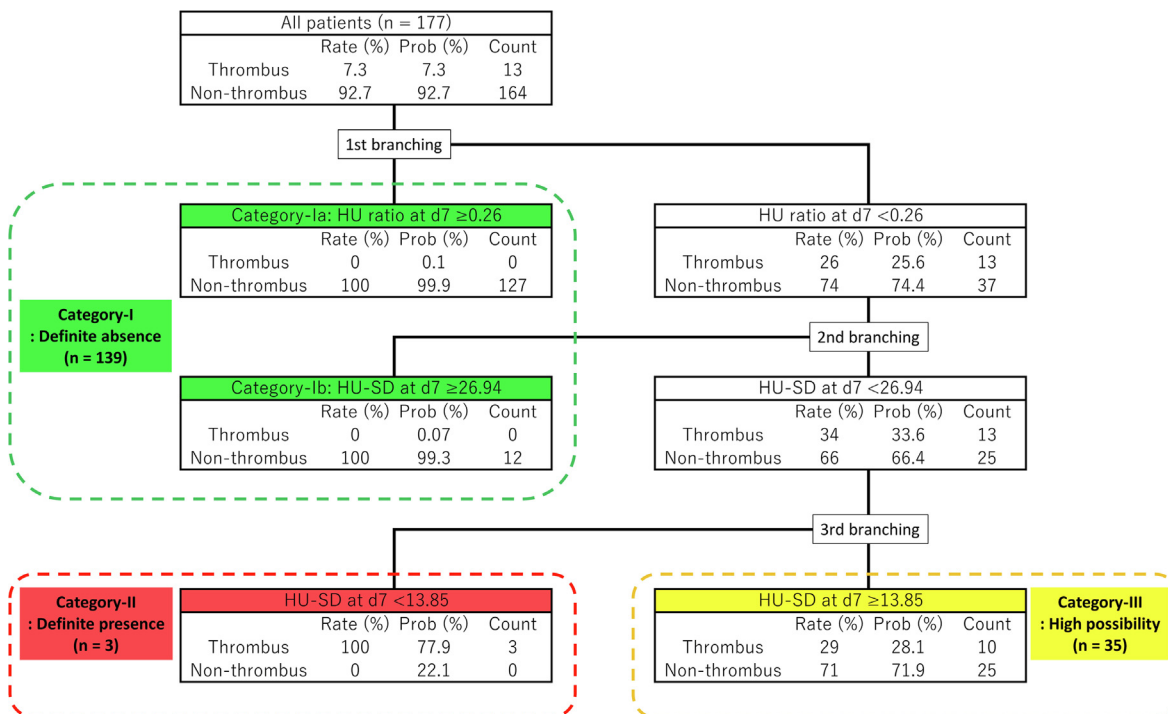


Fig. 6. Novel algorithm to evaluate presence of LAA thrombus. Among patients with an HU ratio of ≥ 0.26 (Category-Ia) or an HU ratio of < 0.26 and an HU-SD of ≥ 26.94 (Category-Ib), no patients ($n = 139$) had a thrombus. Among the remaining patients, those with an HU-SD of < 13.85 ($n = 3$) were diagnosed with a thrombus by TEE (Category-II). Using this algorithm, it was possible to distinguish the presence or absence of an LAA thrombus in 142 out of 177 patients using CT alone. CT indicates computed tomography; HU ratio, Hounsfield unit density ratio; HU-SD, the standard deviation of Hounsfield unit density; LAA, left atrial appendage; TEE, transesophageal echocardiogram.

Table 2
The diagnostic accuracy of our algorithm.

A		Category-Ia : HU ratio at d7 ≥ 0.26		Diagnostic accuracy	
		CT outcome			
		The remaining	Category-Ia	Sensitivity	1.00
Th group		13	0	Specificity	0.77
Non-th group		37	127	Accuracy	0.79
				F value	0.41
				NPV	1.00
B		Category-I : Category-Ia + Category-Ib		Diagnostic accuracy	
		CT outcome			
		Category-II & III	Category-I	Sensitivity	1.00
Th group		13	0	Specificity	0.85
Non-th group		25	139	Accuracy	0.86
				F value	0.51
				NPV	1.00
C		Category-II : HU ratio at d7 < 0.26 and HU-SD at d7 < 13.85		Diagnostic accuracy	
		CT outcome			
		Category-II	Category-I & III	Sensitivity	0.23
Th group		3	10	Specificity	1.00
Non-th group		0	174	Accuracy	0.95
				F value	0.38
				PPV	1.00

A: Confusion matrix for Category-Ia (HU ratio at d7 ≥ 0.26) and the remaining patients. There were no patient with thrombus group in this category. The diagnostic accuracy was 0.79.

B: Confusion matrix for Category-I (Category-Ia + Category-Ib [HU ratio at d7 < 0.26 and HU-SD at d7 ≥ 26.94]) and remaining patients (Category-II and III). There were no patient with thrombus group in Category-I. The diagnostic accuracy improved to 0.86.

C: Confusion matrix for Category-II (HU ratio at d7 < 0.26 and HU-SD at d7 < 13.85) and remaining patients (Category-I & III). There were no patients with non-thrombus group in Category-II. The diagnostic accuracy improved to 0.95.

CT indicates computerized tomography; HU ratio, Hounsfield unit density ratio; HU-SD, the standard deviation of Hounsfield unit density; Non-th, non-thrombus; NPV, negative predictive value; Th, thrombus; PPV, positive predictive value.

After the second step, 38 patients still remain indefinite for the diagnosis of an LAA thrombus. Therefore, as the third step, the cut-off value of HU-SD less than 13.85 (with maximal the likelihood estimation: probability of thrombus formation is 0.78) was applied to a decision tree. When patients had HU-SD less than 13.85 (i.e. low HU density and homogeneously), they were classified into Category-III (definite presence of LAA thrombus [$n = 3$]). Other 35 patients with a HU-SD less than 26.94 and equal or more than 13.85 were diagnosed as a highly possible for thrombus formation: Category-II (high possibility of presence an LAA thrombus; 10/35 [28.57%]). Accordingly, we could enhance the capability of cardiac CT imaging to exclude or detect an LAA thrombus in 142 (Category-I and Category-II) out of 177 (80.23%) through this diagnostic algorithm. The diagnostic accuracy of this algorithm was 0.95 (Table 2C). As the step of branching progresses by combining HU density and HU-SD, the diagnostic accuracy improves from 0.79 to 0.95 (Table 2 and Fig. 6).

5. Discussion

According to our newly established algorithm using the combination of the HU ratio and HU-SD of a cardiac CT image, we successfully determined the absence or presence of an LAA thrombus in approximately 80% (82% in the consecutive 172 patients) of patients with persistent AF. Our novel method allows physicians to appropriately decide whether to perform cardioversion or catheter ablation in the majority of these patients with AF without using TEE. Because thrombus formation is plausible in the remaining 20% (18% in the consecutive 172 patients) of patients even using our algorithm, TEE examination is strongly recommended especially for these patients. In the present study, we excluded paroxysmal AF patients because patients' heart rhythm during MDCT might be different (sinus rhythm or AF). Inhomogeneous heart rhythm during MDCT (some patients might be in sinus rhythm and others in AF) may provide random irregularity (statistical noise). Further, patients with sinus rhythm during the preoperative MDCT, contrast filling of LAA was enough to avoid double check with TEE. If we included patients with paroxysmal AF, we might be able to demonstrate further high accuracy to detect the absence of LAA thrombus by MDCT because many of paroxysmal patients are supposed to maintain sinus rhythm at the evaluation.

5.1. Diagnosis of LAA thrombus using cardiac CT in the previous studies

Attempts to diagnose an LAA thrombus with electrocardiography-gated CT began in the early 2000s. Initially, most investigators used a single-phase CT scanning protocol [25–30], but the accuracy of diagnosis was relatively low in some of these studies. To improve the diagnostic accuracy, investigators have been devising specific CT imaging techniques such as the double CT scanning protocol (early-phase and late-phase scanning) since the 2010s [31–33]. Two meta-analyses demonstrated a beneficial diagnostic role of cardiac CT, and the authors concluded that cardiac CT imaging can serve as an alternative to TEE only when the double scanning technique has been used [34,35]. However, we thought that the results of meta-analyses were caused qualitative diagnostic criteria. Because most previous studies used only qualitative diagnostic criteria (i.e., the existence of an oval or round filling defect in the LAA) to detect thrombus formation [26,27,29]. Our finding demonstrate that a single scan technique was shown to have sufficient diagnostic capability if using quantitative evaluation method of HU density.

5.2. Advantages of our method

According to the results of previous studies using only a single scan protocol, the average diagnostic accuracy was estimated to be 0.87 [35]. Our method provides more reliable diagnostic accuracy than previous reports. There are four possible reasons why our method is superior to the methods described in previous studies with respect to detecting thrombi.

First, we determined the exact site (d7) of the LAA at which to measure the HU density. Measuring the HU density at an uncertain site with any filling defect might cause selection bias because it is determined by the investigator's visual impression. To remove bias and perform an accurate quantitative analysis, we measured the HU density at an exact site and in a precisely sized ROI. Our data demonstrated that the most distal site of the LAA is the best position at which to estimate the presence of a thrombus.

Second, based on the results of our previous study, we found that using the HU density of the proximal LAA as the denominator (reference) to calculate the HU ratio is much more effective than using the HU density of the ascending aorta because the presence of a reference and ROI within the same chamber should provide synchronous timing of peak contrast.

Third, we newly developed a method to evaluate the homogeneity of HU density by using the HU-SD. We focused on the homogeneity of HU density because it may be associated with the blood properties and contrast enhancement in the LAA. A critical decrease in blood flow in the LAA potentially produces a thrombus with erythrocyte aggregates and a fibrin meshwork [36], and we speculate that it may cause very low and homogeneous HU density within the filling defect area. Kirchoff et al [23], reported that low and homogeneous HU density on CT images can be indicative of a thrombus consisting of large fibrin strands and erythrocytes. Following this study, Teunissen et al [24], found that the homogeneity of the region with low attenuation of contrast media is associated with the risk of thrombus formation. Although they evaluated the homogeneity of regions of low attenuation according to their visual impression, their data support our results.

Fourth, we created a novel algorithm for detection of an LAA thrombus by combining two different properties of LAA enhancement by contrast media: the HU ratio and the HU-SD. Further technological development of MDCT may provide an excellent quality of the LAA imaging by obtaining both of a high density and a thin slicing, and may contribute to compensate the weakness of TEE, such as limited echo window and inter-observer variability.

5.3. Clinical implications

To the best of our knowledge, this is the first study to use the HU-SD as a diagnostic criterion for thrombus formation. Using our novel algorithm, approximately 80% of patients with persistent AF can avoid TEE examination to rule out LAA thrombus. Avoiding unnecessary TEE examination can lower the risk of COVID-19 spread, esophageal injury and reduce medical fee. Another advantage of our method is its ease and safety. Dual-enhanced or two-phase scan protocols have been recognized useful for detect LAA thrombi; however, these are more complicated and require larger doses of both contrast media and radiation than our protocol.

6. Limitations

This study has several limitations. First, this study was retrospectively designed. A prospective investigation may allow for more accurate verification by minimizing the interval between the cardiac CT and TEE examinations. In the present study, the

mean interval between cardiac CT and TEE was 21 ± 34 days. However, the treatments for the patients and their heart rhythm remained the same during this interval. Therefore, we believe that the interval between the two examinations did not largely affect our results.

Second, this study included only a small number of patients ($n = 8$) with LAA thrombi, and the enrollment period of five patients with LAA thrombi was different from that of other consecutive 172 patients which included three patients with LAA thrombi. Additional enrollment of five cases with LAA thrombi was statistically required to demonstrate the capability of MDCT. Because it is difficult to enroll a large number of patients with thrombi in a single-center study, a multicenter study is needed to obtain more reliable verification.

Third, the slice with maximum longitudinal depiction of the LAA was used to measure the HU density; we did not analyze the whole LAA cavity. Therefore, the presence of small thrombi outside the analyzed slice cannot be excluded. However, it may be difficult to identify such small mural thrombi even by TEE.

7. Conclusion

We have here in proposed a novel algorithm to diagnose LAA thrombus formation by using the HU ratio and HU-SD on cardiac CT images. Even when using a single scanning protocol with standard imaging software, our algorithm is reliable for exclusion of an LAA thrombus in patients with persistent AF.

Funding

None.

Declaration of Competing Interest

The authors declare that they have no known competing financial interests or personal relationships that could have appeared to influence the work reported in this paper.

Acknowledgment

We thank Angela Morben, DVM, ELS, from Edanz Group (<https://en-author-services.edanz.com/ac>), for editing a draft of this manuscript.

References

- [1] H.S. Jørgensen, H. Nakayama, J. Reith, H.O. Raaschou, T.S. Olsen, Acute stroke with atrial fibrillation. The Copenhagen Stroke Study, *Stroke* 27 (10) (1996) 1765–1769.
- [2] M.F. Stoddard, P.R. Dawkins, C.R. Prince, N.M. Ammash, Left atrial appendage thrombus is not uncommon in patients with acute atrial fibrillation and a recent embolic event: a transesophageal echocardiographic study, *J. Am. Coll. Cardiol.* 25 (2) (1995) 452–459.
- [3] J.L. Blackshear, J.A. Odell, Appendage obliteration to reduce stroke in cardiac surgical patients with atrial fibrillation, *Ann. Thorac. Surg.* 61 (2) (1996) 755–759.
- [4] J.R. Belcher, W. Somerville, Systemic embolism and left auricular thrombosis in relation to mitral valvotomy, *Br. Med. J.* 22 (1955) 1000–1003.
- [5] M. Zabalgoitia, J.L. Halperin, L.A. Pearce, J.L. Blackshear, R.W. Asinger, R.G. Hart, Transesophageal echocardiographic correlates of clinical risk of thromboembolism in nonvalvular atrial fibrillation. Stroke Prevention in Atrial Fibrillation III Investigators, *J. Am. Coll. Cardiol.* 31 (7) (1998) 1622–1626.
- [6] Y. Agmon, B.K. Khandheria, F. Gentile, J.B. Seward, Echocardiographic assessment of the left atrial appendage, *J. Am. Coll. Cardiol.* 34 (7) (1999) 1867–1877.
- [7] C. Pollick, D. Taylor, Assessment of left atrial appendage function by transesophageal echocardiography. Implications for the development of thrombus, *Circulation* 84 (1) (1991) 223–231.
- [8] E. Donal, H. Yamada, C. Leclercq, D. Herpin, The left atrial appendage, a small, blind-ended structure, *Chest* 128 (3) (2005) 1853–1862.
- [9] C.T. January, L.S. Wann, J.S. Alpert, et al., American College of Cardiology/American Heart Association Task Force on Practice Guidelines. 2014 AHA/ACC/HRS guideline for the management of patients with atrial fibrillation: a report of the American College of Cardiology/American Heart Association Task Force on Practice Guidelines and the Heart Rhythm Society, *J. Am. Coll. Cardiol.* 64 (21) (2014) e1–e76.
- [10] H. Calkins, G. Hindricks, R. Cappato, et al., Document Reviewers: 2017 HRS/EHRA/ECAS/APHS/SOLAECE expert consensus statement on catheter and surgical ablation of atrial fibrillation, *Europace*. 20 (2018) e1–e160.
- [11] J.K. Min, K.T. Spencer, K.T. Furlong, J.M. DeCara, L. Sugeng, R.P. Ward, R.M. Lang, Clinical features of complications from transesophageal echocardiography: a single-center case series of 10,000 consecutive examinations, *J. Am. Soc. Echocardiogr.* 18 (9) (2005) 925–929.
- [12] W.G. Daniel, R. Erbel, W. Kasper, C.A. Visser, R. Engberding, G.R. Sutherland, E. Grube, P. Hanrath, B. Maisch, K. Dennig, Safety of transesophageal echocardiography. A multicenter survey of 10,419 examinations, *Circulation* 83 (3) (1991) 817–821.
- [13] J.B. Seward, B.K. Khandheria, J.K. Oh, W.K. Freeman, A.J. Tajik, Critical appraisal of transesophageal echocardiography: limitations, pitfalls, and complications, *J. Am. Soc. Echocardiogr.* 5 (3) (1992) 288–305.
- [14] J.N. Kirkpatrick, C. Mitchell, C. Taub, S. Kort, J. Hung, M. Swaminathan, ASE statement on protection of patients and echocardiography service providers during the 2019 novel coronavirus outbreak: endorsed by the American College of Cardiology, *J. Am. Soc. Echocardiogr.* 33 (6) (2020) 648–653.
- [15] R. Yasuoka, T. Kurita, Y. Kotake, Y. Akaiwa, N. Hashiguchi, K. Motoki, H. Yamamoto, K. Kobuke, Y. Iwanaga, Y. Hirano, S. Miyazaki, A novel method to estimate blood flow velocity in the left atrial appendage using enhanced computed tomography: role of Hounsfield unit density ratio at two distinct points within the left atrial appendage, *Heart Vessels* 32 (7) (2017) 893–901.
- [16] S. Puwanant, B.C. Varr, K. Shrestha, S.K. Hussain, W.H.W. Tang, R.S. Gabriel, O. M. Wazni, M. Bhargava, W.I. Saliba, J.D. Thomas, B.D. Lindsay, A.L. Klein, Role of the CHADS₂ score in the evaluation of thromboembolic risk in patients with atrial fibrillation undergoing transesophageal echocardiography before pulmonary vein isolation, *J. Am. Coll. Cardiol.* 54 (22) (2009) 2032–2039.
- [17] D. Scherr, D. Dalal, K. Chilukuri, et al., Incidence and predictors of left atrial thrombus prior to catheter ablation of atrial fibrillation, *J. Cardiovasc. Electrophysiol.* 20 (2009) 379–384.
- [18] T.W. Wallace, B.D. Atwater, J.P. Daubert, et al., Prevalence and clinical characteristics associated with left atrial appendage thrombus in fully anticoagulated patients undergoing catheter-directed atrial fibrillation ablation, *J. Cardiovasc. Electrophysiol.* 21 (2010) 849–852.
- [19] D. Frenkel, S.A. D'Amato, M. Al-Kazaz, S.M. Markowitz, et al., Prevalence of left atrial thrombus detection by transesophageal echocardiography: a comparison of continuous non-vitamin K antagonist oral anticoagulant versus warfarin therapy in patients undergoing catheter ablation for atrial fibrillation, *JACC Clin. Electrophysiol.* 2 (2016) 295–303.
- [20] B.F. Gage, A.D. Waterman, W. Shannon, M. Boehler, M.W. Rich, M.J. Radford, Validation of clinical classification schemes for predicting stroke: results from the National Registry of Atrial Fibrillation, *JAMA* 285 (22) (2001) 2864, <https://doi.org/10.1001/jama.285.22.2864>.
- [21] G.Y.H. Lip, R. Nieuwlaet, R. Pisters, D.A. Lane, H.J.G.M. Crijns, Refining clinical risk stratification for predicting stroke and thromboembolism in atrial fibrillation using a novel risk factor-based approach: the euro heart survey on atrial fibrillation, *Chest* 137 (2) (2010) 263–272.
- [22] H. Shimizu, Y.o. Murakami, S.-I. Inoue, Y. Ohta, K.o. Nakamura, H. Katoh, T. Sakne, N. Takahashi, S. Ohata, T. Sugamori, Y. Ishibashi, T. Shimada, High plasma brain natriuretic polypeptide level as a marker of risk for thromboembolism in patients with nonvalvular atrial fibrillation, *Stroke* 33 (4) (2002) 1005–1010.
- [23] K. Kirchhof, T. Welzel, C. Mecke, S. Zoubaa, K. Sartor, Differentiation of white, mixed, and red thrombi: value of CT in estimation of the prognosis of the thrombolysis phantom study, *Radiology* 228 (1) (2003) 126–130.
- [24] C. Teunissen, J. Habets, B.K. Velthuis, M.J. Cramer, P. Loh, Double-contrast, single-phase computed tomography angiography for ruling out left atrial appendage thrombus prior to atrial fibrillation ablation, *Int. J. Cardiovasc. Imaging* 33 (1) (2017) 121–128.
- [25] M. Dorenkamp, C. Sohns, D. Vollmann, L. Lüthje, J. Seegers, R. Wachter, M. Puls, W. Staab, J. Lotz, M. Zabel, Detection of left atrial thrombus during routine diagnostic work-up prior to pulmonary vein isolation for atrial fibrillation: role of transesophageal echocardiography and multidetector computed tomography, *Int. J. Cardiol.* 163 (1) (2013) 26–33.
- [26] R.B. Tang, J.Z. Dong, Z.Q. Zhang, Z.A. Li, X.P. Liu, J.P. Kang, R.H. Yu, D.Y. Long, C.S. Ma, Comparison of contrast enhanced 64-slice computed tomography and transesophageal echocardiography in detection of left atrial thrombus in patients with atrial fibrillation, *J. Interv. Card. Electrophysiol.* 22 (3) (2008) 199–203.
- [27] S. Achenbach, D. Sacher, D. Ropers, et al., Electron beam computed tomography for the detection of left atrial thrombi in patients with atrial fibrillation, *Heart* 90 (2004) 1477–1478.
- [28] Y.Y. Kim, A.L. Klein, S.S. Halliburton, et al., Left atrial appendage filling defects identified by multidetector computed tomography in patients undergoing radiofrequency pulmonary vein antral isolation: a comparison with transesophageal echocardiography, *Am. Heart J.* 154 (2007) 1199–1205.
- [29] W.A. Jaber, R.D. White, S.A. Kuzmiak, J.M. Boyle, A. Natale, C. Apperson-Hansen, J.D. Thomas, C.R. Asher, Comparison of ability to identify left atrial thrombus by three-dimensional tomography versus transesophageal

- echocardiography in patients with atrial fibrillation, *Am. J. Cardiol.* 93 (4) (2004) 486–489.
- [30] R. Homsí, B. Nath, J.A. Luetkens, J.O. Schwab, H.H. Schild, C.P. Naehle, Can contrast-enhanced multi-detector computed tomography replace transesophageal echocardiography for the detection of thrombogenic milieu and thrombi in the left atrial appendage: a prospective study with 124 patients, *Rofo.* 188 (2016) 45–52.
- [31] S.T. Sawit, A. Garcia-Alvarez, B. Suri, J. Gaztanaga, L. Fernandez-Friera, J.G. Mirelis, M. D'Anca, V. Fuster, J. Sanz, M.J. Garcia, Usefulness of cardiac computed tomographic delayed contrast enhancement of the left atrial appendage before pulmonary vein ablation, *Am. J. Cardiol.* 109 (5) (2012) 677–684.
- [32] J. Hur, Y.J. Kim, H.-J. Lee, J.-W. Ha, J.H. Heo, E.-Y. Choi, C.-Y. Shim, T.H. Kim, J.E. Nam, K.O. Choe, B.W. Choi, Left atrial appendage thrombi in stroke patients: detection with two-phase cardiac CT angiography versus transesophageal echocardiography, *Radiology* 251 (3) (2009) 683–690.
- [33] S.C. Kim, E.J. Chun, S.I. Choi, S.-J. Lee, H.-J. Chang, M.-K. Han, H.-J. Bae, J.H. Park, Differentiation between spontaneous echocardiographic contrast and left atrial appendage thrombus in patients with suspected embolic stroke using two-phase multidetector computed tomography, *Am. J. Cardiol.* 106 (8) (2010) 1174–1181.
- [34] J. Romero, S.A. Husain, I. Kelesidis, J. Sanz, H.M. Medina, M.J. Garcia, Detection of left atrial appendage thrombus by cardiac computed tomography in patients with atrial fibrillation: a meta-analysis, *Circ. Cardiovasc. Imag.* 6 (2) (2013) 185–194.
- [35] H. Zou, Y. Zhang, J. Tong, Z. Liu, Multidetector computed tomography for detecting left atrial/left atrial appendage thrombus: a meta-analysis, *Intern. Med. J.* 45 (10) (2015) 1044–1053.
- [36] T. Watson, E. Shantsila, G.Y.H. Lip, Mechanisms of thrombogenesis in atrial fibrillation: Virchow's triad revisited, *Lancet* 373 (9658) (2009) 155–166.