

Received: 2021.05.27

Accepted: 2021.08.04

Available online: 2021.08.13

Published: 2021.09.24

# Psoas Major and Iliopsoas Hematomas without Anticoagulant Therapy as a Complication of Carbon Monoxide Poisoning: A Case Report

## Authors' Contribution:

Study Design A  
Data Collection B  
Statistical Analysis C  
Data Interpretation D  
Manuscript Preparation E  
Literature Search F  
Funds Collection G

A 1,2 **Zhenglin Quan**  
B 2 **Huanchao Zeng**  
D 2 **Xianfu Yi**  
BC 2 **Changsheng Li**  
G 2 **Zhicheng Fang**  
DEF 2 **Xianyi Yang**

1 Department of Emergency, Taihe Hospital, Jinzhou Medical University Union Training Base, Shiyan, Hubei, PR China  
2 Department of Emergency, Taihe Hospital, Hubei University of Medicine, Shiyan, Hubei, PR China

**Corresponding Author:** Xianyi Yang, e-mail: [hbsyxy@163.com](mailto:hbsyxy@163.com)

**Financial support:** This work was supported by the Science and Technology Research and Development Project of Shiyan City (19Y36), Teaching and Research Project of Institute of Medicine Nursing, Hubei University of Medicine (YHJ2019035)

**Conflict of interest:** None declared

**Patient:** Male, 46-year-old  
**Final Diagnosis:** Carbon monoxide poisoning  
**Symptoms:** Hematoma  
**Medication:** —  
**Clinical Procedure:** Conservative management  
**Specialty:** Critical Care Medicine • Toxicology

**Objective:** Unusual clinical course

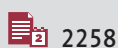**Background:** Carbon monoxide poisoning is a common reason for Emergency Department admissions worldwide. The symptoms of carbon monoxide poisoning vary from headache and dizziness to severe neuropsychological and cardiac impairment. However, psoas major and iliopsoas hematomas are a rare complication of carbon monoxide poisoning.

**Case Report:** A 46-year-old man with carbon monoxide poisoning, after he had been exposed to burning coal without proper ventilation, presented with right low back pain on day 7 after onset. After 2 days, ecchymosis of the right flank occurred, and his hemoglobin concentration gradually decreased. Psoas major and iliopsoas hematomas were shown on computed tomography (CT). The hematomas were successfully treated with transfusions and physical therapy. Owing to the absence of skeletal muscle compartment syndrome, surgical decompression was unnecessary. The patient did not receive anticoagulant therapy during his hospitalization.

**Conclusions:** The direct toxicity of carbon monoxide on the muscles and body weight-induced muscle compression caused skeletal muscle ischemia and necrosis in our patient. The risk of rhabdomyolysis and coagulation abnormality was elevated. Finally, intramuscular hemorrhages occurred in our patient. When a patient has back pain and decreased hemoglobin levels, clinicians should consider the possibility of psoas major and iliopsoas hematomas, and the administration of anticoagulation should be used with caution after admission.

**Keywords:** Anticoagulants • Hematoma • Hyperbaric Oxygenation • Psoas Muscles • Carbon Monoxide Poisoning

Full-text PDF: <https://www.amjcaserep.com/abstract/index/idArt/933322>




2258



—



1



16



## Background

Carbon monoxide poisoning is a common medical emergency worldwide [1], which results in more than 50 000 emergency department visits per year in the United States and 1500 carbon monoxide poisoning-related deaths [2]. The clinical manifestations of carbon monoxide poisoning are nonspecific. The symptoms of mild exposures to carbon monoxide are headache, myalgia, dizziness, and neuropsychological impairment [3]. Severe exposures can lead to disorders of consciousness, loss of consciousness, and even death [2]. Common complications include myocardial damage, brain edema, pulmonary edema, and delayed encephalopathy after acute carbon monoxide poisoning. However, carbon monoxide poisoning complicated with psoas major and iliopsoas hematomas have not been reported. In the present case, the hematomas were found only in the psoas major and iliopsoas, and no hematomas were found elsewhere, such as in the head, chest, and extremities. This is the first report to demonstrate that psoas major and iliopsoas hematomas can be a complication of carbon monoxide poisoning before anticoagulant therapy.

## Case Report

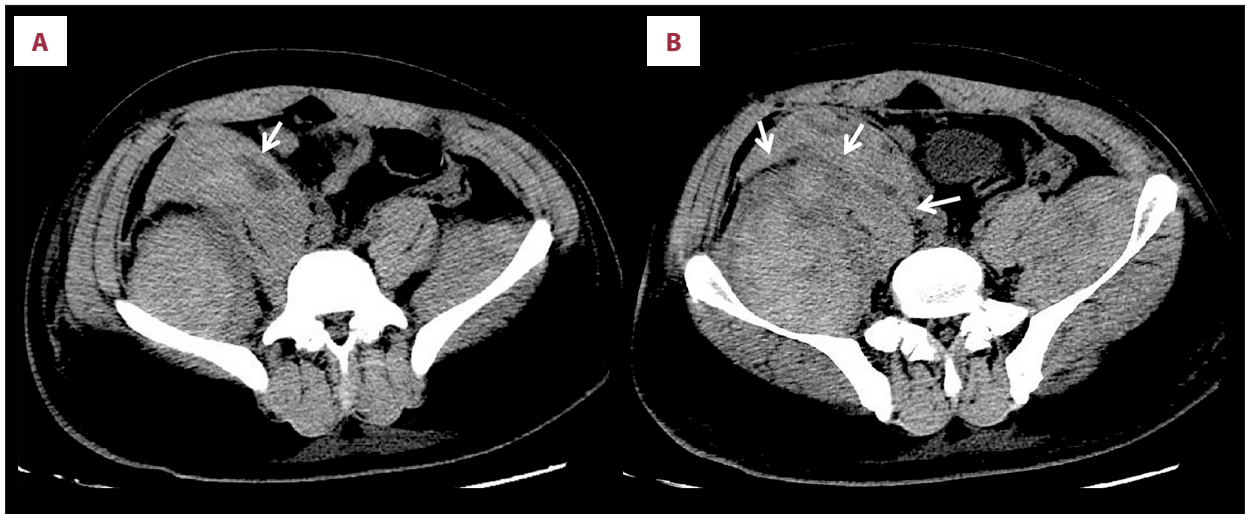A 46-year-old man was admitted to the hospital for loss of consciousness for 10 hours (day 1). He had been exposed to burning coal without proper ventilation. He had no trauma or injuries. Before admission, he lay on his bed. The patient had a history of hepatitis B virus (HBV) infection for more than 8 years and presented with inactive chronic HBV. He did not have a history of smoking or drinking alcohol. His vital signs were as follows: respiratory rate, 25 breaths/min; heart rate, 80 beats/min; blood pressure, 110/86 mmHg; and temperature, 36.5°C. He was unconscious, and his Glasgow Coma Scale score was 8. His pupils remained sluggishly reactive, with a diameter of 2.5 mm. Chest auscultation revealed rough breathing sounds. The skin was normal, without bruises or rashes, and trauma and injuries were excluded. His neurological examination result was normal. Laboratory test results revealed a red blood cell (RBC) count of  $5.14 \times 10^9/L$ , hemoglobin count of 156 g/L, carboxyhemoglobin of 58%, and white blood cell count of  $25.79 \times 10^9/L$ , with 87% neutrophils. The creatine kinase level was 4255 IU/L (reference range, 25-170 IU/L), and the creatine kinase-MB isoenzyme level was 70 IU/L (reference range, 0-17 IU/L). The serum alanine aminotransferase level was 61 U/L, and the aspartate aminotransferase level was 98 U/L. Blood coagulation function results showed a prothrombin time of 14.9 s, partial thromboplastin time of 24.9 s, and thrombin time of 13.7 s. The coagulation factor test showed a factor V of 3.2 mg/mL, antithrombin III of 271 mg/L, protein C of 81%, and protein S of 98%. Relevant examination findings of hepatitis B revealed HBV DNA levels of 1550 IU/mL. Based

on the above characteristics, the primary diagnosis was carbon monoxide poisoning and inactive hepatitis B.

After admission, the patient was treated with mechanical ventilation and symptomatic therapies, such as expectorant, diuresis, anti-infective, and myocardial support. He returned to full consciousness, and was successfully weaned off the ventilator after 3 days of mechanical ventilation. He had no symptoms, such as back pain, at that time. He continued bed rest and did not sit on the edge of the bed. Hyperbaric oxygen therapy (HBOT) was conducted twice per day while the patient was in a stable disease condition. On day 7 after onset, the patient reported having right low back pain. By day 9, the patient had right leg deep blunt pain of a sudden onset. There was no history of falling and injury during hospitalization. Physical examination showed an ecchymosis on the surface of the right flank of the abdomen, with a size of 10×9 cm, and the local tenderness was positive. A large area of ecchymosis was present in the posterolateral of the right thigh and the scrotal region. We considered that the ecchymosis was the result of blood leakage. The patient's muscle strength of both lower limbs had a Lovett scale score of 4. Emergent examination by abdominal computed tomography (CT) showed right psoas major and bilateral iliopsoas hematomas, and the fascia was thickened and swollen (**Figure 1**), with the CT mean value of 19 Hounsfield units. Abdominal ultrasonography showed an anechoic area of the bilateral iliac fossa, intra-abdomen, pelvis, and rectovesical pouch, with a greatest depth of about 14 mm, which was considered as a possible hemorrhage. No hematomas were found in other regions, such as the head, chest, and extremities.

Emergent examination by an arterial blood gas analysis showed metabolic acidosis, with a pH of 7.20 (reference range, 7.35-7.45). Blood coagulation functions showed a prothrombin time of 9.8 s, partial thromboplastin time of 53.3 s, and thrombin time of 13.6 s. Routine laboratory tests showed an RBC count of  $2.73 \times 10^{12}/L$ , hemoglobin of 63 g/dL, and a platelet count in the reference range. Comparing those parameters with those on admission, we noted that the hemoglobin concentration was decreased. The possibility of a rupture of the right psoas major hematoma was considered immediately, and the patient was given supportive transfusions of RBC and plasma and correct metabolic acidosis. The patient was considered to be hemodynamically stable. He had no marked femoral nerve compression, and there was no indication for surgical exploration or embolization. HBOT was stopped, and he was given physical therapy and external application of traditional Chinese herbal medicine. By day 12, his symptoms were relieved, and his hemoglobin was stable at 100 g/L. Because the bleeding had stopped, HBOT was continued.

Before the deep muscle hematomas occurred, there had been no tendency of bleeding in this patient, such as gum bleeding,



**Figure 1.** The abdominal computed tomography scan on day 9. White arrows (↓) indicate the hematomas in the bilateral psoas major and iliopsoas (A, B). On the right side, the white arrow indicates (A) the accumulation of blood in the psoas major with the mean value of 19 Hounsfield units, and (B) the fascia between psoas major and iliopsoas with thickening and swelling.

petechiae, hematuria, or bloody stool. The coagulation function test, coagulation factor tests, including factor V, antithrombin 3, proteins C and S, and routine laboratory tests were normal, revealing no indications of a hemorrhagic condition, such as hemophilia.

In the 4<sup>th</sup> week, the patient presented with weakness of the bilateral lower legs and an inability to stand, without cognitive decline and dementia. Magnetic resonance imaging (MRI) of the brain and an electromyogram of the bilateral lower legs did not show significant changes; therefore, we ruled out the possibility of delayed encephalopathy after acute carbon monoxide poisoning. The patient was discharged after 2 months of HBOT, neurotrophic treatment, and rehabilitation treatment. During 2 years of follow-up, the patient presented with no neuropsychiatric symptoms.

## Discussion

Carbon monoxide poisoning can lead to a severe disturbance of consciousness, brain edema, pulmonary edema, shock, and severe cardiac impairment. However, to the best of our knowledge, there has been no case of carbon monoxide poisoning complicated with psoas major and iliopsoas hematomas reported to date. The affinity of carbon monoxide for hemoglobin is more than 200 times that of oxygen, resulting in the combination of carbon monoxide with hemoglobin to form carboxyhemoglobin while the oxyhemoglobin dissociation curve shifts to the left, causing hypoxia [4]. The toxicity effect on skeletal muscle is one of the complications associated with carbon monoxide poisoning [5]. Carbon monoxide causes hypoxia by inhibiting mitochondrial respiration and impairing cellular

respiration, resulting in an inflammatory response and the production of large amounts of free radicals [2].

A hematoma of the psoas major and iliopsoas is a very rare complication. Artzner et al reported that 0.3% of patients in the intensive care unit develop iliopsoas hematomas [6], while the incidence in patients in the general ward is unclear. Age, obesity, hemodialysis, trauma, iatrogenic injury, liver disease, hematological disease, anticoagulation, and antiplatelet therapies seem to be risk factors of developing psoas major and iliopsoas hematomas [6-9]. Furthermore, nontraumatic iliopsoas hematomas are usually present in patients with hemophilia and anticoagulation therapies [7] and are even a complication of tetanus [10]. Taniguchi et al reported that sitting on the edge of the bed was associated with iliopsoas hematomas in patients with extracorporeal membrane oxygenation [11]. No previous reports have suggested a relationship between psoas major and iliopsoas hematomas and carbon monoxide poisoning, and the present case report is the first to demonstrate that psoas major and iliopsoas hematomas can be a complication of carbon monoxide poisoning.

In our report, the pathogenesis of psoas major and iliopsoas hematomas may be related to the following factors. Carbon monoxide has a direct toxic effect on tissues and cells, especially the skeletal muscle, which can subsequently lead to anaerobic metabolism, cellular hypoxia, lactic acidosis, inflammation reaction, and apoptosis [2,5]. Meanwhile, carbon monoxide can damage vascular endothelial cells and increase vascular permeability, which can lead to deep muscle hematomas. The affinity of myoglobin for carbon monoxide is lower than that of the affinity of hemoglobin for oxygen. Myoglobin-bound carbon monoxide can show accumulation in skeletal muscle due to a

weak disassociation property after exposure to carbon monoxide [5]. The present patient had a long period of bed rest, without sitting upright or having trauma after awakening. In patients with carbon monoxide poisoning, their own weight increases the pressure of the muscle compartment, leading to muscle swelling and ischemia. The waist is the center of gravity of the body, and the continuous compression of the psoas major and iliopsoas causes the production of increased carboxyhemoglobin and the aggravation of anoxia. Thus, skeletal muscle necrosis and rhabdomyolysis occur, leading eventually to hematomas. Previous literature has also indicated that HBOT should be used in cases of carbon monoxide poisoning because this treatment can improve the state of tissue hypoxia to reduce the injury induced by anoxia [12]. Acute renal failure can be caused by rhabdomyolysis, and metabolic acidosis follows. Patients with acute renal failure develop coagulation abnormalities, and the risk of hematomas also increases [13]. According to the American Association for the Study of Liver Diseases 2018 Hepatitis B Guidance, the present patient, with HBV DNA levels of 1550 IU/mL, could be diagnosed with inactive chronic HBV [14]. This patient had no previous coagulation abnormality, no previous use of anticoagulant agents, and no underlying disease associated with hemorrhagic conditions. Therefore, we ruled out the possibility of liver diseases, hidden coagulopathy, and the use of anticoagulants. This patient had no history of trauma, injury, or assault prior to or during hospitalization. There were no additional skin findings, including petechiae or bruising from the initial body examination, and although we did not perform the abdominal CT for the patient on admission, we ruled out the possibility of trauma. Therefore, we suggested that the psoas major and iliopsoas hematoma was a complication of carbon monoxide poisoning.

The clinical presentation of psoas major and iliopsoas hematomas is unspecific, including back, lower abdominal, or groin pain, anemia, limitation in hip extension and bending, positive psoas sign, femoral neuropathy, and hemodynamic instability [15]. The treatment depends on bleeding severity, hemodynamic stability, and the degree of neurological deficit of the patient [7]. In the present case, the creatine kinase level was abnormal, with a peak level of 4255U/L in the early stage, and the patient reported abdominal and back pain.

When ischemia and edema occur in the iliopsoas, rhabdomyolysis follows, leading to skeletal muscle compartment syndrome. After the hematoma ruptures, the blood flows into the abdomen, leading to acute hemorrhagic anemia. Meanwhile, the symptom of femoral nerve compression is relieved immediately after the compartment pressure decreases. When the hematomas occurred in the present patient, the examination revealed active bleeding, HBOT was stopped, and the patient was treated with conservative treatment, including bed rest, blood transfusion, hemostatic treatment, and external

application of Chinese herbal medicine, without surgical exploration or embolization, and these treatments were effective. HBOT was conducted when the hematomas were stable. The patient received more than 2 months of HBOT, and the hematomas of the psoas major and iliopsoas were finally completely absorbed. HBOT is an important adjuvant therapy in the treatment after fasciotomy, which can maximize salvaged tissue, wound healing, and overall outcomes. Applying HBOT in the early stage can prevent the need for fasciotomy altogether [16]. We had suggested an MRI to detect identify the distribution and extent of muscle damage; unfortunately, the patient refused it for economic reasons.

In the management of severe carbon monoxide poisoning, the patient can have prolonged coma and muscle weakness. This case highlights that clinicians should be on alert for toxic effects of carbon monoxide on skeletal muscle. Local body weight may induce psoas major and iliopsoas hematomas rather than hematomas in other regions, such as the extremities. Moreover, when the patient is unconscious, it can be difficult to identify back or abdominal pain from the patient. Therefore, we should perform the physical examination and imaging examination as early as possible and apply anticoagulant therapy with caution.

## Conclusions

This is the first report to describe a case of carbon monoxide poisoning complicated with psoas major and iliopsoas hematomas in a patient without anticoagulant therapy. Clinicians must be alert to the toxic effect of carbon monoxide on the skeletal muscle and be aware that the patient's own weight can increase the risk of deep muscle hematomas, especially the psoas major and iliopsoas. Thus, the possibility of psoas major and iliopsoas hematomas as a complication of carbon monoxide poisoning should be considered in patients with back pain, decreased hemoglobin, and high risk of thrombosis (eg, long period of coma or muscle weakness) and when there is evidence of rhabdomyolysis. Anticoagulation therapy should be used with caution before and during the occurrence of hematomas.

## Department and Institution Where Work Was Done

Emergency Department, Taihe Hospital, Hubei University of Medicine, Shiyan, Hubei, PR China.

## Acknowledgments

The figures were created by ACD See Photo Studio Professional 2020 (ACD Systems International Inc, Victoria, British Columbia, Canada).

## Declaration of Figures Authenticity

All figures submitted have been created by the authors who confirm that the images are original with no duplication and have not been previously published in whole or in part.

## References:

1. Prockop LD, Chichkova RI. Carbon monoxide intoxication: An updated review. *J Neurol Sci.* 2007;262(1-2):122-30
2. Weaver LK. Clinical practice. Carbon monoxide poisoning. *N Engl J Med.* 2009;360(12):1217-25
3. Amitai Y, Zlotogorski Z, Golan-Katzav V, et al. Neuropsychological impairment from acute low-level exposure to carbon monoxide. *Arch Neurol.* 1998;55(6):845-48
4. Rodkey FL, O'Neal JD, Collison HA, et al. Relative affinity of hemoglobin S and hemoglobin A for carbon monoxide and oxygen. *Clin Chem.* 1974;20(1):83-84
5. Ji JW. Acute compartment syndrome which causes rhabdomyolysis by carbon monoxide poisoning and sciatic nerve injury associated with it: A case report. *Hip Pelvis.* 2017;29(3):204-9
6. Artzner T, Clere-Jehl R, Schenck M, et al. Spontaneous ilio-psoas hematomas complicating intensive care unit hospitalizations. *PLoS One.* 2019;14(2):e0211680
7. Chan YC, Morales JP, Reidy JF, et al. Management of spontaneous and iatrogenic retroperitoneal haemorrhage: Conservative management, endovascular intervention or open surgery? *Int J Clin Pract.* 2008;62(10):1604-13
8. Ashrani AA, Osip J, Christie B, et al. Iliopsoas haemorrhage in patients with bleeding disorders – experience from one centre. *Haemophilia.* 2003;9(6):721-26
9. Llitjos JF, Daviaud F, Grimaldi D, et al. Ilio-psoas hematoma in the Intensive Care Unit: A multicentric study. *Ann Intensive Care.* 2016;6(1):8
10. Nagasawa H, Muramatsu KI, Takeuchi I, et al. A case of iliopsoas hematoma as a complication of tetanus in a patient who did not receive anticoagulant therapy. *BMC Infect Dis.* 2020;20(1):731
11. Taniguchi H, Ikeda T, Takeuchi I, Ichiba S. Iliopsoas hematoma in patients undergoing venovenous ECMO. *Am J Crit Care* 2021;30(1):55-63
12. Hampson NB, Piantadosi CA, Thom SR, et al. Practice recommendations in the diagnosis, management, and prevention of carbon monoxide poisoning. *Am J Respir Crit Care Med.* 2012;186(11):1095-101
13. Khan FY. Rhabdomyolysis: a review of the literature. *Neth J Med.* 2009;67(9):272-83
14. Terrault NA, Lok ASF, McMahon BJ, et al. Update on prevention, diagnosis, and treatment of chronic hepatitis B: AASLD 2018 hepatitis B guidance. *Hepatology.* 2018;67(4):1560-99
15. Sunga KL, Bellolio MF, Gilmore RM, et al. Spontaneous retroperitoneal hematoma: Etiology, characteristics, management, and outcome. *J Emerg Med.* 2012;43(2):e157-61
16. Hoy G, Hasenkam C, Fock A, et al. Hyperbaric oxygen as an adjunctive therapy postfasciotomy for unilateral supraspinatus rhabdomyolysis and compartment syndrome. *Case Rep Orthop.* 2018;2018:5485767