


## ORIGINAL RESEARCH

# Antibiotics in mastoid and epitympanic obliteration with S53P4 bioactive glass: A retrospective study

Lauranne Alciato MD<sup>1</sup>  | Daniele Bernardeschi MD, PhD<sup>1</sup>  |  
 Valérie Pourcher MD, PhD<sup>2,3</sup> | Naira Mkrtchyan MD<sup>1</sup> | Frédéric Tankéré MD, PhD<sup>1,4</sup> |  
 Olivier Sterkers MD, PhD<sup>1,5</sup>  | Ghislène Lahlou MD, PhD<sup>1,5</sup> 

<sup>1</sup>Sorbonne Université, AP-HP, Hôpitaux Universitaires Pitié-Salpêtrière Charles-Foix, Service d'Oto-Rhino-Laryngologie, Paris, France

<sup>2</sup>Sorbonne Université, AP-HP, Hôpitaux Universitaires Pitié-Salpêtrière Charles Foix, Service de Maladies infectieuses et Tropicales, Paris, France

<sup>3</sup>Sorbonne Université, INSERM, Institut Pierre Louis d'Épidémiologie et de Santé Publique, Groupe Hospitalier Universitaire APHP-Sorbonne Université, site Pitié-Salpêtrière, Paris, France

<sup>4</sup>Institut du Cerveau et de la Moelle épinière, ICM, Inserm U 1127, CNRS UMR 7225, Sorbonne Université, Paris, France

<sup>5</sup>Institut Pasteur, Institut de l'audition, Technologies and Gene Therapy for Deafness, Paris, France

**Correspondence**

Daniele Bernardeschi, MD, PhD, Service d'Oto-Rhino-Laryngologie, Hôpital Universitaire Pitié-Salpêtrière, 50/52 Boulevard Vincent Auriol 75013, Paris, France.  
 Email: [daniele.bernardeschi@aphp.fr](mailto:daniele.bernardeschi@aphp.fr)

**Abstract**

**Objective:** The role of antibiotics in ear surgery is still controversial. The aim of this study was to assess their need in cholesteatoma surgery when performing obliteration with S53P4 bioactive glass, a biocompatible material with antibacterial properties.

**Methods:** This retrospective cohort study was conducted in a tertiary referral center between January 2017 and May 2019. Sixty-nine consecutive patients, who underwent surgery for cholesteatoma removal and/or rehabilitation of canal-wall-down mastoidectomy with mastoid and epitympanic obliteration using S53P4 granules were included. Before 2019, antibiotics were routinely used (group “w/AB”). Patients received intravenous antibiotics during surgery, oral treatment was continued for 7 days and topical antibiotics for 1 month. After 2019, no antibiotics were administered (group “w/oAB”). The primary outcome was the occurrence of early surgical site infection. Secondary outcomes were late infection, anatomic and functional results at 3 and 12 months.

**Results:** Twenty-three patients were included in group “w/oAB” and 46 in group “w/AB”, with no significant differences in demographics, medical history or follow-up. Five ears (22%) in group “w/oAB” developed an early infection compared with 2 (4%) in group “w/AB” ( $p = .03$ ). The relative risk was 6.11, 95CI%[1.09;31.96]. Infections were successfully treated with antibiotics, and no patient underwent surgical removal of the granules. No late infections or complications were observed. There was no difference in graft failure or air-bone gap closure at 1 year.

**Conclusion:** Peri-/post-operative antibiotics prevent early infection in obliteration surgery with S53P4 granules. Infections can be treated medically without complications or require removal of the implanted material.

**Level of evidence:** 4.

**KEYWORDS**

antibiotic resistance, cholesteatoma, chronic otitis media, middle ear, surgical site infection

This is an open access article under the terms of the [Creative Commons Attribution-NonCommercial-NoDerivs](https://creativecommons.org/licenses/by-nc-nd/4.0/) License, which permits use and distribution in any medium, provided the original work is properly cited, the use is non-commercial and no modifications or adaptations are made.

© 2022 The Authors. *Laryngoscope Investigative Otolaryngology* published by Wiley Periodicals LLC on behalf of The Triological Society.

## 1 | INTRODUCTION

The role of antibiotic administration is still controversial during the peri- and post-operative periods in surgical procedures for primary or revision cholesteatoma and rehabilitation of canal-wall-down mastoidectomy. While some studies have not shown any evidence of some beneficial effect of antibiotics<sup>1-4</sup> in contaminated and dirt-infected surgery, where cholesteatoma is present, others have supported its use in reducing surgical site infections (SSIs) and/or complications.<sup>5,6</sup> Despite the lack of clinical evidence for the benefit of antibiotics in this condition, a recent state-of-the-art review recommends its use intraoperatively in clean-contaminated or contaminated surgery (Evidence: Level 2b, Grade C).<sup>7</sup> Since the misuse of antibiotics has been shown to induce bacteria-resistant strains<sup>8</sup> and expose patients to potentially serious side effects,<sup>9-14</sup> there is a real need to understand the necessity of using them in obliteration surgical procedures.

Mastoid and epitympanic obliteration is a surgical technique that has been shown to significantly reduce the rate of recurrent/residual disease in cholesteatoma surgery.<sup>15,16</sup> It has also been employed in its sequelae, such as rehabilitation of canal-wall-down mastoidectomy in the case of a troublesome cavity.<sup>17,18</sup> Many materials have been used for obliteration.<sup>16,19</sup> All large series claimed to use antibiotics when performing such a procedure.<sup>15,20-22</sup> Some of these studies reported the use of S53P4 bioactive glass (BAG) (Bonalive<sup>®</sup>, Bonalive Biomaterials Ltd.) for mastoid and epitympanic obliteration.<sup>21-28</sup> It is a bone-substitute silica-based biomaterial composed of a mixture of oxides (53% SiO<sub>2</sub>, 23% Na<sub>2</sub>O, 20% CaO, and 4% P<sub>2</sub>O<sub>5</sub>) known to have antibacterial and anti-biofilm activities. S53P4 BAG has been used as a bone graft substitute in various clinical applications including chronic osteomyelitis.<sup>29,30</sup> Its antibacterial properties have been proven in many aerobic, anaerobic, and multiresistant bacteria<sup>27,31-33</sup> and to date, no mechanism of resistance has been reported.<sup>33</sup> The inhibition of bacterial growth is probably due to the release of ions during the first stage of implantation, which causes an increase in pH and osmotic pressure.<sup>34</sup> S53P4 BAG is also effective in eradicating *Staphylococcus aureus* and *Pseudomonas aeruginosa* in biofilm formation in vitro.<sup>33,35-37</sup> Bacterial biofilms are present in cholesteatoma and may cause chronicity of infection,<sup>38</sup> since resistance is largely increased in biofilm formation, leading to failure of antibiotics.<sup>39,40</sup> In addition to surgical eradication of cholesteatoma, obliteration with S53P4 BAG could be effective in preventing bacterial biofilm formation.

Considering the antibacterial and anti-biofilm activities of S53P4 BAG and since the usefulness of antibiotics in cholesteatoma surgery is still uncertain, we questioned the use of peri-/post-operative antibiotics in mastoid and epitympanic obliteration when using S53P4 BAG. The aim of this study was to retrospectively compare two groups of patients who underwent surgery with or without peri-/post-operative antibiotics for early and late SSIs, and the 1-year anatomic and functional results.

## 2 | MATERIALS AND METHODS

This article has been revised according to the STROBE guidelines for observational studies.<sup>41</sup> The Ethics Committee of the French Society

of Oto-Rhino-Laryngology approved this retrospective cohort study (N° 2021-04-010-LA) set in a tertiary otological referral center. All patients provided written informed consent for the use of their data.

### 2.1 | Participants

The inclusion criterion was all consecutive patients who underwent surgery for cholesteatoma removal and/or rehabilitation of a canal-wall-down mastoidectomy with mastoid and epitympanic obliteration using S53P4 BAG granules performed by the senior authors between January 2017 and May 2019. The exclusion criteria were age <18 years, administration of antibiotics in the 2-week period before surgery, and incomplete data for primary outcome.

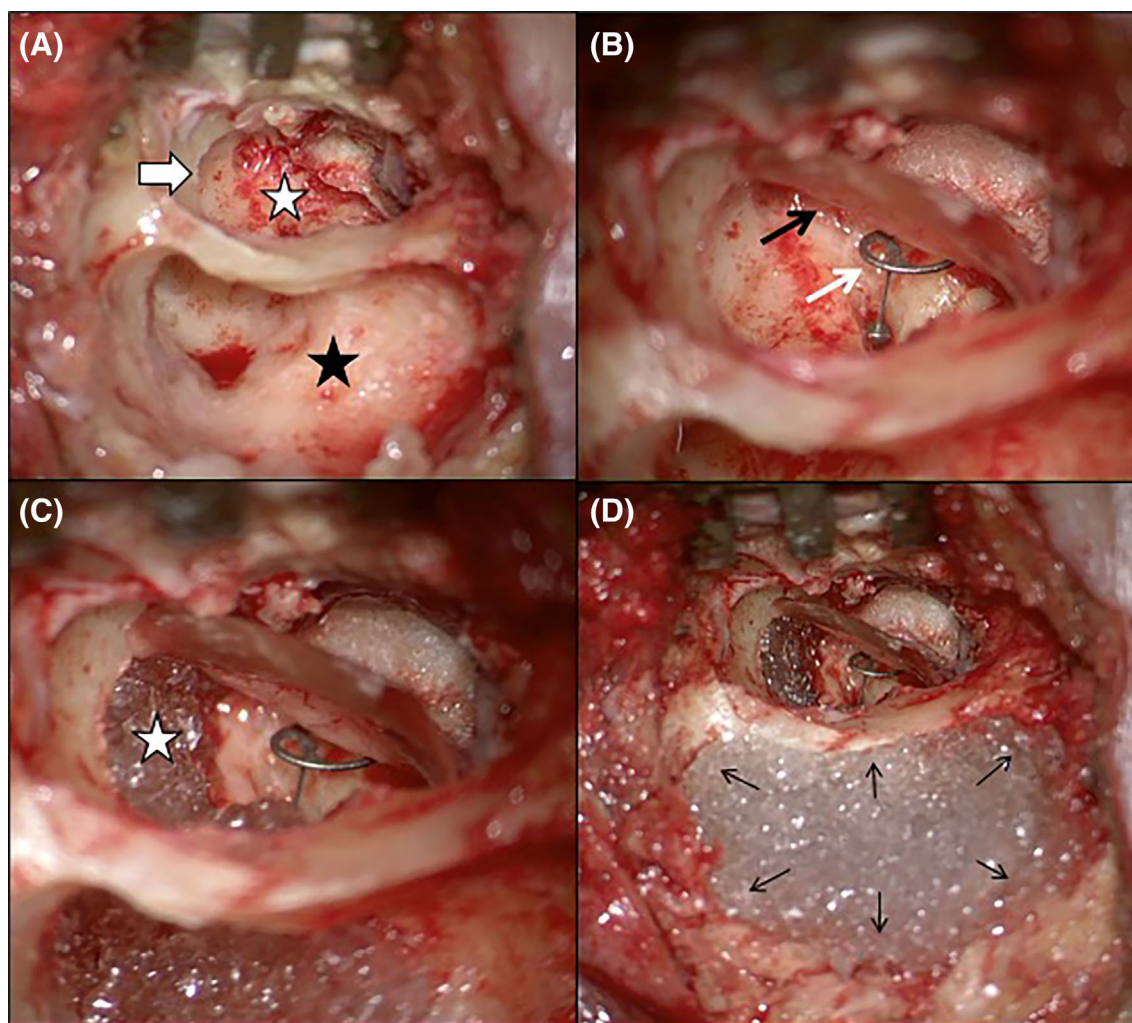
### 2.2 | Pre-operative assessment

Data from patients were analyzed for demographic characteristics and risk factors for infection (diabetes, obesity, active smokers, rhinological diseases, corticosteroid therapy, neck irradiation, and the American Society of Anesthesiologists [ASA] score<sup>42</sup>). Pre-operatively, patients underwent clinical examination, and pure-tone audiometry with both air and bone conduction performed as recommended by the Committee on Hearing and Equilibrium,<sup>43</sup> and imagery with systematic CT scans and MRI in case with suspected cholesteatoma.

### 2.3 | Surgery, antibiotic prophylaxis protocol, and perioperative assessment

The procedures were performed under general anesthesia using a facial nerve monitoring system (NIM<sup>®</sup> 3.0, Medtronic). For skin disinfection, povidone-iodine was used after shaving hair in the postauricular area. The surgical technique used for obliteration has been reported previously.<sup>22,27</sup> Briefly, lesions in the middle ear and mastoid were removed (Figure 1A), and the middle ear was reconstructed including a tympanic membrane graft (with temporalis fascia and thinned conchal cartilage) and ossiculoplasty using a titanium ossicular replacement prosthesis (Kurz<sup>®</sup>, Heinz Kurz GmbH Medzintechnik) when required<sup>44</sup> (Figure 1B). In both canal-wall-up and canal-wall-down mastoidectomies, mastoid and epitympanic obliteration was performed using granules (0.5/0.8 mm diameter) of S53P4 BAG moistened with saline solution. All the paratympanic spaces (including the anterior epitympanum and supratubal recess) were obliterated (Figure 1C) up to the level of the mastoid cortex (Figure 1D). Granules in contact with the skin of the external auditory canal were covered with cartilage and fibrous tissue.

Antibiotics were routinely administered before January 2019 (group “w/AB”). During surgery, after intraoperative bacteriological samples had been collected, patients received intravenous antibiotic prophylaxis with amoxicillin/clavulanate (2000 mg) or clindamycin (600 mg) in the case of penicillin allergy. Oral treatment



**FIGURE 1** Right canal-wall-up mastoidectomy and type 3 tympanoplasty with mastoid and epitympanic obliteration using S53P4 bioactive glass. (A) View after removal of all lesions (cholesteatoma and/or inflammatory mucosa) in the middle ear (white star) and mastoid (black star) and extensive drilling of the cavities, including a large transcanal atticotomy to control the epitympanum (white arrow). All ossicles were removed. (B) Reconstruction of the middle ear. A tympanic membrane graft is performed with the temporalis fascia and thinned conchal cartilage (black arrow), and a total ossicular replacement prosthesis is placed (white arrow). (C) Obliteration with S53P4 bioactive glass. All of the paratympenic spaces, including the anterior epitympanum and supratubal recess (white star), are filled with S53P4 granules, taking care to avoid contact between the granules and prosthesis. (D) Obliteration is continued up to the level of the mastoid cortex (black arrows)

with amoxicillin/clavulanate (1000 mg, three times daily) or clindamycin (600 mg, three times daily) was continued post-operatively until the first post-operative visit (usually 7 days after surgery). Ofloxacin ear drops were administered for 1 month. After 2019, the senior authors did not administer antibiotics to patients (group “w/oAB”). Instead of ofloxacin, antiseptic drops (H<sub>2</sub>O<sub>2</sub> solution 100 g + boric acid 2.50 g + sodium borate 0.50 g) were prescribed for 1 month. These drops were used to wet the bioresorbable ear packing with esterified hyaluronic acid (MeroGel®, Medtronic) to facilitate its absorption and its removal by aspiration 1 month after surgery.

Aerobic bacteriological samples were collected during surgery. The surgical procedure, presence of cholesteatoma, its extent following the STAMCO classification<sup>45</sup> and duration of surgery were recorded.

## 2.4 | Post-operative assessment

Post-operatively, the patients underwent clinical examination by an otologist 1 week, and 1, 3, and 12 months after surgery. Infectious complications (retroauricular swelling, discharge and/or abscess, purulent otorrhea, perichondritis, periauricular cellulitis), facial palsy, signs of labyrinthitis (worsening of the bone-conducted hearing threshold, vertigo), and the presence of fever or unusual pain were noted. In the case of SSI, bacteriological samples were collected from the external auditory canal or retroauricular wound.

Anatomic results were evaluated using otomicroscopy at 3 and 12 months: dry ear with an intact tympanic membrane and external auditory canal was considered to indicate a successful procedure. Functional results were evaluated at 3 and 12 months using the air-bone gap (ABG) closure, defined as the difference between pre-

operative and post-operative ABG. The ABG was calculated using the pure-tone average (mean of 500–1000–2000–4000 Hz) in both air conduction and bone conduction conditions.<sup>43</sup>

The primary outcome was the occurrence of an early SSI, defined as an infection occurring within the first month after surgery.<sup>46,47</sup> Secondary outcomes in the two groups were the occurrence of late SSI (after the first month) and the anatomic and functional results 3 and 12 months after surgery. If an SSI occurred, the bacteria responsible, any complications due to the infection, and its management were reported.

## 2.5 | Statistical analysis

This was performed using Prism for macOS (GraphPad Software). Quantitative data are presented as mean  $\pm$  SEM; Student's *t* test was performed for normally distributed data and the Mann-Whitney test for data that were not normally distributed. Differences in pre-operative and post-operative pure-tone audiometry thresholds and ABG were analyzed using a paired *t* test or two-way ANOVA. Fisher's exact test was used to analyze qualitative data. SSI rate was calculated as the proportion of patients who developed an SSI over 1 month (early SSI) or from 1 month to 1 year (late SSI) after surgery, for groups "w/AB" and "w/oAB." SSI rate was then contrasted as the relative risk with a 95% confidence interval (CI).

For all comparisons,  $p < .05$  was considered to indicate a statistically significant difference.

## 3 | RESULTS

### 3.1 | Population and pre-operative data

In total, 69 ears (67 patients) were divided into two groups. Twenty-three ears (23 patients) operated on without antibiotics were included in group "w/oAB," represented by 14 men (61%) and 9 women (39%) with a mean age of  $42 \pm 3.7$  (18–68) years. Forty-six ears (44 patients) operated on with antibiotics were included in group "w/AB" represented by 26 males (57%) and 20 females (43%) with a mean age of  $46 \pm 2.4$  (19–76) years. There were no significant differences in terms of demographic characteristics or risk factors for infection between the two groups (Table 1). The mean pre-operative air and bone conduction thresholds were, respectively,  $52 \pm 5.5$  dB and  $26 \pm 4.3$  dB in group "w/oAB" and  $53 \pm 2.4$  dB and  $26 \pm 2.3$  dB in group "w/AB" (ns).

### 3.2 | Surgery and intraoperative findings

Surgery was mostly revision procedures: 15 (65%) in group "w/oAB" and 33 (72%) in group "w/AB" (ns) (Table 1). In group "w/oAB," 14 (61%) underwent a canal-wall-up mastoidectomy, and 9 (39%) a canal-wall-down mastoidectomy. In group "w/AB," 29 (63%) underwent a canal-wall-up mastoidectomy, and 17 (37%) a canal-wall-down

mastoidectomy. Cholesteatoma was present in 15 ears (65%) in group "w/oAB" and in 36 ears (78%) in group "w/AB" (ns). The groups were comparable in terms of the STAM classification, complications caused by cholesteatoma, and ossicular chain status. Tympanoplasties were mostly represented by type 2 (partial ossicular replacement prosthesis used on intact stapes) and type 3 (total ossicular replacement prosthesis used on an intact footplate) in both groups (Table 1). The mean duration of surgery was  $147 \pm 10.2$  (90–300) minutes in group "w/oAB" and  $127 \pm 5.0$  (80–250) minutes in group "w/AB" (ns). Patients were mostly operated on as outpatient, 13 (57%) in group "w/oAB" and 19 (41%) in group "w/AB." With regard to length of hospitalization after surgery, the mean duration was  $1 \pm 0.1$  day in both groups. No hospitalization was prolonged because of infectious complications.

Intraoperative bacteriological tests were performed in 23 ears in group "w/oAB" and in 44 ears in group "w/AB." In group "w/oAB," 5 ears (22%), including 3 with cholesteatoma were aseptic for all samples compared with 15 ears (34%), including 9 with cholesteatoma in group "w/AB" (ns). In the other cases, commensal and pathogenic bacteria and fungi were identified, sometimes in association (Table 2).

### 3.3 | Post-operative results

The mean follow-up period was  $17 \pm 1.4$  (3–26) and  $14 \pm 1.1$  (3–36) months in groups "w/oAB" and "w/AB," respectively. Data from all patients were analyzed for primary outcome (Table 3).

In group "w/oAB," five cases from 23 (22%) were found to have an early SSI, three within the first week after surgery, and two within the first month (Table 4). On the other hand, only 2 cases from 46 (4%) in group "w/AB" developed an early SSI ( $p = .03$ , Fisher's exact test), one within the first week after surgery, and the other within the first month. The relative risk of early SSIs was 6.11, 95%CI[1.09;31.96]. SSIs were represented by purulent retroauricular discharge (5 cases) and purulent otorrhea (2 cases). The bacteria responsible are listed in Table 4. In four cases (57%), the same bacteria were identified on intraoperative bacteriological tests. All infections were successfully treated with adapted treatment: oral antibiotics in five cases, intravenous antibiotics in one case, and local antifungal in one case. No late SSI occurred in either group "w/oAB" or "w/AB." No revision surgery with material removal was necessary. One patient in group "w/oAB" underwent excision of a small retroauricular fistula under local anesthesia at 3 months. No complications (facial palsy, labyrinthitis, meningitis, intracranial empyema or abscess, or systemic infection) were noted due to these infections. No antibiotic-related complications have been reported.

After 3 months, three patients (13%) and eight patients (17%) were lost to follow-up in groups "w/oAB" and "w/AB," respectively. There was no significant difference in anatomic and functional results between the two groups at 3 and 12 months (Table 3). All but two patients had an intact tympanic membrane at the last follow-up: two residual perforations were observed in group "w/AB" and none in group "w/oAB" (ns). At 12 months, the mean post-operative air and bone conduction thresholds were  $38 \pm 5.1$  dB and  $19 \pm 3.3$  dB in group "w/oAB" and  $44 \pm 2.9$  dB and  $24 \pm 2.6$  dB in group "w/AB,"

respectively (ns). The mean ABG closure was  $7 \pm 2.5$  dB and  $6 \pm 2.3$  dB in group “w/oAB” and “w/AB,” respectively (ns), showing a significant improvement between pre- and post-operative ABG in both groups ( $p < .01$  in group “w/oAB” and  $p = .02$  in group “w/oAB,” paired t test).

## 4 | DISCUSSION

The role of antibiotic prophylaxis in surgery is to reduce the risk of SSI by limiting bacterial proliferation, and to prevent SSI-related morbidity

and mortality.<sup>48</sup> Its benefits in surgery for cholesteatoma are still subject to debate, resulting in the inappropriate use of antibiotics. A Cochrane review analyzing 11 randomized controlled trials did not find any difference in anatomic and functional results or complications between groups receiving perioperative antibiotics compared with placebo or no prophylaxis.<sup>49</sup> Despite this, in a recent paper on evidence-based use of perioperative antibiotics, Patel et al. recommended intraoperative antibiotic use with little evidence for this approach.<sup>7</sup> Given the paucity of studies on this topic and its potential implications, not only for ENT but also for public health issues, any additional data to add to the existing literature should be encouraged.

**TABLE 1** Patients' demographic characteristics, risk factors for infection, pre-operative audiometry and surgical procedure

	w/AB (n = 46)	w/oAB (n = 23)	p
No (%) with data	46 (100)	23 (100)	
Age, mean (SEM), years	46 (2.4)	42 (3.7)	.41 <sup>a</sup>
Male, no (%)	26 (57)	14 (61)	.80 <sup>b</sup>
Risk factors for infection			
Diabetes, no (%)	3 (7)	2 (9)	> 0.99 <sup>b</sup>
Obesity, no (%)	2 (4)	2 (9)	.60 <sup>b</sup>
Active smokers, no (%)	14 (30)	5 (22)	.57 <sup>b</sup>
Rhinologic diseases, no (%)	2 (4)	2 (9)	.60 <sup>b</sup>
Corticosteroid therapy, no (%)	0	1 (4)	.33 <sup>b</sup>
Head and neck irradiation, no (%)	0	0	
ASA score			.79 <sup>b</sup>
1, no (%)	30 (65)	14 (61)	
2, no (%)	16 (35)	9 (39)	
Preoperative PTA			
AC-PTA, mean (SEM), dB	53 (2.4)	52 (5.5)	.84 <sup>c</sup>
BC-PTA, mean (SEM), dB	26 (2.3)	26 (4.3)	.36 <sup>a</sup>
ABG, mean (SEM), dB	27 (1.7)	26 (2.7)	.82 <sup>a</sup>
Previous surgery			.59 <sup>b</sup>
0, no (%)	13 (28)	8 (35)	
≥ 1, no (%)	33 (72)	15 (65)	
Cholesteatoma, no (%)	36 (78)	15 (65)	.26 <sup>b</sup>
STAMCO classification*, No (%)			
STAM1, no (%)	6 (18)	2 (14)	
STAM2, no (%)	7 (20)	6 (43)	
STAM3, no (%)	21 (62)	6 (43)	
Cn, no (%)	26 (76)	13 (93)	
C1, no (%)	8 (24)	1 (7)	
C2, no (%)	0	0	
On, no (%)	6 (18)	5 (36)	
O1, no (%)	8 (24)	1 (7)	
O2, no (%)	11 (32)	3 (21)	
O3, no (%)	11 (32)	5 (33)	
CWU			
Primary, no (%)	17 (36)	8 (35)	> 0.99 <sup>b</sup>
Revision, no (%)	12 (26)	6 (26)	.77 <sup>b</sup>

TABLE 1 (Continued)

	w/AB (n = 46)	w/oAB (n = 23)	p
CWD			
Primary, no (%)	5 (11)	0	.16 <sup>b</sup>
Revision, no (%)	12 (26)	9 (39)	.28 <sup>b</sup>
Recurrent cholesteatoma, no (%)	5 (11)	1 (4)	.66 <sup>b</sup>
Rehabilitation, no (%)	7 (15)	8 (35)	.34 <sup>b</sup>
Type of tympanoplasty			
1, no (%)	3 (7)	0	.55 <sup>b</sup>
2, no (%)	26 (57)	14 (61)	.80 <sup>b</sup>
3, no (%)	16 (35)	8 (35)	> 0.99 <sup>b</sup>
4, no (%)	1 (2)	1 (4)	> 0.99 <sup>b</sup>
Duration, mean (SEM), min	127 (5.0)	147 (10.2)	.09 <sup>a</sup>

Abbreviations: AB, antibiotics; ABG, air-bone gap; AC, air conduction; ASA, American Society of Anesthesiologists; BC, bone conduction; CWD, canal-wall-down; CWU, canal-wall-up; no, number; PTA, pure-tone audiometry; SEM, standard error of mean; w/, with; w/o, without.

<sup>a</sup>Mann-Whitney test.

<sup>b</sup>Fisher's exact test.

<sup>c</sup>Student's *t* test.

<sup>d</sup>STAMCO cholesteatoma classification system: registration of the extent of cholesteatoma (STAM), complications (C), and ossicular chain status (O) during surgery.

With this in mind, we aimed to evaluate the usefulness of antibiotics in mastoid and epitympanic obliteration for cholesteatoma using S53P4 BAG, a biomaterial known to have antibacterial and anti-biofilm activities.

#### 4.1 | Key results

Our results showed that the relative risk of developing an early SSI was higher in patients not receiving any antibiotic than in those receiving peri-/post-operative antibiotics. This indicates that antibiotics are necessary to prevent SSI. This is in line with the observations of Govaerts et al., who found that antibiotic prophylaxis decreased the early SSI rate in contaminated and dirty ear surgical procedures.<sup>5</sup> In their protocol, perioperative cefuroxime was used in the antibiotic group. The external auditory canal was packed with antibiotic ointment in both groups. Whether any obliteration was performed or not was not specified. Similar results were obtained by Pierce et al., who found a higher incidence of SSI in patients receiving no perioperative antibiotics compared with clindamycin and ceftazidime administered within 1 h before incision.<sup>6</sup> As in Govaerts et al.'s paper, all patients received post-operative otological antibiotic drops, and no mention of an obliteration procedure was detailed.

In a systematic review of single-stage mastoid obliteration in cholesteatoma surgery (with many different materials, including bone pâté, cartilage, hydroxyapatite, glass ceramic crystals, macroporous biphasic calcium phosphate, or abdominal fat), van der Toom et al. reported an SSI rate of 4.9%, which is comparable to that observed in our group of patients with antibiotics.<sup>16</sup>

In our study, all patients with an early SSI were treated with antibiotics, and no revision surgery was necessary to remove the implanted

material. This point must be emphasized because heterologous material risks forming a biofilm on its surface when an SSI occurs, forcing the implanted material to be removed. It is likely that the antibacterial properties of S53P4 BAG alone are insufficient to prevent SSI but could prevent biofilm formation and thus allow medical treatment of the infection without revision surgery for the removal of granules. This is in contrast to what was observed when we used another biosynthetic material (biphasic ceramic granules formed by hydroxyapatite and tricalcium phosphate) that had no antibacterial properties with the same antibiotic prophylaxis protocol: 3 cases of SSI occurred in 59 patients (5.1%), and in all cases, we had to remove the granules.<sup>18</sup> Several studies using other biomaterials in obliteration surgery have also reported the need to remove infected material,<sup>16,50-53</sup> whereas no study using S53P4 presented cases of surgical removal for infection.<sup>19,20-28</sup> Therefore, S53P4 BAG seems to provide an important advantage when performing mastoid obliteration, since even in the case of SSI, it is easily treatable with antibiotics.

No local or intracranial complications were observed in our study. No late SSIs occurred in either group, and there were no differences in anatomic and functional results at the last follow-up visit. In the literature, no cases of complications or late SSIs have been reported with S53P4 BAG.<sup>20-28</sup> This important point deserves mention since, even in the case of SSI, there is no increased risk for the patient if the infection is correctly managed. These results confirm the idea of antibacterial and anti-biofilm activities of S53P4 BAG and encourage the rational prescription of antibiotic prophylaxis. However, authors usually reported the use of antibiotics, including intravenous doses during surgery (cefazoline or amoxicillin/clavulanate), continued post-operatively orally for a week (amoxicillin/clavulanate or amoxicillin) when using S53P4 BAG.<sup>21,25,26</sup> No information regarding the use of topical drops was provided.

Moreover, a recent study showed that S53P4 BAG seems to have an inhibitory effect on keratinocyte growth in vitro,<sup>54</sup> thus

adding another attractive feature, especially in cholesteatoma. Finally, a recent systematic review of mastoid obliteration with bio-synthetic materials indicated that S53P4 BAG is a very reliable material<sup>19</sup>; its volume remains stable over time, and it can easily be differentiated from the common pathologies of the temporal bone on imaging.<sup>55</sup>

## 4.2 | Strengths and limitations

Some strengths of this study should be mentioned. A relatively homogeneous population with regard to pathology and ear status was included in this study, all patients experiencing cholesteatoma or its sequelae. This allowed us to focus our attention on dirty/

	w/AB (n = 44)	w/oAB (n = 23)	p
Aseptic, no (%)	15 (34)	5 (22)	.40 <sup>a</sup>
Aseptic and cholesteatoma, no (%)	9 (20)	3 (13)	.52 <sup>a</sup>
<i>Staphylococcus</i> <sup>b</sup> , no (%)	14 (32)	11 (48)	.29 <sup>a</sup>
<i>S. epidermidis</i>	6 (14)	6 (26)	
<i>S. capitis</i>	2 (5)	3 (13)	
<i>S. aureus</i>	3 (7)	1 (4)	
<i>S. lugdunensis</i>	1 (2)	2 (9)	
<i>S. auricularis</i>	0	2 (9)	
<i>S. caprae</i>	1 (2)	1 (4)	
<i>S. saprophyticus</i>	1 (2)	0	
<i>S. haemolyticus</i>	1 (2)	0	
<i>S. pettekoferi</i>	1 (2)	0	
<i>S. warneri</i>	1 (2)	0	
<i>Cutibacterium acnes</i> , no (%)	6 (14)	10 (43)	.01 <sup>a</sup>
<i>Turicella otitidis</i> , no (%)	4 (9)	1 (4)	.65 <sup>a</sup>
<i>Pseudomonas aeruginosa</i> , no (%)	1 (2)	1 (4)	>.99 <sup>a</sup>
<i>Haemophilus influenza</i> , no (%)	0	1 (4)	
<i>Corynebacterium</i> , no (%)			
<i>C. amycolatum</i>	0	1 (4)	
<i>C. accolens</i>	0	1 (4)	
<i>C. tuberculostearicum</i>	1 (2)	0	
<i>Actinomyces</i> , no (%)			
<i>A. odontolyticus</i>	1 (2)	0	
<i>A. urogenitalis</i>	1 (2)	0	
<i>Actinotignum schaalii</i>	1 (2)	0	
<i>Kocuria</i> sp.	0	1 (4)	
<i>Enterobacteriaceae</i> , no (%)			
<i>Klesbiella pneumoniae</i>	0	1 (4)	
<i>Enterococcus faecalis</i>	1 (2)	0	
Polymorphic bacterial flora, no (%)	2 (5)	0	
Anaerobic flora	1 (2)	0	
<i>Candida</i> , no (%)			
<i>C. albicans</i>	2 (5)	1 (4)	>.99 <sup>a</sup>
<i>C. parapsilosis</i>	2 (5)	2 (9)	.60 <sup>a</sup>
<i>Aspergillus</i> , no (%)			
<i>A. welwitschiae</i>	1 (2)	0	
<i>A. flavus</i>	1 (2)	0	

**TABLE 2** Results for intraoperative bacteriological test (n = 67)

Abbreviations: AB, antibiotics; no, number; w/, with; w/o, without.

<sup>a</sup>Fisher's exact test.

<sup>b</sup>*Staphylococcus* was the most frequent bacterial genus, represented by different species, usually found in association in the same ear.

**TABLE 3** Follow-up, outcomes and main results

	w/AB (n = 46)	w/oAB (n = 23)	p
Follow-up, mean (SEM), months	14 (1.1)	17 (1.4)	
<b>SSIs</b>			
Early SSIs, no (%)	2 (4)	5 (22)	.03 <sup>a</sup>
Retroauricular swelling or abscess	2	3	
Purulent otorrhea	0	2	
Late SSIs, no (%)	0	0	
<b>M3</b>			
No (%) with data	46 (100)	23 (100)	>.99 <sup>a</sup>
Dry ear, no (%)	45 (98)	23 (100)	>.99 <sup>a</sup>
Intact TM, no (%)	45 (98)	23 (100)	>.99 <sup>a</sup>
Intact EAC, no (%)	46 (100)	23 (100)	>.99 <sup>a</sup>
AC-PTA, mean (SEM), dB	44 (2.7)	47 (5.8)	.90 <sup>b</sup>
BC-PTA, mean (SEM), dB	23 (2.5)	27 (5.2)	.86 <sup>b</sup>
ABG, mean (SEM), dB	21 (1.4)	21 (2.6)	.87 <sup>c</sup>
<b>M12</b>			
No (%) with data	38 (83)	20 (87)	.74 <sup>a</sup>
Dry ear, no (%)	36 (95)	20 (100)	>.99 <sup>a</sup>
Intact TM, no (%)	36 (95)	20 (100)	>.99 <sup>a</sup>
Intact EAC, no (%)	38 (100)	20 (100)	>.99 <sup>a</sup>
AC-PTA, mean (SEM), dB	44 (2.9)	38 (5.1)	.07 <sup>b</sup>
BC-PTA, mean (SEM), dB	24 (2.6)	20 (3.3)	.20 <sup>b</sup>
ABG, mean (SEM), dB	21 (1.8)	17 (2.9)	.32 <sup>c</sup>
ABG closure, mean (SEM), dB	6 (2.3)	7 (2.5)	.69 <sup>c</sup>

Abbreviations: AB, antibiotics; ABG, air-bone gap; AC, air conduction; BC, bone conduction; EAC, external auditory canal; M3, follow-up at 3 months; M12, follow-up at 12 months; no, number; PTA, pure-tone audiometry; SEM, standard error of mean; SSIs, surgical site infections; TM, tympanic membrane; w/, with; w/o, without.

<sup>a</sup>Fisher's exact test.

<sup>b</sup>Mann-Whitney test.

<sup>c</sup>Student's t test.

contaminated ear surgery, where peri-/post-operative antibiotics are generally recommended. We focused our attention solely on cases who underwent surgery for mastoid obliteration and, to the best of our knowledge, as yet, no other studies have been published comparing antibiotic protocols when performing mastoid obliteration. In fact, all large series of mastoid obliteration cases claimed to use peri-/post-operative antibiotics.<sup>15,20-22,24-27</sup> Moreover, the surgical technique and post-operative follow-up were quite homogenous, reducing the possibility of bias due to these variables. Finally, the total absence of any antibiotics (either general or local) in the group treated without antibiotics made comparison with the group treated with antibiotics more reliable.

This study had several important limitations that could affect the interpretation and generalization of our results. The retrospective design introduced methodological biases that were difficult to overcome. The follow-up was not long enough to provide meaningful results about cholesteatoma recidivism. Even though this was not the aim of this study, one could assume that, with longer follow-up, there

might be differences between groups. The limited number of patients included have restricted the validity of the results, and the statistical power of the study was low.

### 4.3 | Interpretation

Therefore, our results should be interpreted with caution. Peri-/post-operative antibiotics seem to reduce the incidence of SSI. However, when SSI occurs, it can be treated with antibiotics without revision surgery, complications, or increased risk for the patient. Therefore, from the point of view of the patient and surgeon, peri-/post-operative antibiotic therapy can be recommended.<sup>5</sup> Nevertheless, from the standpoint of limiting the use of antibiotics, and in order to reduce their associated complications, this recommendation can no longer be valid since, in the group with no peri-/post-operative antibiotics, we limited their prescription to only a few who developed an SSI. Moreover, this approach limits health costs.



TABLE 4 Characteristics and findings in patients who developed a surgical site infection

Pt. Group	Age (y)	Risk factors for infection	ASA Surgery	Surgical Chol. complications	Length (min)	SSIs	Time	Intraop. bacteriological tests	Postop. bacteriological tests <sup>a</sup>	Systemic treatment	Local treatment	Postop. complications
1. w/AB	22	Smoking	1 Revision CWU, tymp. 3	Yes None	190	Retro-auricular discharge	1st week	<i>P. aeruginosa</i> (sensitive to FQ and C3G)	<i>P. aeruginosa</i> (sensitive to FQ and C3G)	Oral Ciprofloxacin	Ofoxacin	None
2. w/AB	76	None	2 Primary CWD, tymp. 2	Yes Tegmen defect; Lateral SCC fistula	110	Retro-auricular discharge	1st month	<i>C. albicans</i> (NA)	<i>C. albicans</i> (sensitive to all antifungal tested)	None	Antifungal	None
3. w/oAB	19	Smoking	1 Revision CWD, tymp. 3	Yes None	90	Purulent otorrhea	1st month	<i>S. epidermidis</i> ; <i>S. capitis</i> (both sensitive to Oxa and Clinda, Clinda, resistant to Amox)	<i>S. aureus</i> (sensitive to Oxa and Clinda, resistant to Amox); <i>Corynebacterium amycolatum</i> (NA)	Oral Pristinamycin	Dexa-Nystatin-PolymyxinB	None
4. w/oAB	67	Diabetic	2 Primary CWU, tymp. 2	Yes None	200	Retro-auricular discharge	1st month	Aseptic	<i>Citrobacter koseri</i> (sensitive to Amox/Clav); <i>S. epidermidis</i> (NA)	Intravenous C3G + Clinda (3 days) followed by oral Amox/Ac	Ofoxacin	None
5. w/oAB	18	None	1 Revision CWU, tymp. 4	Yes Tegmen defect	110	Retro-auricular discharge	1st week	<i>S. lugdunensis</i> (sensitive to Oxa, Amox and Clinda)	<i>S. lugdunensis</i> (sensitive to Oxa, Amox and Clinda); <i>S. epidermidis</i> (NA)	Oral Pristinamycin	Ofoxacin	None
6. w/oAB	41	None	1 Revision CWD, tymp. 2	No SS injury	90	Purulent otorrhea	1st week	Aseptic	<i>Enterobacter cloacae</i> (NA); <i>Streptococcus oralis</i> (NA); <i>Streptococcus constellatus</i> (NA); <i>Corynebacterium amycolatum</i> (NA)	Oral Amox/Ac	Dexa-Neomycin-PolymyxinB	None
7. w/oAB	36	Smoking; Rhinologic disease	1 Primary CWU, tymp. 2	Yes None	130	Perichondritis and retro-auricular discharge	1st week	<i>S. aureus</i> (sensitive to Oxa, Amox and Clinda); <i>S. epidermidis</i> (NA); <i>Cutibacterium acnes</i> (NA)	<i>S. aureus</i> (sensitive to Oxa, Amox and Clinda)	Oral Amox/Ac + Ciprofloxacin	Ofoxacin	Retro-auricular fistula

Abbreviations: AB, antibiotics; ASA, American Society of Anesthesiologists (score); C., Candida; C3G, cephalosporins 3rd generation; Chol., cholesteatoma; CWD, canal-wall-down; CWU, canal-wall-up; FQ, fluoroquinolones; Intraop., intra-operative; min, minutes; NA, not available; P., Pseudomonas; Postop., post-operative; Pt., patient; SCC, semicircular canal; S., *Staphylococcus*; SS, sigmoid sinus; SSI, surgical site infection; Tymp., tympanoplasty (type); w/, with; w/o, without; y, years.

<sup>a</sup>Post-operative bacteriological tests were performed on retroauricular discharge or purulent otorrhea.

It is also important to note that our results were obtained using S53P4 BAG, which exhibits antibacterial properties. The generalization can be limited if other materials are used.

## 5 | CONCLUSION

The use of peri-/post-operative antibiotics appears to reduce SSIs when dealing with contaminated and dirty ear surgical procedures for obliteration. When an infection occurs, S53P4 BAG can allow it to be treated medically without the need to surgically remove the implanted material. Further prospective studies are necessary to confirm these results in order to reduce the consumption of antibiotics.

## CONFLICTS OF INTEREST

The authors declare that there is no conflicts of interest.

## ORCID

Lauranne Alciato  <https://orcid.org/0000-0001-5928-1511>

Daniele Bernardeschi  <https://orcid.org/0000-0002-5937-8847>

Ghizlène Lahlou  <https://orcid.org/0000-0002-1067-045X>

## REFERENCES

- Jackson CG. Antimicrobial prophylaxis in ear surgery. *Laryngoscope*. 1988;98(10):1116-1123.
- Hester TO, Jones RO. Prophylactic antibiotics in surgery for chronic ear disease. *Laryngoscope*. 1998;108(9):1334-1337.
- Winerman I, Segal S, Man A. Effectiveness of prophylactic antibiotic treatment in mastoid surgery. *Am J Otol*. 1981;3(1):65-67.
- Bertrand M, Mangez J-F, Choussy O, Dehesdin D, Marie J-P. Comparison of two antibioprophyllaxis protocols in ear surgery. *Ann Otolaryngol Chir Cervicofac*. 2008;125(3):115-121.
- Govaerts PJ, Raemaekers J, Verlinden A, Kalai M, Somers T, Offeciers FE. Use of antibiotic prophylaxis in ear surgery. *Laryngoscope*. 1998;108(1 Pt 1):107-110.
- Pierce NE, Antonelli PJ. Efficacy of antibiotic prophylaxis prior to tympanoplasty for contaminated cholesteatoma. *Laryngoscope*. 2016;126(10):2363-2366.
- Patel PN, Jayawardena ADL, Walden RL, Penn EB, Francis DO. Evidence-based use of perioperative antibiotics in otolaryngology. *Otolaryngol Head Neck Surg*. 2018;158(5):783-800.
- Laxminarayan R, Duse A, Wattal C, et al. Antibiotic resistance—the need for global solutions. *Lancet Infect Dis*. 2013;13(12):1057-1098. doi:10.1016/S1473-3099(13)70318-9
- Cox LM, Blaser MJ. Antibiotics in early life and obesity. *Nat Rev Endocrinol*. 2015;11(3):182-190.
- Rasmussen SH, Shrestha S, Bjerregaard LG, et al. Antibiotic exposure in early life and childhood overweight and obesity: a systematic review and meta-analysis. *Diabetes Obes Metab*. 2018;20(6):1508-1514.
- Mahana D, Trent CM, Kurtz ZD, et al. Antibiotic perturbation of the murine gut microbiome enhances the adiposity, insulin resistance, and liver disease associated with high-fat diet. *Genome Med*. 2016;8(1):48.
- Stokholm J, Sevelsted A, Bønnelykke K, Bisgaard H. Maternal propensity for infections and risk of childhood asthma: a registry-based cohort study. *Lancet Respir Med*. 2014;2(8):631-637.
- Pedersen TM, Stokholm J, Thorsen J, Mora-Jensen A-RC, Bisgaard H. Antibiotics in pregnancy increase children's risk of otitis media and ventilation tubes. *J Pediatr*. 2017;183:153-158.e1.
- McDonald LC, Gerding DN, Johnson S, et al. Clinical practice guidelines for clostridium difficile infection in adults and children: 2017 update by the Infectious Diseases Society of America (IDSA) and Society for Healthcare Epidemiology of America (SHEA). *Clin Infect Dis*. 2018;66(7):987-994.
- van Dinther JJS, Vercruyse J-P, Camp S, et al. The bony obliteration tympanoplasty in pediatric cholesteatoma: long-term safety and hygienic results. *Otol Neurotol*. 2015;36(9):1504-1509.
- van der Toom HFE, van der Schroeff MP, Pauw RJ. Single-stage mastoid obliteration in cholesteatoma surgery and recurrent and residual disease rates: a systematic review. *JAMA Otolaryngol Head Neck Surg*. 2018;144(5):440-446.
- Vercruyse J-P, van Dinther JJS, De Foer B, et al. Long-term results of troublesome CWD cavity reconstruction by mastoid and epitympanic bony obliteration (CWR-BOT) in adults. *Otol Neurotol*. 2016;37(6):698-703.
- Bernardeschi D, Nguyen Y, Mosnier I, Smail M, Ferrary E, Sterkers O. Use of granules of biphasic ceramic in rehabilitation of canal wall down mastoidectomy. *Eur Arch Otorhinolaryngol*. 2014;271(1):59-64.
- Skoulakis C, Koltsidopoulos P, Iyer A, Kontorinis G. Mastoid obliteration with synthetic materials: a review of the literature. *J Int Adv Otol*. 2019;15(3):400-404.
- Gantz BJ, Wilkinson EP, Hansen MR. Canal wall reconstruction tympanomastoidectomy with mastoid obliteration. *Laryngoscope*. 2005;115(10):1734-1740.
- de Veij Mestdagh PD, Colnot DR, Borggreven PA, Orelia CC, Quak JJ. Mastoid obliteration with S53P4 bioactive glass in cholesteatoma surgery. *Acta Otolaryngol*. 2017;26:1-5.
- Bernardeschi D, Pyatigorskaya N, Russo FY, et al. Anatomical, functional and quality-of-life results for mastoid and epitympanic obliteration with bioactive glass S53P4: a prospective clinical study. *Clin Otolaryngol*. 2017;42(2):387-396.
- Sarin J, Grénman R, Aitasalo K, Pulkkinen J. Bioactive glass S53P4 in mastoid obliteration surgery for chronic otitis media and cerebrospinal fluid leakage. *Ann Otol Rhinol Laryngol*. 2012;121(9):563-569.
- Silvola JT. Mastoidectomy cavity obliteration with bioactive glass: a pilot study. *Otolaryngol Head Neck Surg*. 2012;147(1):119-126.
- Vos J, de Vey MP, Colnot D, Borggreven P, Orelia C, Quak J. Bioactive glass obliteration of the mastoid significantly improves surgical outcome in non-cholesteatomatous chronic otitis media patients. *Eur Arch Otorhinolaryngol*. 2017;274(12):4121-4126.
- Król B, Cywka KB, Skarżyńska MB, Skarżyński PH. Mastoid obliteration with S53P4 bioactive glass after canal wall down mastoidectomy: preliminary results. *Am J Otolaryngol*. 2021;42(2):102895.
- Bernardeschi D, Nguyen Y, Russo FY, Mosnier I, Ferrary E, Sterkers O. Cutaneous and labyrinthine tolerance of bioactive glass S53P4 in mastoid and epitympanic obliteration surgery: prospective clinical study. *Biomed Res Int*. 2015;2015:242319.
- Stoor P, Pulkkinen J, Grénman R. Bioactive glass S53P4 in the filling of cavities in the mastoid cell area in surgery for chronic otitis media. *Ann Otol Rhinol Laryngol*. 2010;119(6):377-382.
- van Gestel NAP, Geurts J, DJW H, van Rietbergen B, Hofmann S, Arts JJ. Clinical applications of S53P4 bioactive glass in bone healing and osteomyelitic treatment: a literature review. *Biomed Res Int*. 2015;2015:684826.
- Drago L, Romanò D, De Vecchi E, et al. Bioactive glass BAG-S53P4 for the adjunctive treatment of chronic osteomyelitis of the long bones: an in vitro and prospective clinical study. *BMC Infect Dis*. 2013;13:584.
- Leppäranta O, Vaahtio M, Peltola T, et al. Antibacterial effect of bioactive glasses on clinically important anaerobic bacteria in vitro. *J Mater Sci Mater Med*. 2008;19(2):547-551.
- Munukka E, Leppäranta O, Korkeamäki M, et al. Bactericidal effects of bioactive glasses on clinically important aerobic bacteria. *J Mater Sci Mater Med*. 2008;19(1):27-32.

33. Drago L, De Vecchi E, Bortolin M, Toscano M, Mattina R, Romanò CL. Antimicrobial activity and resistance selection of different bioglass S53P4 formulations against multidrug resistant strains. *Future Microbiol.* 2015;10(8):1293-1299.
34. Zhang D, Leppäranta O, Munukka E, et al. Antibacterial effects and dissolution behavior of six bioactive glasses. *J Biomed Mater Res A.* 2010;93(2):475-483.
35. Coraça-Huber DC, Fille M, Hausdorfer J, Putzer D, Nogler M. Efficacy of antibacterial bioactive glass S53P4 against *S. aureus* biofilms grown on titanium discs in vitro. *J Orthop Res.* 2014; 32(1):175-177.
36. Grønseth T, Vestby LK, Nesse LL, von Unge M, Silvola JT. Bioactive glass S53P4 eradicates *Staphylococcus aureus* in biofilm/planktonic states in vitro. *Ups J Med Sci.* 2020;18:1-9.
37. Höing B, Kirchoff L, Arnolds J, et al. Bioactive glass granules inhibit mature bacterial biofilms on the surfaces of cochlear implants. *Otol Neurotol.* 2018;39(10):e985-e991.
38. Chole RA, Faddis BT. Evidence for microbial biofilms in cholesteatomas. *Arch Otolaryngol Head Neck Surg.* 2002;128(10):1129-1133.
39. Stewart PS. Mechanisms of antibiotic resistance in bacterial biofilms. *Int J Med Microbiol.* 2002;292(2):107-113.
40. Stewart PS, Costerton JW. Antibiotic resistance of bacteria in biofilms. *Lancet.* 2001;358(9276):135-138.
41. von Elm E, Altman DG, Egger M, et al. Strengthening the Reporting of Observational Studies in Epidemiology (STROBE) statement: guidelines for reporting observational studies. *BMJ.* 2007;335(7624): 806-808.
42. Mayhew D, Mendonca V, Murthy BVS. A review of ASA physical status—historical perspectives and modern developments. *Anaesthesia.* 2019;74(3):373-379.
43. American Academy of Otolaryngology Head and Neck Surgery Foundation. Committee on hearing and equilibrium guidelines for the evaluation of results of treatment of conductive hearing loss. *Otolaryngol Head Neck Surg.* 1995;113(3):186-187.
44. Lahlou G, Sonji G, De Seta D, et al. Anatomical and functional results of ossiculoplasty using titanium prosthesis. *Acta Otorhinolaryngol Ital.* 2018;38(4):377-383.
45. van der Toom H, van der Schroeffer MP, Janssen J, Westzaan AM, Pauw RJ. A retrospective analysis and comparison of the STAM and STAMCO classification and EAONO/JOS Cholesteatoma staging system in predicting surgical treatment outcomes of middle ear Cholesteatoma. *Otol Neurotol.* 2020;41(4):e468-e474.
46. Bastier PL, Leroyer C, Lashéras A, Rogues A-M, Darrouzet V, Franco-Vidal V. Early and late surgical site infections in ear surgery. *Acta Otorhinolaryngol Ital.* 2016;36(2):127-134.
47. Horan TC, Gaynes RP, Martone WJ, Jarvis WR, Emori TG. CDC definitions of nosocomial surgical site infections, 1992: a modification of CDC definitions of surgical wound infections. *Infect Control Hosp Epidemiol.* 1992;13(10):606-608.
48. Bratzler DW, Dellinger EP, Olsen KM, et al. Clinical practice guidelines for antimicrobial prophylaxis in surgery. *Surg Infect (Larchmt).* 2013;14(1):73-156.
49. Verschuur HP, de Wever WWH, van Benthem PPG. Antibiotic prophylaxis in clean and clean-contaminated ear surgery. *Cochrane Database Syst Rev.* 2004;2004(3):CD003996.
50. Bandino F, Kenway B, Chatzimichalis M. SerenoCem™ granules: a retrospective analysis of 43 patients and identification of a subset with progressive erosion. *Clin Otolaryngol.* 2021;46(2):430-435.
51. Bagot d'Arc M, Daculsi G, Emam N. Biphasic ceramics and fibrin sealant for bone reconstruction in ear surgery. *Ann Otol Rhinol Laryngol.* 2004;113(9):711-720.
52. Harrison L, Kumar S, Bull M, Hatton PV, Bottrill I, Aldren C. Clinical case series describes a contraindication for SerenoCem Granules™ in mastoid obliteration: our experience in sixty-four patients. *Clin Otolaryngol.* 2017;42(5):1095-1100.
53. Weiss NM, Stecher S, Bächinger D, et al. Open mastoid cavity obliteration with a high-porosity hydroxyapatite ceramic leads to high rate of revision surgery and insufficient cavity obliteration. *Otol Neurotol.* 2020;41(1):55-63.
54. Sarin J, Vuorenmaa M, Vallittu PK, et al. The viability and growth of HaCaT cells after exposure to bioactive glass S53P4-containing cell culture media. *Otol Neurotol.* 2021;42(5):559-567.
55. Bernardeschi D, Law-Ye B, Bielle F, et al. Bioactive glass granules for mastoid and epitympanic surgical obliteration: CT and MRI appearance. *Eur Radiol.* 2019;29(10):5617-5626.

**How to cite this article:** Alciato L, Bernardeschi D, Pourcher V, et al. Antibiotics in mastoid and epitympanic obliteration with S53P4 bioactive glass: A retrospective study. *Laryngoscope Investigative Otolaryngology.* 2022;7(5):1584-1594. doi:10.1002/lio2.923