

Surveillance

Disease surveillance in England and Wales, April 2021

Highlights from the scanning surveillance network

Cattle

Schmallenberg virus surveillance

Like other orthobunyaviruses, Schmallenberg virus (SBV) typically shows three- to five-year cycles of infection. Therefore, SBV was anticipated to cause disease in 2020/21 following its previous identification in the UK in 2012/13 and again in 2016/17.

A two-day-old crossbred Aberdeen Angus calf, from a herd of 140 dairy cows, was euthanased because it had a spinal deformity and had struggled to stand and suckle although it was born unassisted.

Postmortem examination (PME) at the APHA Shrewsbury Veterinary Investigation Centre (VIC) showed marked scoliosis of the lumbar spine (Fig 1), but the limb joints had a full range of movement. Arthrogryposis, which is a characteristic feature of in-utero SBV infection between 80 and 150 days' gestation in cattle, was not present. The brain and the spinal cord were grossly unremarkable.

Fibrinous polyarthritis and omphalitis, reflecting postnatal bacterial infection, were identified, and the anus was imperforate.

APHA DISEASE SURVEILLANCE REPORT HEADLINES

- Schmallenberg virus surveillance in calves
- Pregnancy toxemia and toxoplasmosis in a ewe
- Water deprivation (salt toxicity) in growing pigs
- Causes of death of raptors in spring 2021

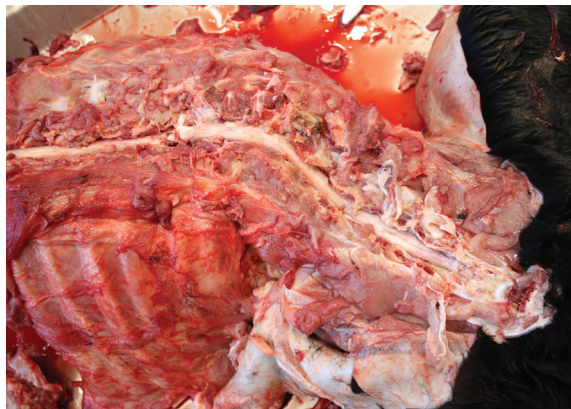

Fig 1: Scoliosis of the lumbar spine of a two-day-old calf

PCR testing on the brain confirmed SBV infection; however, histopathology of the lumbar spine did not identify necrosis and dysplasia of the ventral horn of the spinal cord, which are the characteristic lesions of SBV. Instead, diplomyelia (duplication) of the lumbar spinal cord was present. The cause of diplomyelia is

uncertain and it is considered most likely a spontaneous congenital malformation. There was also a mild non-suppurative encephalitis, which may reflect late gestational SBV infection.

A four-day-old heifer from a 550-cow dairy herd was also examined for SBV infection at Shrewsbury VIC. It was euthanased because it exhibited generalised weakness.

No gross brain or spinal cord pathology was present and there were no significant musculoskeletal lesions. A PCR test on brain tissue did not detect SBV.

Histopathology identified a multifocal non-suppurative encephalitis and myelitis, with a few suspect protozoa, in addition to asymmetric dysplasia of the sacral cord.

Subsequent PCR testing of the brain confirmed *Neospora caninum* infection. The nature of the non-suppurative encephalomyelitis was suggestive of possible protozoal and viral infection and therefore in this case it was considered that a combination of neosporosis with SBV infection may have accounted for the central nervous system lesions.

A calf with schistosomus reflexus malformation was delivered by caesarean in a small herd of 10 suckler cows. The next calving was reported by the farmer to have been unassisted, with one live normal calf and one abnormal calf delivered per vaginam. He was concerned about possible SBV infection and the abnormal calf was submitted for examination.

The gross pathology in this calf was again consistent with schistosomus reflexus malformation (Fig 2) and the SBV PCR test proved negative.

There has been debate about the cause of schistosomus reflexus and a

ABOUT THIS REPORT

This report is produced each month by the APHA Surveillance Intelligence Unit and the six Species Expert Groups (livestock and wildlife). The international horizon-scanning summaries are produced by the Defra/APHA International Disease Monitoring (IDM) team, notifiable disease reports by the APHA Veterinary Exotic and Notifiable Disease Unit (VENDU), and threat analysis by the cross-agency Veterinary Risk Group (VRG). The report is drawn from scanning surveillance information, data and reports produced by the APHA Veterinary Investigation Centres and non-APHA partner postmortem examination providers contributing to the Veterinary Investigation Diagnosis Analysis (VIDA) database and complying with standardised diagnostic and laboratory testing criteria. Other livestock and wildlife scanning surveillance reports may also be found at www.gov.uk/government/collections/animal-disease-surveillance-reports

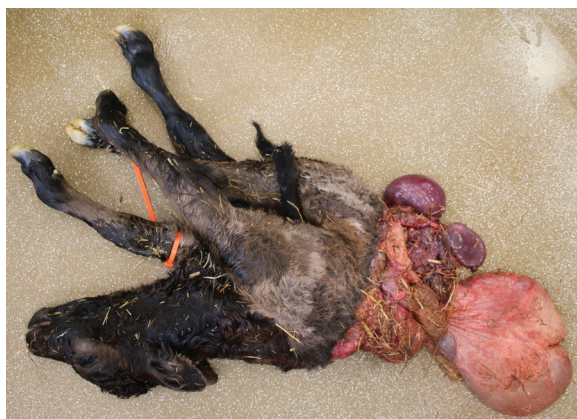

Fig 2: Calf with malformation typical of schistosomus reflexus

20-year study in Australia concluded that it was likely to be a spontaneous defect with no breed association.¹ There are also reports of twins with one affected and one normal calf, as in the case described here.

Since detection of SBV in the fetal brain depends on the stage of gestation when the fetus became infected, a negative PCR test does not rule out in-utero infection. The real-time PCR test is less sensitive for cattle than it is for sheep and only a relatively small proportion of SBV-infected calves are PCR positive. In some cases, testing of serum samples from a representative number of cows, including any that have aborted (particularly with characteristic gross pathological changes in the calf), is indicated, to detect antibodies to SBV in the dam.

The APHA is offering free-of-charge SBV surveillance testing for small ruminants and cattle, following discussion of cases with a Veterinary Investigation Officer. The findings from this enhanced surveillance will be reported later in the year.

Small ruminants

Death in a ewe with concurrent pregnancy toxoemia and toxoplasmosis

A four-year-old in-lamb ewe died after being recumbent for 24 hours and was submitted for investigation. Ewes had been on a diet of round bale silage and ewe nuts (0.6 kg/day) for six weeks. Lambing in the group of 130 ewes had started.

Postmortem examination showed fetal membranes at the vulva and a purple malodorous discharge.

The liver was pale yellow-orange in colour with multiple irregular indentations across the serosal surface that were firm in texture and extended approximately 0.5 cm into the parenchyma. The uterus was gravid and contained two large fetuses which appeared at or near term. Both fetuses were severely autolysed. The placentas and uterine lining were coated in a thick red-brown exudate and the endometrium was reddened.

Measurement of beta-hydroxybutyrate (BHB) in the aqueous humour of the ewe gave a result of 12.4 mmol/l, extremely elevated above the reference range (<2.5 mmol/l) and consistent with pregnancy toxoemia. The calcium level in the aqueous humour was within the reference range.

The yellow-orange colour of the liver was likely due to hepatic lipidosis (fatty liver). The irregular lesions on the serosal surface of the liver were considered likely to be due to historical parasitic damage (Fig 3). No adult or immature fluke were identified within the liver or gall bladder. The placentas from the lambs tested PCR positive for *Toxoplasma gondii*.

This ewe was aborting twin fetuses, which were putrefying within the uterus, and secondary endotoxaemia with concurrent pregnancy toxoemia was considered the most likely cause of death.

Toxoplasmosis was the likely initial cause of abortion in this ewe. Sheep usually acquire *Toxoplasma* infections from feed or bedding contaminated with oocysts shed in the faeces of young cats. Infection early in pregnancy may result in fetal

death and resorption, giving rise to an apparent infertility problem. Later infection leads to abortion or to the birth of weak lambs.

Control measures include:

- keeping concentrate and feed intended for pregnant ewes in closed containers;
- excluding cats from barns in which forage and bedding intended for use with pregnant sheep is stored;
- keeping older cats but discouraging breeding; oocyst shedding is highest in young cats hunting for the first time; castration of males may be considered;
- attempting to expose bought-in breeding replacement sheep to the contaminated environment two to three months before tupping (although this is not a reliable way of ensuring that all animals will become infected before pregnancy);
- vaccination before the next tupping; this is the most effective option.

Infection constitutes potential environmental and foodborne zoonotic risks, especially to pregnant women.

Blood sampling of a representative group of ewes from the same cohort for BHB levels was recommended alongside a review of management and nutrition.

Pigs

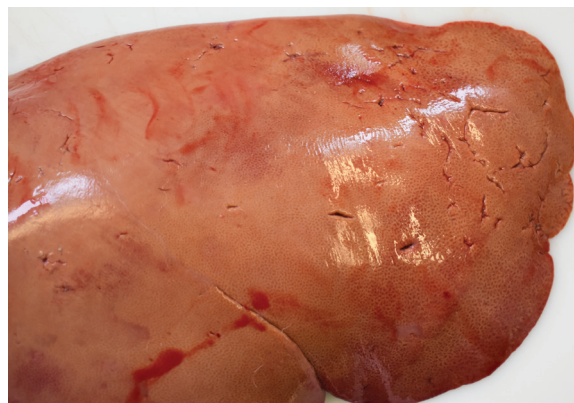Respiratory disease involving pandemic H1N1 2009 and H1N2 swine influenza strains

Swine influenza due to strain H1N2 was diagnosed in a group of outdoor maiden gilts, 10 per cent of which were coughing. One gilt died and was submitted for PME to the APHA Bury St Edmunds VIC.

PME revealed red, cranioventral consolidation of 35 per cent of the lung mass, froth in the airways and the stomach contained very little food. Histopathology showed a severe acute suppurative bronchointerstitial pneumonia which was likely to have complicated the swine influenza and, with respiratory distress, to have resulted in the gilt's death.

More complex respiratory disease

Fig 3. Pale liver most likely due to fatty changes (hepatic lipidosis) in a ewe with pregnancy toxoemia. The indentations are likely due to historical parasitic damage



was diagnosed in three 10-week-old pigs submitted from an indoor breeder-finisher unit to investigate the cause of their sudden death. The pigs were vaccinated for *Mycoplasma hyopneumoniae* and porcine circovirus type 2 (PCV-2) at weaning.

All three pigs had severe fibrinous pleuropneumonia with pericardial and peritoneal effusions. Bacteriology confirmed *Actinobacillus pleuropneumoniae* (APP), and swine influenza and porcine reproductive and respiratory syndrome (PRRS) viruses were both detected by PCR testing. The PRRS virus strain was identified as a field strain by ORF-5 gene sequencing and the swine influenza virus (SIV) was found to be the pandemic H1N1 2009 strain.

One of the APP isolates was resistant to ampicillin using in-vitro antimicrobial sensitivity testing by disc diffusion; this resistance had been detected previously on this unit.² It is therefore of concern as amoxicillin is used to treat pigs in outbreaks of APP and emphasises the importance of additional interventions to control APP, including vaccination. Treatment for APP cases on this farm had changed to tilmicosin, alongside additional interventions to control intercurrent disease, which had significantly reduced the occurrence of clinical APP in recent months.

Defra-funded surveillance provides free-of-charge PCR testing of respiratory tissues or nasal swabs for SIV. Samples should be collected at the first signs of respiratory disease or malaise as the window of opportunity for detecting SIV is short and individual pigs excrete influenza virus for only about seven days.

Recent diagnoses of swine influenza have involved the two strains detected in the cases described above; avian-like H1N1 is also occasionally detected, while H3N2 has not been identified in pigs in Great Britain since 1997.

More information on this surveillance can be found at <http://apha.defra.gov.uk/documents/surveillance/diseases/Swine%20influenza%20surveillance%20vets%20Dec2020.pdf>

Water deprivation (salt toxicity) in growing pigs with nervous disease

Two diagnoses of water deprivation (salt toxicity) were made in separate incidents in March. In one of these, three five-week-old pigs were submitted to the APHA Thirsk VIC to investigate an outbreak of neurological disease in a batch that had recently arrived on the farm.

Since arrival, 10 pigs in the batch had died and there were another 34 pigs showing clinical signs, including recumbency, ataxia, fitting, opisthotonos and head pressing, suggesting pain. The submitting veterinary surgeon was suspicious of salt poisoning.

On arrival at the farm, the pigs had received paracetamol-treated water. The mains water drinker setup was new but there had not been problems in other batches with similar management and older pigs on the same water supply were unaffected.

Postmortem findings included lack of food in the stomach, dry faeces, engorged meningeal vessels and a visible loss of definition to the cerebral sulci due to swelling of the cerebral hemispheres.

Streptococcus suis 2 was not detected in the brain by fluorescent antibody testing and bacteriology on the meninges of all three pigs did not detect any pathogens.

Plasma sodium levels in two pigs sampled antemortem were above the reference range at 153 and 157 mmol/l respectively (reference range 139–150 mmol/l).

Histopathology on the brain revealed severe, acute, multifocal, segmental, laminar cerebrocortical neuronal necrosis with lymphohistiocytic and eosinophilic perivascular cuffs in all three piglets, consistent with sodium toxicity (salt poisoning).

The second incident was similar in that a specific period of water deprivation was not identified. Clinical signs affected 32 six-week-old pigs and resulted in the death of seven by the time of submission to the APHA Shrewsbury VIC. In this case also, the cerebral hemispheres of each pig were visibly swollen, with mild to moderate cerebellar 'coning' which occurs as intracranial



A specific reason for water deprivation is not always identified

pressure forces the cerebellum into the foramen magnum.

Pigs appear to be particularly susceptible as a species to the effects of water deprivation and care must be taken to restore water intake gradually in pigs that have been water deprived to avoid triggering severe disease; sudden water intake after deprivation can lead to rapid swelling of the brain.

A specific period or reason for water deprivation is not always identified; where morbidity is low, some pigs may have failed to establish normal drinking and eating at weaning, or to access water points. It is important that any predisposing factors, including the weather, intercurrent disease (for example, diarrhoea) or changes in the salt content of the diet, are identified and resolved, and that the water supply to all watering points is checked.

Birds

Poultry

Enterococcus cecorum infection in broilers

The APHA received two unrelated submissions from commercial broiler farms with a history of lameness. The birds were between 15 and 17 days of age.

Postmortem examination of birds from both submissions showed signs of septicaemia, with the main finding being fibrinous pericarditis. In one of the submissions, hepatosplenomegaly and perihepatitis were also reported. The femoral heads of some of the birds in each submission fractured easily on manipulation, suggesting osteomyelitis. Grossly, no lesions were detected in the hock joints.

Bacteriology yielded *Enterococcus cecorum* from the pericardium, joints and bone in one of the submissions and from the liver and spleen in the other.

In one of the submissions, histopathology was carried out on the hock joints, revealing a subacute granulocytic and mononuclear synovitis; in some of the samples this was associated with a more acute osteomyelitis. These lesions explain the clinical presentation of lameness observed on the farm, although no

lesions had been detected in the hock joints at gross PME.

E cecorum infection was first described in broilers in the early 2000s.³ Spinal osteomyelitis later in the production cycle is a typical finding associated with this infection but the bacterium can also cause pericarditis, synovitis and other changes, usually associated with systemic infection. As with these recent cases, *E cecorum* infections can also be a problem earlier in the production cycle with the main presenting lesions being pericarditis and in some birds osteomyelitis of the femoral head.

Based on the APHA's experience, lesions of septic arthritis can be difficult to detect at gross examination (or even absent) because they are more subtle than those observed in cases of *Escherichia coli* or staphylococcal infections.

A recent paper showed that pathogenic *E cecorum* is relatively resistant under environmental conditions commonly observed in broiler houses.⁴ Therefore, it is very important to have good hygiene management to avoid carry over of infection between successive crops of birds.

Wildlife

Wild birds

Causes of death in raptors during spring 2021

A large number of wild birds have been submitted to the APHA during the 2020/21 outbreak of avian influenza virus. These have included birds of prey and, since the start of the epidemic in November 2020, highly pathogenic avian influenza (HPAI) virus has been detected in Great Britain in the following species: four buzzards (*Buteo buteo*), two peregrine falcons (*Falco peregrinus*), two red kites (*Milvus milvus*), a kestrel (*Falco tinnunculus*) and a sparrowhawk (*Accipiter nisus*).

It is possible that these species may have been infected from catching and eating infected wild birds. Infection in the buzzards and kites may also have arisen from scavenging the carcasses of HPAI virus-infected wild birds.

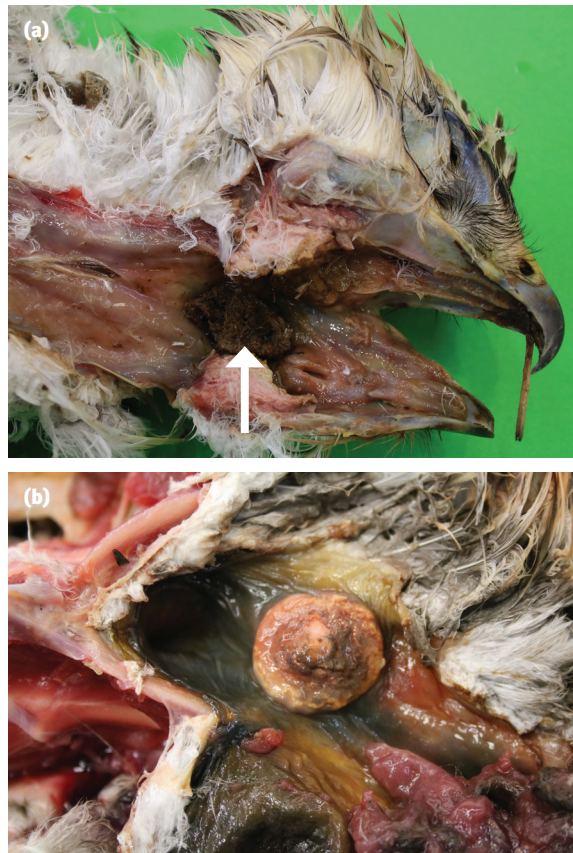


Fig 4: (a) Oropharynx of a buzzard showing pale, necrotic soft tissue (arrow) associated with trichomonosis. (b) Circular firm pale lesion due to trichomonosis in the oesophagus of an adult buzzard. The lesion had obstructed the passage of food

The buzzard is now the commonest bird of prey in the UK and during the months of February and March 2021, 37 buzzards were examined. Avian influenza virus was not detected in any of these birds and the findings included starvation (eight cases), significant parasitic infections, including trichomonosis (six cases) (Fig 4), trauma (four cases) and bacterial or fungal disease (four cases).

International disease monitoring

International Disease Monitoring (IDM) horizon-scanning activities monitor for major, notifiable or new and re-emerging animal disease outbreaks worldwide. This is done to provide an early warning and to assess the risks they may pose to the UK, in particular those diseases that impact on animal health and welfare, international trade, public health or wider society.

IDM also assesses the risk that animal diseases might come into the UK through the trade in animals or animal products (legal or illegal), through movements of wildlife, or

through the movement of fomites and vectors such as insects, which may carry infectious disease. These outbreak assessments are used to guide decisions on how to manage or reduce the risks and are published online at www.gov.uk/government/collections/animal-diseases-international-monitoring

The following summarises outbreaks during March 2021.

Highly pathogenic avian influenza

In March, the following outbreaks of HPAI H5N8 were reported in domestic poultry in Europe: Estonia (two), Italy (two), the Netherlands (one), Poland (14) and Sweden (nine).

HPAI H5N8 was also reported in wild birds in Austria (15), Croatia (three), Czech Republic (13), Estonia (19), Finland (nine), France (five), Hungary (one), Latvia (16), Lithuania (four), the Netherlands (10), Norway (nine), Poland (16) and Sweden (27).

HPAI H5N5 was reported in domestic poultry in Sweden (one). It was also reported in wild birds in Austria (one), Czech Republic (one), Hungary (one) and Sweden (11).

HPAI H5N1 was reported in wild birds in France (one) and the Netherlands (five).

HPAI H5N4 was reported in wild birds in the Netherlands (two).

HPAI H5Nx was reported in domestic poultry in Ukraine (one), and in wild birds in Austria (seven), Belgium (six), Sweden (seven) and Ukraine (three).

In Asia, outbreaks of HPAI H5N8 were reported in domestic poultry in Afghanistan (one) and Kuwait (seven).

HPAI H5N2 was reported in domestic poultry in Taiwan (one).

Other reports included HPAI H5N5 in poultry (two) and wild birds (one) in Taiwan.

In Africa, HPAI H5N8 was reported in poultry (one) and wild birds (one) in Algeria. HPAI H5N1 was reported in poultry in Niger (three).

In March, the risk to the UK of HPAI incursion in wild birds was reduced to low, and the risk of exposure of poultry to low (with stringent biosecurity) to medium

(where biosecurity is suboptimal). An avian influenza prevention zone is in place, and personnel should be taking additional biosecurity measures.

The chief veterinary officers of England, Scotland, Wales and Northern Ireland are urging bird keepers across the UK to maintain and strengthen their biosecurity measures to prevent further outbreaks of avian influenza. All poultry keepers (including those who keep gamebirds or pet poultry), should follow the biosecurity best practice advice available at www.gov.uk/guidance/avian-influenza-bird-flu#biosecurity-advice

Poultry keepers are requested to remain vigilant for any signs of disease in their flock and report any sign of avian influenza to the appropriate contact number (see 'Contacting the APHA', p 347).

Details of the latest situation can be found at www.gov.uk/government/publications/avian-influenza-bird-flu-in-europe

African swine fever

In March, in Europe, reports of outbreaks of African swine fever (ASF) in domestic pigs continued in Romania (53 outbreaks), Russia (four) and Ukraine (one).

Outbreaks in wild boar were reported in Hungary (575), Latvia (22), Romania (75) and Russia (four).

Elsewhere, outbreaks of ASF in domestic pigs were reported in China (six), Malaysia (seven), the Philippines (27) and South Africa (23).

ASF is still present in domestic pigs across eastern Europe, where Romania in particular has continued to report high numbers of outbreaks in domestic pigs in 2021, albeit in small holdings. ASF is also still circulating in wild boar across much of eastern Europe and in Germany (Brandenburg and Saxony), close to the border with Poland. Therefore, there is a medium risk of incursion of ASF virus to the UK, and this is being kept under review.

More information on the situation in Europe is available at www.gov.uk/government/publications/

[african-swine-fever-in-pigs-and-boars-in-europe](http://www.gov.uk/government/publications/african-swine-fever-in-pigs-in-china), while information on the situation in Asia can be found at www.gov.uk/government/publications/african-swine-fever-in-pigs-in-china

Despite the impact of Covid-19 on international travel, which may make introduction from personal imports or fomites less likely, there still remains a risk of entry of ASF virus in products of animal origin from affected countries, including from illegal imports. Although the UK has now left the EU, there will be no immediate change to the rules for passengers travelling into Great Britain from the EU with products of animal origin. However, Great Britain will be bringing in controls in July 2021.

All travellers are strongly advised to avoid bringing any pork products – for example, dried or cured meats, sausages, salamis or pâté – back to the UK from affected parts of Europe. Travellers from Asia and other third country areas who bring meat or dairy products can face prosecution and a large fine.

Disease can be spread by feeding catering waste, kitchen scraps or pork products to pigs. Everyone should observe the swill feeding ban. It remains illegal to feed catering waste, kitchen scraps, meat or meat products to farmed animals, including those kept as pets. This is to prevent the introduction and spread of potentially devastating notifiable animal diseases, such as ASF, classical swine fever (CSF) and foot-and-mouth disease (FMD). Outbreaks of these diseases can cause significant animal health and welfare problems and damage to the economy (www.gov.uk/government/news/apha-warns-not-to-feed-kitchen-scraps-to-farm-animals-because-of-disease-risk).

Information on how to spot ASF, including photos of clinical signs, and how to report suspect cases is available online at www.gov.uk/guidance/african-swine-fever

Classical swine fever

In March, Japan reported no new outbreaks of CSF in domestic pigs, and there were no new wild boar reports.

Elsewhere, outbreaks in domestic pigs were reported in Brazil (two).

There is a very low risk of incursion of CSF virus to the UK, but this is being kept under review.

Bluetongue

In March, in Europe, there were cases of bluetongue virus (BTV) serotype 8 in Belgium (one) and BTV-16 (13) and BTV-4 (11) in Greece.

Currently the risk of BTV incursion to the UK remains low. Animals travelling to or from BTV-affected areas of Europe, and back to the UK, must be vaccinated against both BTV-8 and BTV-4.

More information on the BTV situation in Europe can be found at www.gov.uk/government/publications/bluetongue-virus-in-europe. Further advice on how to spot and report BTV can be found at www.gov.uk/guidance/bluetongue

Foot-and-mouth disease

In March, one outbreak of FMD serotype O was reported in Mauritius.

There remains a low risk of FMD incursion to the UK from any affected region.

Newcastle disease

There were no new reports of Newcastle disease to the World Organisation for Animal Health (OIE) in March.

The risk level for exposure to poultry in the UK is unchanged: there remains a low risk of incursion into the UK from any affected region.

References

- 1 Knight RP. The occurrence of schistosomus reflexus in bovine dystokia. *Aust Vet J* 1996;73:105–7
- 2 APHA. Pneumonia due to ampicillin-resistant *Actinobacillus pleuropneumoniae*. In GB pig quarterly report: Disease surveillance and emerging threats. Volume 24: Q1 January to March 2020, pp 10–11. 2020; https://assets.publishing.service.gov.uk/government/uploads/system/uploads/attachment_data/file/889984/pub-survrep-p0120.pdf (accessed 22 April 2021)
- 3 Wood AM, MacKenzie G, McGiliveray NC, et al. Isolation of *Enterococcus cecorum* from bone lesions in broiler chickens. *Vet Rec* 2002;150:27
- 4 Grund A, Rautenschlein S, Jung A. Tenacity of *Enterococcus cecorum* at different environmental conditions. *J Appl Microbiol* 2021;130:1494–507