

Dissecting aneurysm of common iliac artery in a long-distance runner

Susanne Regus, MD,^a Stephan Söder, MD,^b and Werner Lang, MD, FEBVS,^a Erlangen, Germany

We present an unusual case of a long-distance runner suffering from acute dissection of a common iliac artery (CIA) aneurysm with endofibrotic lesions. He suffered from acute pelvic and abdominal pain after exercise. Computed tomography angiography confirmed the dissecting aneurysm of the left CIA without signs of rupture. After cutdown, resection of the CIA and iliac bifurcation as well as bypass grafting was performed. Histologic examination confirmed endofibrotic lesions without calcifications. Complicated iliac artery aneurysm could be the result of endofibrotic lesions. Clinicians should keep this in mind, even if physical examination findings and the ankle-brachial index are normal at rest and after exercise. (*J Vasc Surg Cases* 2016;2:4-6.)

High-performance athletes without cardiovascular risk factors can suffer from arterial complications, such as stenosis or thrombosis, due to endofibrosis. The external iliac artery (EIA) is mostly affected, especially in cyclists.¹

We want to discuss the unusual case of a long-distance runner who suffered from a dissecting aneurysm of the left common iliac artery (CIA) with histologic signs of endofibrosis.

The patient gave informed consent to publish this article.

CASE REPORT

A 52-year-old male long-distance runner with no cardiovascular risk factors developed acute left pelvic pain after endurance exercise. He had been running competitively about 30 to 40 miles a week for the past 20 years and denied having any thigh or lower limb pain at rest or during exercise. Because of increased pelvic and lumbar pain, he consulted his family practitioner, who suspected a disk prolapse after neurosurgical intervention 5 years ago. A lumbar and spinal magnetic resonance tomography scan was performed and showed normal spine and spinal cord without any abnormalities. However, a dissecting aneurysm of 3.2 cm in diameter of the left CIA was visualized, whereupon the patient was referred to our emergency department.

The patient was hemodynamically stable. On clinical examination, he had a pressure pain in the left lower abdominal wall. Femoral and pedal pulses were palpable without coldness or

discoloration. The ankle-brachial index (ABI) was 1.0 at rest; evaluation after exercise was not possible because of persistent pelvic pain.

Computed tomography angiography confirmed the dissecting aneurysm of the left CIA without signs of rupture. Furthermore, bending of the CIA and EIA on both sides was visible (Fig 1).

Surgery was performed without any delay because of acute abdominal pain and correlating high risk for rupture. After median laparotomy, resection of the CIA aneurysm and iliac bifurcation was performed (Fig 2). Finally, a Dacron graft was inserted from the aortic bifurcation with separate distal anastomosis to the external and internal iliac artery.

Histologic examination confirmed intimal hyperplasia as previously described in endofibrotic lesions. There was no suspicion of atherosclerosis or congenital weakness of the connective tissue, such as in Marfan and Ehlers-Danlos syndromes (Fig 3). Furthermore, the patient denied any recent illness, especially feverish infections. During surgery, there were no indications for false aneurysm of the iliac arteries from prior neurosurgical treatment.

After uneventful recovery, the patient was discharged 7 days after surgery. During a follow-up time of 23 months, the patient has remained symptom free and was able to run about 30 miles a week.

DISCUSSION

Endofibrosis of the EIA was first described in 1985 by Mosimann et al in two young performance cyclists.¹ In the following year, a series of seven bicycle racers suffering from symptomatic stenoses of the EIA was published.² The authors described endofibrosis as an intimal thickening primarily affecting the left EIA with maximum stenosis of 30% to 40% of the diameter. Interestingly, the intimal lesions are not circumferential but eccentric, located at the greater curvature of the arterial bend. This can be explained by repetitive external shear stress to this arterial sector.³ The case presented confirmed these findings because intimal thickness was also identified at the greater bending radius of the CIA. However, in >90% of previously published data, endofibrosis affects the EIA; only in a small number of cases has it been found to involve the CIA.⁴

From the Department of Vascular Surgery^a and Department of Pathology,^b University Hospital.

Author conflict of interest: none.

Correspondence: Susanne Regus, MD, Department of Vascular Surgery, University Hospital, Krankenhausstrasse 12, 91054 Erlangen, Germany (e-mail: Susanne.regus@uk-erlangen.de).

The editors and reviewers of this article have no relevant financial relationships to disclose per the Journal policy that requires reviewers to decline review of any manuscript for which they may have a conflict of interest.

2352-667X

Copyright © 2016 The Authors. Published by Elsevier Inc. on behalf of the Society for Vascular Surgery. This is an open access article under the CC BY-NC-ND license (<http://creativecommons.org/licenses/by-nc-nd/4.0/>).

<http://dx.doi.org/10.1016/j.jvsc.2015.11.001>

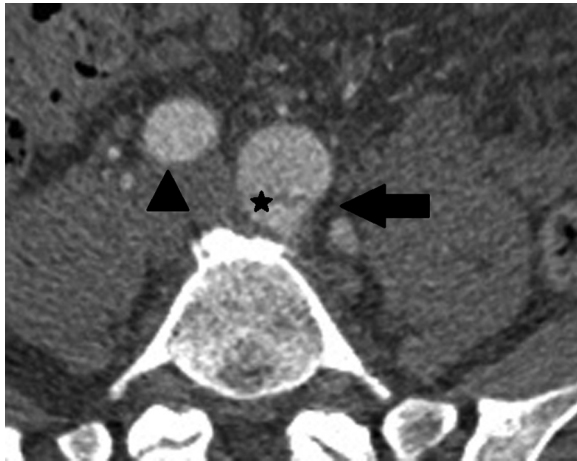


Fig 1. Computed tomography angiography demonstrates left common iliac artery (CIA) aneurysm (*arrow*) with dissection membrane (*asterisk*) and the right CIA (*arrowhead*).

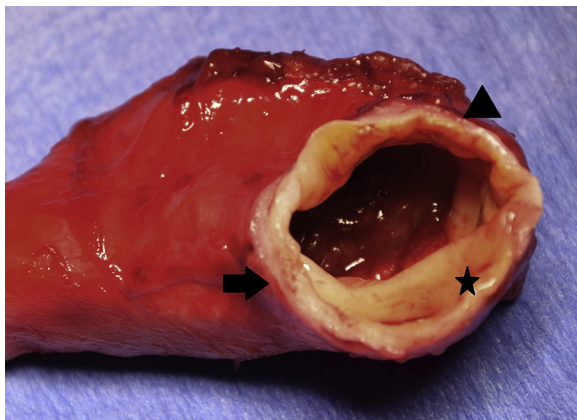


Fig 2. Sliced and resected segment of the common iliac artery (CIA) after cutdown: intimal hyperplasia (*arrow*), unaffected vessel wall (*arrowhead*), and dissection membrane (*asterisk*).

We do not exactly know why the patient in this case developed complicated aneurysm in the CIA. One explanation could be the expressive psoas muscle hypertrophy and therefore the repetitive compression of the CIA. Furthermore, extreme bending of the CIA is likely to have been caused by this hypertrophied muscle and to be the reason for chronic arterial wall lesions.

Endofibrosis development has been linked to mechanical and systemic factors. Mechanical factors are the aerodynamic posture, especially of cycling athletes, and therefore maximal kinking of the iliac arteries.⁵ Furthermore, muscular branches to the psoas muscle tether the iliac bifurcation and may increase stretching and compression of the iliac arteries during hip flexion.⁶ Systemic factors include increased blood pressure, especially in the lower extremity arteries during long-distance running. High cardiac outputs and maximum systolic arterial

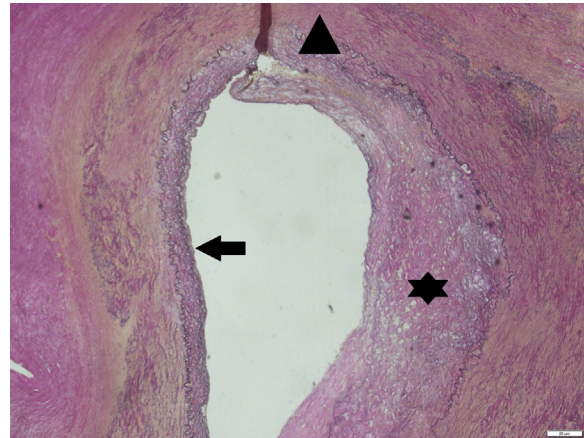


Fig 3. Histologic examination (van Gieson stain, magnification $\times 5$) of the iliac artery showing eccentric intimal thickness due to endofibrosis on half of the circumference (*asterisk*) with dissection membrane (*arrowhead*) and normal vessel wall without thickening of the intima on the other half of the circumference (*arrow*).

pressures of 180 to 240 mm Hg can be attained by top-level athletes.⁷ Moreover, endothelial dysfunction and reduced elasticity have been described in long-distance runners.⁸

Most complications of endofibrotic lesions are arterial stenoses. Especially because they are much smaller than those of atherosclerosis, they may be dismissed as insignificant.⁹ Complications such as dissection, thrombosis, and rupture are extremely rare but reduce delay of correct diagnosis.³

Clinical examination and absence of cardiovascular risk factors often do not suggest a vascular cause of the patient's symptoms. The ABI is usually normal at rest but reduced after near-maximal exercise. A patient with an ABI of <0.7 after a maximum exercise test should be referred for further arterial imaging by duplex sonography or magnetic resonance angiography (MRA).¹⁰

Alternative noninvasive imaging techniques like duplex sonography would have been more convincing, but kinkings in the CIA are difficult to visualize sonographically.¹¹ MRA appears to be the most effective imaging technique to confirm pathologic alterations of the CIA.⁹ Because of increasing pain, we decided for use of computed tomography angiography and against more time-consuming MRA, which would have been the preferred imaging technique in an elective case.

Various surgical and endovascular treatment techniques have been described in the literature. In contrast to atherosclerosis, there is a poor response to balloon angioplasty in endofibrotic lesions, and stent implantation is necessary in most cases. Afterward, remaining compression due to muscle hypertrophy often results in recurrent stenosis with disappointing long-term results.¹² For these reasons, we were afraid of such complications as stent graft

compression and endoleaks and decided against endovascular and for surgical management.

The use of prosthetic grafts should be avoided whenever possible because of the potential risks of infection and false aneurysm formation. In the case presented, after resection of the affected arteries, reconstruction had to be performed with a Dacron prosthesis. We have decided against using the deep femoral veins as bypass material because of an increased surgical morbidity and potential sequelae from a reduced venous outflow.

CONCLUSIONS

Even if endofibrosis primarily results in EIA stenosis, this case illustrates an uncommon complication of a dissecting aneurysm of the CIA. Lower limb pain after exercise is the most reported symptom of endofibrosis, but clinicians should pay attention to unusual signs such as abdominal or pelvic pain.

REFERENCES

- Mosimann R, Walder J, Vanmelle G. Stenotic intimal thickening of the external iliac artery: illness of the competition cyclists? Report of 2 cases. *Vasc Surg* 1985;19:258-63.
- Chevalier JM, Enon B, Walder J, Barral X, Pillet J, Megret A, et al. Endofibrosis of the external iliac artery in bicycle racers: an unrecognized pathological state. *Ann Vasc Surg* 1986;1:297-303.
- Peach G, Schep G, Palfreeman R, Beard JD, Thompson MM, Hinchliffe RJ. Endofibrosis and kinking of the iliac arteries in athletes: a systematic review. *Eur J Vasc Endovasc Surg* 2012;43:208-17.
- Rouviere O, Feugier P, Gutierrez JP, Chevalier JM. Arterial endofibrosis in endurance athletes: angiographic features and classification. *Radiology* 2014;273:294-303.
- Bender MH, Schep G, de Vries WR, Hoogeveen AR, Wijn PF. Sports-related flow limitations in the iliac arteries in endurance athletes: aetiology, diagnosis, treatment and future developments. *Sports Med* 2004;34:427-42.
- Schep G, Bender MH, Kaandorp D, Hammacher E, de Vries WR. Flow limitations in the iliac arteries in endurance athletes. Current knowledge and directions for the future. *Int J Sports Med* 1999;20:421-8.
- Lim CS, Gohel MS, Shepherd AC, Davies AH. Iliac artery compression in cyclists: mechanisms, diagnosis and treatment. *Eur J Vasc Endovasc Surg* 2009;38:180-6.
- Wright IA, Pugh ND, Goodfellow J, Wood AM, Lane IF, Fraser AG. Dynamic obstruction of the external iliac artery in endurance athletes and its relationship to endothelial function: the case of a long distance runner. *Br J Sports Med* 1997;31:156-8.
- Schep G, Kaandorp DW, Bender MH, Weerdenburg H, van Engeland S, Wijn PF. Magnetic resonance angiography used to detect kinking in the iliac arteries in endurance athletes with claudication. *Physiol Meas* 2001;22:475-87.
- Taylor AJ, George KP. Ankle to brachial pressure index in normal subjects and trained cyclists with exercise-induced leg pain. *Med Sci Sports Exerc* 2001;33:1862-7.
- Schep G, Bender MH, Schmikli SL, Wijn PF. Color Doppler used to detect kinking and intravascular lesions in the iliac arteries in endurance athletes with claudication. *Eur J Ultrasound* 2001;14:129-40.
- van Rensburg DC, van Rensburg AJ, van Duuren EM, Grant CC. Iliac artery endofibrosis in a middle-aged female long-distance runner. *Am J Phys Med Rehabil* 2014;93:1100-3.

Submitted Oct 13, 2015; accepted Nov 20, 2015.