

Tension pneumocephalus causing brain herniation after endoscopic sinus surgery

Erhan Çelikoglu, Jülide Hazneci, Ali Fatih Ramazanoglu

Department of Neurosurgery, Neurosurgery Clinic, Ministry of Health, Fatih Sultan Mehmet Education and Research Hospital, Istanbul, Turkey

ABSTRACT

Endoscopic sinus surgery (ESS) may rarely be complicated by intracranial complications; the most common of them is a cerebrospinal fluid fistula. Pneumocephalus as a complication of ESS is quite rare. Here, we presented a unique case of tension pneumocephalus causing brain herniation as a complication of ESS, to whom emergent craniotomy was performed.

Key words: Brain herniation, craniotomy, endoscopic sinus surgery, tension pneumocephalus

Introduction

Endoscopic sinus surgery (ESS) may rarely be complicated by several intracranial complications, which occurs as <1% of the cases.^[1] The most common intracranial complication of ESS is cerebrospinal fluid (CSF) fistula. Pneumocephalus as a complication of ESS is quite rare. Furthermore, tension pneumocephalus causing brain herniation after ESS is almost unique.

Here, we presented a case of tension pneumocephalus causing brain herniation as a complication of ESS, on whom emergent craniotomy was performed.

Case Report

A 72-year-old female underwent ESS for chronic rhinosinusitis and nasal polyposis at an outside institution. The 1st day after the nasal packings were removed, she gradually developed a headache, vomiting, and altered mental status. Then, the patient was referred to our institution. On arrival, her Glasgow Coma Scale score was 8. Her pupils were asymmetric with a right pupil is 3 mm larger than the left pupil and sluggishly reactive to light. She was opening her eyes with noxious

stimulus and was not following commands. She was able to localize noxious stimulus with no verbal response.

Emergent computed tomography (CT) of the head revealed a large bifrontal air collection [Figure 1a and b]. The initial diagnosis was tension pneumocephalus with brain herniation. The patient underwent an emergency bifrontal craniotomy for the evacuation of the air and the dural defect repair. The dura was opened in a standard fashion, the exploration of the anterior skull base revealed a bony defect through ethmoidal sinus to the anterior skull base with a dural tear. The dural defect was repaired with galea and fibrin glue. The patient was kept in bed rest and intravenous antibiotics for 3 days. She was extubated on her first postoperative day, and neurological examination was completely normal. Postoperative CT obtained at the 9th day revealed complete resolution of the pneumocephalus [Figure 1c and d]. She was discharged on the 9th postoperative day as well-being.

Discussion

Pneumocephalus is defined as the presence of air within the cranium. The most common causes of pneumocephalus were head trauma and iatrogenic violation of the dura. Moreover, emphysematous bacterial infections, tumor invasion, encephalocele, and valsalva maneuver may cause pneumocephalus.^[2] Pneumocephalus as a complication of ESS is quite rare.^[3] Furthermore, tension pneumocephalus

This is an open access article distributed under the terms of the Creative Commons Attribution-NonCommercial-ShareAlike 3.0 License, which allows others to remix, tweak, and build upon the work non-commercially, as long as the author is credited and the new creations are licensed under the identical terms.

For reprints contact: reprints@medknow.com

Access this article online	
Quick Response Code:	Website: www.asianjns.org
	DOI: 10.4103/1793-5482.179646

Address for correspondence:

Dr. Jülide Hazneci, Department of Neurosurgery, Fatih Sultan Mehmet, Education and Research Hospital, C Block 3. Floor, 34844, Ataşehir, Istanbul, Turkey.
E-mail: jhazneci3@hotmail.com

How to cite this article: Çelikoglu E, Hazneci J, Ramazanoglu AF. Tension pneumocephalus causing brain herniation after endoscopic sinus surgery. Asian J Neurosurg 2016;11:309-10.

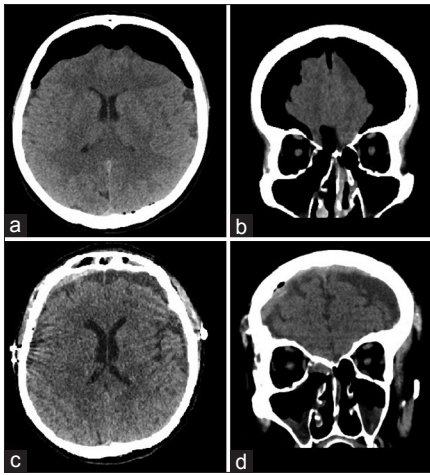


Figure 1: Preoperative computed tomography revealing bifrontal pneumocephalus (a and b). Postoperative computed tomography obtained on the 9th day revealing a complete resolution of the pneumocephalus (c and d)

is a condition, in which pneumocephalus progresses gradually, behaving like a mass effect, causing intracranial hypertension, and leading to neurological deficits.^[4] Tension pneumocephalus after ESS as a cause of brain herniation is a unique condition. To the best of our knowledge, there were only two previously reported cases treated by craniotomy in the English literature.^[2,5]

There are two theories for the development of pneumocephalus: The “inverted bottle” and the “ball-valve.” In the “inverted bottle” theory, drainage of CSF leads to negative intracranial pressure causing a pressure gradient concluding the influx of air. The “ball-valve” mechanism theorizes that the positive pressure forces air through the cranial defect.^[3]

Because of the existing literature that is consist of the case reports and small case series rather than larger clinical studies; a standard treatment regimen for tension pneumocephalus after ESS has not been presented yet. Conservative treatment

including bed rest, head of bed elevation, avoidance of positive pressure events, pain control, and normobaric oxygen therapy can be tried on small defects with small amounts of air. Although, complete resorption of 50 ml of air can take 6 weeks, and conservative treatment may not be definitive in many cases with tension pneumocephalus and large defects.^[6] Tension pneumocephalus causing brain herniation is a life-threatening condition, and the emergency craniotomy with dural repair is the treatment of choice.

Conclusion

After ESS, tension pneumocephalus causing brain herniation is an extremely rare condition. To the best of our knowledge, the presented case is the third case in the English literature. Despite ESS is considered as a minimally invasive procedure, tension pneumocephalus causing brain herniation must be kept in mind by physicians as a life-threatening complication.

Financial support and sponsorship

Nil.

Conflicts of interest

There are no conflicts of interest.

References

1. Carrau RL, Snyderman CH, Kassam AB. The management of cerebrospinal fluid leaks in patients at risk for high-pressure hydrocephalus. *Laryngoscope* 2005;115:205-12.
2. Simmons J, Luks AM. Tension pneumocephalus: An uncommon cause of altered mental status. *J Emerg Med* 2013;44:340-3.
3. DelGaudio JM, Ingley AP. Treatment of pneumocephalus after endoscopic sinus and microscopic skull base surgery. *Am J Otolaryngol* 2010;31:226-30.
4. Dandy WE. Pneumocephalus (Intracranial pneumatocele or arocele). *Arch Surg* 1926;12:949-82.
5. Aksoy F, Dogan R, Ozturan O, Tugrul S, Yildirim YS. Tension pneumocephalus: An extremely small defect leading to an extremely serious problem. *Am J Otolaryngol* 2013;34:749-52.
6. Dexter F, Reasoner DK. Theoretical assessment of normobaric oxygen therapy to treat pneumocephalus. *Anesthesiology* 1996;84:442-7.