



Case report

A fractured inferior vena cava filter strut migrating to the left pulmonary artery



Tamer Hudali*, Ali Zayed, Bernard Karnath

Department of Internal Medicine, University of Texas Medical Branch at Galveston, 301 University Blvd, Galveston, TX 77555, USA

ARTICLE INFO

Article history:

Received 29 January 2015

Received in revised form

5 June 2015

Accepted 7 June 2015

Keywords:

IVC filters

Filter complication

Filter fracture

ABSTRACT

Inferior vena cava filters are increasingly used in patients with recurrent venous thromboembolism who are contraindicated to anticoagulation. Migration of a broken strut to the pulmonary artery is a very rare complication of these filters. We report the case of an 83-year-old female who experienced this complication with the migratory strut remaining in the same position for years. This case provides evidence that such filters probably have higher rates of complications than what has been thought that remain asymptomatic. The indications and the management of complications of such devices need to be studied further.

© 2015 The Authors. Published by Elsevier Ltd. This is an open access article under the CC BY-NC-ND license (<http://creativecommons.org/licenses/by-nc-nd/4.0/>).

1. Introduction

Inferior vena cava (IVC) filters have been utilized in the prevention of pulmonary embolism (PE) in patients with proximal deep vein thrombosis (DVT) where anticoagulation is contraindicated [1]. The use of these filters may be associated with rare but potentially life-threatening complications. We report a case of fractured IVC filter strut migration to the pulmonary vasculature and we highlight possible management of such cases.

2. Case report

In 06/2008, an 83-year-old, Caucasian female with a past medical history of Alzheimer's disease, coronary artery disease, hypertension, and hyperlipidemia presented with acute shortness of breath to the University of Texas Medical Branch emergency department. Computed tomography (CT) of the chest with intravenous (IV) contrast showed a saddle embolus with multiple bilateral, central, and peripheral pulmonary emboli. She was diagnosed with acute, unprovoked PE. Hypotension requiring monitoring by the intensive care unit complicated her hospital course. Transthoracic echocardiogram showed moderately reduced

left ventricular systolic function with an ejection fraction of 30–35%, moderately dilated right ventricle (RV), and mildly reduced RV function. Right ventricular systolic pressure was 40–45 mm Hg. Bilateral doppler ultrasound of lower limbs revealed bilateral DVTs. She received anticoagulation therapy and, due to the high risk of further PEs in the future, an interventional radiologist deployed an infrarenal vena cava filter (G-2 recovery retrievable filter). Six months later, a repeated CT scan of the chest with IV contrast showed an almost complete resolution of the PE. However, the patient remained on chronic oral anticoagulation and there was no discussion of retrieving the IVC filter.

In 9/2010, the patient presented to the internal medicine clinic with left sided pleuritic chest pain. Unchanged electrocardiogram and negative cardiac biomarkers ruled out acute coronary syndrome. Chest CT scan with IV contrast showed a high-density linear structure extending into the superior segmental and superior lingular segmental pulmonary artery branches and the left lower lobe (Fig. 1). This most likely represented a broken IVC filter strut. A chest x-ray shows the same finding (Fig. 2). Abdominal CT scan with IV contrast revealed the infrarenal IVC filter with missing struts. Fig. 3 shows a comparison between two abdominal CTs. The CT scan taken in 12/2008 shows the IVC filter with 12 struts while the CT taken in 9/2010 shows only 11 struts. The patient was diagnosed with stable chronic angina pectoris and her chest pain improved with nitroglycerine. As the displacement was asymptomatic and the removal procedure holds risk of complications, a multidisciplinary team chose a conservative approach and left the IVC filter strut and the original IVC filter in place. The patient was managed

Abbreviations: CT, computed tomography; DVT, deep vein thrombosis; IV, intravenous; IVC, inferior vena cava; PE, pulmonary embolism; RV, right ventricle.

* Corresponding author. Department of Internal Medicine, Southern Illinois University, 751 N Rutledge St., Springfield, IL 62704, USA.

E-mail address: thudali39@siu.edu (T. Hudali).

<http://dx.doi.org/10.1016/j.rmcr.2015.06.002>

2213-0071/© 2015 The Authors. Published by Elsevier Ltd. This is an open access article under the CC BY-NC-ND license (<http://creativecommons.org/licenses/by-nc-nd/4.0/>).

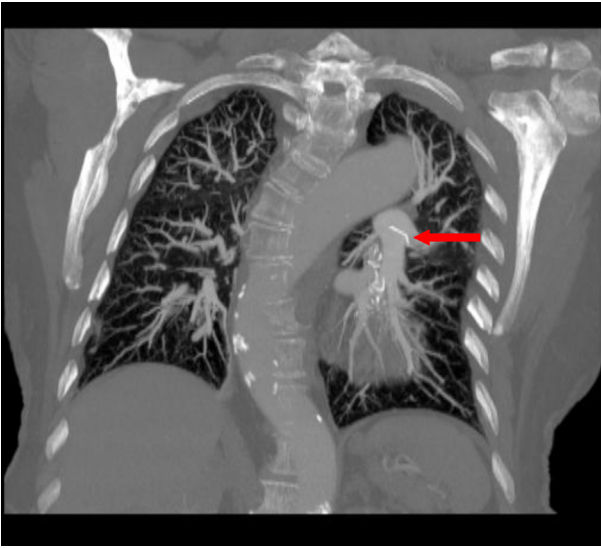

Fig. 1. Red arrow pointing to the IVC filter strut at the pulmonary vasculature. (For interpretation of the references to colour in this figure legend, the reader is referred to the web version of this article.)

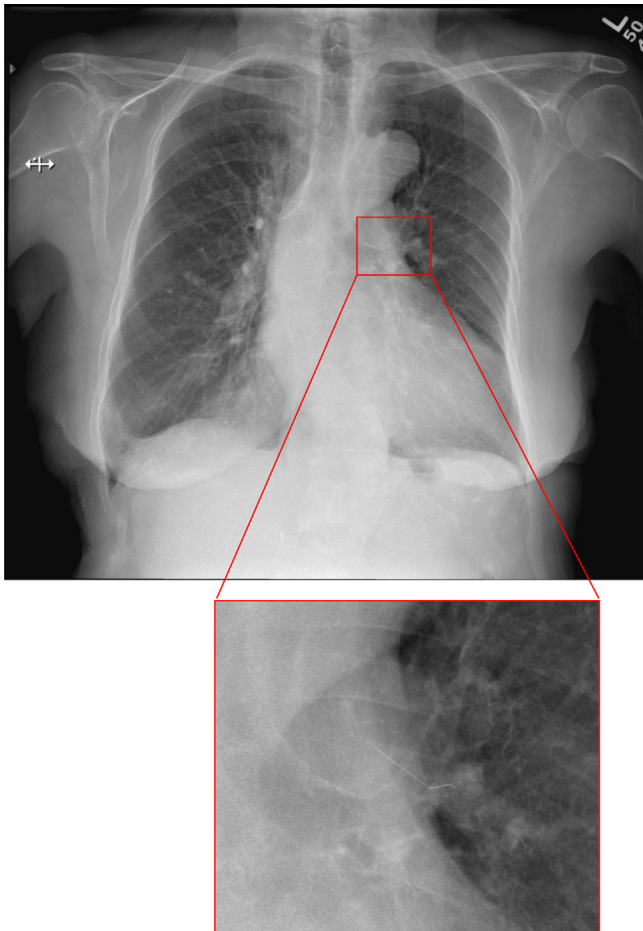


Fig. 2. Chest x-ray showing a foreign linear structure at the left upper part of the lung (structure better seen in the magnified image on the right).

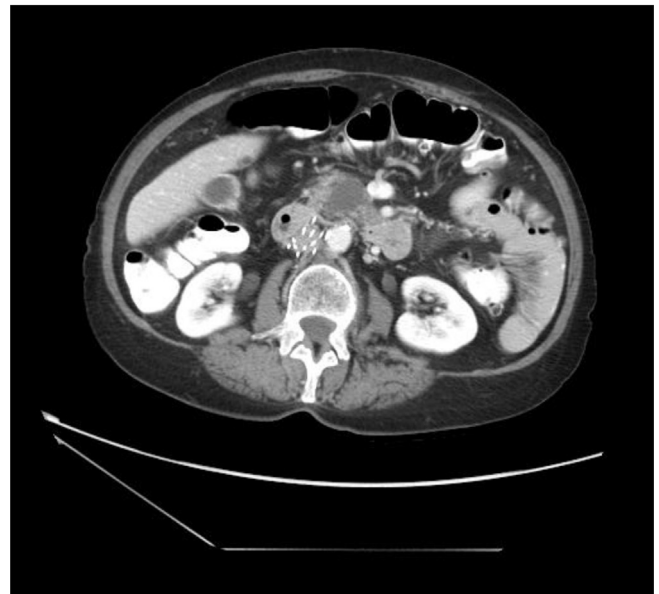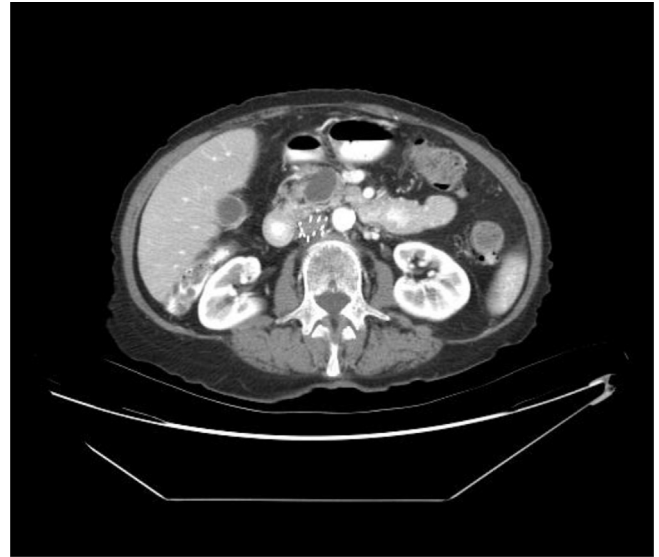


Fig. 3. The abdominal CT shown above was in 12/2008 showing 12 struts as compared to the bottom CT abdomen taken on 9/2010 showing only 11 struts.

with chronic oral anticoagulation. Over the next 4 years the patient's symptoms were monitored through regular clinic follow ups and serial chest CT scans. As of 2/2014, the patient remained asymptomatic and there was no evidence of any complications, including changes in the position of the fractured and migratory strut.

3. Discussion

A study conducted from 1980 to 1990 in Olmsted County, Minnesota, United States estimated the incidence of venous thromboembolism in the USA as 70 per 100,000 person-years [2]. Anticoagulation is still the mainstay of treatment for venous thromboembolism [1]. According to the recent American College of Chest Physicians (ACCP) 2012 guidelines, IVC filters are only indicated with the diagnosis of acute proximal DVT or acute PE with the contraindication to anticoagulation [1]. No randomized studies

have evaluated IVC filters as a therapeutic measure without anticoagulation for DVTs or PEs [1]. A single large randomized controlled trial evaluated permanent IVC filter insertion as an adjunct to anticoagulant therapy in patients with acute DVT who were considered to be at high risk for PE [3]. The study found that although IVC filters reduced the risk of PE, they increased risk of recurrent DVT and didn't change overall mortality.

Complications of IVC filters are well documented and can occur either early during placement or later on after positioning. They range from simple local complications to death. The overall morbidity and mortality from filter placement varies between review studies but is generally low [4,5]. In one series with a total of 2557 patients, a retrospective review found an overall mortality rate of 0.12% [4]. Another series studying 1765 filter insertions showed a major complications rate of 0.3% [5]. The most common complication of IVC filter insertion is thrombosis [6], which could relate to the interaction between the underlying process of thrombosis and the site of filter insertion. A systematic review described the overall incidence of IVC filter thrombosis or stenosis as 2.8% with a range of 0.6–8.0% [7]. This wide range may vary according to the type of filters used, which would indicate an involvement of the filter's technical structure in the pathogenesis of such a complication. Other less common complications include filter migration [6,8], filter occlusion [6], filter erosion through the filter wall [9], filter misplacement [6,10] and, as seen in our case, filter fracture with fragment embolization.

Our patient remained asymptomatic despite having a filter strut fracture and embolization all the way to the pulmonary vasculature. A few case reports describe similar complications involving different locations of strut embolization including the heart [11–17], aorta [18], liver [13], renal vein [19] and lungs [13,20,21]. A retrospective, single-center study evaluated 80 patients who underwent Bard recovery and Bard G2 IVC filters. The study found an overall strut fracture rate of 16% (13 patients). In 9 patients, one or more fractured struts embolized to at least one of several locations (heart, lungs, and liver), and 5 of these patients were symptomatic [13]. The authors concluded that Bard Recovery and Bard G2 filters have high prevalence of a potentially life threatening complication. Vijay K et al. [21] conducted a retrospective review of 548 removed filters and estimated an overall fracture rate of 12% with a 13% rate of embolization. They noted that only one patient had symptoms related to the fractured strut. Most of the embolized struts were in the lungs. The patients were asymptomatic, and there were no attempts for retrieval due to the inaccessibility of the struts. Conversely, Tam M et al. [20] retrospectively studied 266 Recovery filters. They looked at the images obtained after placement of the filters and estimated a filter fracture risk rate of 40% at 5.5 years [20]. However, they didn't report any symptoms related to the fractured struts, and they suggested that struts tend to be asymptomatic when they migrate beyond the heart [20]. Another study found that a total of 3.4% of removed Bard G2 filters have a fractured strut prior to removal [22]. This same study showed a high success rate of filter removal. Removal of filters that had been in place for more than 180 days had comparable outcomes to those removed sooner. This conclusion supports the retrieval of IVC filters when they are no longer indicated in order to minimize the possibility of side effects.

Fracture of IVC filters may involve multiple mechanisms. Repetitive flexion of the strut could cause metal fatigue that leads to fracture. Fracture can also be related to tilting, strenuous physical activity, or strain from the Valsalva maneuver or respiratory motion [12]. However, our patient's physical activity is minimal due to her co-morbidities, suggesting an alternative mechanism of fracture. Other possible factors include the type of the IVC filter. Angel F et al. [7] evaluated filter complications reported in the MAUDE database

and found that most reported filter fractures involved G2 recovery filters. Newer reports suggests less incidences of fractures in newer filters. A retrospective, 5-year follow up of 741 patients with Celect filters showed no reports of fractures [23]. They found a risk of fracture of less than 4.3% at 12 months after insertion.

The optimal treatment of fractured and migrated struts of an IVC filter is not clear due to the very low incidence of such complications. It is worth mentioning, however, that these complications are more frequent with longer duration of implantation [13]. A suggested conservative approach with close observation (as with our patient) might be effective, especially with asymptomatic patients. Tam M et al. briefly addressed such an approach [20]. They suggested against general screening for fractured and embolized parts in all patients with IVC filters. Rather, they suggested an individualized approach to symptomatic patients. Other percutaneous and surgical approaches have been reported in case reports involving symptomatic and life threatening situations [12,13,16,18,19,21,24]. The use of such interventions in asymptomatic patients hasn't been described well and further studies are warranted.

The fact that our patient remained asymptomatic for more than 4 years should not overshadow the importance of educating physicians and patients about IVC filter complications, especially potentially life threatening ones. Another important factor for the prevention of such complications is careful compliance with current indications of IVC filter placement. A recent study showed that in a single center the rate of IVC filter insertion without a definitive indication according to ACCP guidelines is as high as 40% [25]. Our patient didn't have a definitive indication of an IVC filter deployment. She could have been treated with anticoagulation and avoided exposure to such complications.

We decided to continue conservative management because our patient remained asymptomatic and most of the cases reported in literature had a benign asymptomatic course if the fractured strut reached the pulmonary vasculature. We opted against removal of the IVC filter due to increased risk of complications such as further strut fractures, bleeding, and thrombosis. Our patient will continue with serial imaging studies and we will watch for any emerging symptoms.

4. Conclusion

We present our medical experience with a case of IVC filter complication. We suggest close monitoring and periodic surveillance of asymptomatic patients until long term data further elucidates the indications, effectiveness, and safety of IVC filters. We also suggest strict compliance with the current guidelines of IVC filter insertion, adequate follow up, and retrieval of the filters when they are no longer indicated.

Acknowledgments

The authors would like to thank Dr.Rami Eldaya for helping us retrieve the images of the patient and Lydia Howes, MS a member of the Scientific Editing Service of Southern Illinois University Medical Library for helping us in language proofing and editing of the manuscript.

References

- [1] C. Kearon, E.A. Akl, A.J. Comerota, P. Prandoni, H. Bounameaux, S.Z. Goldhaber, et al., Antithrombotic therapy for VTE disease: Antithrombotic therapy and prevention of thrombosis, 9th ed: American College of Chest Physicians evidence-based clinical practice guidelines, *Chest* 141 (2012) e419S–e494S, <http://dx.doi.org/10.1378/chest.11-2301>.
- [2] J.A. Heit, L.J. Melton 3rd, C.M. Lohse, T.M. Petterson, M.D. Silverstein, D.N. Mohr, et al., Incidence of venous thromboembolism in hospitalized

- patients vs community residents, *Mayo Clin. Proc.* 76 (2001) 1102–1110, <http://dx.doi.org/10.4065/76.11.1102>.
- [3] H. Decousus, A. Leizorovicz, F. Parent, Y. Page, B. Tardy, P. Girard, et al., A clinical trial of vena caval filters in the prevention of pulmonary embolism in patients with proximal deep-vein thrombosis. Prévention du Risque d'Embolie Pulmonaire par Interruption Cave Study Group, *N. Engl. J. Med.* 338 (1998) 409–415, <http://dx.doi.org/10.1056/NEJM199802123380701>.
- [4] D.M. Becker, J.T. Philbrick, J.B. Selby, Inferior vena cava filters. Indications, safety, effectiveness, *Arch. Intern. Med.* 152 (1992) 1985–1994, <http://dx.doi.org/10.1001/archinte.1992.00400220023005>.
- [5] C.A. Athanasoulis, J.A. Kaufman, E.F. Halpern, A.C. Waltman, S.C. Geller, C.M. Fan, Inferior vena caval filters: review of a 26-year single-center clinical experience, *Radiology* 216 (2000) 54–66, <http://dx.doi.org/10.1148/radiology.216.1.r00j11254>.
- [6] J. Chung, R.J.T. Owen, Using inferior vena cava filters to prevent pulmonary embolism, *Can. Fam. Physician Médecin Fam. Can.* 54 (2008) 49–55.
- [7] L.F. Angel, V. Tapson, R.E. Galgon, M.I. Restrepo, J. Kaufman, Systematic review of the use of retrievable inferior vena cava filters, *J. Vasc. Interv. Radiol. JVIR* 22 (2011) 1522–1530, <http://dx.doi.org/10.1016/j.jvir.2011.08.024> e3.
- [8] E.J. Ferris, T.C. McCowan, D.K. Carver, D.R. McFarland, Percutaneous inferior vena caval filters: follow-up of seven designs in 320 patients, *Radiology* 188 (1993) 851–856, <http://dx.doi.org/10.1148/radiology.188.3.8351361>.
- [9] P.A. Poletti, C.D. Becker, L. Prina, P. Ruijs, H. Bounameaux, D. Didier, et al., Long-term results of the Simon nitinol inferior vena cava filter, *Eur. Radiol.* 8 (1998) 289–294, <http://dx.doi.org/10.1007/s003300050382>.
- [10] D. Imberti, M. Bianchi, A. Farina, S. Siragusa, M. Silingardi, W. Ageno, Clinical experience with retrievable vena cava filters: results of a prospective observational multicenter study, *J. Thromb. Haemost.* JTH 3 (2005) 1370–1375, <http://dx.doi.org/10.1111/j.1538-7836.2005.01448.x>.
- [11] J.E. Hull, S.W. Robertson, Bard recovery filter: evaluation and management of vena cava limb perforation, fracture, and migration, *J. Vasc. Interv. Radiol. JVIR* 20 (2009) 52–60, <http://dx.doi.org/10.1016/j.jvir.2008.09.032>.
- [12] S.P. Kumar, A. Mahtabifard, J.N. Young, Fractured inferior vena cava filter strut presenting as a penetrating foreign body in the right ventricle: report of a case, *J. Card. Surg.* 23 (2008) 378–381, <http://dx.doi.org/10.1111/j.1540-8191.2007.00539.x>.
- [13] W. Nicholson, W.J. Nicholson, P. Tolerico, B. Taylor, S. Solomon, T. Schryver, et al., Prevalence of fracture and fragment embolization of bard retrievable vena cava filters and clinical implications including cardiac perforation and tamponade, *Arch. Intern. Med.* 170 (2010) 1827–1831, <http://dx.doi.org/10.1001/archinternmed.2010.316>.
- [14] I. Saeed, M. Garcia, K. McNicholas, Right ventricular migration of a recovery IVC filter's fractured wire with subsequent pericardial tamponade, *Cardiovasc. Interv. Radiol.* 29 (2006) 685–686, <http://dx.doi.org/10.1007/s00270-005-0136-7>.
- [15] J.K. Kalavakunta, C.S. Thomas, V. Gupta, A needle through the heart: rare complication of inferior vena caval filters, *J. Invasive Cardiol.* 21 (2009) E221–E223.
- [16] B. Desjardins, S.H. Kamath, D. Williams, Fragmentation, embolization, and left ventricular perforation of a recovery filter, *J. Vasc. Interv. Radiol. JVIR* 21 (2010) 1293–1296, <http://dx.doi.org/10.1016/j.jvir.2010.04.019>.
- [17] J.E. Hull, J. Han, G.M. Giessel, Retrieval of the recovery filter after arm perforation, fracture, and migration to the right ventricle, *J. Vasc. Interv. Radiol. JVIR* 19 (2008) 1107–1111, <http://dx.doi.org/10.1016/j.jvir.2008.03.011>.
- [18] J. Touchan, M.S. Levy, R.J. Laham, Percutaneous retrieval of fractured bird's nest IVC filter penetrating into aorta, *Catheter Cardiovasc. Interv. Off. J. Soc. Card. Angiogr. Interv.* 80 (2012) 657–660, <http://dx.doi.org/10.1002/ccd.24304>.
- [19] S.A. Taheri, M.N. Kulaylat, E. Johnson, E. Hoover, A complication of the greenfield filter: fracture and distal migration of two struts—a case report, *J. Vasc. Surg.* 16 (1992) 96–99, [http://dx.doi.org/10.1016/0741-5214\(92\)90424-7](http://dx.doi.org/10.1016/0741-5214(92)90424-7).
- [20] M.D. Tam, J. Spain, M. Lieber, M. Geisinger, M.J. Sands, W. Wang, Fracture and distant migration of the bard recovery filter: a retrospective review of 363 implantations for potentially life-threatening complications, *J. Vasc. Interv. Radiol. JVIR* 23 (2012) 199–205, <http://dx.doi.org/10.1016/j.jvir.2011.10.017> e1.
- [21] K. Vijay, J.A. Hughes, A.S. Burdette, L.B. Scorza, H. Singh, P.N. Waybill, et al., Fractured bard recovery, G2, and G2 express inferior vena cava filters: incidence, clinical consequences, and outcomes of removal attempts, *J. Vasc. Interv. Radiol. JVIR* 23 (2012) 188–194, <http://dx.doi.org/10.1016/j.jvir.2011.10.005>.
- [22] F.C. Lynch, S. Kekulawela, Removal of the G2 filter: differences between implantation times greater and less than 180 days, *J. Vasc. Interv. Radiol. JVIR* 20 (2009) 1200–1209, <http://dx.doi.org/10.1016/j.jvir.2009.05.039>.
- [23] W. Wang, D. Zhou, N. Obuchowski, J. Spain, T. An, E. Moon, Fracture and migration of Celect inferior vena cava filters: a retrospective review of 741 consecutive implantations, *J. Vasc. Interv. Radiol. JVIR* 24 (2013) 1719–1722, <http://dx.doi.org/10.1016/j.jvir.2013.07.019>.
- [24] A.S. Jassar, S.P. Nicotera, N. Levin, W.J. Vernick, W.Y. Szeto, Inferior vena cava filter migration to the right ventricle, *J. Card. Surg.* 26 (2011) 170–172, <http://dx.doi.org/10.1111/j.1540-8191.2010.01194.x>.
- [25] G. Patel, R. Panikkath, M. Fenire, S. Gadwala, K. Nugent, Indications and appropriateness of inferior vena cava filter placement, *Am. J. Med. Sci.* 349 (2015) 212–216, <http://dx.doi.org/10.1097/MAJ.0000000000000386>.