

DOI: 10.5455/msm.2021.33.75-77

Received: FEB 09 2021; Accepted: MAR 12, 2021

© 2021 Fauzi Yusuf, Reno Keumalazia Kamarlis, Muhsin Muhsin

This is an Open Access article distributed under the terms of the Creative Commons Attribution Non-Commercial License (<http://creativecommons.org/licenses/by-nc/4.0/>) which permits unrestricted non-commercial use, distribution, and reproduction in any medium, provided the original work is properly cited.

## CASE REPORT

Mater Sociomed. 2021 Mar; 33(1): 75-77

# Ulcerative Colitis in Hemophilia A Patient: Case Report

Fauzi Yusuf<sup>1</sup>, Reno Keumalazia Kamarlis<sup>2</sup>, Muhsin Muhsin<sup>3</sup>

<sup>1</sup>Division of Gastroenterology-Hepatology, Department of Internal Medicine,

Faculty of Medicine, Universitas Syiah Kuala, Banda Aceh, Indonesia

<sup>2</sup>Department of Pathology Anatomy, Faculty of Medicine, Universitas Syiah Kuala, Banda Aceh, Indonesia

<sup>3</sup>Department of Internal Medicine, Faculty of Medicine, Universitas Syiah Kuala, Banda Aceh, Indonesia

## Corresponding author:

Fauzi Yusuf, MD, PhD, Division of Gastroenterology-Hepatology, Department of Internal Medicine, Faculty of Medicine, Universitas Syiah Kuala, Address: Jl. Tgk. Daud Beureueh No. 108, Banda Aceh, Indonesia, Phone: +62811683514, E-mail address: fozi\_ysf63@yahoo.co.id, ORCID ID: <https://orcid.org/0000-0002-5822-300X>

## ABSTRACT

**Introduction:** Ulcerative colitis (UC) is a chronic inflammatory disease that affects colon while the incidence is increasing worldwide. The pathogenesis of the disease is complex and involves multi factors such genetic predisposition, defects in epithelial barrier and immune response as well as environmental factors. Combination UC with Hemophilia A, a hereditary hemorrhagic disorder, is very rare but can lead massive rectal bleeding that will be fatal for the patients. **Aim:** The case report present a case of a man with hemophilia A with rectal bleeding and recently diagnosed with ulcerative colitis. **Case Report:** A 52 years old man presented with massive rectal bleeding since 3 days before admitted to hospital. The patient reported recurrent rectal bleeding for years but never continue for more than a week. He was previously diagnosed with hemophilia A since 34 years ago with factor VIII between 5 to 8 percent and receive recombinant human factor VIII routinely. Colonoscopy examination showed redness and ulcer along colon descendent and was confirmed for ulcerative colitis with histopathology analysis. The patient showed clinical improvement after administered with sulfasalazine and tranexamide acid. **Conclusion:** UC can cause fatal bleeding in patient with hemophilia A therefore early diagnosis of UC altogether with UC flare prevention, continuing FVII infusion and anti-hemorrhagic administration are the most important strategy in management UC in hemophilia A patient.

**Keywords:** ulcerative colitis, hemophilia A, FVIII infusion, anti-hemorrhagic drug.

and immune responses as well as environmental factors.(1)and its incidence is rising worldwide. The pathogenesis is multifactorial, involving genetic predisposition, epithelial barrier defects, dysregulated immune responses, and environmental factors. Patients with ulcerative colitis have mucosal inflammation starting in the rectum that can extend continuously to proximal segments of the colon. Ulcerative colitis usually presents with bloody diarrhoea and is diagnosed by colonoscopy and histological findings. The aim of management is to induce and then maintain remission, defined as resolution of symptoms and endoscopic healing. Treatments for ulcerative colitis include 5-aminosalicylic acid drugs, steroids, and immunosuppressants. Some patients can require colectomy for medically refractory disease or to treat colonic neoplasia. The therapeutic armamentarium for ulcerative colitis is expanding, and the number of drugs with new targets will rapidly increase in coming years. Most patients with UC present to hospital with bloody diarrhea that lead to colonoscopy and biopsy. Colonoscopy and histopathology result are gold standard for diagnosing UC. Optimal management of UC including disease-modifying anti rheumatic drugs (DMARDs) and immunosuppressive therapy lead to decreases risk of recurrent that may prevent disease development and complications (1, 2) with low risk of colectomy, and are managed by primary care physicians or gastroenterologists. Optimal management of these patients decreases the risk of relapse and proximal disease extension, and may prevent disease progression, complications, and need for immunosuppressive therapy. With several medications (eg, sulfasalazine, diazobonded 5-aminosalicylates [ASA], mesalamines, and corticosteroids, including budesonide.

Hemophilia A is a hereditary hemorrhagic disorders characterized by lack or dysfunction

## 1. INTRODUCTION

Ulcerative colitis (UC) is a chronic inflammatory disease affecting mucosa of the colon. The pathogenesis of UC involving several etiologies including genetic, defects in epithelial barrier

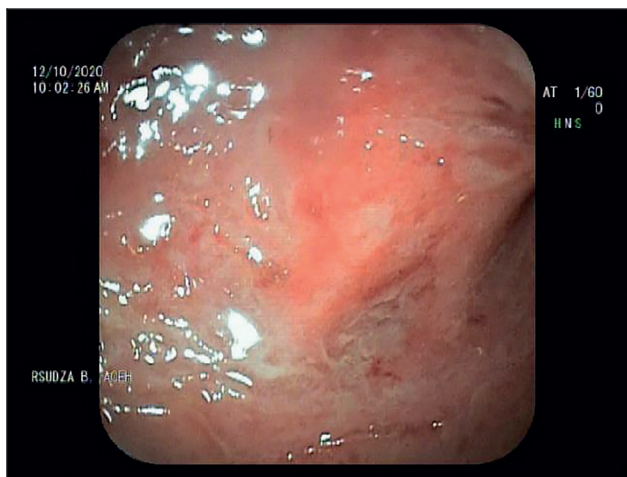


Figure 1. Colonoscopy examination showed ulcer and redness along colon descendent.

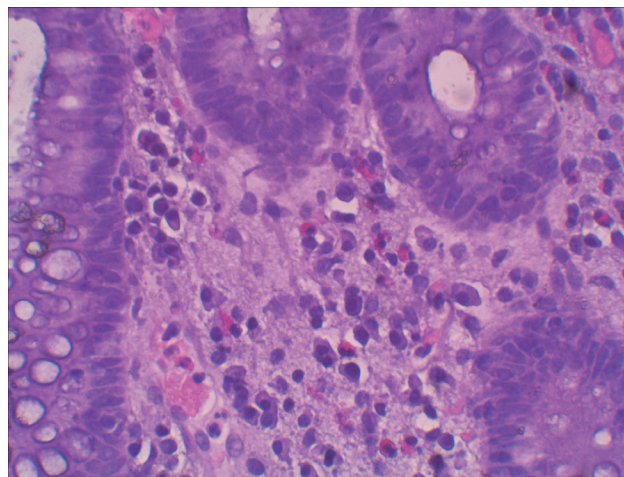


Figure 2. Histopathology result showed plasma cells and lymphocytes (HE, 400x magnification)

of coagulation protein factors VIII that lead to intermittent bleeding. Hemophilia A is potentially become lethal that can cause fatal and recurrent joint, muscle and gastrointestinal bleeding lead to severe musculoskeletal and gastrointestinal damages (3, 4) respectively. Recurrent joint and muscle bleeds lead to severe and progressive musculoskeletal damage. Existing treatment relies on replacement therapy with clotting factors, either at the time of bleeding (ie, on demand). The diagnosis is usually made with blood examination of factor VIII with purpose of the treatment is to minimize the risk of bleeding (5). Since they have different predisposing factor and etiologies, the combination of Hemophilia A and UC is very uncommon.

## 2. AIM

The case report present a case of a man with hemophilia A with rectal bleeding and recently diagnosed with ulcerative colitis.

## 3. CASE REPORT

A 52 years old man came to emergency department with massive rectal bleeding since 3 days before admitted to hospital. He reported recurrent rectal bleeding for 5 years but never continuously for 1 week and never worse than this time. He does not experience pain when defecating or abdominal pain. No history of fever, weight loss, antibiotic use or previous colonoscopy were found. He experienced nosebleeds and bleeding due to injuries that were difficult to stop when he was child. He was previously diagnosed with hemophilia A since 34 year ago with factor activity between 5 and 8 percent. He was routinely infused with recombinant human factor VIII every two or three months. He had a history of controlled diabetes mellitus since 15 years ago using anti diabetic drug combination vildagliptin 5mg/metformin 850mg, 2 times a day.

On physical examination when the patient arrived at emergency department, the patient appeared mildly ill with normal vital signs and physical examination. Hemoglobin was 7.3 g/dl and hematocrit 23%. Other blood parameter showed in normal range. Radiology imaging such as chest X ray and abdominal computed tomography scan were also shown normal. Patient was then scheduled for a colonos-

copy examination after having blood transfusion. Colonoscopy examination showed redness and ulcer along colon descendent specific for ulcerative colitis (UC) as shown in Figure 1 and confirmed with histopathology analysis for UC as shown in Figure 2. He was diagnosed with UC and administered sulfasalazine 500 mg 3 times a day and anti-hemorrhagic tranexamide acid 500 mg 3 times daily. The patient showed clinical improvement and discharged after 5 days' hospitalization. He suggested to control the diseases to Gastroenterology and hematology outpatient centers.

## 4. DISCUSSION

Ulcerative colitis in Hemophilia A patient is a rare and unique case. It shows a more complex spectrum of disease confirmed by colonoscopy and biopsy. Actually, hemophilia A can protect UC by different mechanisms including increasing thrombosis in vena as is commonly found in inflammatory bowel disease patients (6). However, due to coagulation dysfunction in patient with hemophilia A, it can also worsen inflammation and bleeding. Therefore, the exact mechanism of development of UC in hemophilia A patients is still unclear, probably due to local gut thrombogenic dysfunction. Significantly low prevalence of UC in hemophilia A patients that is reported also lead to lack of information regarding this disease combination (7, 8), patients may present with easy bruising, inadequate clotting of traumatic or mild injury, or in severe hemophilia, spontaneous hemorrhage.

Control of bleeding is one of important management for the patients as in our case since subject continued to bleed despite regular and additional dose of recombinant human factor VIII was administrated direct after admitted to hospital. Therapeutic option with anti-hemorrhagic agents such as anti-fibrinolytic can also be considered although the etiology of bleeding may be due to FVIII deficiency alone as data showed that less than 4% of ulcerative colitis patients suffer from massive bleeding. Data on Hemophilia A and UC together are very rare therefore lack of evidence-based protocol can be applied to treat or prevent further episodes of massive bleeding in hemophilia A patient with UC. This case also shows that bleeding in hemophilia A patients with UC can be fatal if not treated. Therefore, comprehensive

management for both conditions including early diagnosis and prevention of UC flares as well as administration of factor VIII and anti-hemorrhagic agent are very important to prevent worsening of the patients.

## 5. CONCLUSION

Since UC in hemophilia A can cause fatal bleeding in patient with hemophilia A, early diagnosing and prevention UC flare is the most important strategy in management UC in hemophilia A patient. FVIII should be continued and anti-hemorrhagic should be added in these patients in order to prevent severe bleeding and progression of UC.

- **Authors contribution:** All authors were involved in preparation this article. Final proofreading was made by the first author.
- **Conflict of interest:** None to declared.
- **Financial support and sponsorship:** No specific funding was received for this study.

## REFERENCES

1. Ungaro R, Mehandru S, Allen PB, Peyrin-Biroulet L, Colombel JF. Ulcerative colitis. *Lancet*. 2017; 389(10080): 1756-1770.
2. Singh S, Feuerstein JD, Binion DG, Tremaine WJ. AGA Technical Review on the Management of Mild-to-Moderate Ulcerative Colitis. *Gastroenterology* [Internet]. 2019; 156(3): 769-808. e29. Available from: <https://doi.org/10.1053/j.gastro.2018.12.008>.
3. Peyvandi F, Garagiola I, Young G. The past and future of haemophilia: diagnosis, treatments, and its complications. *Lancet* [Internet]. 2016; 388(10040): 187-197. Available from: [http://dx.doi.org/10.1016/S0140-6736\(15\)01123-X](http://dx.doi.org/10.1016/S0140-6736(15)01123-X).
4. Srivastava A, Brewer AK, Mauser-Bunschoten EP, Key NS, Kitchen S, Llinas A, et al. Guidelines for the management of hemophilia. *Haemophilia*. 2013; 19(1): 1-47.
5. Lamb CA, Kennedy NA, Raine T, Hendy PA, Smith PJ, Limdi JK, et al. British Society of Gastroenterology consensus guidelines on the management of inflammatory bowel disease in adults. *Gut*. 2019; 68: s1-106.
6. Thompson NP, Wakefield AJ, Pounder RE. Inherited Disorders of Coagulation Appear to Protect Against Inflammatory Bowel Disease. *Gastroenterology*. 1995;(108): 1011-1015.
7. Olivier M, Madruga M, Carlan SJ, Ge L. Hemophilia A Complicated by Ulcerative Colitis. *Case Rep Gastrointest Med*. 2018; 2018: 1-3.
8. Nishimura T, Naka H, Yamashita T, Morii N, Yoshioka A, Hisao F, et al. Haemophilia A with Ulcerative Colitis. *Japanese J Thromb Hemost*. 1990; 1(2): 141-144.