



Aptis Distal Radioulnar Joint Implant: Management of Remarkable Complications

Shirley D. Stougie, BHS^{1,2,*} Frederique M. Kemme, MD^{1,*} J. Henk Coert, MD, PhD²
Joris G. M. Oonk, MSc³ Lara Plugge, MSc¹ Margriet H. M. van Doesburg, MD, PhD¹

¹Plastic, Reconstructive and Hand Surgery, Amsterdam UMC, Amsterdam, The Netherlands

²Plastic, Reconstructive and Hand Surgery, University Medical Centre Utrecht, Utrecht, The Netherlands

³Biomedical Engineering and Physics, Amsterdam UMC location University of Amsterdam, Amsterdam, The Netherlands

Address for correspondence Shirley D. Stougie, BHS, Plastic, Reconstructive and Hand Surgery, Amsterdam UMC, Meibergdreef 9, 1105 Amsterdam, The Netherlands
(e-mail: shirleystougie@gmail.com).

J Wrist Surg 2025;14:134–143.

Abstract

Background The aim of an Aptis distal radioulnar joint (DRUJ) implant is to reconstruct the DRUJ in patients with a destroyed, painful DRUJ, and gross ulnar instability. The literature is scarce regarding the management of (severe) early complications related to the Aptis implant in wrists with more rare conditions, such as rheumatoid arthritis, congenital malformations, or leiomyosarcoma of the distal ulna.

Purpose This paper describes the clinical results, (severe) early complications related to the implant, revision surgery, patient satisfaction with the revision surgery, and esthetic appearance of the affected wrist in this specific cohort.

Materials and Methods Retrospective evaluation of five consecutive patients with a short-to-medium follow-up time of 32 months (range: 18–53 months) was carried out.

Results The follow-up revealed implant osseointegration failure in two cases, peri-prosthetic fractures in two cases, and acute carpal tunnel syndrome in one case. Three Aptis DRUJ arthroplasties were converted into a proximal Darrach. In four cases (80%), the patient was satisfied with the revision surgery due to pain reduction. In four cases (80%), the esthetic appearance of the affected wrist was found disappointing.

Conclusion This study describes remarkable complications related to the Aptis implants in wrists with more rare conditions. The implant is more likely to fail in wrists with poor bone stock, remodeling of the radius, deformation, and malformation of the radius. The range of indications for the usage of the implant to maintain wrist function may be strict.

Level of Evidence IV.

Keywords

- ▶ Aptis
- ▶ distal radioulnar joint
- ▶ arthroplasty
- ▶ rheumatoid arthritis
- ▶ congenital malformations
- ▶ complications

Rheumatoid arthritis, congenital malformations, and destruction of the distal ulna resulting in a destroyed, painful distal radioulnar joint (DRUJ), and ulnar instability can compromise wrist function and diminish the quality of

life. Conventional procedures for this complex ulnar pathology can lead to gross ulnar instability and pain.¹ Scheker and colleagues² designed the (semi-) constrained Aptis DRUJ implant to address these problems, as most patients prefer pain reduction and preservation of wrist motion. The implant aims to reconstruct the DRUJ and is associated with

* Both authors contributed equally to the manuscript.

received

June 19, 2023

accepted

January 9, 2024

article published online

February 2, 2024

DOI <https://doi.org/10.1055/s-0044-1779448>.

ISSN 2163-3916.

© 2024. The Author(s).

This is an open access article published by Thieme under the terms of the Creative Commons Attribution-NonDerivative-NonCommercial-License, permitting copying and reproduction so long as the original work is given appropriate credit. Contents may not be used for commercial purposes, or adapted, remixed, transformed or built upon. (<https://creativecommons.org/licenses/by-nc-nd/4.0/>)

Thieme Medical Publishers, Inc., 333 Seventh Avenue, 18th Floor, New York, NY 10001, USA

positive clinical results, high survival rates, high patient satisfaction, and yet a high incidence of complications and revision surgery are reported.^{3–12} Stougie et al⁴ proposed that the current design of the implant could lead to limited proximal-distal translation of the radius along the ulnar axis during pronation–supination motion and displacement of the forearm rotation axis and may explain the possible causes for complications and revision surgery.

To date, the literature is scarce regarding the management of complications related to the Aptis implant in wrists with more rare conditions, such as rheumatoid arthritis, congenital malformations, or tumors in the distal end of the ulna.^{13,14}

To this end, this study aims to describe the clinical results, management of remarkable complications, patient satisfaction regarding revision surgery, and the esthetic appearance of the wrist in this specific cohort.

Materials and Methods

Study Design

Patients with an Aptis DRUJ implant in wrists with rheumatoid arthritis, Madelung's deformity, and distal ulna resection due to a leiomyosarcoma were retrospectively identified. The patients were treated between 2011 and 2023 at a tertiary university hospital. Nine patients were screened for eligibility, and five patients agreed to participate. Patients were asked for written informed consent during medical follow-up. In this study, one patient, with a history of rheumatoid arthritis and awaiting a one-bone forearm procedure, of the study of Stougie³ was included and evaluated at a longer follow-up time.

Clinical data were extracted from the patient's medical files: demographics; dominant hand, affected hand, relevant medical history, indications, complications, revision surgery, wrist range of motion, the visual analog scale (VAS) for pain, work/hobby status, patient satisfaction with revision surgery and the esthetic appearance of the wrist, X-rays, computed tomography scans, and magnetic resonance imaging (MRI) scans. The complications following implantation of the Aptis implant within a period of 24 months were reported and graded by the Clavien–Dindo Classification.¹⁵ This study was approved by the Medical Ethics Committee of our hospital.

Surgical Technique and Postoperative Treatment

In all cases, the second-generation Aptis implant (Aptis Medical, Louisville, KY, United States) was placed and the procedures were performed in the standard fashion by two senior surgeons with an experience level V as described by Nakamura.¹⁶

Scheker et al² described the surgical technique in detail and specifically used a retinaculum flap to cover the implant. However, in this study, the senior surgeons performed a small modification of this original surgical technique by approaching the DRUJ through the fifth extensor compartment followed by opening the dorsal DRUJ capsule and closing the fifth extensor compartment to cover the implant. The postoperative treatment consisted of 7 days of short arm casting and hand therapy; active mobilization of the wrist

was allowed in all directions and gradual weight bearing with a maximum weight lifting of up to 15 kilograms 3 months postoperatively according to the Aptis manual.

Radiographic Assessment

Postoperative X-rays were reviewed at surgical follow-up for positioning and signs of implant loosening.

Statistics

Descriptive analyses were used to describe the study cohort in terms of (severe) complications related to the implant, revision surgery, patient satisfaction with the revision surgery, and esthetic appearance of the affected wrist.

Results

Demographics and Follow-up

Demographic characteristics, follow-up, and surgical characteristics are listed in ►Table 1. The database search identified two men and three women with a (mean) age of 51 years (range: 35–69 years). The dominant hand was operated in three patients. All patients had undergone between 1 and 4 surgical procedures before the placement of the Aptis implant. The main indication was a destroyed DRUJ and ulnar instability as a result of rheumatoid arthritis ($n = 3$), Madelung's deformity ($n = 1$), and a distal ulna resection due to a leiomyosarcoma ($n = 1$). The (mean) follow-up time was 32 months (range: 18–53 months). Functional complaints, complications identification after Aptis DRUJ arthroplasty, Clavien–Dindo classification, radiological follow-up, and revision surgery are listed in ►Table 2. Patient satisfaction with revision surgery, patient satisfaction with esthetic appearance, pain status after revision surgery, and hobby/work status are listed in ►Table 3. The complications requiring revision surgery in all cases will be described and in Cases 1, 2, and 3 X-rays will be used for illustration. In Case 1, a preoperative MRI scan will be used for illustration as well.

Clinical Evaluation

Case 1

A right-handed, 52-year-old man, with a history of leiomyosarcoma in the right distal ulna (►Fig. 1A, B) presented with severe wrist pain and limited forearm rotation. The VAS for pain was eight points during activities and zero points at rest.

The symptoms were caused by a leiomyosarcoma destroying the distal ulna for which removal of the leiomyosarcoma and an Aptis DRUJ arthroplasty was performed in one single session. The procedure was complicated by aseptic loosening of the ulna component at 1 year postoperatively (►Fig. 2A). Possible explanations for the aseptic loosening could be altered DRUJ geometry and a displacement of the forearm rotation axis^{4,17} most likely resulting in a deviation of the radius toward the ulna causing extreme friction forces (►Fig. 2B). Other causes could be the size of the ulna pen which was too little for the ulna shaft (►Fig. 2C) or a relatively short ulna shaft after the removal of the leiomyosarcoma. At 43 months of follow-up, the surgeon

Table 1 Demographics characteristics, follow-up, and surgical characteristics

| Case | Age (years) | Gender M/F | Follow-up time (months) | Dominant hand | Affected hand | Indication | Relevant medical history | Previous surgeries |
|------|-------------|------------|-------------------------|---------------|---------------|------------------------------|---|--------------------|
| 1 | 52 | M | 53 | R | R | Ulna destruction | Leiomyosarcoma distal ulna (R) | None |
| 2 | 46 | F | 21 | R | R | Destroyed DRUJ + instability | Rheumatoid arthritis | 1 |
| 3 | 54 | M | 45 | R | L | Destroyed DRUJ + instability | Rheumatoid arthritis Radioscapholunate fusion (L) Aptis implant (L) Dislocation radial component Aptis implant (L) Reimplantation Aptis implant (L) Recurrent dislocation radial component (L) | 4 |
| 4 | 69 | F | 18 | R | L | DRUJ OA + instability | Systemic lupus erythematosus | None |
| 5 | 35 | F | 22 | R | R | DRUJ OA + instability | Madelung's deformity | None |
| Mean | 51,2 | | 31,8 | | | | | |

Abbreviations: DRUJ, distal radioulnar joint; OA, osteoarthritis.

Table 2 Functional complaints, complications identification after Aptis DRUJ arthroplasty, Clavien–Dindo classification, radiological follow-up, revision surgery

| Case | Functional complaints | Complications (months) | Clavien-Dindo classification | Radiological evaluation (months) | Revision surgery (months) |
|------|----------------------------|--|------------------------------|--|---|
| 1 | Pain | Aseptic loosening ulna component (12) | Grade IIIa | Implant osseointegration failure (12) | Disconnection of the implant (43) Explantation (48 mo after initial placement) |
| 2 | Pain | Periprosthetic fracture at proximal screw level (5 wk postoperative) | Grade IIIa | Periprosthetic fracture at proximal screw level (5 wk postoperative) Malunion of the radius in volar and ulnar deviation (13) | Explantation and corrective osteotomy of the radius in one single session (16) |
| 3 | Pain, limited wrist motion | Nonunion after one bone forearm procedure | Grade IIIa | Dislocation radial component implant (3) Nonunion one bone forearm procedure (4) | One bone forearm procedure (18) Removal osteosynthesis material and ulnar shortening osteotomy in one single session (4) |
| 4 | Pain | Periprosthetic fracture at proximal screw level (5 wk postoperative) | Grade IIIa | Malunion and volar angulation of the radius (9 wk postoperatively) | Proximal screw removal and corrective osteotomy (10) |

Table 2 (Continued)

| Case | Functional complaints | Complications (months) | Clavien-Dindo classification | Radiological evaluation (months) | Revision surgery (months) |
|------|-----------------------|--|------------------------------|----------------------------------|---|
| 5 | Pain | Acute carpal tunnel syndrome (1 d postoperatively) | Grade IIIa | None | Carpal tunnel release (1 day postoperatively) |

Table 3 Patient satisfaction with revision surgery, patient satisfaction with esthetic appearance, pain status after revision surgery, and hobby/work status

| Case | Patient satisfaction with revision surgery | Patient satisfaction with esthetic appearance | Pain status after revision surgery | Work/Hobby status |
|------|--|---|---|--|
| 1 | Satisfied; despite limited weight bearing capacity | Not satisfied | Pain reduction | Able to resume rowing in the gym |
| 2 | Satisfied | Not satisfied | VAS 7 during activities VAS 5 at rest | Able to resume work as professional golf teacher |
| 3 | Satisfied | Not satisfied | Considerable pain reduction | Not reported |
| 4 | Satisfied | Not reported | Pain reduction | Not reported |
| 5 | Not reported | Not satisfied | VAS 10 during activities VAS 8 at rest | Able to resume work as a cashier |
| % | (80%) | (80%) | | |

Abbreviation: VAS, visual analogue scale.

disconnected the implant (► **Fig. 2D**) due to persisting wrist pain (VAS five points during activities and VAS zero points at rest) possibly as a result of implant osseointegration failure. Finally, the patient requested the implant to be removed, 4 years postoperatively (► **Fig. 2E**) because the pain reduced after disconnecting the implant, most likely as a result of reduced friction forces. The patient did not want to undergo a

new reconstruction due to the risk of failure again from the patient's perspective.

At a follow-up time of 6 months after the removal of the implant, the patient was satisfied despite limited weight-bearing capacity and the disappointing esthetic appearance of the wrist. He was able to resume rowing in the gym, but it was no longer possible to do high-impact activities such as push-ups.

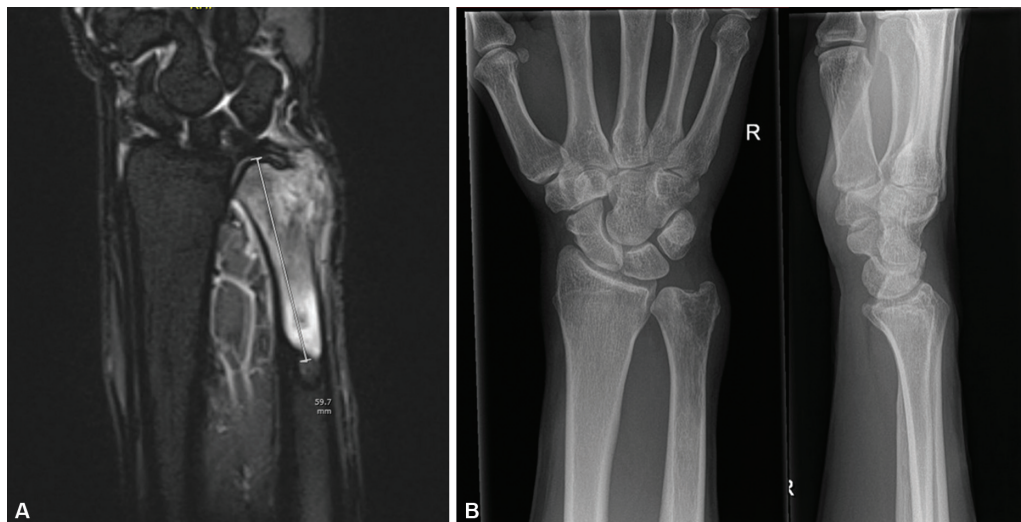


Fig. 1 (A) Preoperative MRI scan Case 1, note the appearance of the leiomyosarcoma (59,7 mm) in the end of the right distal ulna. (B) Preoperative anteroposterior and lateral X-rays of Case 1 before placement of the Aptis implant.

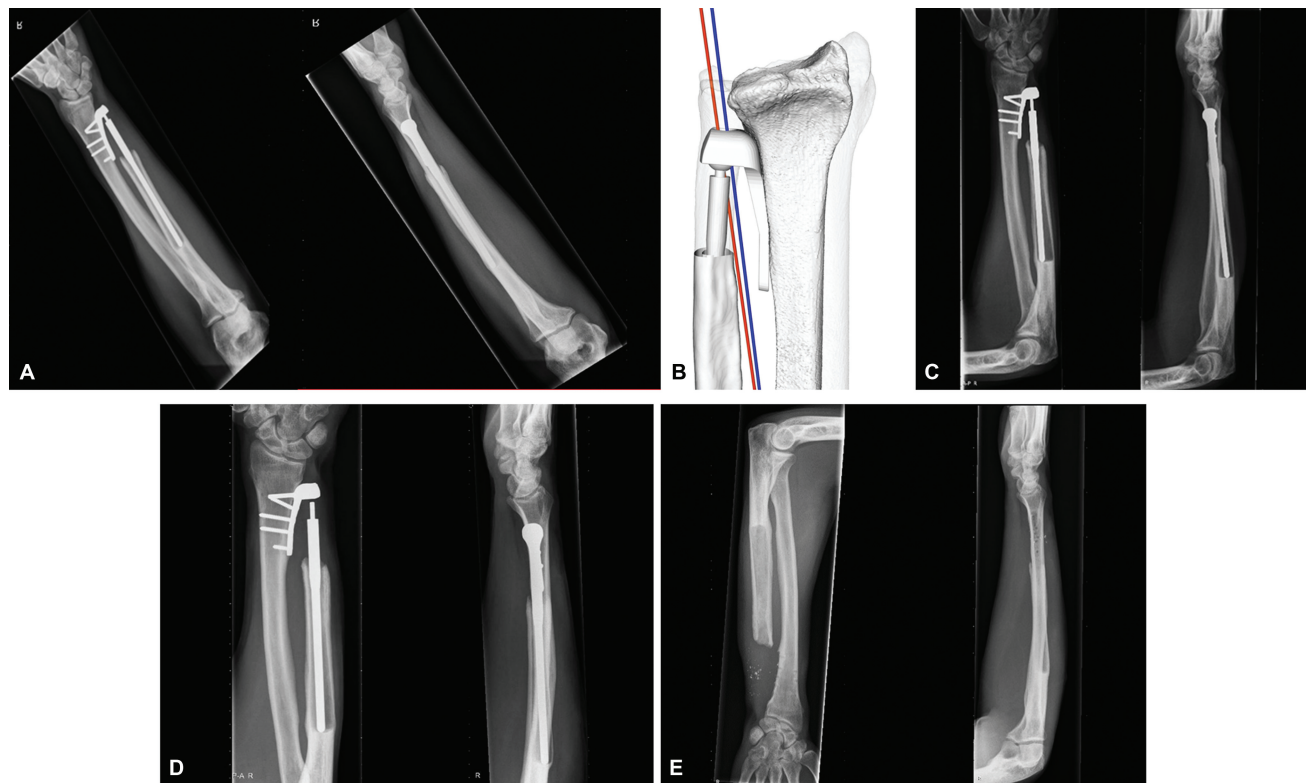


Fig. 2 (A) Anteroposterior and lateral X-rays of Case 1, 12 months after the placement of the Aptis implant. Note, the implant osseointegration failure. (B) The axis of rotation in a forearm with an Aptis implant (red) relative to the axis of rotation in a healthy forearm (blue). Illustration of an Aptis implant resulting in the deviation of the radius toward the ulna, mirrored on the contralateral healthy forearm. (C) Anteroposterior and lateral X-rays of Case 1, 36 months after placement of the Aptis implant. Note, the implant osseointegration failure in the ulna. (D) Anteroposterior and lateral X-rays of Case 1, 43 months after placement of the Aptis implant. Note, the disconnection of the implant. (E) Anteroposterior and lateral X-rays of Case 1, 48 months after placement of the Aptis implant.

Case 2

A right-handed, 46-year-old woman, with a history of rheumatoid arthritis, right-sided total wrist arthrodesis, and Darrach procedure, presented with severe wrist pain and

limited wrist motion as a result of a destroyed DRUJ and gross ulnar instability. To address these problems, an Aptis implant was placed. Five weeks postoperatively, the procedure was complicated by a periprosthetic fracture (► **Fig. 3**) at the level

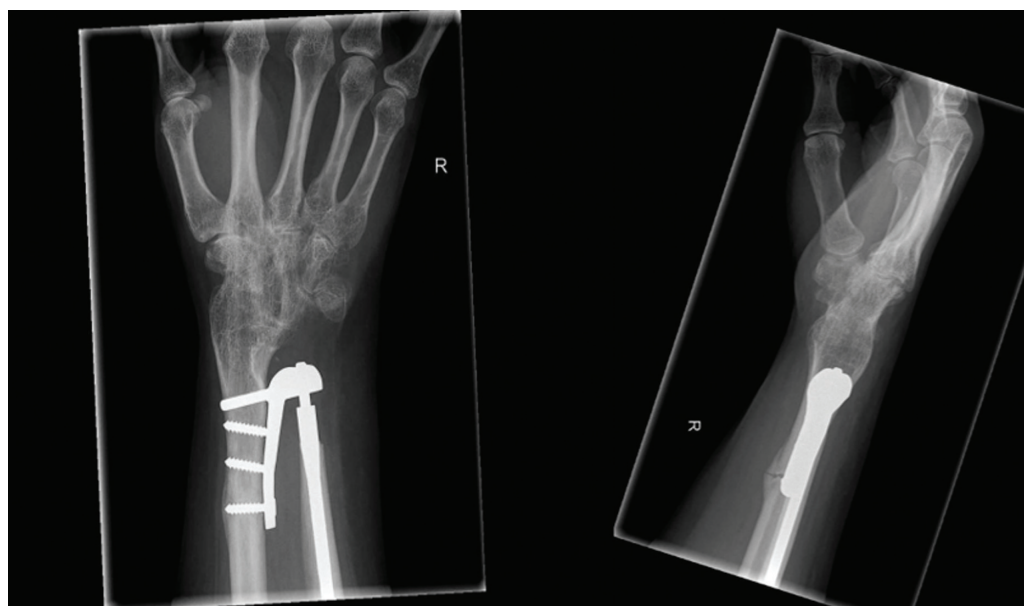

Fig. 3 Anteroposterior and lateral X-rays of Case 2, 3 months after the placement of the Aptis implant. Note, the periprosthetic fracture at the level of the proximal screw.

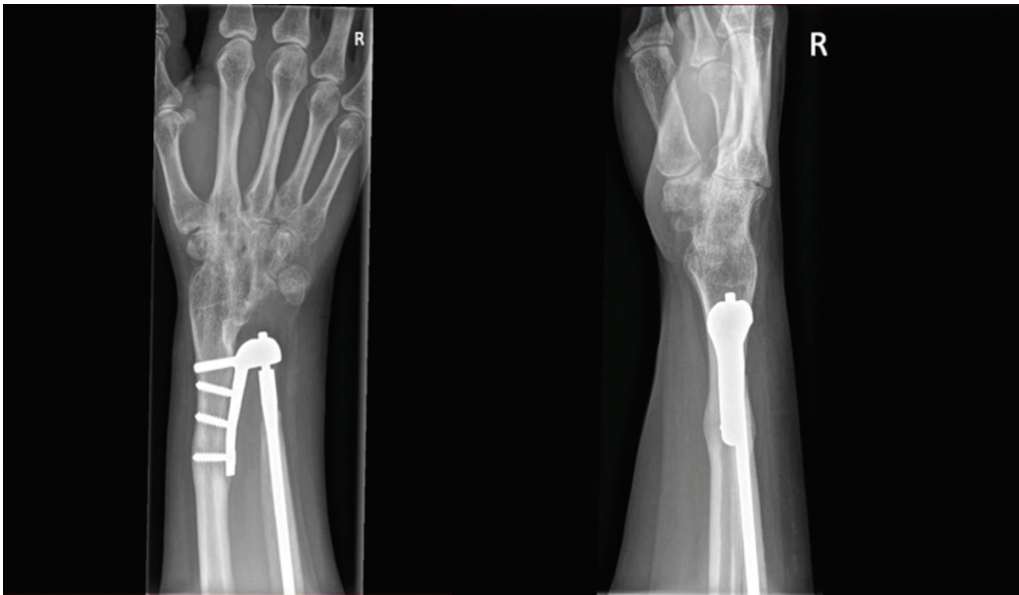


Fig. 4 Anteroposterior and lateral X-rays of Case 2, 13 months after the placement of the Aptis implant.

of the bicortical proximal screw, most likely as a result of poor bone stock and proximal placement of the implant due to the considerable curvature of the radius. Mall et al¹⁸ described that the mean radial length in women is 22 cm unlike 24.6 cm in men. The radial component in this case could have been relatively large and caused extreme friction forces resulting in a periprosthetic fracture. Unfortunately, the patient kept considerable ulnar-sided as well as radial-sided wrist pain and limited wrist motion (supination 40 degrees and pronation 50 degrees) after short arm

casting. The patient was not able to perform her work as a professional golf teacher. X-rays taken at 13 months postoperatively showed a malunion of the radius in volar and ulnar deviation (►Fig. 4). ►Fig. 5 illustrates a three-dimensional reconstruction of the malpositioning of the implant in the distal region of the radius with a volar angulation after a periprosthetic fracture. After 16 months of follow-up, the implant was removed and a corrective osteotomy of the radius was adequately performed (►Fig. 6). Five months postoperatively the patient was satisfied with this revision

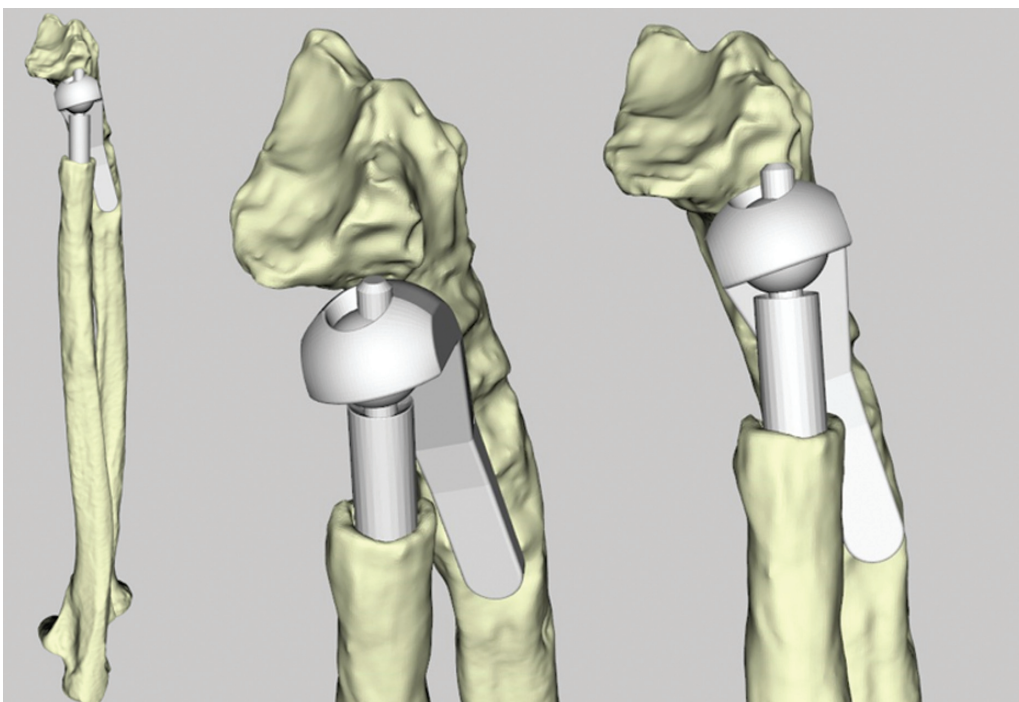


Fig. 5 Illustration of the three-dimensional reconstruction of malpositioning of the implant in the distal region of the radius with a volar angulation. Note, the dorsal placement of the implant.

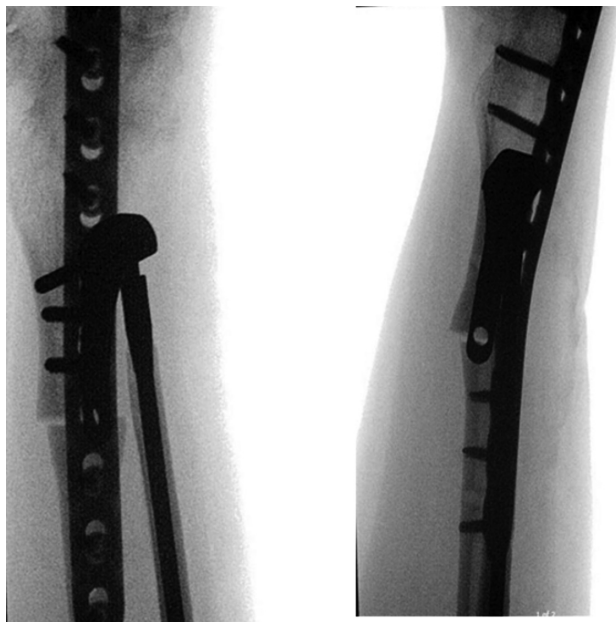


Fig. 6 Perioperative anteroposterior and lateral X-rays of Case 2, 16 months after placement of the Aptis implant.

procedure, despite pain (VAS 5 at rest and VAS 7 during activities) and the disappointing esthetic appearance of the wrist. The patient could resume her work as a golf professional teacher.

Case 3

A right-handed, 54-year-old man, with a history of rheumatoid arthritis, and left-sided combined radio scapholunate fusion and placement of an Aptis implant, presented with severe wrist pain (VAS 10 points during activities and VAS 10 points at rest) and limited wrist motion, 4 months postoperatively, most likely as a result of the dislocation of the radial

component due to inflammation of rheumatoid arthritis or a low-grade infection. The radial component was removed after 4 months and during surgery specimens for bacterial cultures, and histology were collected. Unfortunately, this procedure was complicated by an extensor pollicis longus (EPL) tendon rupture. The patient was treated with antibiotics for the clinical suspicion of a low-grade infection. Four months later, the ulnar component was removed. Nine months after the removal of the ulnar component, a new Aptis DRUJ arthroplasty and an extensor indicis proprius tendon to EPL tendon transposition were performed in one single session. Unfortunately, 3 months postoperatively, the patient presented with severe wrist pain again and X-rays showed a recurrent dislocation of the radial component. To this end, the implant was explanted, and after 18 months, a one-bone forearm procedure was performed with an autologous iliac crest bone graft (►Fig. 7), which was complicated by a nonunion (►Fig. 8). The osteosynthesis material was removed after 4 months, and the ulna was shortened at the proximal shaft (►Fig. 9). The patient was satisfied with this revision procedure, 44 months after the initial placement of the Aptis implant, due to considerable pain reduction, and uses a custom made short-arm splint during daily living activities. The patient, however, was not satisfied with esthetic appearance of the wrist.

Case 4

A right-handed, 69-year-old woman, with a history of systemic lupus erythematosus, presented with severe left-sided wrist pain due to DRUJ osteoarthritis and ulnar instability for which reason an Aptis DRUJ arthroplasty was performed. Unfortunately, the procedure was complicated at 5 weeks by a periprosthetic fracture at the level of the proximal bicortical screw, after lifting a heavy object. The clinical consequences were pain and limited rotation (supination

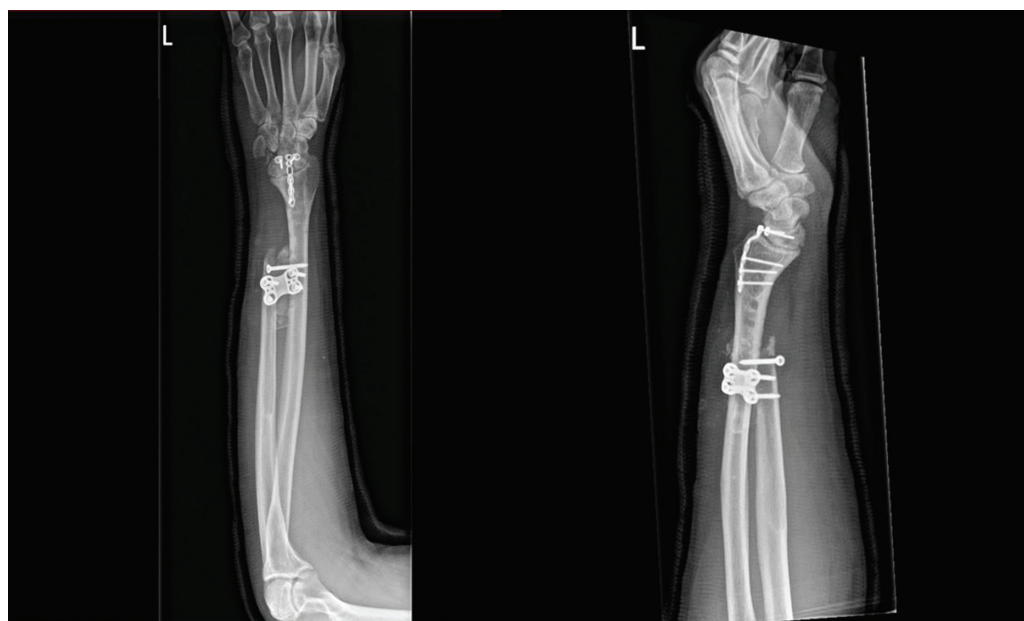

Fig. 7 Anteroposterior and lateral X-rays of Case 3, 1 week after one bone forearm procedure.

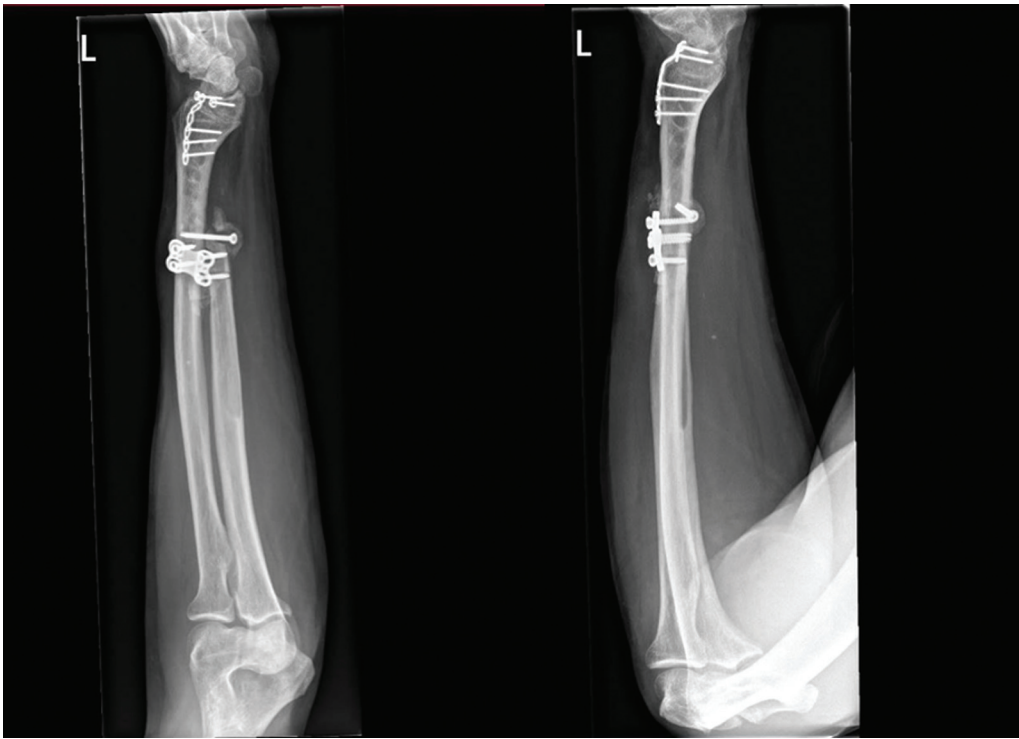


Fig. 8 Anteroposterior and lateral X-rays of Case 3, 2, 5 months after one bone forearm procedure. Note, the non-union.

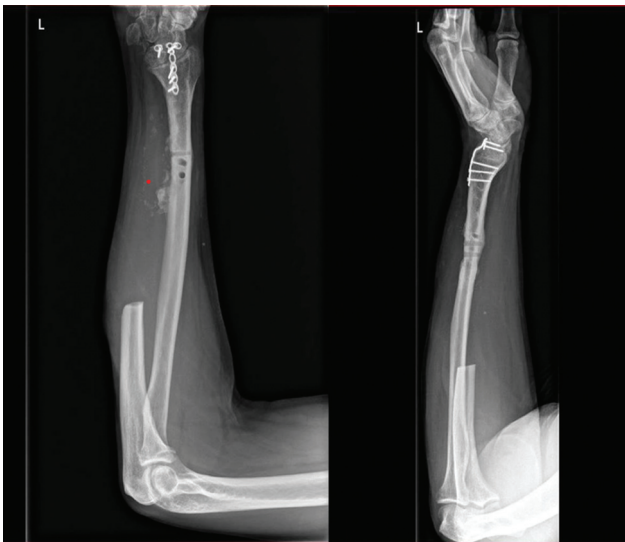


Fig. 9 Anteroposterior and lateral X-rays of Case 3, after the removal of the osteosynthesis material and shortening the ulna at the proximal shaft.

30 degrees and pronation 70 degrees). X-rays at 9 weeks postoperatively showed a malunion and a volar angulation of the radius. Ten months postoperatively, the screw of the radial component at the level of the fracture was removed and a corrective osteotomy of the radius, with the implant left in situ, was performed with the usage of a bridging plate, which adequately reduced the pain and the rotation (60 degrees supination and 80 degrees pronation) was reasonable.

Case 5

A right-handed, 35-year-old woman, with a history of Madelung's deformity presented with severe right-sided wrist pain (VAS 10 points during activities and eight points at rest) due to DRUJ osteoarthritis and instability. The placement of an Aptis DRUJ implant was complicated by an acute carpal tunnel syndrome as a result of postoperative edema, which was adequately released 1 day postoperatively. The patient was not satisfied with the procedure, despite a good forearm rotation (90 degrees supination and 90 degrees pronation) and pain reduction. The VAS pain score showed a noteworthy improvement from 10 points to 8 points during activities. However, there was no notable change in the VAS pain score at rest, which remained at 8. The esthetic appearance of the wrist was found very disappointing. The patient could resume her work as a cashier in the supermarket.

Discussion

The present study focused on evaluating the clinical results, management of remarkable complications, and patient satisfaction with revision surgery in patients with an Aptis implant in wrists with more rare conditions. The Aptis implant has been associated with both positive functional outcomes and a high incidence of complications and revision surgery in the literature. Our results are quite disappointing compared with the findings of previously conducted studies.^{11–13} Galvis et al¹¹ suggested that an Aptis implant is of benefit for patients with rheumatoid arthritis and reported good clinical results and patient satisfaction with the implant of 17 patients. Coffey et al¹² reported good clinical

results and patient satisfaction of three patients with Madelung's deformity with a follow-up time of 2 years. Pacheco-Núñez et al.¹³ suggested that a custom-made implant can be used to reconstruct the DRUJ after resection of the distal ulna due to a tumor and reported promising results in one case with a follow-up time of 4 years. On the contrary, Cooney et al.¹⁴ suggested that the reconstruction of the DRUJ is not required after the removal of a tumor in the distal end of the ulna to maintain wrist function, which is in line with the findings in this study.

The follow-up of five cases revealed remarkable complications requiring revision surgery: implant osseointegration failure ($n=2$), periprosthetic fractures ($n=2$), and acute carpal tunnel syndrome ($n=1$). Possible explanations for the cause of the complications could be a strict range of indications for usage of the implant, malpositioning of the implant, or the current design of the implant⁴ which could have resulted in deviation of the radius toward the ulna causing extreme friction forces. Of note, the esthetic appearance of the affected wrist was found disappointing in most cases, since the patients suggested that their hand was rotated relative to the forearm.

Nonetheless, in three cases the Aptis DRUJ arthroplasty was converted into a proximal Darrach due to persisting wrist pain. In Case 1, the Aptis implant was removed at the request of the patient. The patient kept considerable wrist pain, most likely as a result of friction forces of the radius relative to the ulna due to a small size of the ulna pen or a large resection of the distal ulna, which could be a result of an inadequate indication or inadequate placement of the implant.

The surgeon suggested the removal of the implant in two stages. At first, the surgeon disconnected the implant, most likely to evaluate pain after the reduction of friction forces. Second, the surgeon suggested preparing the ulna for a new reconstruction by using a bone graft substitute after the removal of the implant. However, the patient was satisfied with the pain reduction after disconnecting the implant, and the Aptis DRUJ arthroplasty was converted into a Darrach 4 years after the placement of the Aptis implant.

In Case 2 and Case 3, it was found to be inevitable to perform new Aptis DRUJ arthroplasties due to the curvature of the radius and poor bone stock. In Case 2, the question arises if treatment with a volar plate would have been a better option to avoid malunion of the radius in volar and ulnar deviation due to the possible friction forces of the implant on the radius. In an attempt to stabilize the radius and ulna in Case 3, a one-bone forearm procedure was performed. Unfortunately, a nonunion occurred. The patient was satisfied with considerable pain reduction after the removal of the osteosynthesis and shortening of the ulna at the proximal shaft. In Case 4, the same question applies to operative treatment versus short arm casting as in Case 2, operative treatment of the periprosthetic fracture could have been considered in an attempt to stabilize the radius with the implant in situ.

In case 5, a young woman with Madelung's deformity, the decision to perform an Aptis DRUJ arthroplasty as the

primary treatment option is debatable since the implant is designed to fit patients with DRUJ anatomy in a normal range. Therefore, the implant may cause problems when used in patients with altered DRUJ geometry and displacement of the forearm rotation axis due to deformations and congenital malformations of the radius. A corrective osteotomy of the radius should have been considered as the initial treatment to treat the deformity of the radius before the placement of an Aptis implant.

This study has several limitations. First, the retrospective design and the fact that pre- and postoperative data regarding active range of motion and VAS scores for pain are missing. In addition, data regarding patient satisfaction with the revision surgery and the esthetic appearance were extracted from the patient's electronic medical files. This is a descriptive cohort study with a heterogeneous and small study group. We described remarkable complications related to the Aptis implant used in rare indications. We aimed to raise awareness among surgeons that this is a good implant for wrists with primary and posttraumatic DRUJ osteoarthritis and ulnar instability. However, it may have a strict range of indications for usage in wrists with poor bone stock and considerable deformation and malformation of the radius.

In conclusion, this study describes remarkable complications related to the Aptis implants in wrists with more rare conditions. The implant is more likely to fail in wrists with poor bone stock, remodeling of the radius, deformation, and malformation of the radius.

Authors' Contributors

All named authors were actively involved in the planning, enactment, and writing up of the study.

Ethical Approval

Approval of the Medical Ethical Committee of the Amsterdam University Medical Center, the Netherlands.

Patient's Consent

Written informed consent was obtained from a legally authorized representative (s) for anonymized patient information to be published in this article.

Funding

None.

Conflict of Interest

None declared.

References

- 1 Kachooei AR, Chase SM, Jupiter JB. Outcome assessment after Aptis distal radioulnar joint (DRUJ) implant arthroplasty. *Arch Bone Jt Surg* 2014;2(03):180–184
- 2 Schecker LR, Babb BA, Killion PE. Distal ulnar prosthetic replacement. *Orthop Clin North Am* 2001;32(02):365–376, x
- 3 Stougie SD, Boekel LCV, Beumer A, Hoogvliet P, Strackee SD, Coert JH. Aptis Distal Radioulnar Joint Arthroplasty: A Multicenter Evaluation of Functional Outcomes, Complications, and Patient Satisfaction. *J Wrist Surg* 2023;13(04):318–327

- 4 Stougie SD, van Doesburg MHM, Oonk JGM, et al. Performance of the Aptis distal radioulnar joint implant: a clinical case series including four-dimensional computed tomography kinematic analysis. *J Clin Med* 2023;12(18):5815
- 5 Amundsen A, Rizzo M, Berger RA, Houdek MT, Frihagen F, Moran SL. Twenty-year experience with primary distal radioulnar joint arthroplasty from a single institution. *J Hand Surg Am* 2023;48(01):53–67
- 6 DeGeorge BR Jr, Berger RA, Shin AY. Constrained implant arthroplasty for distal radioulnar joint arthrosis: evaluation and management of soft tissue complications. *J Hand Surg Am* 2019;44(07):614.e1–614.e9
- 7 Warlop J, Nuffel MV, Smet L, Degreef I. Midterm functional outcomes of the linked semiconstrained distal radioulnar joint prosthesis. *J Wrist Surg* 2021;11(04):335–343
- 8 Fuchs N, Meier LA, Giesen T, Calcagni M, Reissner L. Long-term results after semiconstrained distal radioulnar joint arthroplasty: a focus on complications. *Hand Surg Rehabil* 2020;39(03):186–192
- 9 Reissner L, Böttger K, Klein HJ, Calcagni M, Giesen T. Midterm results of semiconstrained distal radioulnar joint arthroplasty and analysis of complications. *J Wrist Surg* 2016;5(04):290–296
- 10 Moulton LS, Giddins GEB. Distal radio-ulnar implant arthroplasty: a systematic review. *J Hand Surg Eur Vol* 2017;42(08):827–838
- 11 Galvis EJ, Pessa J, Scheker LR. Total joint arthroplasty of the distal radioulnar joint for rheumatoid arthritis. *J Hand Surg Am* 2014;39(09):1699–1704
- 12 Coffey MJ, Scheker LR, Thirkannad SM. Total distal radioulnar joint arthroplasty in adults with symptomatic Madelung's deformity. *Hand (N Y)* 2009;4(04):427–431
- 13 Pacheco-Núñez JA, Sheppard JE, Mahoney AP. Distal ulna leiomyosarcoma treated with custom polymethylmethacrylate prosthesis with a 4-year follow-up. *Hand (N Y)* 2015;10(03):541–546
- 14 Cooney WP, Damron TA, Sim FH, Linscheid RL. En bloc resection of tumors of the distal end of the ulna. *J Bone Joint Surg Am* 1997;79(03):406–412
- 15 Clavien PA, Barkun J, de Oliveira ML, et al. The Clavien-Dindo classification of surgical complications: five-year experience. *Ann Surg* 2009;250(02):187–196
- 16 Nakamura T. Surgeons' level of expertise. *J Wrist Surg* 2020;9(03):185–185
- 17 Oonk JGM, Dobbe JGG, Strijkers GJ, van Rijn SK, Streekstra GJ. Kinematic analysis of forearm rotation using four-dimensional computed tomography. *J Hand Surg Eur Vol* 2023;48(05):466–475
- 18 Mall G, Hubig M, Büttner A, Kuznik J, Penning R, Graw M. Sex determination and estimation of stature from the long bones of the arm. *Forensic Sci Int* 2001;117(1-2):23–30