

Original Article

Age-dependent changes in vancomycin-induced nephrotoxicity in mice

Masaki Takigawa^{1,2}, Hirofumi Masutomi¹, Yoshitomo Shimazaki^{1,2}, Tomio Arai³, Jaewon Lee⁴, Toshihiro Ishii⁵, Yoshiko Mori^{1,2}, and Akihito Ishigami^{1*}

¹ Molecular Regulation of Aging, Tokyo Metropolitan Institute of Gerontology, 35-2 Sakae-cho, Itabashi-ku, Tokyo 173-0015, Japan

² Department of Pharmacy, Tokyo Metropolitan Geriatric Hospital, 35-2 Sakae-cho, Itabashi-ku, Tokyo 173-0015, Japan

³ Department of Pathology, Tokyo Metropolitan Geriatric Hospital, 35-2 Sakae-cho, Itabashi-ku, Tokyo 173-0015, Japan

⁴ College of Pharmacy, Pusan National University, 2, Busandaehak-ro 63beon-gil, Geumjeong-gu, Busan 46241, Korea

⁵ Department of Practical Pharmacy, Faculty of Pharmaceutical Sciences, Toho University, 2-2-1 Miyama, Funabashi, Chiba 274-8510, Japan

Abstract: Vancomycin hydrochloride (VCM) is a glycopeptide antibiotic that is commonly used to eradicate methicillin-resistant gram-positive cocci, despite its nephrotoxic side effects. Elderly people are particularly susceptible to developing VCM-induced nephrotoxicity. However, the precise mechanism by which VCM induces nephrotoxicity in elderly people is not completely understood. Therefore, we investigated VCM-induced nephrotoxicity in mice of different ages. VCM was injected intraperitoneally into mice at 1, 3, 6, 12, and 24 months of age at a dosage of 400 mg/kg body weight for 3 and 14 days. Twenty-four hours after the last injection, we examined plasma creatinine levels and histopathological alterations in the kidneys. VCM administration increased plasma creatinine levels, and these values gradually increased to higher levels with aging. The histological examination revealed renal tubular degeneration, such as brush-border atrophy, apoptosis/necrosis of the tubular epithelium, and epithelial desquamation, that gradually became more severe with aging. Furthermore, immunohistochemical staining with anti-CD10 and anti-single-stranded DNA antibodies revealed damaged renal proximal tubules with marked dilatation, as well as numerous apoptotic cells, and these features increased in severity in 12- and 24-month-old mice receiving VCM. Based on these results, aged mice were highly susceptible to kidney damage induced by VCM administration. In addition, proximal tubular epithelial cells likely underwent apoptosis after the administration of VCM. This report is the first to document VCM-induced nephrotoxicity in mice of different ages. Thus, this mouse model could be useful for understanding the mechanisms of VCM-induced nephrotoxicity in the elderly. (DOI: 10.1293/tox.2018-0036; J Toxicol Pathol 2019; 32: 57–66)

Key words: aging, apoptosis, kidney, mouse, nephrotoxicity, vancomycin

Introduction

Vancomycin hydrochloride (VCM) is a routinely prescribed antibiotic that is used to treat humans who are infected with methicillin-resistant gram-positive cocci, such as *Staphylococcus aureus*, *S. epidermidis*, and enterococci^{1, 2}. Since the incidence of these infections has increased substantially in recent years, the use of this medication has widely increased³. VCM is mainly excreted via the kidney, where its damaging side effects occur^{4, 5}. In fact, VCM-in-

duced nephrotoxicity has been reported in 5–25% of recipient patients⁶, constituting the major clinical cause of renal failure.

Previously, we reported time-dependent alterations of VCM-induced nephrotoxicity in mice, focusing on detailed biochemical and histological analyses of the VCM-induced nephrotoxicity process⁷. In our previous study, VCM was intraperitoneally injected into 3-month-old mice at a dose of 400 mg/kg body weight at 24-h intervals for 3, 5, 7, and 14 days, and VCM-induced renal damage and incipient renal failure began soon after the first treatment and progressively worsened. Furthermore, a histological examination of VCM-treated mice revealed renal damage, such as dilated proximal tubules with occasional casts and interstitial fibrosis. The severity of the symptoms progressed until day 15. This mouse model is exceedingly useful for clarifying the poorly understood mechanism of VCM-induced nephrotoxicity.

VCM treatment is known to lead to progressive renal

Received: 9 June 2018, Accepted: 1 October 2018

Published online in J-STAGE: 10 December 2018

*Corresponding author: A Ishigami (e-mail: ishigami@tmig.or.jp)

©2019 The Japanese Society of Toxicologic Pathology

This is an open-access article distributed under the terms of the Creative Commons Attribution Non-Commercial No Derivatives

(by-nc-nd) License. (CC-BY-NC-ND 4.0: <https://creativecommons.org/licenses/by-nc-nd/4.0/>).



failure in the elderly^{8,9}. Therefore, patient age is a prominent risk factor for VCM-induced renal failure¹⁰. In fact, several clinical studies have reported VCM-induced renal failure in the elderly^{11,12}. Sokol *et al.*¹² reported that renal failure began only 3 days after the initial VCM treatment in 71-year-old females with MRSA bacteremia. Moreover, according to Mizokami *et al.*¹¹, elderly patients with potentially poor renal function are likely to have increased area under the curve (AUC) values for VCM and a poor prognosis. Thus, elderly people are susceptible to developing renal failure after treatment with VCM; however, the details of its mechanism of onset remain unclear. Furthermore, no reports have been published regarding the effects of aging on VCM-induced renal failure in an aged mouse model. Therefore, we used mice of different ages to investigate whether aging is a factor that exacerbates VCM-induced renal failure.

Materials and Methods

Animals

Animal experiments were performed in accordance with the animal care and use protocol approved by the Institutional Animal Care and Use Committee of Tokyo Metropolitan Institute of Gerontology (TMIG) (Permit Number: 12001) and the TMIG Guidelines for the Care and Use of Laboratory Animals. Male C57BL/6NCrSlc mice aged 1, 3, 6, 12, and 24 months of age were obtained from the animal facility of TMIG, Tokyo, Japan. All mice were fed a commercial chow diet (CRF-1, Oriental Yeast Co., Ltd., Tokyo, Japan) and were maintained on a 12-h/12-h light/dark cycle in a controlled environment. The number of animals used in this study was kept to the minimum necessary for a meaningful interpretation of the data, and animal discomfort was minimized. Aged mice were divided into groups according to the random comparison group method used in pharmacology. Mice were randomly assigned to the VCM treatment and control groups prior to the start of the experiment.

VCM administration and group sizes

VCM (Lot No. AWM1657, Wako Pure Chemical, Osaka, Japan) was dissolved in saline and intraperitoneally injected into each mouse at a dose of 400 mg/kg body weight at 24-h intervals for 3 and 14 days, as shown in Fig. 1A. The administration period and dose were consistent with a previous study that confirmed the occurrence of renal injury in mice⁷. VCM was administered to ten mice in each group at 1, 3, 6, 12, and 24 months of age, while the control groups contained ten mice each at 1 and 3 months of age and nine mice each at 6, 12, and 24 months of age.

Mortality and body weight measurement

Survival of mice of different ages was checked daily during VCM treatment until the end of the experiment. The body weight of the mice was measured on the 1st, 4th, and 15th days during the experimental period.

Biochemical analysis of plasma

Twenty-four hours after the last injection, mice were sacrificed under anesthesia with pentobarbital, and blood was collected from the inferior vena cava of each mouse into an ethylenediaminetetraacetic acid (EDTA)-containing syringe. Plasma was obtained by centrifuging the blood samples at $880 \times g$ for 10 min at 4°C, followed by storage at -80°C until use. The plasma levels of creatinine (P-Cre) were assessed biochemically (Oriental Yeast Co., Ltd., Tokyo, Japan).

Kidney weight measurement, histological analysis, and normalization

After blood samples were collected, the mice were systemically perfused with ice-cold phosphate-buffered saline through the left ventricle to remove the remaining blood from the tissues. The kidneys were removed and then weighed. Each kidney was divided longitudinally into two sections of equal size, which were then fixed with 10% formalin for 48 h. Each formalin-fixed kidney was embedded in paraffin and serially cut into 4- μ m-thick sections. After deparaffinization, kidney sections were subjected to hematoxylin-eosin (HE), periodic acid-Schiff (PAS), and azan staining. Digital images of all specimens were captured using a NanoZoomer 2.0-RS virtual slide imaging system (Hamamatsu Photonics, Hamamatsu, Japan). For estimation of the renal tubular and glomerular sizes, twenty tubules and glomeruli in HE-stained kidney sections were randomly selected, and the minor axis of each was measured using NDP.view2 (Hamamatsu Photonics). The number of casts in renal tubules was counted in a single randomly selected 1 mm² field from the HE-stained kidney sections. The percentages of interstitial fibrosis areas were measured using the WinROOF Ver. 7.4.1 image analysis software (MITANI Corporation, Fukui, Japan) in a single randomly selected 0.4 mm² field from the azan-stained kidney sections.

Immunohistochemistry and normalization

Kidney sections were stained with a rabbit polyclonal anti-CD10 antibody (1:400 dilution, ab109275, Abcam plc, Cambridge, UK) to verify that the damaged renal tubules were proximal tubules¹³, a rabbit polyclonal anti-single-stranded DNA (ssDNA) antibody (1:400 dilution, A4506, DAKO Japan Co., Ltd., Tokyo, Japan), which is a marker of apoptosis¹⁴, and a VECTASTAIN Elite ABC kit (VECTOR Laboratories, Inc., Burlingame, CA, USA); 3,3'-diaminobenzidine was the chromogenic substrate. The number of CD10-positive dilated proximal tubules was counted in one randomly selected 1 mm² field from the kidney sections stained with the anti-CD10 antibody. The percentage of positive ssDNA-stained areas (containing the tubules with the affected nuclei) was measured in one randomly selected 0.4 mm² field from the kidney sections stained with the ssDNA antibody.

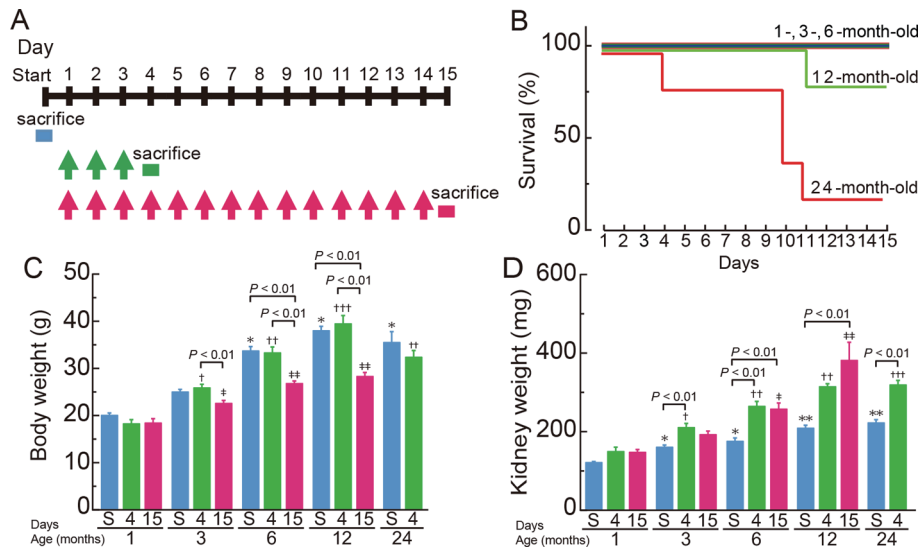


Fig. 1. Experimental design, survival, and body and kidney weights of VCM-treated mice of various ages. (A) Schematic representation of the experimental design for VCM administration. VCM was intraperitoneally injected into mice at a dose of 400 mg/kg body weight at 24-h intervals for 3 (n=10 mice in each age group) and 14 days (n=10 mice in each age group). Mice were sacrificed 24 h after the last injection. Control mice aged 1 and 3 months (n=10) and 6, 12, and 24 months (n=9) on the 1st day were sacrificed. (B) Survival rates of mice of different ages after the VCM treatment. (C) Body and (D) kidney weights were measured on the indicated days. Statistical analyses were performed using one-way analysis of variance (ANOVA) followed by post hoc unpaired t-tests with the Bonferroni correction. Differences between age groups were considered significant at $P < 0.01$. (C) * $P < 0.01$ compared with 1- and 3-month-old mice on the 1st day. † $P < 0.01$ compared with 1-month-old mice on the 4th day of VCM treatment. †† $P < 0.01$ compared with 1- and 3-month-old mice on the 4th day of VCM treatment. ††† $P < 0.01$ compared with 1-, 3-, 6-, and 24-month-old mice on the 4th day of VCM treatment. ‡ $P < 0.01$ compared with 1-month-old mice on the 15th day of VCM treatment. ‡† $P < 0.01$ compared with 1- and 3-month-old mice on the 15th day of VCM treatment. (D) * $P < 0.01$ compared with 1-month-old mice on the 1st day of VCM treatment. ** $P < 0.01$ compared with 1-, 3-, and 6-month-old mice on the 1st day of VCM treatment. † $P < 0.01$ compared with 1-month-old mice on the 4th day of VCM treatment. ††† $P < 0.01$ compared with 1-, 3-, and 6-month-old mice on the 4th day of VCM treatment. ‡ $P < 0.01$ compared with 1-month-old mice on the 15th day of VCM treatment. ‡†† $P < 0.01$ compared with 1-, 3-, and 6-month-old mice on the 15th day of VCM treatment.

Data blinding and statistical analysis

Body and kidney weights, P-Cre levels, mean values for the minor axes of renal tubules, mean values for the minor axes of renal glomeruli, numbers of casts, numbers of tubules with epithelial desquamation, percentages of area positive for interstitial fibrosis, numbers of CD10-positive tubules with renal proximal tubular degeneration, and percentages of ssDNA-positive areas were analyzed by two observers who were blinded to the animal group assignments. Data files were labeled with the date and a sample identifier. The data were analyzed in this file format and subsequently assigned to the corresponding experimental conditions using laboratory records.

The results are presented as means \pm standard errors of the means (SEM). The probability of significant differences between experimental groups was determined using analysis of variance (ANOVA) followed by post hoc unpaired t-tests with the Bonferroni correction. All statistical analyses were performed using GraphPad Prism 6 (GraphPad Software, Inc., San Diego, CA USA). Differences were considered significant at $P < 0.01$.

Results

Survival, body weight, and kidney weight of mice of different ages during VCM treatment

Survival is shown in Fig. 1B. During the experimental period, the first 24-month-old mice died after 3 days of VCM treatment, and 80% of mice in that age group died in the first 11 days of VCM treatment. Moreover, the first 12-month-old mice died after 11 days of VCM treatment. However, no mice in the 1-month, 3-month, or 6-month age groups died until 15 days of VCM treatment. Since only a small number of 24-month-old mice were alive on the 14th day of VCM treatment, these mice were excluded from the subsequent analysis.

The mean body weights are shown in Fig. 1C. The mean body weights of 12-month-old mice on the 1st day were significantly higher by 1.9- and 1.5-fold than those of 1- and 3-month-old mice, respectively. The 12-month-old mice displayed significantly greater mean body weights on the 4th day of VCM treatment, with their mean body weights being significantly higher by 2.2-, 1.5-, 1.2- and 1.2-fold than those of 1-, 3-, 6-, and 24-month-old mice, respectively. The mean body weights of 12-month-old mice on the 15th day of VCM

treatment were significantly higher by 1.5- and 1.3-fold than those of 1- and 3-month-old mice, respectively, and those of 3-, 6-, and 12-month-old mice on the 15th day of VCM treatment were significantly decreased by 0.9-, 0.8-, and 0.7-fold, respectively, compared with the same age groups on the 4th day of VCM treatment. The mean body weights of 6- and 12-month-old mice on the 15th day of VCM treatment were significantly decreased by 0.8- and 0.7-fold, respectively, compared with the same age groups on the 1st day.

The mean kidney weights are shown in Fig. 1D. The mean kidney weights of 24-month-old mice on the 1st day were significantly higher by 1.8-, 1.4-, and 1.3-fold than those of 1-, 3-, and 6-month-old mice, respectively, and those of 12-month-old mice on the 1st day were significantly higher by 1.7-, 1.3-, and 1.2-fold than those of 1-, 3-, and 6-month-old mice, respectively. The mean kidney weights of 24-month-old mice on the 4th day of VCM treatment were significantly increased by 2.1-, 1.5-, and 1.2-fold compared with the 1-, 3-, and 6-month-old mice, respectively, and those of 12-month-old mice on the 4th day of VCM treatment were significantly higher by 2.1- and 1.5-fold higher than those of 1- and 3-month-old mice, respectively. The mean kidney weights of 12-month-old mice on the 15th day of VCM treatment were significantly increased by 2.6-, 2.0-, and 1.5-fold compared with 1-, 3-, and 6-month-old mice, respectively, and those of 6-month-old mice on the 15th day of VCM treatment were significantly increased by 1.7-fold compared with 1-month-old mice. The mean kidney weights of 3-, 6- and 24-month-old mice on the 4th day of VCM treatment were significantly higher by 1.3-, 1.5- and 1.4-fold, respectively, than those of the same age groups on the 1st day. Finally, the mean kidney weights were observed in 6- and 12-month-old mice on the 15th day of VCM treatment were significantly higher by 1.5- and 1.8-fold, respectively, than those of the same age groups on the 1st day.

Biochemical analysis of P-Cre levels

The P-Cre levels are shown in Fig. 2. The P-Cre levels of 24-month-old mice on the 1st day were significantly higher by 7.8-, 5.8-, 8.9-, and 5.4-fold than those of 1-, 3-, 6-, and 12-month-old mice, respectively, and those of 24-month-old mice on the 4th day of VCM treatment were significantly increased by 12.2-, 10.1-, and 7.6-fold compared with 1-, 3-, and 6-month-old mice, respectively. The P-Cre levels of 12-month-old mice on the 15th day of VCM treatment were significantly higher by 10.9-fold than those of 1-month-old mice, and those of 1-, 3-, and 12-month-old mice on the 15th day of VCM treatment were significantly increased by 3.4-, 3.6-, and 25.8-fold, respectively, compared with the same age groups on the 1st day. The P-Cre levels in 1- and 3-month-old mice on the 15th day of VCM treatment were significantly increased by 1.8- and 2.1-fold, respectively, compared with the same age groups on the 4th day. Finally, the P-Cre levels in 3-month-old mice on the 4th day of VCM treatment were significantly increased by 1.7-fold compared with the same age group on the 1st day.

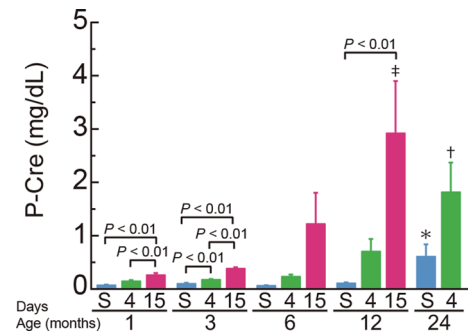


Fig. 2. Plasma Cre levels in VCM-treated mice. The plasma Cre levels in mice were measured on the indicated days. First day, 1 and 3 months old (n=10 mice) and 6, 12, and 24 months old (n=9 mice); 4th day, 1, 3, and 6 months old (n=10 mice), 12 months old (n=9 mice), and 24 months old (n=8 mice); 15th day, 1, 3 and 6 months old (n=10 mice) and 12 months old (n=8 mice). Values are presented as means \pm SEM. Statistical analyses were performed using one-way ANOVA followed by post hoc unpaired t-tests with the Bonferroni correction. Differences between groups were considered significant at $P < 0.01$. * $P < 0.01$ compared with 1-, 3-, 6-, and 12-month-old mice on the 1st day. † $P < 0.01$ compared with 1-, 3-, and 6-month-old mice on the 4th day of VCM treatment. ‡ $P < 0.01$ compared with 1-month-old mice on the 15th day of VCM treatment. P-Cre, plasma creatinine.

Histological analysis of kidneys from VCM-treated mice during aging

Histological data are shown in Fig. 3. The histological examination revealed renal tubular degeneration, such as brush-border atrophy, apoptosis/necrosis of the tubular epithelium, and epithelial desquamation (white arrowheads), which appeared in 3-, 6-, 12-, and 24-month-old mice after 4 days of VCM treatment, and the damage gradually became more severe with aging. However, marked damage was not observed in 1-month-old mice after 4 days of VCM treatment. On the 15th day of VCM treatment, renal tubular degeneration was observed in mice aged 1, 3, 6, and 12 months, and the damage gradually became more severe with aging. On the 1st day, renal tubular degeneration was observed in the 24-month-old group. However, marked damage was not observed on the 1st day in mice aged 1, 3, 6, or 12 months. PAS staining revealed tubular epithelial desquamation and hyaline casts (black arrowheads) after 4 days of VCM treatment in mice aged 1, 3, 6, 12, and 24 months, and these features continuously increased in severity with aging. On the 15th day of VCM treatment, tubular epithelial desquamation was observed in 1-, 3-, 6-, and 12-month-old mice, and the damage gradually became more severe with aging. On the 1st day, tubular epithelial desquamation and hyaline casts (black arrowheads) were observed in the 24-month-old group. However, marked damage was not observed in mice aged 1, 3, 6, or 12 months. Azan staining showed interstitial fibrosis in the kidneys of mice aged 1, 3, 6, and 12 months after 15 days of VCM treatment, and the fibrosis gradually increased in severity with aging (white arrows). In contrast,

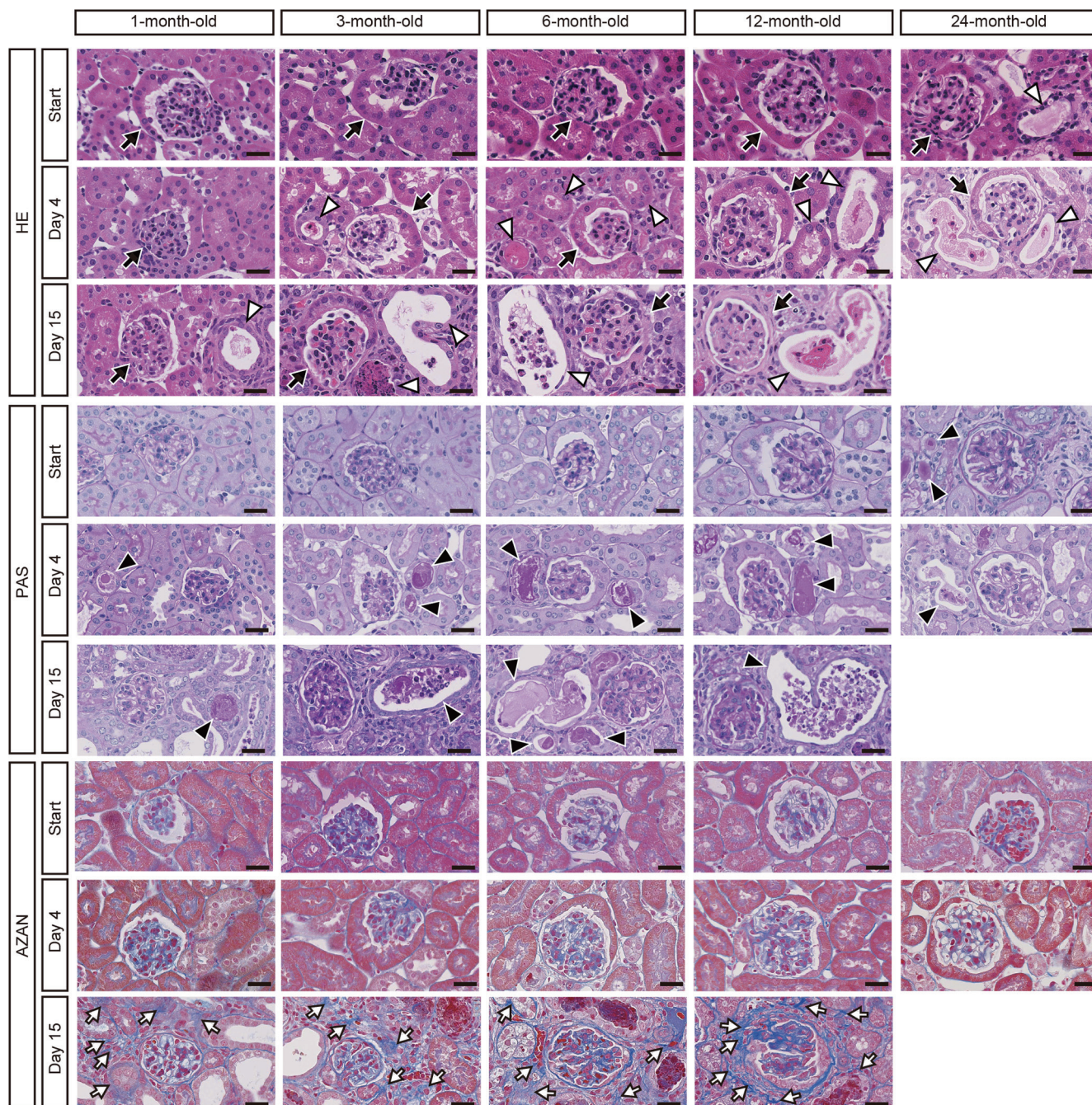


Fig. 3. Histological analysis of kidneys from VCM-treated mice. Black arrows indicate glomeruli. White arrowheads indicate renal tubular degeneration. Black arrowheads indicate tubular epithelial desquamation. White arrows indicate interstitial fibrosis. Bars, 25 μ m. HE, hematoxylin-eosin staining. PAS, periodic acid-Schiff staining.

on the 1st day and the 4th day of VCM treatment, interstitial fibrosis in kidneys was not observed in any of the age groups – 1, 3, 6, 12, or 24 months.

Measurements of the mean minor axis of the renal tubules are shown in Fig. 4A. The mean minor axes of the renal tubules of 6-, 12-, and 24-month-old mice on the 1st day were significantly larger than those of 1- or 3-month-old mice. The mean minor axes of the renal tubules of 24-month-old mice on the 4th day of VCM treatment were

significantly larger than those of 1-, 3-, or 6-month-old mice, and those of 6- and 12-month-old mice on the 4th day of VCM treatment were significantly larger than those of 1- or 3-month-old mice. The mean minor axes of the renal tubules of 12-month-old mice on the 15th day of VCM treatment were significantly larger than those of 1-, 3-, or 6-month-old mice, and those of 1-, 3-, 6-, and 12-month-old mice on the 15th day were significantly larger than those of the same age groups on the 4th day of VCM treatment. Additionally,

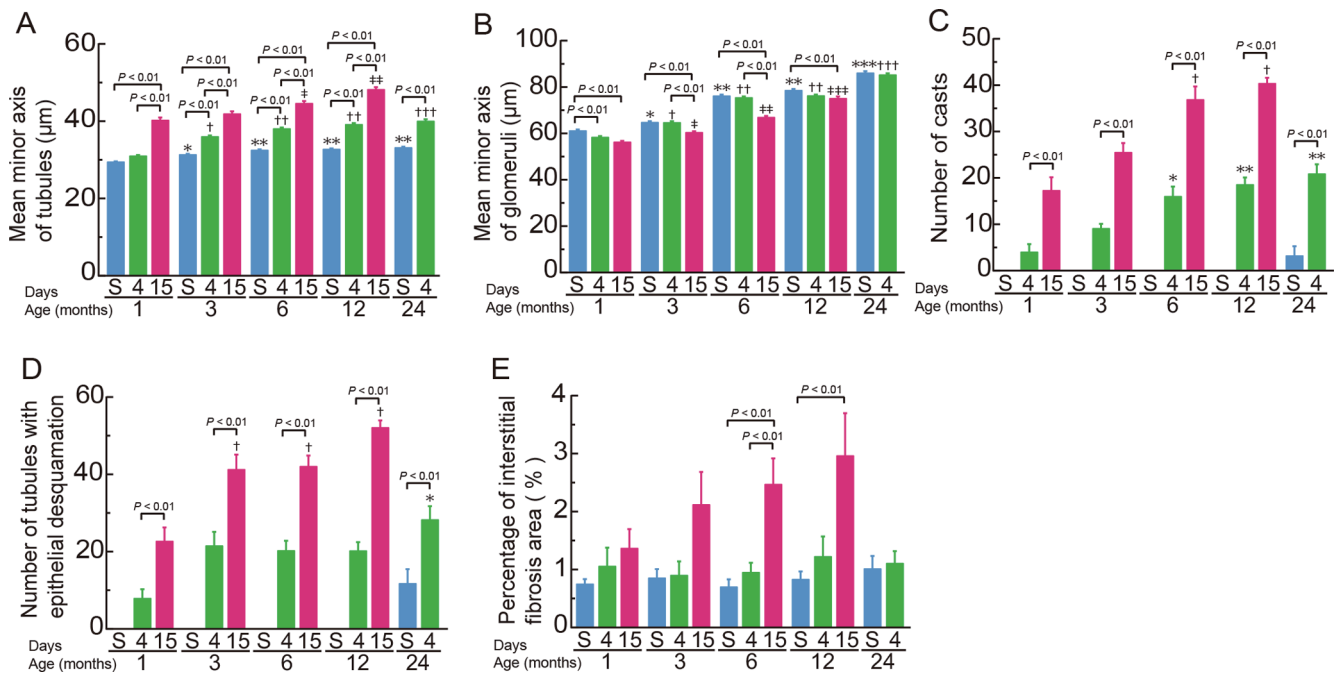


Fig. 4. Estimates of renal tubule and glomerulus sizes, numbers of casts in renal tubules, tubular epithelial desquamation, and percentages of interstitial fibrosis areas in VCM-treated mice. The mean values for minor axes of renal tubules (A) and glomeruli (B), numbers of casts in renal tubules (C), numbers of tubules exhibiting epithelial desquamation (D), and percentages of interstitial fibrosis areas (E) in VCM-treated and control mice were evaluated as described in the Materials and Methods section. First day, 1 and 3 months old ($n=10$ mice) and 6, 12, and 24 months old ($n=9$ mice); 4th day, 1, 3, and 6 months old ($n=10$ mice), 12 months old ($n=9$ mice), and 24 months old ($n=8$ mice); 15th day, 1, 3 and 6 months old ($n=10$ mice) and 12 months old ($n=8$ mice). Values are presented as the means \pm SEM of eight to ten animals. Statistical analyses were performed using one-way ANOVA followed by post hoc unpaired t-tests with the Bonferroni correction. Differences between age groups were considered significant at $P<0.01$. (A) * $P<0.01$ compared with 1-month-old mice on the 1st day. ** $P<0.01$ compared with 1- and 3-month-old mice on the 1st day. † $P<0.01$ compared with 1-month-old mice on the 4th day of VCM treatment. †† $P<0.01$ compared with 1- and 3-month-old mice on the 4th day of VCM treatment. ††† $P<0.01$ compared with 1-, 3- and 6-month-old mice on the 4th day of VCM treatment. ‡ $P<0.01$ compared with 1-month-old mice on the 15th day of VCM treatment. ‡‡ $P<0.01$ compared with 1-, 3-, and 6-month-old mice on the 15th day of VCM treatment. (B) * $P<0.01$ compared with 1-month-old mice on the 1st day. ** $P<0.01$ compared with 1- and 3-month-old mice on the 1st day. *** $P<0.01$ compared with 1-, 3-, 6-, and 12-month-old mice on the 1st day of VCM treatment. † $P<0.01$ compared with 1-month-old mice on the 4th day of VCM treatment. †† $P<0.01$ compared with 1- and 3-month-old mice on the 4th day of VCM treatment. ††† $P<0.01$ compared with 1-, 3-, 6-, and 12-month-old mice on the 4th day of VCM treatment. ‡ $P<0.01$ compared with 1-month-old mice on the 15th day of VCM treatment. ‡‡ $P<0.01$ compared with 1- and 3-month-old mice on the 15th day of VCM treatment. ‡‡‡ $P<0.01$ compared with 1-, 3-, and 6-month-old mice on the 15th day of VCM treatment. (C) * $P<0.01$ compared with 1-month-old mice on the 4th day of VCM treatment. ** $P<0.01$ compared with 1- and 3-month-old mice on the 4th day of VCM treatment. † $P<0.01$ compared with 1- and 3-month-old mice on the 15th day of VCM treatment. (D) * $P<0.01$ compared with 1-month-old mice on the 4th day of VCM treatment. † $P<0.01$ compared with 1-month-old mice on the 15th day of VCM treatment.

the mean minor axes of the renal tubules of 1-, 3-, 6-, and 12-month-old mice on the 15th day were significantly larger than those of the same age groups on the initial day of VCM treatment. Finally, the mean minor axes of the renal tubules of 3-, 6-, 12-, and 24-month-old mice on the 4th day were significantly larger than the same age groups on the 1st day.

Measurements of the mean minor axis of the glomeruli are shown in Fig. 4B. The mean minor axes of the renal glomeruli of 24-month-old mice on the 1st day were significantly larger than those of 1-, 3-, 6-, or 12-month-old mice, and those of 6- and 12-month-old mice on the 1st day were significantly larger than those of 1- or 3-month-old mice. The mean minor axes of the glomeruli of 24-month-old mice on the 4th day of VCM treatment were significantly larger

than those of 1-, 3-, 6-, and 12-month-old mice, and those of 6- and 12-month-old mice on the 4th day of VCM treatment were significantly larger than those of 1- or 3-month-old mice. Moreover, the mean minor axes of the glomeruli of 12-month-old mice on the 15th day of VCM treatment were significantly larger than those of 1-, 3-, or 6-month-old mice, and those of 1-, 3-, 6-, and 12-month-old mice on the 15th day were significantly smaller than those of the same age groups on the initial day of treatment. Additionally, the mean minor axes of the renal tubules of 3- and 6-month-old mice on the 15th day were significantly smaller than those of the same age groups on the 4th day of VCM treatment. Finally, the mean minor axes of the glomeruli of 1-month-old mice on the 4th day were significantly smaller than those

of the same age group on the 1st day.

The numbers of casts in the renal tubules are shown in Fig. 4C. Significantly greater numbers of casts were observed in the renal tubules of 12- and 24-month-old mice on the 4th day of VCM treatment than in 1- or 3-month-old mice. The numbers of casts in the renal tubules of 6- and 12-month-old mice were significantly greater on the 15th day of VCM treatment than in 1- or 3-month-old mice. Although the renal tubules of control mice aged 1, 3, 6, or 12 months did not display detectable casts, renal casts were observed in control mice at the age of 24 months. The numbers of casts in the renal tubules of 1-, 3-, 6-, and 12-month-old mice on the 15th day of VCM treatment were significantly increased by 4.3-, 2.8-, 2.3-, and 2.2-fold, respectively, compared with the same age groups on the 4th day of VCM treatment. The numbers of casts in the renal tubules of 24-month-old mice on the 4th day of VCM treatment were significantly increased by 6.5-fold compared with the same age group on the 1st day.

The numbers of tubules exhibiting epithelial desquamation are shown in Fig. 4D. Tubules manifesting epithelial desquamation were observed in control mice at the age of 24 months; however, control mice at the ages of 1, 3, 6, and 12 months did not display detectable tubular epithelial desquamation. The number of tubules exhibiting epithelial desquamation in 24-month-old mice on the 4th day of VCM treatment was significantly increased by 3.6-fold compared with 1-month-old mice, and those in 3-, 6-, and 12-month-old mice on the 15th day of VCM treatment were significantly increased by 1.8-, 1.9-, and 2.3-fold, respectively, compared with 1-month-old mice. Although the renal tubules of control mice did not display detectable casts at 1, 3, 6, or 12 months, renal casts appeared in control mice at the age of 24 months. The numbers of tubules with epithelial desquamation in 1-, 3-, 6-, and 12-month-old mice were significantly increased by 2.9-, 1.9-, 2.1-, and 2.6-fold, respectively, on the 15th day of VCM treatment compared with the 4th day of VCM treatment, and that in 24-month-old mice was significantly increased by 2.4-fold on the 4th day of VCM treatment compared with the 1st day.

Azan staining showed interstitial fibrosis in the kidneys, and the percentage of interstitial fibrosis area in VCM-treated mice on day 15 gradually increased with advancing age, but the change was not significant (Fig. 4E). The percentage of interstitial fibrosis area in 6- and 12-month-old mice was significantly increased by 3.5- and 3.6-fold, respectively, on the 15th day of VCM treatment compared with the 1st day, and that in 6-month-old mice was significantly increased by 2.6-fold on the 15th day of VCM treatment compared with the 4th day.

Immunohistochemical staining for CD10 in the kidneys of VCM-treated mice

Immunohistochemistry revealed dilation of the renal proximal tubules on the 4th and 15th days of VCM treatment (Fig. 5A, white arrowhead). Although control mice aged 1, 3, 6, and 12 months did not exhibit any detectable CD10-

positive dilated proximal tubules, 24-month-old control mice did exhibit this change (Fig. 5A and B). The numbers of CD10-positive dilated proximal tubules recorded in 24-month-old mice on the 4th day of VCM treatment were 3.8-, 2.8-, and 3.7-fold greater than the numbers in 1-, 3-, and 6-month-old mice, respectively (Fig. 5B), and those in 12-month-old mice on the 15th day of VCM treatment were significantly increased by 3.0-, 2.0-, and 2.0-fold compared with the numbers in 1-, 3-, and 6-month-old mice, respectively (Fig. 5B). Finally, the number of CD10-positive dilated proximal tubules in 6-month-old mice was significantly increased by 1.8-fold on the 15th day of VCM treatment compared with the 4th day, and that in 24-month-old mice was significantly increased by 15.8-fold on the 4th day of VCM treatment compared with the 1st day.

Detection of apoptotic cells in the kidneys of VCM-treated mice

Immunohistochemically, numerous ssDNA-positive apoptotic cells or bodies were present in renal tubules on the 4th and 15th days of VCM treatment, gradually worsening with aging (Fig. 6A). Control mice aged 1, 3, 6, 12, and 24 months did not display detectable ssDNA-positive apoptotic cells or bodies (Fig. 6A and B). The percentages of ssDNA-positive areas in 24-month-old mice recorded on the 4th day of VCM treatment were significantly increased by 4.9- and 3.3-fold compared with the percentages in 1- and 3-month-old mice, respectively (Fig. 6B). Those in 3-, 6-, and 12-month-old mice were significantly increased by 1.9-, 2.7-, and 2.4-fold, respectively, on the 15th day of VCM treatment compared with the percentages in 1-month-old mice (Fig. 6B). The percentages of ssDNA-positive areas in 1-, 3-, 6-, and 12-month-old mice were significantly increased by 3.2-, 4.0-, 4.7-, and 3.8-fold, respectively, on the 15th day of VCM treatment compared with the same age groups on the 4th day of VCM treatment.

Discussion

In the present study, we observed indisputable evidence of renal damage induced by the VCM treatment in mice of different ages. Interestingly, this pathological and biochemical deterioration was confirmed in young mice and substantially progressed with aging. These results closely resembled findings from clinical and pathological human studies¹⁵.

Mortality among 12- and 24-month-old mice was 20% and 80%, respectively, when VCM was administered for 14 days. On the other hand, mortality was 0% among 1-, 3-, and 6-month-old mice. Since the median lifespan of male C57BL/6J mice is approximately 27 months, according to the Jackson Laboratory¹⁶, the cause of death in the 12- and 24-month-old mice was presumably the VCM treatment. Thus, with aging, mice became more likely to die of VCM-induced renal failure. This report is the first to investigate the survival of aging mice during VCM treatment.

The administration of VCM to mice for 15 days de-

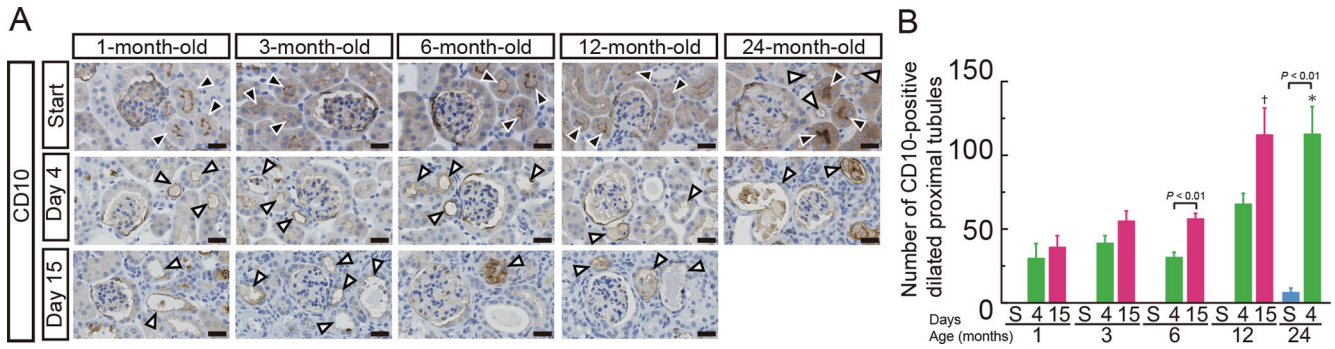


Fig. 5. CD10-positive dilated proximal tubules in kidneys from VCM-treated mice. (A) Kidney sections were stained with an anti-CD10 antibody. Black arrowheads indicate normal proximal tubules. White arrowheads indicate dilated proximal tubules. Bars, 25 μ m. (B) The number of CD10-positive dilated proximal tubules was evaluated as described in the Materials and Methods section. First day, 1 and 3 months old ($n=10$ mice) and 6, 12, and 24 months old ($n=9$ mice); 4th day, 1, 3, and 6 months old ($n=10$ mice), 12 months old ($n=9$ mice), and 24 months old ($n=8$ mice); 15th day, 1, 3 and 6 months old ($n=10$ mice) and 12 months old ($n=8$ mice). Values are presented as the means \pm SEM of eight to ten animals. Statistical analyses were performed using one-way ANOVA followed by post hoc unpaired t-tests with the Bonferroni correction. Differences between age groups were considered significant at $P<0.01$. * $P<0.01$ compared with 1-, 3-, and 6-month-old mice on the 4th day of VCM treatment. † $P<0.01$ compared with 1-, 3-, and 6-month-old mice on the 15th day of VCM treatment.

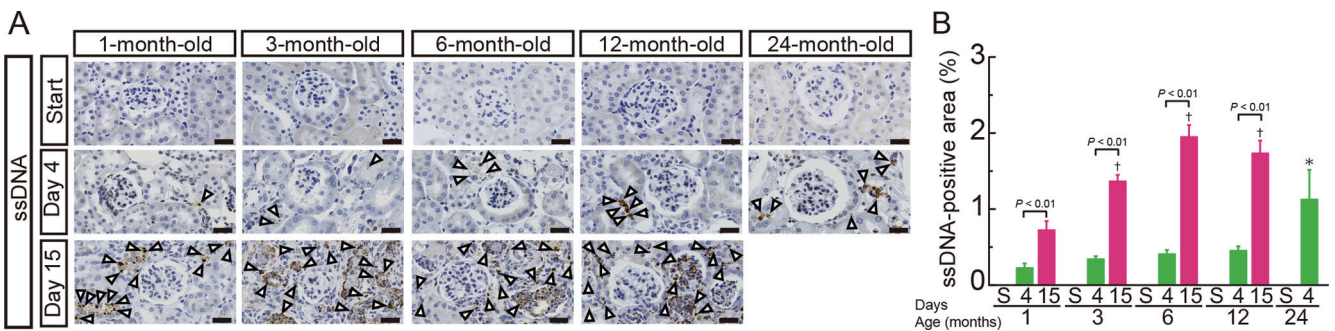


Fig. 6. Detection of apoptotic cells in kidneys of VCM-treated mice. (A) Kidney sections were stained with an anti-single-stranded DNA antibody. White arrowheads indicate apoptotic tubular epithelial cells. Bars, 25 μ m. ssDNA, single-stranded DNA. (B) The percentage of the ssDNA-positive area was evaluated as described in the Materials and Methods section. First day, 1 and 3 months old ($n=10$ mice) and 6, 12, and 24 months old ($n=9$ mice); 4th day, 1, 3, and 6 months old ($n=10$ mice), 12 months old ($n=9$ mice), and 24 months old ($n=8$ mice); 15th day, 1, 3 and 6 months old ($n=10$ mice) and 12 months old ($n=8$ mice). Values are presented as the means \pm SEM of eight to ten animals. Statistical analyses were performed using one-way ANOVA followed by post hoc unpaired t-tests with the Bonferroni correction. Differences between age groups were considered significant at $P<0.01$. * $P<0.01$ compared with 1- and 3-month-old mice on the 4th day of VCM treatment. † $P<0.01$ compared with 1-month-old mice on the 15th day of VCM treatment.

creased the body weight and, conversely, increased the kidney weight. The mean body weights of 1-, 3-, 6-, and 12-month-old mice were 8, 10, 20, and 26% lower, respectively, after 15 days of VCM treatment than on the 1st day. Moreover, the mean kidney weights of 1-, 3-, 6-, and 12-month-old mice were 1.2-, 1.2-, 1.5- and 1.8-fold higher, respectively, after 15 days of VCM treatment than on the 1st day. The body weight losses of 1- and 3-month-old mice were small, but as age increased, the losses became noticeable. Additionally, slight increases in the kidney weights were observed 1- and 3-month-old mice, but as the animals aged, the increase in the kidney weight became noticeable. The cause of body weight loss was considered renal failure, and the increase in the kidney weight evidently resulted

from renal damage and interstitial fibrosis. Moreover, the P-Cre level was increased by the VCM treatment, and this effect was remarkably exacerbated with aging. Previously, we examined the time-dependent alterations in kidney damage due to VCM administration and confirmed that body weight decreases and kidney lesions worsened as kidney damage progressed⁷. Therefore, aged mice were considered highly susceptible to renal damage caused by the VCM treatment, resulting in body weight loss and kidney lesions.

In the present study, significantly higher P-Cre levels were observed in 24-month-old mice on the 1st day than in 1-, 3-, 6-, or 12-month-old mice. Moreover, casts and tubular epithelial desquamation were observed in the kidneys of 24-month-old mice on the 1st day, although these signs

were not detectable in mice aged 1, 3, 6, or 12 months. Thus, 24-month-old mice may have an underlying renal impairment because of aging. In fact, mice develop renal damage with age, and spontaneous renal damage is the main cause of death in mice^{17, 18}. In the present study, 24-month-old mice showed severe kidney damage due to the VCM treatment, as described above, and these changes were distinct from age-related renal damage. Therefore, 24-month-old mice had worse kidney damage following the VCM treatment than 1-, 3-, 6-, or 12-month-old mice, which may have led to the high mortality rate.

Histologically, renal tubular degeneration gradually increased in severity with aging. In humans, many reports have described similar episodes of renal failure after VCM treatment in the elderly^{12, 15}. Therefore, our results in mice were analogous to renal failure in humans. Moreover, immunohistochemical staining using an anti-CD10 antibody, which is known to be a specific indicator of proximal tubules in humans¹³, revealed that the renal proximal tubules were markedly dilated and that this condition was exacerbated with aging. Based on these results, the brush-border exhibited atrophy in response to the VCM treatment. Furthermore, immunohistochemical staining for ssDNA revealed apoptotic cells that were presumably derived from epithelial cells in dilated proximal tubules, and the number of apoptotic cells gradually increased with aging. Thus, proximal tubular epithelial cells likely undergo apoptosis in response to VCM administration.

In aged mice, the nephrotoxic effects of VCM may become more severe the longer the drug is administered. For instance, the P-Cre levels in 1-month-old mice were 1.9- and 3.4-fold higher after 4 and 15 days of VCM treatment, respectively, than on the 1st day. On the other hand, the P-Cre levels in 12-month-old mice were 6.2- and 25.8-fold higher after 4 and 15 days of VCM treatment, respectively, than on the 1st day. Additionally, similar trends were observed for the body weight, kidney weight, and histological features.

Elderly patients with impaired renal function have been reported to be at risk for VCM-induced nephrotoxicity¹⁰. Although the precise mechanism of VCM-induced nephrotoxicity remains unclear, an elevation of oxidative stress induced by VCM administration may be one of the triggers of renal damage. According to Arimura *et al.*¹⁹, VCM increases intracellular reactive oxygen species (ROS) production by inactivating mitochondrial complex I in cultured LLC-PK1 cells. Additionally, as shown in the study by Sakamoto *et al.*²⁰, cardiolipin peroxidation mediates VCM-induced intracellular ROS production and initiates apoptosis in proximal epithelial cells. Therefore, we postulate that the proximal renal tubular epithelial cells of aged mice must be particularly susceptible to increased oxidative stress, but further studies are needed to confirm this hypothesis.

One limitation of the present study is that we were unable to evaluate the VCM concentration in the blood of the mice. Therefore, we were not able to exclude the possibility that the blood concentration varied with aging. Further studies are needed to clarify this point.

In conclusion, aged mice are likely highly susceptible to kidney damage induced by VCM treatment. Moreover, VCM treatment is likely to induce the apoptosis of proximal tubular epithelial cells. This report is the first to document VCM-induced renal failure in mice of different ages ranging from 1 to 24 months. This mouse model could be useful for understanding the mechanisms of VCM-induced nephrotoxicity in the elderly.

Disclosure of Potential Conflicts of Interest: The authors have no conflicts of interest to declare.

Acknowledgments: This study was supported by the Japan Society for the Promotion of Science (JSPS) through KAKENHI Grant Numbers 15H04505 and 15K15104 (Ishigami A).

References

1. Rodvold KA, Everett JA, Pryka RD, and Kraus DM. Pharmacokinetics and administration regimens of vancomycin in neonates, infants and children. *Clin Pharmacokinet.* **33**: 32–51. 1997.
2. Wood CA, Kohlhepp SJ, Kohnen PW, Houghton DC, and Gilbert DN. Vancomycin enhancement of experimental tobramycin nephrotoxicity. *Antimicrob Agents Chemother.* **30**: 20–24. 1986.
3. Levine DP. Vancomycin: a history. *Clin Infect Dis.* **42**(Suppl 1): S5–S12. 2006.
4. Davies SW, Efird JT, Guidry CA, Dietch ZC, Willis RN, Shah PM, Hennessy SA, and Sawyer RG. Vancomycin-Associated Nephrotoxicity: The Obesity Factor. *Surg Infect (Larchmt).* **16**: 684–693. 2015.
5. Wood MJ. The comparative efficacy and safety of teicoplanin and vancomycin. *J Antimicrob Chemother.* **37**: 209–222. 1996.
6. Iwamoto T, Kagawa Y, and Kojima M. Clinical efficacy of therapeutic drug monitoring in patients receiving vancomycin. *Biol Pharm Bull.* **26**: 876–879. 2003.
7. Takigawa M, Masutomi H, Kishimoto Y, Shimazaki Y, Hamano Y, Kondo Y, Arai T, Lee J, Ishii T, Mori Y, and Ishigami A. Time-Dependent Alterations of Vancomycin-Induced Nephrotoxicity in Mice. *Biol Pharm Bull.* **40**: 975–983. 2017.
8. Bailie GR, and Neal D. Vancomycin ototoxicity and nephrotoxicity. A review. *Med Toxicol Adverse Drug Exp.* **3**: 376–386. 1988.
9. Pauly DJ, Musa DM, Lestico MR, Lindstrom MJ, and Hetsko CM. Risk of nephrotoxicity with combination vancomycin-aminoglycoside antibiotic therapy. *Pharmacotherapy.* **10**: 378–382. 1990.
10. Elyasi S, Khalili H, Dashti-Khavidaki S, and Mohammadpour A. Vancomycin-induced nephrotoxicity: mechanism, incidence, risk factors and special populations. A literature review. *Eur J Clin Pharmacol.* **68**: 1243–1255. 2012.
11. Mizokami F, Shibasaki M, Yoshizue Y, Noro T, Mizuno T, and Furuta K. Pharmacodynamics of vancomycin in elderly patients aged 75 years or older with methicillin-resistant *Staphylococcus aureus* hospital-acquired pneumonia. *Clin Interv Aging.* **8**: 1015–1021. 2013.

12. Sokol H, Vigneau C, Maury E, Guidet B, and Offenstadt G. Biopsy-proven anuric acute tubular necrosis associated with vancomycin and one dose of aminoside. *Nephrol Dial Transplant*. **19**: 1921–1922. 2004.
13. Shen SS, Truong LD, Scarpelli M, and Lopez-Beltran A. Role of immunohistochemistry in diagnosing renal neoplasms: when is it really useful? *Arch Pathol Lab Med*. **136**: 410–417. 2012.
14. Naruse I, Keino H, and Kawarada Y. Antibody against single-stranded DNA detects both programmed cell death and drug-induced apoptosis. *Histochemistry*. **101**: 73–78. 1994.
15. Htike NL, Santoro J, Gilbert B, Elfenbein IB, and Teehan G. Biopsy-proven vancomycin-associated interstitial nephritis and acute tubular necrosis. *Clin Exp Nephrol*. **16**: 320–324. 2012.
16. C57BL/6J Survival plot (The Jackson Laboratory), from charles river website: https://www.crj.co.jp/cms/pdf/info_common/17/6033572/B6J_Survival_plot_JAX.pdf
17. Frazier KS, Seely JC, Hard GC, Betton G, Burnett R, Nakatsuji S, Nishikawa A, Durchfeld-Meyer B, and Bube A. Proliferative and nonproliferative lesions of the rat and mouse urinary system. *Toxicol Pathol*. **40**(Suppl): 14S–86S. 2012.
18. Seely JC. Kidney. In: *Pathology of the mouse: Reference and atlas*, Maronpot RR ed., Cache River Press, 1999.
19. Arimura Y, Yano T, Hirano M, Sakamoto Y, Egashira N, and Oishi R. Mitochondrial superoxide production contributes to vancomycin-induced renal tubular cell apoptosis. *Free Radic Biol Med*. **52**: 1865–1873. 2012.
20. Sakamoto Y, Yano T, Hanada Y, Takeshita A, Inagaki F, Masuda S, Matsunaga N, Koyanagi S, and Ohdo S. Vancomycin induces reactive oxygen species-dependent apoptosis via mitochondrial cardiolipin peroxidation in renal tubular epithelial cells. *Eur J Pharmacol*. **800**: 48–56. 2017.