

## C A S E R E P O R T

# Isolated fronto-ethmoidal allergic fungal rhinosinusitis: case report and review of the literature

Gabriele Oretti<sup>1</sup>, Giuseppe Castellana<sup>1</sup>, Roberta Manuguerra<sup>2</sup>, Enrico Maria Silini<sup>2</sup>, Teore Ferri<sup>1</sup>

<sup>1</sup>Department of Otorhinolaryngology, Azienda Ospedaliera Parma, University of Parma, Parma, Italy; <sup>2</sup>Department of Pathology, Azienda Ospedaliera Parma, University of Parma, Parma, Italy

**Summary.** *Background and aim of the work:* Fungal rhinosinusitis (FRS) is a clinical entity characterized by the presence of fungi within sino-nasal cavities that may occur in patients with normal or defective immunity. Allergic fungal rhinosinusitis (AFRS) is a form of non-invasive FRS that affects patients with an abnormal immuno-mediated response to fungal antigens. This article describes a case of isolated fronto-ethmoidal AFRS. *Methods:* A 20-year old male patient presented with a history of a left nasal respiratory obstruction and allergic oculorhinitis. CT scans showed a polypoid mass in the left nasal cavity and opacification of the left ethmoid sinus, frontal recess and frontal sinus with hyperdense component. The patient underwent functional endonasal sinus surgery (FESS) with removal of nasal polyps from the left nasal cavity and of cheesy-like material and dense mucus from the left ethmoid and frontal sinus. Histological examination showed presence of fungal hyphae within the allergic mucus; a diagnosis of AFRS was made. *Results:* Follow up at 14 months showed no signs of recurrence. *Conclusions:* The AFRS case reported herein is characterized by isolated unilateral fronto-ethmoid involvement, a rare presentation. Endoscopic nasal treatment was effective with complete patient recovery. ([www.actabiomedica.it](http://www.actabiomedica.it))

**Key words:** ethmoid, frontal, fungal, rhinosinusitis, allergic, sinus

## Introduction

Chronic rhinosinusitis (CRS) is a common inflammatory condition of the mucosa of the nasal and paranasal cavities affecting even up to 13% of the population (1). Fungal rhinosinusitis (FRS) is part of the spectrum of CRS. Over the years, mycotic infections of the nose and paranasal sinuses have been more clearly defined, although some features concerning its physiopathology, diagnosis and management remain challenging.

Sinus mycosis can occur in individuals with normal immune system as well in patients with immunodeficiency. Deficiency of protective mechanisms, such as mucosal properties, cellular and humoral immunity, and bacterial antagonism are central for FRS development (1).

Allergic fungal rhinosinusitis (AFRS) is a non-invasive form of FRS with a prevalence of 6-9% (2). Typically, AFRS is unilateral and involves multiple paranasal sinuses. The ethmoid sinus is the most frequent localization and it's rarely involved alone; the frontal sinus is very rarely affected (3). We describe a rare case of AFRS in a young man involving only the ethmoid and frontal sinuses.

## Case report

We report a case of a 20 year-old male patient with a history of left nasal respiratory obstruction and allergic oculorhinitis. He had positive Prick tests for *Dermatophagoides spp.*, *graminaceae*, *Parietaria*, *Alter-*

*naria (molds)* and *cat epithelium*. Pre-operative evaluation showed signs of rhinitis and left deviation of nasal septum. The eosinophils blood count was normal.

Pre-operative CT scan showed a polypoid mass in left nasal cavity, opacification of the left ethmoid sinus with a hyperdense component, obliteration of the left ostio-meatal complex, opacification of the left frontal recess and of the correspondent sinus and a right concha bullosa (figure 1). A diagnosis of chronic rhinosinusitis with fungal infection was suggested. Surgical treatment was proposed to the patient.

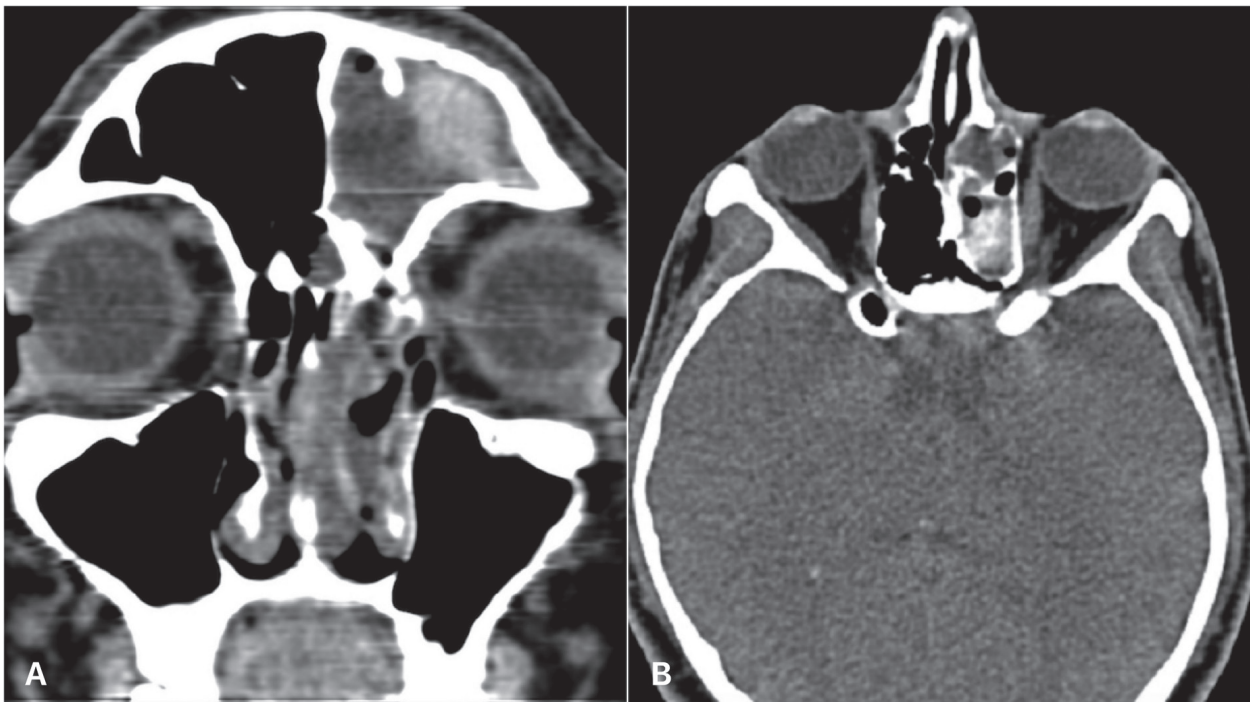
The patient underwent functional endonasal sinus surgery (FESS), frontal and ethmoid sinus mucus removal and Draf IIA on the left side. Intra-operatively dense mucus of the frontal sinus and cheesy-like material from the ethmoid sinus were removed and sent for histopathological examination (figure 2). Maxillary sinus was found empty with no pathological findings.

Histological examination showed fungal septate dichotome hyphae consistent with species of *Aspergillus*, allergic mucus and polypoid inflammatory hyperplasia of the sino-nasal mucosa (figure 3). These find-

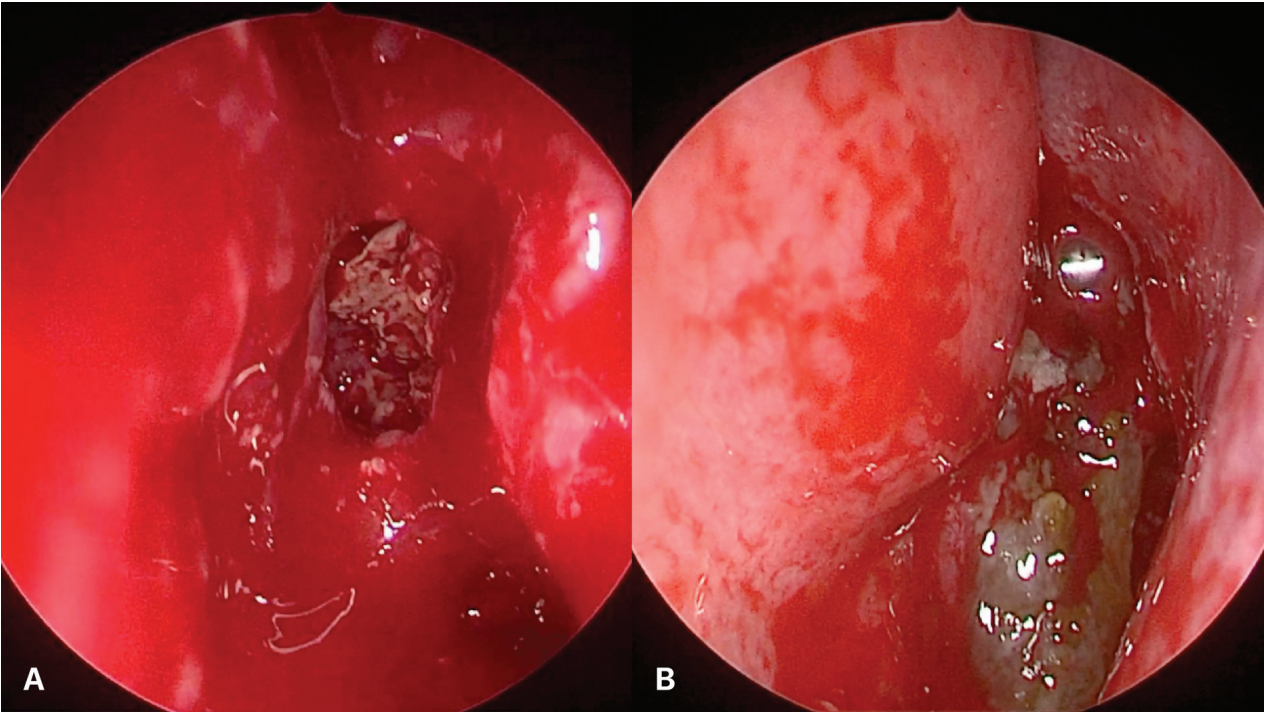
ings are consistent with a diagnosis of AFRS. Follow up at 14 months showed no signs of recurrence.

## Discussion

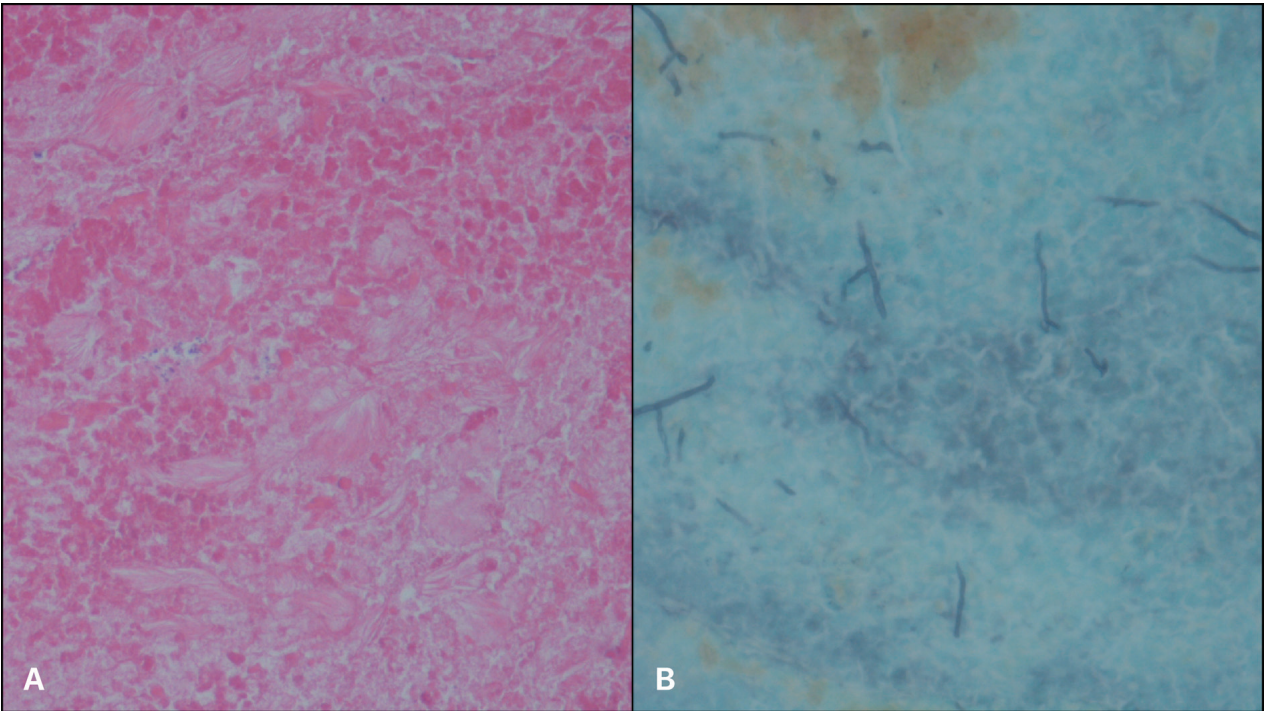
Fungal spores, due to their ubiquitous nature, are continuously inhaled and deposited in the airway mucosa. Fungi are normal pathobionts of the mammalian respiratory tract that, under conditions of abnormal immune response, may cause overt disease. CRS can progress from a local to a systemic allergic reaction; the prevalence of AFRS and FRS is 1,3% and 2,8% respectively in CRS patients (2). Fungal sinusitis results from interaction of different factors, such as the integrity of upper airways mucosa, the expression of antimicrobial proteins on the ciliated epithelium and the host's immune response (4). A protective role of Th17 cells and IL-17A in defense against fungal infections has been implicated (5). Environmental conditions, such as high air concentration of fungal spores at certain workplaces (farmers, gardeners, carpenters)



**Figure 1.** Pre-operative CT scan shows left nasal polyps and opacification of the left frontal and ethmoid sinus (a, coronal image) with hyperdense component in the ethmoid sinus (b, axial image)



**Figure 2.** Endoscopic findings: inflammatory mucus within the frontal sinus (a); allergic mucus within the ethmoid sinus (b)



**Figure 3.** Histologic examination showed necro-inflammatory material (a, Haematoxylin-eosin staining; original magnification, x20) with fungal hyphae (b, Grocott's metamyne silver stain; original magnification, x40).

**Table 1.** Previous studies on CT findings in AFRS (PE=posterior ethmoid; AE=anterior ethmoid; NR=not reported; E=ethmoid)

Author, year	Patients number (age range)	Ethmoid sinus involvement (%)	Maxillary sinus involvement (%)	Sphenoid sinus involvement (%)	Frontal sinus involvement (%)	Isolated involvement of ethmoid, frontal sinus or both	Isolated species
Samir et al, 1996	14 (9-50 y)	11 (79%)	9 (64%)	8 (57%)	6 (43%)	0	<i>Aspergillus fumigatus</i> 57% <i>Aspergillus flavus</i> 14%
Torres et al, 1996	16 (8-71 y)	16 (100%)	13 (81%)	13 (81%)	5 (31%)	0	<i>Exserohilum</i> 19% <i>Bipolaris</i> sp. 6% <i>Curvularia</i> 6% <i>Drechslera</i> 6%
Mannign et al, 1997	10 (13-57 y)	9 (90%)	4 (40%)	6 (60%)	5 (50%)	1 isolated PE involvement (10%)	<i>Bipolaris</i> sp. 40% <i>Exserohilum</i> sp. 20% <i>Curvularia</i> sp. 10% No growth 20%
Mukherji et al, 1998	45 (8-68 y)	43 (96%)	42 (93%)	30 (67%)	32 (71%)	1 isolated E involvement (2%)	NR
Nussebaum et al, 2001	28* (NR)	24 (86%)	2 (7%)	22 (79%)	8 (29%)	NR	<i>Bipolaris</i> sp. 57% <i>Curvularia</i> 14% No growth 18% Others 11%
Aribandi et al, 2007	7 (8-67 y)	6 PE (86%) 5 AE (71%)	3 (43%)	6 (86%)	4 (57%)	NR	<i>Bipolaris</i> sp. 100%
Wise et al, 2009	111	77%	68%	58%	53%	NR	NR
Verma et al, 2016	100	AE 92 (92%) PE 84 (84%)	76 (76%)	67 (67%)	65 (65%)	NR	<i>Aspergillus flavus</i> 64%

or in humid and poorly ventilated rooms may also predispose to fungal sinusitis (6-9). Climatic factors, such as temperature and humidity, may explain differences in the prevalence of mycoses in different geographic areas.

There are five forms of fungal disease that affect the nose and the paranasal sinuses: acute invasive FRS (including rhinocerebral mucormycosis), chronic invasive RHA, invasive granulomatous FRS, mycetoma (fungus ball) and non-invasive AFRS (4).

AFRS is a disease of young adults, with an average age of 26 years at time of diagnosis (10). It is often associated with nasal polyps (NP), IgE-mediated hypersensitivity, and allergic mucin (2, 11). Since the early 90's, several studies have described the CT findings in AFRS that are characterized by multiple sinus involvement or pansinusitis in the majority of the cases. Ethmoid sinus is the most frequently involved site, followed by the maxillary, sphenoid and frontal sinuses. Although AFRS is a predominately unilateral disease, isolated involvement of the frontal and ethmoid sinus represents a rare finding in literature.

In 1996, Samir and Torres (12, 13) described the CT findings in 30 AFRS cases; none of them had isolated involvement of frontal and ethmoid sinus. In 1997, Manning et al. (14) reported 10 cases of AFRS, including one case of isolated ethmoid involvement. A series of 45 cases was reported by Mukherji et al. (15) with only one case of isolated ethmoid involvement. Gupta et al. (3) reported 12 cases of isolated AFRS of the frontal sinus. Other authors (16-19) reported frequencies of involvement of the ethmoid (71-92%), maxillary (7-76%), sphenoid (58-86%) and frontal sinus (29-65%) in AFRS, but no cases of isolated fronto-ethmoid involvement were described. Different species have been identified by cultures; the most frequent are *Aspergillus* species followed by *Bipolaris*, *Exserohilum* and *Curvularia* species. The previous studies are summarized in Table 1.

The AFRS case reported herein is characterized by isolated unilateral fronto-ethmoid involvement, a rare presentation. Endoscopic nasal treatment was effective with total removal of allergic mucin and inflammatory material within the sinuses and complete patient recovery.

**Conflict of interest:** Each author declares that he or she has no commercial associations (e.g. consultancies, stock ownership, equity interest, patent/licensing arrangement etc.) that might pose a conflict of interest in connection with the submitted article

## References

1. Twarużek, Magdalena, et al. The occurrence of molds in patients with chronic sinusitis. *European archives of otorhino-laryngology* 271.5 (2014): 1143-1148.
2. Barac, Aleksandra, et al. Study toward resolving the controversy over the definition of allergic fungal rhinosinusitis. *Medical Mycology* (2017): myx032.
3. Gupta R, Gupta AK. Isolated primary frontal sinus aspergillosis: role of endonasal endoscopic approach. *J Laryngol Otol* 2013; 127: 274-278.
4. Fokkens WJ, Ebbens F, van Drunen CM. Fungus: a role in pathophysiology of chronic rhinosinusitis, disease modifier, a treatment target, or no role at all? *Immunol Allergy Clin N Am* 2009; 29: 677-88.
5. Acosta-Rodriguez EV, Rivino L, Geginat J, et al. Surface phenotype and antigenic specificity of human interleukin 17-producing T helper memory cells. *Nat Immunol* 2007; 8(6): 639-46.
6. Morawska A, Hydzik-Sobocińska K, Wiatr M, Składzień J, Pradel U. Fungal infections with otorhinological diseases patients. *Otorhinolaryngologia* 2007; 6(3): 142-146.
7. Dynowska M, Góralska K, Roslan M. Contribution of yeast-like fungi in hospital infections. *Mikol Lek* 2008; 15(3): 151-154.
8. Daghistani KJ, Jamal TS, Zaher S, Nassif OI. Allergic aspergillus sinusitis with proptosis. *J Laryngol Otol* 1992; 106(9): 799-803.
9. Zukiewicz-Sobczak WA. The role of fungi in allergic diseases. *Postep Derm Alergol* 2013; 30(1): 42-45.
10. Younis RT, Ahmed J. Predicting revision sinus surgery in allergic fungal and eosinophilic mucin chronic rhinosinusitis. *The Laryngoscope* 2017; 127(1): 59-63.
11. Arunalohe, Chakrabarti, et al. Fungal Rhinosinusitis: A Categorization and Definitional Schema Addressing Current Controversies. *QNRS Repository* 2011.1 (2011): 3063.
12. Samir M, Masoud AR. Sinus aspergillosis and allergic fungal sinusitis. *Annals of Saudi medicine* 1996; 16(4): 395-399.
13. Torres C, Ro JY, El-Naggar AK, Sim SJ, Weber RS, Ayala AG. Allergic fungal sinusitis: a clinicopathologic study of 16 cases. *Human pathology* 1996; 27(8): 793-799.
14. Manning SC, Merkel M, Kriesel K, Vuitch F, Marple B. Computed tomography and magnetic resonance diagnosis of allergic fungal sinusitis. *The Laryngoscope* 1997; 107(2): 170-176.
15. Mukherji SK, Figueroa RE, Ginsberg LE, Zeifer BA, Marple BF, Alley JG, Kupferberg SB. Allergic fungal sinusitis: CT findings. *Radiology* 1998; 207(2): 417-422.
16. Nussenbaum B, Marple BF, Schwade ND. Characteristics of bony erosion in allergic fungal rhinosinusitis. *Otolaryngology - Head and Neck Surgery* 2001; 124(2): 150-154.
17. Aribandi M, Bazan C. CT and MRI features in Bipolaris fungal sinusitis. *Journal of Medical Imaging and Radiation Oncology* 2007; 51(2): 127-132.
18. Wise SK, Rogers GA, Ghegan MD, Harvey RJ, Del Gaudio JM, Schlosser RJ. Radiologic staging system for allergic fungal rhinosinusitis (AFRS). *Otolaryngology – Head and Neck Surgery* 2009; 140(5): 735-740.
19. Verma RK, Patro SK, Francis AA, Panda NK, Chakrabarti A, Singh P. Role of preoperative versus postoperative itraconazole in allergic fungal rhinosinusitis. *Medical mycology* 2016; 55(6): 614-62.

Received: 10 November 2018

Accepted: 9 January 2019

Correspondence:

Dr. Giuseppe Castellana

Department of Otorhinolaryngology,

Azienda Ospedaliera Parma, University of Parma,

Via Gramsci 14 - Parma (PR)

Tel. +39 0521703542

E-mail: giuseppecas8@gmail.com