



Contents lists available at ScienceDirect

International Journal of Surgery Case Reports

journal homepage: www.casereports.com

Forgotten goiter: Diagnosis and management. A case report and literature review



Kunal M. Patel (MD), Chase C. Parsons (MD)*

Florida International University Herbert Wertheim College of Medicine, American University of Antigua College of Medicine, United States

ARTICLE INFO

Article history:

Received 16 May 2016

Received in revised form 24 August 2016

Accepted 24 August 2016

Available online 5 September 2016

Keywords:

Mediastinal mass

Substernal goiter, "Forgotten goiter"

Goiter

Total thyroidectomy

ABSTRACT

INTRODUCTION: A mediastinal thyroid mass discovered years after a total thyroidectomy represents an unusual and uncommon clinical situation. Few cases have been reported and controversy exists regarding the etiology of this ectopic thyroid tissue as well as the optimal surgical approach for resection. We herein describe a case of a mediastinal thyroid goiter discovered five years after a total thyroidectomy.

PRESENTATION OF CASE: A 54-year-old Hispanic female was diagnosed with a diffuse cervical goiter secondary to Hashimoto's Thyroiditis and subsequently underwent a total thyroidectomy. Five years later the patient had a chest X-ray as part of a preoperative evaluation for an unrelated and elective surgical procedure. Significant tracheal deviation was identified. A computed tomography scan was obtained and demonstrated a well encapsulated mass in the superior mediastinum resulting in tracheal deviation and compression. This "forgotten" goiter was successfully resected utilizing a standard cervical approach and the patient recovered uneventfully.

DISCUSSION: A thyroid mass within the mediastinum following a total thyroidectomy is a condition often referred to as "forgotten goiter". Prior reported cases are few, and data is limited, with some uncertainty remaining as to the exact origin of this ectopic thyroid tissue. Possible etiologies include an incomplete removal of the thyroid gland during initial cervical thyroidectomy, or perhaps an autonomous intrathoracic goiter (AIG) – a thyroid gland located in the mediastinum, independent and with no parenchymatous or vascular connection with the cervical thyroid gland.

CONCLUSION: A trans-thoracic or sternal splitting approach is generally not required for resection of a mediastinal goiter and our experience confirms that the case of the "forgotten goiter" can be safely approached through a cervical incision as well.

© 2016 The Author(s). Published by Elsevier Ltd on behalf of IJS Publishing Group Ltd. This is an open access article under the CC BY-NC-ND license (<http://creativecommons.org/licenses/by-nc-nd/4.0/>).

1. Introduction

In 1992 Massard et al. reported 7 cases of mediastinal thyroid tissue discovered after total cervical thyroidectomy and described these findings as "goiter oublié" or the "forgotten goiter" [1]. The forgotten goiter lacks any visible connection to the cervical portion of the thyroid gland and may represent remnants of an incompletely resected cervical goiter or perhaps the result of completely separate and autonomously functioning thyroid tissue that becomes hypertrophic following removal of the cervical thyroid. Review of the published data suggests a latency period ranging from 1 to 39 years following cervical thyroidectomy. Patients may become symptomatic either from hormonally active thyroid tissue within the mediastinum or from mass effect causing tracheal compression and deviation. More commonly however the mediastinal

goiter is clinically silent and presents only with asymptomatic tracheal deviation as an incidental finding. Since Massard's initial description of the "forgotten goiter" there have been very few additional reported cases in the literature and no clear consensus as to the optimal approach for resection.

2. Presentation of case

A 54-year-old Hispanic female with a past medical history of Hashimoto's Thyroiditis was referred for a total thyroidectomy five years prior to our encounter. During the initial thyroidectomy, the surgeon noted the left side of the thyroid gland to be unusually large and partially intrathoracic.

The entire thyroid gland was reported to have been removed and sent to pathology where it weighed 95 g, measured 9.8 × 6 × 4 cm, and had a multinodular appearance consistent with the diagnosis of Hashimoto's Thyroiditis.

Five years later the patient had a chest X-ray as part of a preoperative evaluation for an unrelated and elective surgical procedure and was found to have significant deviation of the mediastinal tra-

* Corresponding author at: 2117 Sturbridge Court, Winter Springs, FL 32708, United States.

E-mail addresses: Kunalpa@auamed.net (K.M. Patel), chasep@auamed.net, cpars008@fiu.edu (C.C. Parsons).

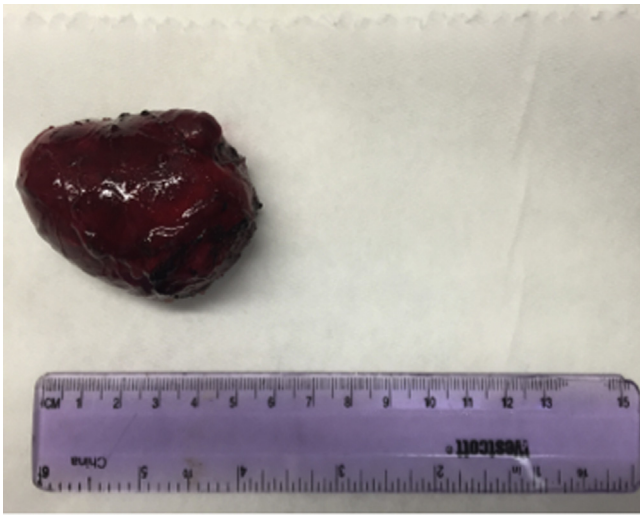

Fig. 1. Gross specimen showing well encapsulated mass measuring 5.0 × 4.0 × 3.3 cm and weighing 43.6 g.

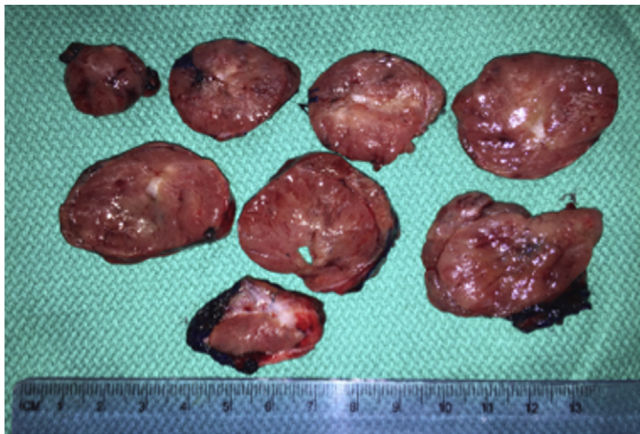


Fig. 2. Cut section showing a benign ectopic thyroid with nodular hyperplasia.

chea. A computed tomography scan (CT scan) was obtained which demonstrated a well circumscribed 6.4 × 3.2 cm superior mediastinal mass on the left side, causing rightward deviation of the trachea suggestive for a mediastinal goiter. The patient was completely asymptomatic and there was no palpable cervical thyroid on examination. The patient subsequently underwent resection for the superior mediastinal mass utilizing a trans-cervical approach without need for sternotomy. A neural integrity monitor (NIM) and electromyogram (EMG) endotracheal tube were used during the procedure to identify the left recurrent laryngeal nerve. The specimen was delivered from the mediastinum with the capsule intact and was sent to pathology. Grossly the specimen measured 5.0 × 4.0 × 3.3 cm (Fig. 1) and weighed 43.6 g. Histologic sections (Fig. 2) revealed a benign ectopic thyroid with nodular hyperplasia (Fig. 3) and unremarkable subcapsular parathyroid (Fig. 4). The patient's recovery was uneventful.

3. Discussion

A thyroid mass within the mediastinum following a total thyroidectomy is a condition often referred to as “forgotten goiter”. Prior reported cases are few, and data is limited, with some uncertainty remaining as to the exact origin of this ectopic thyroid tissue. Possible etiologies include an incomplete removal of the thyroid gland during initial cervical thyroidectomy, or perhaps an

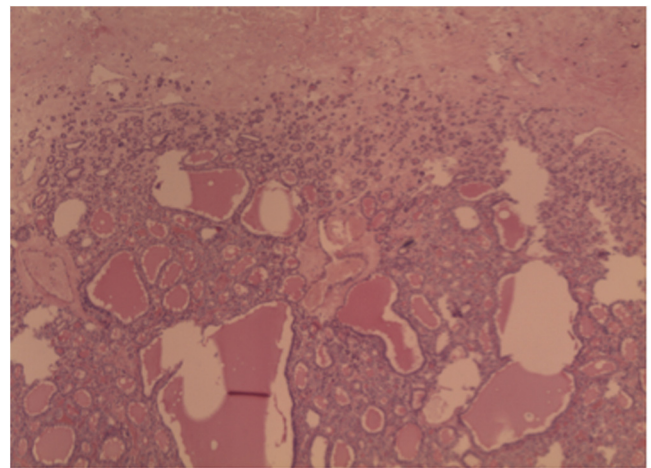


Fig. 3. Histologic section revealing a benign ectopic thyroid with nodular hyperplasia.

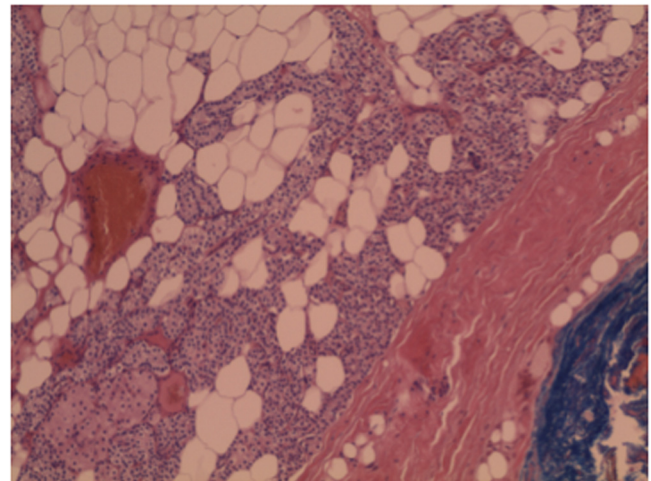


Fig. 4. Histologic section revealing an unremarkable subcapsular parathyroid.

autonomous intrathoracic goiter (AIG) – a thyroid gland located in the mediastinum, independent and with no parenchymatous or vascular connection with the cervical thyroid gland [2].

Embryological development of the thyroid gland begins with the entodermal diverticulum, which appears in the midline of the ventral surface of the pharynx. This sac will form the parenchyma of the thyroid gland and is connected to the ventral floor of the pharynx via the thyroglossal duct. As the thyroglossal duct atrophies, the thyroid gland relocates anterior to the trachea. Anomalies may occur, however it is rare to have the gland located deep to the sternum [3].

While substernal extension of a cervical goiter is a far more common presentation, only 1% of mediastinal masses are intrathoracic thyroid tumors [4]. Our patient's development of an asymptomatic mediastinal mass 5 years after total thyroidectomy is consistent with the description of other authors and most likely represents a clinically silent goiter left behind at the time of original thyroidectomy.

Compensatory hypertrophy of residual thyroid tissue following partial thyroidectomy was first described by Wagner in 1884 and was subsequently confirmed by the work of Loeb, Marine, and Cameron [5]. Any thyroid tissue remaining after cervical thyroidectomy can grow or migrate inferiorly. In a review of the literature, Calo et al. reported that in the majority of cases forgotten goiter is the consequence of the incomplete removal of a plunging goiter,

although sometimes it may be attributed to a concomitant, unrecognized mediastinal goiter which is not connected to the thyroid [6]. In our case, the original operating surgeon noted that the left side of the thyroid gland was large and had an intrathoracic component. Despite the belief that the entire gland was identified and excised at the initial operation, we strongly suspect that at least some functional thyroid tissue remained and over time underwent compensatory hypertrophy.

4. Conclusion

Contrary to the recent reported experiences of others, we found a complete resection of the forgotten goiter can be safely accomplished using the same standard cervical approach commonly utilized for thyroidectomy with mediastinal extension and does not require sternotomy [7].

Our review of the literature found few cases of a mediastinal goiter following total cervical thyroidectomy between the years 1992 and 2013. Whether this is indicative of the true rare occurrence of this condition or rather represents significant underreporting is unclear. In our case report, the patient's mediastinal goiter may have been a remnant inadvertently left behind at initial thyroidectomy, or may have been an ectopic thyroid that became substantially hypertrophic in the years following thyroidectomy. Awareness of the potential for compensatory hypertrophy of any remaining thyroid tissue however should compel the surgeon to be meticulous in the identification and complete removal of any mediastinal extensions at the time of cervical thyroidectomy.

This case reaffirms that a mediastinal goiter can be safely and completely resected using a standard cervical approach and the case of the "forgotten goiter" is no exception. The size, location, and benign characteristics remain the more relevant considerations in determining a cervical rather than trans-sternal entry.

Conflict of interest

The authors declare that they have no competing interests.

Funding

No applicable source of funding

Ethical approval

Consent was obtained from the patient for publication of this case report. It is not a research study requiring ethical approval and does not use patient information.

Consent

Written informed consent was obtained from the patient for publication of this case report and any accompanying images. A copy of the written consent is available for review by the Editor-in-Chief of this journal.

Author contribution

KP and CP equally contributed to the creation of this manuscript. Both authors read and approved the final manuscript.

Gurantor

Chase C. Parsons, MD and Kunal M. Patel, MD, are the gurantors who accept full responsibility for the case report.

Acknowledgments

Ronald Reis, MD Westchester General Hospital 2500 SW 75th Street Miami, Florida 33155.

References

- [1] G. Massard, J.M. Wihlm, M.Y. Jeung, N. Roeslin, P. Dumont, J.P. Witz, Forgotten mediastinal goiter: seven cases, *Ann. Chir.* 46 (1992) 770–773.
- [2] M. Riquet, M. Deneuve, B. Debesse, J. Chretien, Autonomous intrathoracic goiter: apropos of 2 new cases, *Rev. Pneumol. Clin.* 42 (1986) 267–273.
- [3] Forsham, Peter H., Section II. The Ciba Collection of Medical Illustrations. Vol. 4. West Caldwell, NJ: Ciba, 1974. 43–44. Print.
- [4] C. David Sabiston Jr., *Textbook of Surgery: The Biological Basis of Modern Surgical Practice*, 15th ed., WB Saunders, Philadelphia, 1996, pp. 1, 924MD.
- [5] Leo Loeb, Cora Hesselberg, Studies on compensatory hypertrophy of thyroid gland, *J. Med. Res.* (1920) 283–303 (Web).
- [6] P.G. Calò, A. Tatti, F. Medas, P. Petruzzo, G. Pisano, A. Nicolosi, Forgotten goiter: our experience and a review of the literature, *Ann. Ital. Chir.* 83 (2012) 487–490.
- [7] A. Sahbaz, N. Aksakal, B. Ozcinar, F. Onuray, K. Caglayan, Y. Erbil, The Forgotten goiter after total thyroidectomy, *Int. J. Surg. Case Rep.* 4 (3) (2013) 269–271.

Open Access

This article is published Open Access at sciedirect.com. It is distributed under the [IJSCR Supplemental terms and conditions](#), which permits unrestricted non commercial use, distribution, and reproduction in any medium, provided the original authors and source are credited.