

## Pemphigus Vulgaris: A Rare Case of Gingival Involvement

### Abstract

Pemphigus vulgaris (PV) is an autoimmune mucocutaneous disease characterized by epithelial blistering affecting the mucosal/cutaneous surfaces. This case report demonstrates the oral manifestations of PV in the uncommon locations such as the attached, marginal, and interdental gingiva with no involvement of oral mucosa, tongue, palate, or buccal mucosa.

**Keywords:** *Acantholysis, autoimmune, Nikolsky's sign, pemphigus vulgaris*

### Introduction

Pemphigus is derived from the Greek word *pemphix* meaning blister or bubble.<sup>[1-5]</sup> It is represented by a group of potentially life-threatening autoimmune mucocutaneous diseases such as epithelial blistering affecting the mucosal/cutaneous surfaces.<sup>[1-10]</sup> It not only affects the oral mucosa and the skin but also affects the mucosa of the conjunctivae, nose, pharynx, larynx, genitals, and esophagus.<sup>[1-3]</sup> Pemphigus affects 0.1–0.5/100,000 individuals per year.<sup>[1-7]</sup> It affects both sexes equally and is more common in middle-aged and elderly patients,<sup>[1,2,4,6-8]</sup> but few shows to be slightly predominant in women.<sup>[2,6,7]</sup> The etiology of pemphigus vulgaris (PV) is not known, and in some cases, it may have a strong genetic basis.<sup>[1,3-5,7]</sup> The possible etiological factors that are responsible for the pathogenesis of PV are human leukocyte antigen complex;<sup>[1-5]</sup> diet; drugs; viruses; some autoimmune disorders such as myasthenia gravis, rheumatoid arthritis, pernicious anemia, and lupus erythematosus; pregnancy; smoking; and high exposure to pesticides.<sup>[2]</sup> The oral mucous membrane is frequently affected in PV patients; most of patients present with oral lesions as the first sign of PV. Lesions may occur anywhere on the oral mucosa,<sup>[3,6,8]</sup> but the buccal mucosa<sup>[6-8]</sup> is the most commonly affected site, followed by involvement of the palatal, lingual, and labial mucosae;<sup>[6-8]</sup> the gingiva is the least

This is an open access journal, and articles are distributed under the terms of the Creative Commons Attribution-NonCommercial-ShareAlike 4.0 License, which allows others to remix, tweak, and build upon the work non-commercially, as long as appropriate credit is given and the new creations are licensed under the identical terms.

For reprints contact: WKHLRPMedknow\_reprints@wolterskluwer.com

commonly affected site<sup>[4,8]</sup> and erosive or desquamative gingivitis is a common manifestation of the disease.<sup>[4,8]</sup> In majority of PV patients, the oral lesions are followed by the development of skin lesions. If oral PV is recognized early, progression of the disease to skin involvement can be prevented. Early oral lesions of PV are difficult to diagnose and diagnostic delay of more than 6 months is common as they are nonspecific, presenting as ulcerations or superficial erosions, and they rarely present with the intact bullae formation.<sup>[8]</sup> This study describes the case of a patient presenting with a 8-month history of painful gingiva who was finally diagnosed as having PV.

### Case Report

A 32-year-old homemaker reported to the department of dentistry with a chief complaint of burning sensation in the gums, pain when brushing and eating, and painful gingival erosion and desquamation for the past 8 months. The patient was not able to eat or drink adequately.

A detailed family history was obtained and it was noncontributory.

On intraoral examination, there were denuded, spontaneously bleeding gingival zones. Nikolsky's sign showed a positive reaction, and the epithelium could be peeled away easily by slightly scratching the surface of the gingiva. There was presence of white patches and ulcerative and erythematous area on the on the gingival surface. Periodontal examination revealed no calculus and plaque formation.

**How to cite this article:** Thakur N, Rayast D, Negi M, Bansal S. Pemphigus vulgaris: A rare case of gingival involvement. *Contemp Clin Dent* 2020;11:277-9.

**Nisha Thakur,  
Deepa Rayast,  
Mayum Negi,  
Shivanjli Bansal**

*Department of Periodontics,  
H. P. Government Dental  
College and Hospital, Shimla,  
Himachal Pradesh, India*

**Submitted :** 26-Oct-2018

**Accepted :** 04-Dec-2018

**Published :** 26-Nov-2020

#### Address for correspondence:

*Dr. Nisha Thakur,  
Department of Periodontics,  
H. P. Government Dental  
College and Hospital, Shimla,  
Himachal Pradesh, India.  
E-mail: nshakur123@yahoo.  
co.in*

#### Access this article online

**Website:**  
[www.contempclindent.org](http://www.contempclindent.org)

**DOI:** 10.4103/ccd.ccd\_799\_18

#### Quick Response Code:



There was no attachment and bone loss. Gingiva was reddish blue, soft, and edematous and showed bleeding on probing. The site most severely affected was her gingival surface (attached marginal and interdental gingival) with no involvement of oral mucosa, tongue, or palate [Figure 1].

On extraoral examination, no skin lesions were present. A dermatologist confirmed the absence of any cutaneous lesions. Other sites such as conjunctival, nasal, genital, and esophageal mucosa did not show any evidence of the lesions. The cytological smear was performed before obtaining biopsy specimens. Smears were prepared by exfoliating from the labial surface of the gingiva [Figure 2]. Cytosmear showed Tzanck (acantholytic) cells with a high nuclear–cytoplasmic ratio with hyperchromatic nuclei and a very smooth nuclear outline [Figure 3]. An incisional biopsy was drawn from perilesional site of the involved gingival surface. Histopathological examination revealed suprabasal separation with the formation of tombstone appearance. The dermis showed mild perivascular inflammation [Figure 4].

Differential diagnosis of PV included aphthous stomatitis, gingivostomatitis, erythema multiforme, erosive lichen planus, or oral candidiasis and may be improperly treated for months or even years.<sup>[7]</sup>

### Discussion

PV is an autoimmune disease that is characterized by acantholysis (loss of cell-to-cell contact) in the epithelium,<sup>[1,2,8]</sup> with a positive Nikolsky’s phenomenon which was seen in our study. Histologically, there is presence of intraepithelial blister, rounded acantholytic, and Tzanck cells,<sup>[2,4,7]</sup> demonstrating degenerative changes, including round, swollen hyperchromatic nuclei with a clear perinuclear halo in the cytoplasm,<sup>[8]</sup> which was also evident in our study. According to Coscia-Porrazzi *et al.*, acantholytic/Tzanck cells were recognized in 37 out of 40 PV patients and stated that cytomorphologic studies are useful to screen the cases suspected to be oral PV.<sup>[8]</sup> In our study, acantholytic cells were seen in the cytological smear, which enabled us to make a presumptive diagnosis of PV.

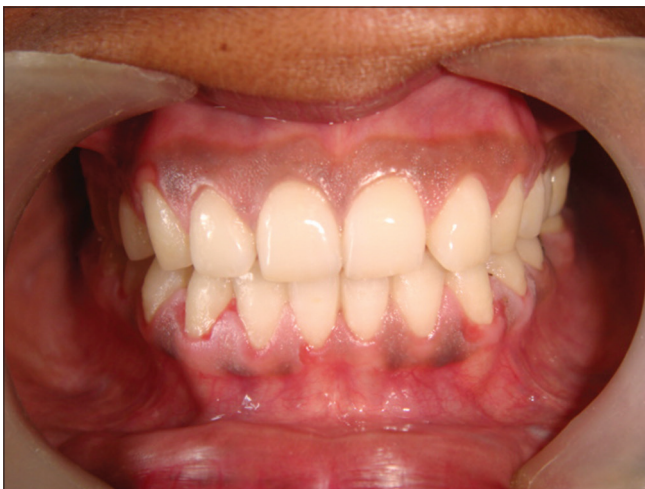

Figure 1: Gingival desquamation

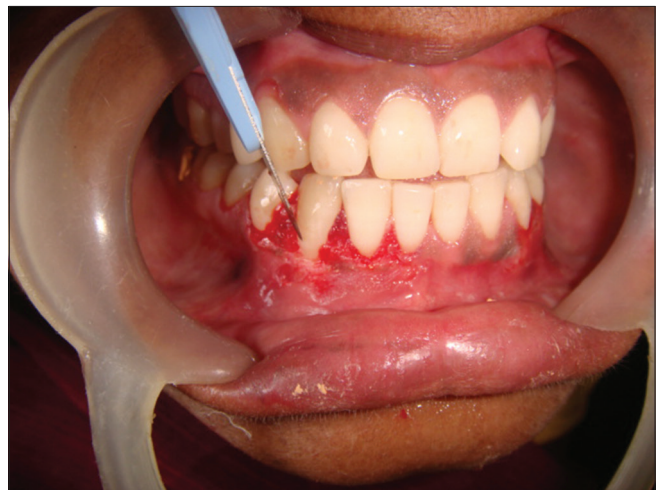

Figure 2: Cytological smears prepared by exfoliating from the labial surface of the gingiva

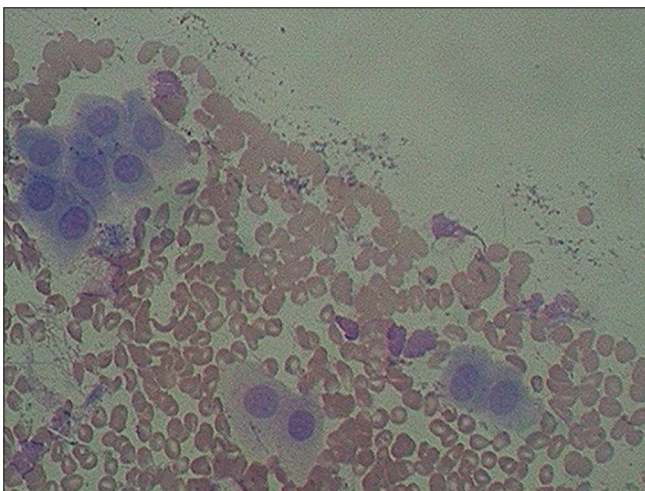


Figure 3: Tzanck cell showing slight high nuclear–cytoplasmic ratio with well-defined nuclear outline

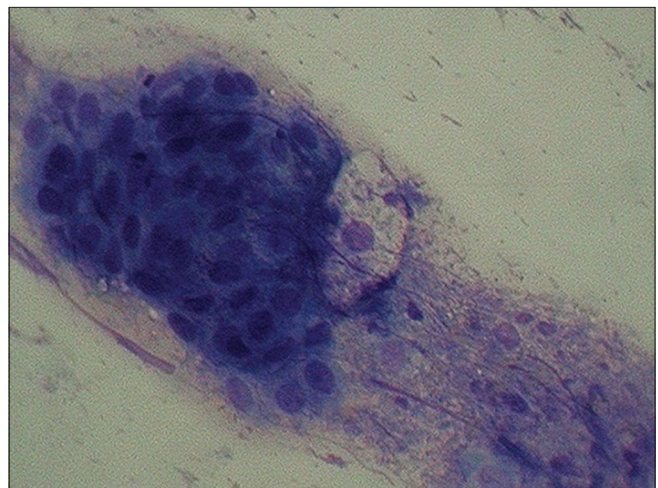


Figure 4: Suprabasilar separation

However, biopsy is necessary because the acantholytic cells alone are not a definitive diagnosis of PV, but it is only a presumptive diagnosis as the acantholytic cells may also appear in other diseases such as impetigo, Darier's disease, transient acantholytic dermatosis, viral infections, and carcinoma.<sup>[8]</sup>

The mainstay of treatment with PV, even if confined to the oral mucosa, is systemic corticosteroids though the oral lesions may respond partially to topical corticosteroids (creams such as clobetasol propionate and intralesional injections such as triamcinolone).<sup>[6,7]</sup> The periodontal care consists of frequent professional oral prophylaxis, 0.2% chlorhexidine mouth rinse, the powered tooth brushes for home care, and removing local irritating factors such as sharp cusps of the teeth, thus minimizing irritation.<sup>[3]</sup> The initial dose of corticosteroids (prednisolone) is typically about 0.75–1 mg/kg/day. The dose is increased by 25%–50% every 5–7 days, if the initial dose is insufficient in controlling the disease. Adjuvant immunosuppressives are added if more than 1 mg/kg/day of prednisolone is needed for their “steroid-sparing” effect and are also instituted also if there are frequent relapses of the disease when doses of prednisolone are tapered or if significant side effects are experienced with the steroids. The most commonly used immunosuppressants are azathioprine, mycophenolate mofetil, and cyclophosphamide.<sup>[7]</sup>

## Conclusion

Being a serious disease, it becomes very important to diagnose PV at an early stage when it is limited to oral cavity and a close follow-up is essential, and referral to the specialists should be done in the event of appearance of extraoral symptoms. Careful assessment and correlation of the clinical appearance, histological features, and immunofluorescence findings should be done. As it is a life-threatening disease condition, it is important that the dentist is able to recognize oral manifestations of PV and treat or refer appropriately.<sup>[2]</sup>

## Declaration of patient consent

The authors certify that they have obtained all appropriate patient consent forms. In the form, the patient has given her consent for her images and other clinical information to be reported in the journal. The patient understands that her name and initials will not be published and due efforts will be made to conceal her identity, but anonymity cannot be guaranteed.

## Financial support and sponsorship

Nil.

## Conflicts of interest

There are no conflicts of interest.

## References

1. Thorat MS, Raju A, Pradeep AR. Pemphigus vulgaris: Effects on periodontal health. *J Oral Sci* 2010;52:449-54.
2. Sreeshyla HS, Hegde U, Vidy GD. Oral pemphigus vulgaris-report of a case-review on its etiopathogenesis. *Arch Oral Sci Res* 2011;1:210-4.
3. Pradeep AR, Thorat MS, Raju A. Pemphigus vulgaris associated with significant periodontal findings: A case report. *Int J Med Med Sci* 2009;8:297-301.
4. Javali MA, Zainab H. Pemphigus vulgaris presenting as gingival involvement. *Indian Dermatol Online J* 2012;3:202-4.
5. Scully C, Challacombe SJ. Pemphigus vulgaris: Update on etiopathogenesis, oral manifestations, and management. *Crit Rev Oral Biol Med* 2002;13:397-408.
6. Karagir A, Ranpise SG, Ranpise T. Oral pemphigus vulgaris-A case report. *JIDA* 2012;6:2012.
7. Dagistan S, Goregen M, Miloglu O, Cakur B. Oral pemphigus vulgaris: A case report with review of the literature. *J Oral Sci* 2008;50:359-62.
8. Ohta M, Osawa S, Endo H, Kuyama K, Yamamoto H, Ito T. Pemphigus vulgaris confined to the gingiva: A case report. *Int J Dent* 2011;2011:207153.
9. Solanki A, Chokshi K, Patel S. Review article on treatment of pemphigus vulgaris. *Int J Curr Pharm Res* 2012;4:10-4.
10. Caltabiano R, Magro G, Puzzo L, Vasquez E, De Pasquale R. Unusual clinical and pathological features in pemphigus vulgaris: A potential diagnostic pitfall. *Case Rep Med* 2011;2011:518758.