


CASE REPORT



## Delayed spontaneous recanalization of chronic total occlusion of left anterior descending artery after attempted but failed revascularization during percutaneous coronary intervention

Nirmal Guragai <sup>a</sup>, Upamanyu Rampal<sup>a</sup>, Rahul Vasudev<sup>a</sup>, Hiten Patel<sup>a</sup>, Hashita Diana Manohar<sup>b</sup>, Pragma Bhandari<sup>c</sup>, Mahesh Bikkina<sup>a</sup>, Fayeze Shamoon<sup>a</sup> and Hartaj Virk<sup>a</sup>

<sup>a</sup>Department of Cardiology, New York Medical College at St Joseph's Regional Medical Center, Paterson, NJ, USA; <sup>b</sup>Research Intern, University of Louisville, Louisville, KY, USA; <sup>c</sup>Department of Internal Medicine, Manipal College of Medical Sciences, Pokhara, Nepal

### ABSTRACT

Chronic total occlusion (CTO) of coronary artery remains the Achilles heel of the interventional cardiologist and is present in a significant proportion of referrals for coronary artery bypass graft surgery (CABG); however, with the development and standardization of modern CTO recanalization techniques, it has been able to achieve excellent success while coping with lesions of increasing complexity. Nevertheless, failure to recanalize despite the development of new techniques still remains one of the challenges in the field of interventional cardiology. Spontaneous recanalization has been described in nonocclusive coronary artery dissections in detail; none has addressed the possibility of spontaneous recanalization after failed percutaneous coronary intervention (PCI). We report a case of spontaneous but delayed recanalization of CTO of left anterior descending artery 3 years after attempted but failed revascularization during PCI.

### ARTICLE HISTORY

Received 24 March 2018  
Accepted 12 June 2018

### KEYWORDS

Chronic total occlusion; delayed spontaneous recanalization; revascularization; percutaneous coronary intervention; microdissection

## 1. Introduction

A chronic total occlusion (CTO) is defined as an angiographically documented or clinically suspected complete interruption of antegrade coronary flow (Thrombolysis In Myocardial Infarction-TIMI – 0 flow) of at least 3 months durations [1]. CTOs are a common finding during routine coronary angiography and the prevalence varies from 18% to 52% [2]. CTOs typically have collateralization of the distal vessel on coronary angiography, but these collaterals may not provide sufficient blood flow to the myocardial bed, resulting in ischemia and anginal symptoms. Patients who remain symptomatic with demonstration of viable myocardium despite maximal medical therapy can be considered for revascularization. The development and standardization of modern CTO recanalization techniques during percutaneous coronary intervention (PCI) has led to success rates far beyond 90% despite encountering lesions of greater complexity [3]. Despite these recent advances only 10% of all CTOs have been treated with percutaneous techniques over a long period of time, with the majority of patients primarily managed medically or referred for coronary artery bypass graft surgery (CABG) [4].

Over a long period of time CTO-PCI complications rates remained <2%, which is comparable to complication rates for non-CTO interventions [5]. This rate seems to hold steady even in the contemporary era of advanced

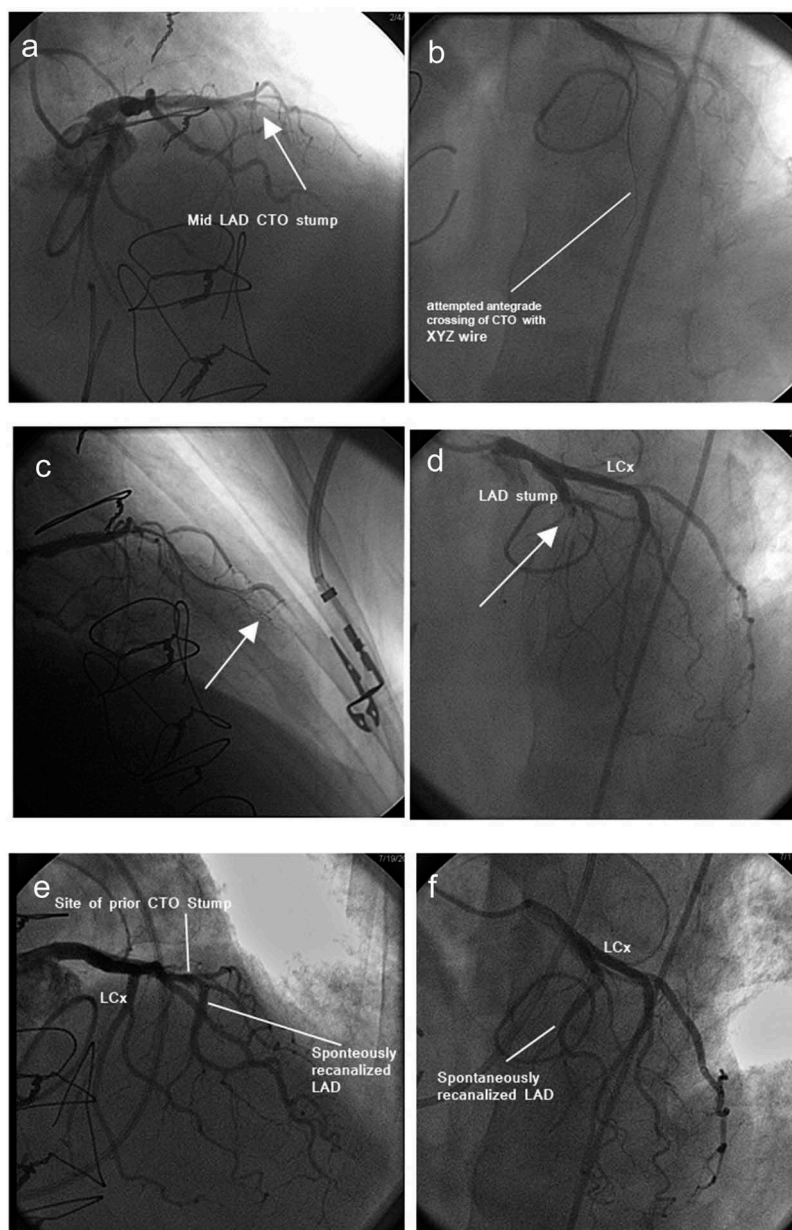
techniques and new dedicated guidewires. However, the development of novel techniques such as antegrade dissection reentry and retrograde approach have overall improved success in even in more complex lesion subsets such as those with ambiguous proximal cap, poor distal targets, and long occlusions. With these recent advances in the technique and device technology, success rates have improved to 80–90% in specialized centers [6]. Nevertheless, failure to recanalize despite the development of new techniques still remains one of the challenges in the field of interventional cardiology. Usually, symptomatic patients who have undergone a failed PCI of a CTO would be considered candidates for CABG. However, it is extremely rare to see spontaneous recanalization after failed PCI [7]. This spontaneous recanalization has been well documented in nonocclusive coronary artery dissections in detail; none has addressed the possibility of spontaneous recanalization after guidewire induced microdissections. Although its true incidence is unknown, we report an interesting case of late spontaneous revascularization of CTO of left anterior descending (LAD) artery after failed revascularization during PCI.

## 2. Case presentation

A 76 years old male with past medical history of end-stage renal disease on hemodialysis, hypertension,

dyslipidemia, anemia of chronic disease, and obstructive sleep apnea presented to the office for evaluation of typical exertional chest pain. On examination, his vitals were within normal limits. Physical examination was also grossly unremarkable. He underwent coronary angiography due to the typical nature of his symptoms and high pretest probability for coronary artery disease. Coronary angiography showed a 100% stenosis of mid-LAD artery suggestive of CTO. Subsequently he underwent a Thallium nuclear viability study which revealed viable myocardium in the LAD artery territory. He was thus brought back to the cardiac catheterization laboratory for revascularization. Initially, a 7F XB 3.5 guiding catheter was

used to intubate the vessel. 014 HT Balance Middle Weight Universal 300-cm wire was used in an unsuccessful attempt to cross the lesion. An antegrade wire escalating using Fielder FC wire with Finecross® microcatheter was attempted. However, the wire could not be crossed across the full length of the CTO. Following attempted intervention, there was still a 100% residual stenosis, and the procedure was aborted (Figure 1(A–D)). It was decided to manage the patient with optimal medications including aspirin, statin, lisinopril, and nitrates. The patient had a fair clinical outcome and did not report any exertional chest pain for the next few years. Three years later, the patient presented to the clinic for



**Figure 1.** Panel A, C, and E with right anterior oblique projection showing mid left anterior descending (LAD) artery chronic total occlusion (CTO) stump, unable to cross XYZ wire into true lumen of LAD artery distal to CTO stump, and spontaneous recanalization after 3 years, respectively. Panel B, D, and F with antero-posterior cranial view showing attempted antegrade crossing of CTO with XYZ wire, unchanged LAD artery stump CTO after attempted antegrade wire crossing and spontaneously recanalized LAD artery 3 years after attempted wire crossing, respectively. (LCx: Left Circumflex).

preoperative evaluation for creation of arteriovenous fistula for dialysis. Echocardiography demonstrated severe pulmonary hypertension and eventually the patient underwent repeat coronary angiography that revealed spontaneous recanalization of the prior CTO of the mid-LAD artery with a 60% stenosis at the site of prior CTO (Figure 1(E,F)). The lesion was moderately calcified. Hemodynamic assessment of this lesion was performed using Fractional Flow reserve and was calculated at 0.81, suggestive of non-hemodynamically significant stenosis. Thus, the previously noted CTO of mid-LAD artery was no longer present, and there was a spontaneous recanalization of the totally occluded artery.

### 3. Discussion

Here, we have reported an interesting case of spontaneous recanalization of a macrodissection of LAD artery following attempted guidewire crossing of a CTO. CTOs are routinely encountered during coronary angiography, but subsequent revascularization rates are low. With the advent of newer techniques and interventional devices, CTO is being intervened upon with increasing frequency [8,9]. New devices and therapies continue to be developed to improve CTO-PCI procedural success despite which there are about 10% chance of failure and about 1% risk for major complications of death, myocardial infarction, tamponade, and contrast-induced nephropathy [5].

The typical pathological finding in a occluded segment would show fibrous tissue, atheroma with or without calcification, vascular tissue, and infiltrates of lymphocytes [10]. The basic pathological feature of a CTO consists firstly of a proximal cap with fibrotic or calcified constituents and with either a tapering or non-tapering morphology. Occlusions with tapered cap are shorter and are less likely to have side branches at the proximal cap (1/5 versus 4/5 for non-tapered occlusions). The tissue content of tapered occlusions consists characteristically of loose fibrous tissue, with prominent neovascularization. There may be multiple small non-functional recanalized neo-microchannels throughout the occlusions or one central lumen for recanalization connecting the proximal and distal lumens [5], giving the false impression of a functionally sub-occlusive lesion. Careful examination of the occlusion in multiple views can delineate the position of these collaterals outside the vessel architecture.

Failure to revascularize depends upon several factors. There are two important factors that relate to the feasibility of crossing the occlusion with a wire. First is plaque composition, which has a straightforward relationship with lesion age, with gradual replacement of cholesterol and foam cells with fibrous and calcific material. The other factor is extent of vessel

recanalization, which is associated with loose fibrous tissue, less resistance to wire passage and does not seem to have a clear relationship with age nor lesion length.

The key aspect determining the success of revascularization in CTO PCI is the operator to manipulate the guidewire across the occluded segment from the proximal lumen to distal lumen. Frequently, the CTO segments have a highly resistant proximal end, at the point of transition from patent vessel to the occluded proximal cap, and these segments are often heavily calcified. An analogous distal cap is also recognized as a point of difficult re-entry into the distal true lumen, but less so than the proximal cap. Neovascularization channels are approximately 200 microns in diameter, which is slightly smaller than the tip of a specialized CTO wires (such as fielder XT/FC, Asahi Intecc, Japan).

We postulate that the use of the wire to open the lesion must have lead to the opening of microchannels within the thrombus resulting in the opening of occluded vessel as well as the enzymatic degradation of connective tissue by release of collagenase during CTO PCI, which could have enabled rapid and reliable wire crossing.

### 4. Conclusion

Percutaneous revascularization of CTO is often complicated by the inability to cross or dilate the lesion, as well as a high incidence of restenosis and reocclusion. Although spontaneous coronary recanalization can occur in patients undergoing catheterization for acute myocardial infarction or failed PCI due to coronary dissection, it is a rare event in CTOs, particularly in native coronary arteries. In some instances, just manipulation with wire during PCI can lead to macrodissection and spontaneous opening of the chronically occluded lesion.

### Disclosure statement

No potential conflict of interest was reported by the authors.

### ORCID

Nirmal Guragai  <http://orcid.org/0000-0002-6477-7789>

### References

- [1] Sianos G, Werner GS, Galassi AR, et al. Recanalisation of chronic total coronary occlusions: 2012 consensus document from the EuroCTO club. *Euro Interv.* 2012;8(1):139–145.
- [2] Fefer P, Knudtson ML, Cheema AN, et al. Current perspectives on coronary chronic total occlusions: the Canadian multicenter chronic total occlusions registry. *J Am Coll Cardiol.* 2012;59(11):991–997.

- [3] Sianos G, Konstantinidis NV, Di Mario C, et al. Theory and practical based approach to chronic total occlusions. *BMC Cardiovasc Disord.* 2016 Feb 9;16:33.
- [4] Sathananthan JI, Džavík V. Coronary intervention for chronic total occlusion: current indications and future directions. *Coron Artery Dis.* 2017 Aug;28(5):426–436.
- [5] Rathore S, Matsuo H, Terashima M, et al. Procedural and in-hospital outcomes after percutaneous coronary intervention for chronic total occlusions of coronary arteries 2002 to 2008: impact of novel guidewire techniques. *JACC Cardiovasc Interv.* 2009;2(6):489–497.
- [6] Shan P. Management of coronary chronic total occlusion Pinak B. *Circulation.* 2011;123:1780–1784.
- [7] Özer C, Özeke Ö, Güngör M, et al. Late spontaneous recanalization of in-stent chronic total occlusion facilitating successful percutaneous coronary revascularization of the right coronary artery: case report. *TurkiyeKlinikleri J Cardiovasc Sci.* 2012;24(3):346–348.
- [8] Stone GW, Colombo A, Teirstein PS, et al. Percutaneous recanalization of chronically occluded coronary arteries: procedural techniques, devices, and results. *Catheter Cardiovasc Interv.* 2005;66(2):217–236.
- [9] Thompson C. Techniques for percutaneous revascularization of coronary CTO; Necessary skillsets for a hybrid approach to CTO PCI. *Interventional Cardiology Clinics.* 2012;1(3):349–353.
- [10] Irving J, Pathophysiology CTO. How does this affect management? *Curr Cardiol Rev.* 2014 May;10(2):99–107.