

Dengue fever-associated necrotizing scleritis

A case report with long-term follow-up

Koju Kamoi, MD, PhD*, Manabu Mochizuki, MD, PhD, Kyoko Ohno-Matsui, MD, PhD

Abstract

Rationale: Dengue fever is a notable emerging infectious disease that is now seen worldwide, with an estimated incidence of approximately 390 million cases per year. Although ocular complications are uncommon among dengue fever-infected patients, caution is needed to prevent vision loss. Here we report a potentially serious sight-threatening complication of dengue fever, dengue fever-associated necrotizing scleritis.

Patient concerns and diagnosis: After being bitten by mosquitoes, a 60-year-old Japanese female exhibited positive serologic tests of immunoglobulin M and G enzyme immunoassays for dengue viral infection along with a decrease of leukocytes and platelets. These findings led to a dengue fever diagnosis. Slit lamp examination of her left eye revealed a conjunctival and scleral injection, elevation of the entire circumference of the sclera, and bulging of the sclera on the nasal upper side with a patch of avascular episcleral tissue. Since additional systemic examinations identified no autoimmune diseases such as rheumatism, we diagnosed the patient as dengue fever-associated scleritis.

Interventions: Intensive systemic and topical steroids were administered during the initial acute phase. Over the next 15 months, the amount of steroid was tapered off.

Outcome: Initial findings for the scleritis gradually declined in response to steroid treatment. Although there was no recurrence of active scleritis, gradual thinning of the sclera continued to occur during the 18-year follow-up.

Lessons: To the best of our knowledge, this is the first reported case of dengue fever-associated necrotizing scleritis with long-term follow-up. This case suggests the existence of a long-term immune-mediated mechanism during the development of the dengue fever-associated necrotizing scleritis. Dengue fever virus patients found to have red eyes need to be carefully followed and treated, as these eyes might develop thinning of the sclera that could lead to rupture of the globe, thereby resulting in blindness.

Abbreviations: BCVA = best corrected visual acuity, DEN = dengue virus.

Keywords: blindness, dengue fever, necrotizing scleritis, scleritis

1. Introduction

Dengue fever is a notable emerging infectious disease that is now seen worldwide, with an estimated incidence of approximately 390 million cases per year.^[1] Dengue fever viruses, which are classified as *Flaviviridae*, are composed of 4 serotypes (dengue virus, DEN-1, DEN-2, DEN-3, DEN-4).^[2,3] These viruses are transmitted primarily through the bite of the *Aedes aegypti* and *A albopictus* mosquito. Dengue fever is usually found in tropical and subtropical regions.

Editor: N/A.

The authors declare no conflicts of interests.

Department of Ophthalmology and Visual Science, Graduate school of Medical and Dental Science, Tokyo Medical and Dental University, Tokyo, Japan.

* Correspondence: Koju Kamoi, Department of Ophthalmology and Visual Science, Graduate School of Medical and Dental Sciences, Tokyo Medical and Dental University, 1-5-45 Yushima, Bunkyo-ku, Tokyo 113-8519, Japan (e-mail: koju.oph@tmd.ac.jp).

Copyright © 2018 the Author(s). Published by Wolters Kluwer Health, Inc. This is an open access article distributed under the terms of the Creative Commons Attribution-Non Commercial-No Derivatives License 4.0 (CCBY-NC-ND), where it is permissible to download and share the work provided it is properly cited. The work cannot be changed in any way or used commercially without permission from the journal.

Medicine (2018) 97:32(e11875)

Received: 20 April 2018 / Accepted: 26 July 2018

<http://dx.doi.org/10.1097/MD.00000000000011875>

In Japan, dengue fever was considered to be one of the afferent infectious diseases,^[4] as the mosquitoes responsible for the disease were not found in the metropolitan areas of Japan. However, after 70 years with no confirmed autochthonous cases, a dengue fever outbreak occurred in Tokyo, Japan, in 2014.^[5] Since then, a total of 160 additional autochthonous cases have been confirmed in Japan, with dengue fever now the focus of a great deal of attention within the country.

In general, dengue fever presents as an acute febrile illness, retro-orbital pain, muscle and joint pain, nausea, vomiting, and a petechial rash.^[6] Although ocular complications are uncommon among dengue fever-infected patients, it has been shown that the anterior segment of the eye in some cases exhibited subconjunctival hemorrhage, uveitis, and a dengue-related shallow anterior chamber. In the posterior segment of the eye, maculopathy, macular edema, optic neuropathy, vitreous hemorrhage, and vein occlusions have been reported.^[7,8]

In the current study, we report for the first time a new ocular complication of dengue fever, dengue fever-associated necrotizing scleritis. In order to document the changes in the condition of the sclera, the patient in this case was followed over an 18-year period.

2. Case report

A 60-year-old female was bitten by mosquitoes during her stay in the Republic of the Philippines in September 1998. Several days

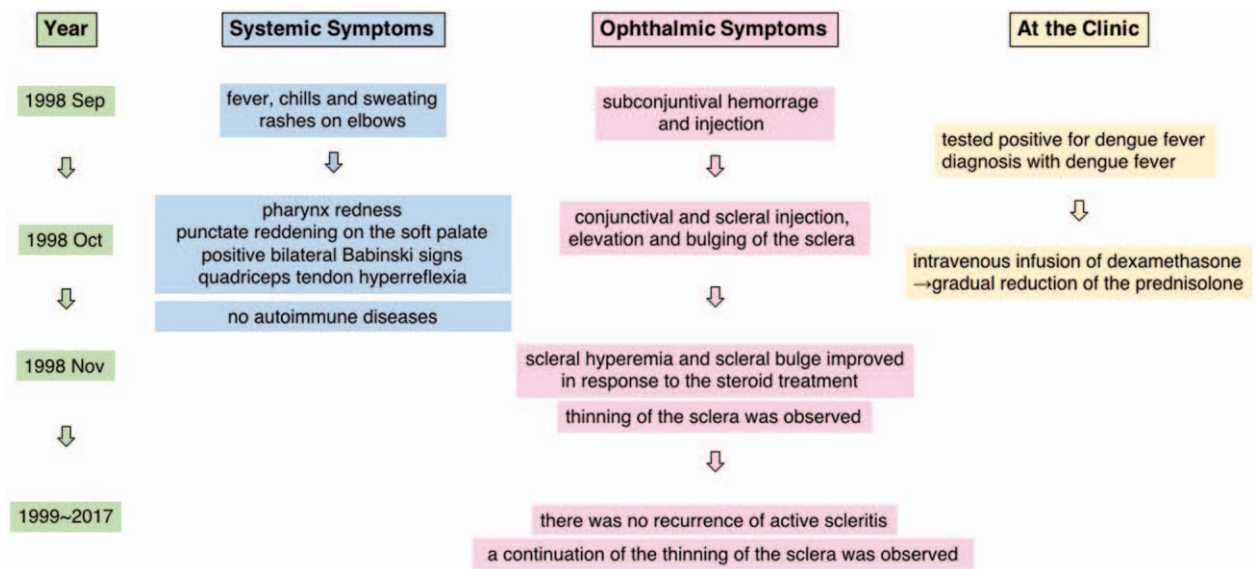


Figure 1. Timeline of the events leading up to the administration of steroid and the subsequent systemic and ophthalmic symptoms. Left column: year during which the event occurred. Middle columns: systemic and ophthalmic symptoms including responses to treatments. Right column: actions taken by the attending physician such as performing a test, making a diagnosis, or administering a treatment.

after being bitten, the patient had a 38.8°C fever, chills, and sweating (Fig. 1). The administration of antipyretics was not effective. Rashes were present on her elbows bilaterally, and subconjunctival hemorrhage and injection were also seen in her left eye. After being referred to a regional clinic in the Philippines, positive serologic tests of immunoglobulin M and immunoglobulin G enzyme immunoassays for dengue viral infection and a decrease of leukocytes to 1400/μL, platelets to 1900/μL, and hematocrit to 37.0, led to a diagnosis of dengue fever.

Although symptomatic treatments were performed, her left eye pain did not resolve. As her condition was not getting better and instead had worsened, she returned to Japan and visited the Tokyo Medical and Dental University Hospital. At her initial presentation on 16 October 1998, her best-corrected visual acuity (BCVA) was 1.5 in the right eye and 0.06 in the left eye. The intraocular pressure was 8 mmHg in both eyes. Slit lamp examination of the right eye was normal. Examination of her left

eye revealed a conjunctival and scleral injection, elevation of the entire circumference of the sclera (Fig. 2A), and bulging of the sclera on the nasal upper side with a patch of avascular episcleral tissue (Fig. 2B). Keratic precipitate, cells (3+), flare (3+), and fibrin were observed in the anterior chamber. Funduscopy recordings showed optic disc swelling, but did not show vasculitis and serous retinal detachment. Magnetic resonance imaging identified anterior scleral thickening.

The patient was also referred to specialists in general medicine for further systemic evaluation. Additional examinations revealed pharynx redness, punctate reddening on the soft palate, positive bilateral Babinski signs, and left quadriceps tendon hyperreflexia. However, there were no autoimmune diseases such as rheumatism identified.

In consideration of the above findings in conjunction with the classification scheme of scleral inflammatory diseases,^[9] we diagnosed the patient as dengue fever-associated necrotizing

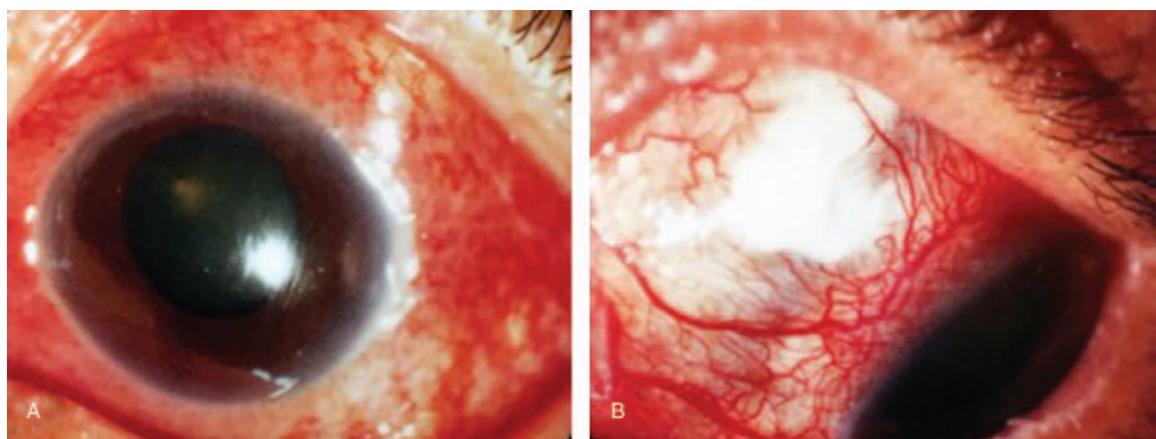


Figure 2. Slit lamp photo obtained at the first visit. A, The image shows conjunctival and scleral injection, elevation of the entire circumference of the sclera. B, The image shows bulging of the sclera on the nasal upper side with a patch of avascular episcleral tissue.

scleritis. In order to suppress the active scleritis, the patient was given an intravenous infusion of 100 mg of dexamethasone during the initial 3 days of her hospitalization, with 50 mg of dexamethasone then administered over the next 3 days. Subsequently, the patient then underwent a gradual reduction of the prednisolone starting from 20 mg. Ophthalmic solutions given in her left eye included topical 0.1% dexamethasone (8 times a day), 0.3% ofloxacin (4 times a day), 0.5% tropicamide (3 times a day), and 1% atropine sulfate (once a day).

The initial findings for the scleritis gradually declined in response to the steroid treatment, with the scleral hyperemia and scleral bulge improving after 1 month. The BCVA of her left eye recovered to 0.4 and there was a decrease in the inflammation of the anterior chamber. In conjunction with the decreasing inflammation, there was obvious thinning of the sclera (referred to as blue sclera) observed all around the sclera (Fig. 3A).

Over the next 15 months, the amount of steroid was gradually tapered off. There was no recurrence of active scleritis after discontinuation of the treatment. During her follow-up, there were no other ocular complications identified by ophthalmic examination, and the BCVA of her eye was maintained throughout this period. However, gradual thinning of the sclera continued to occur during the 18-year follow-up (Fig. 3B).

3. Discussion

Dengue fever has attracted worldwide attention as an emerging infectious disease. In Japan, it has been regarded as an imported sporadic infectious disease, with more than 200 patients since 2010 reported to have contracted the disease.^[4] Data collected during a survey of European international travelers revealed that an estimated 1% to 3% of tourists were infected with dengue virus after staying in a tropical region for 1 month.^[10] However, the recent outbreaks of autochthonous dengue fever infection in the Tokyo metropolitan area have startled the Japanese population, with dengue fever now regarded as a known infectious disease.^[5]

While there have been reports of eye diseases caused by the dengue fever virus, there have been no previous cases of necrotizing scleritis. Depending on the anatomic site of the disease, scleritis can be classified as either anterior or posterior

scleritis.^[9] Anterior scleritis can be divided into 4 subtypes: diffuse, nodular, necrotizing, and necrotizing without inflammation. Of these subtypes, our case's clinical features corresponded to that of the necrotizing scleritis, as the patient exhibited scleral edema with an overlying/adjacent patch of avascular episcleral tissue in the early stages of the disease, and scleral thinning after the acute phase.

With regard to the causes, scleritis has been shown to be closely associated with autoimmune diseases such as rheumatoid arthritis, Wegener's granulomatosis, and systemic lupus erythematosus, in addition to being associated with infectious diseases such as tuberculosis, syphilis, herpes zoster, and herpes simplex virus.^[9] In our current case, we performed systemic examinations in order to exclude autoimmune diseases and any infectious diseases that are associated with necrotizing scleritis. With the cooperation of specialists in general medicine, examinations of the patient revealed the presence of red eye in conjunction with the dengue-associated conditions, such as fever and a decrease in the number of leukocytes and platelets, in addition to also excluding other clinical entities that could have potentially caused scleritis.

Although the pathogenic mechanism of the ocular complications associated with dengue fever remains unknown, the mechanism is considered to be an immune-mediated process rather than a direct viral infection.^[8] Recent research has shown that the infection is the actual trigger of the inflammation, including in the eye, and that this can be explained by the danger signal theory.^[11,12] Furthermore, it has also been reported that long-term persistent symptoms in dengue-infected persons are associated with alterations in immunological disorders.^[13] Since it appeared that the dengue fever infection was most likely the trigger of the inflammation of the sclera in the current case, and that the persistent scleral thinning was associated with the immunological alteration caused by the dengue fever infection, it is our belief that this should be classified as dengue fever-associated necrotizing scleritis.

As for treatment, infections in a large number of the patients found to have dengue-related ocular disease have been reported to be self-limiting and resolved spontaneously without any treatment.^[7,8] However, steroids have been used as the main treatment in patients infected by the dengue fever virus who were persistently symptomatic and had poor vision due to dengue-

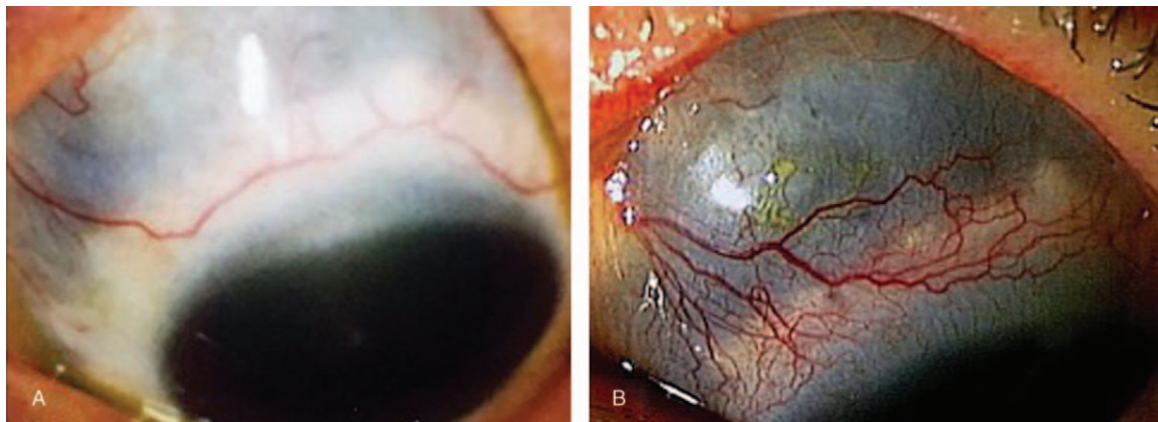


Figure 3. A, Image of the eye during treatment of the scleritis. Although there was improvement of the conjunctival and scleral injection, the appearance of a blue sclera indicated the presence of thinning of the sclera. B, Image showing the clear presence of a blue sclera. As compared to the initial images collected at the earlier visits, this image demonstrates the presence of significant thinning of the sclera that occurred over the 18 years of observation.

related ocular complications.^[8] Although the sclera initially exhibited thickening due to the inflammation in the current case, the sclera started thinning once the inflammation was cured. Our results showed that intensive steroid treatment clearly prevented the rapid thinning of sclera during the acute phase. Due to the nature of the necrotizing scleritis, we believed that failing to continue administering steroids over a longer time could potentially result in a continuation of the thinning of the sclera. Therefore, in the current case, we decided to gradually taper off the steroid dose over a 15-month period. After the scleritis began to settle down, we then stopped the use of the topical and internal corticosteroid, as there was no recurrence of the active scleritis during the follow-up period. Thus, these findings suggest that the thinning of the sclera after the steroid discontinuation was due to a change in the immune status caused by the dengue virus.

In conclusion, we report the first case of dengue fever-associated necrotizing scleritis. Dengue fever virus patients found to have red eyes need to be carefully followed and treated, as these eyes might develop necrotizing scleritis that could lead to blindness.

Author contributions

Data curation: Koju Kamoi, Manabu Mochizuki.

Investigation: Koju Kamoi, Manabu Mochizuki.

Supervision: Manabu Mochizuki, Kyoko Ohno-Matsui.

Writing – original draft: Koju Kamoi.

Writing – review & editing: Koju Kamoi, Manabu Mochizuki, Kyoko Ohno-Matsui.

References

- [1] Bhatt S, Gething PW, Brady OJ, et al. The global distribution and burden of dengue. *Nature* 2013;496:504–7.
- [2] Halstead SB. Dengue. *Curr Opin Infect Dis* 2002;15:471–6.
- [3] Rigau-Perez JG, Clark GG, Gubler DJ, et al. Dengue and dengue haemorrhagic fever. *Lancet* 1998;352:971–7.
- [4] Takasaki T. Imported dengue fever/dengue hemorrhagic fever cases in Japan. *Trop Med Health* 2011;39:13–5.
- [5] Kutsuna S, Kato Y, Moi ML, et al. Autochthonous dengue fever, Tokyo, Japan, 2014. *Emerg Infect Dis* 2015;21:517–20.
- [6] Guzman MG, Kouri G. Dengue: an update. *Lancet Infect Dis* 2002;2:33–42.
- [7] Chan DP, Teoh SC, Tan CS, et al. Ophthalmic complications of dengue. *Emerg Infect Dis* 2006;12:285–9.
- [8] Ng AW, Teoh SC. Dengue eye disease. *Surv Ophthalmol* 2015;60:106–14.
- [9] Watson PG, Hayreh SS. Scleritis and episcleritis. *Br J Ophthalmol* 1976;60:163–91.
- [10] Ratnam I, Leder K, Black J, et al. Dengue fever and international travel. *J Travel Med* 2013;20:384–93.
- [11] Caspi RR. A look at autoimmunity and inflammation in the eye. *J Clin Invest* 2010;120:3073–83.
- [12] Mochizuki M, Sugita S, Kamoi K. Immunological homeostasis of the eye. *Prog Retin Eye Res* 2013;33:10–27.
- [13] García G, González N, Pérez AB, et al. Long-term persistence of clinical symptoms in dengue-infected persons and its association with immunological disorders. *Int J Infect Dis* 2011;15:e38–43.