

Classification and Treatment of Glabella-Radix Deficiency in Primary Augmentation Rhinoplasty

Ray-Hon Chang, MD; and Yean-Lu Chang, MD

Aesthetic Surgery Journal Open Forum
2020, 1–21

© 2020 The Aesthetic Society

This is an Open Access article distributed under the terms of the Creative Commons Attribution-NonCommercial-NoDerivs licence (<http://creativecommons.org/licenses/by-nc-nd/4.0/>), which permits non-commercial reproduction and distribution of the work, in any medium, provided the original work is not altered or transformed in any way, and that the work is properly cited. For commercial re-use, please contact journals.permissions@oup.com

DOI: 10.1093/asjof/ojaa016
www.asjopenforum.com

OXFORD
UNIVERSITY PRESS

Abstract

Background: A systematic approach to treating glabella-radix deficiency is lacking, and the management of brow-tip aesthetic lines remains technically challenging.

Objectives: The authors describe implantation of a customized Gore-Tex prosthesis combined with primary augmentation rhinoplasty to address the glabella-radix deficiency.

Methods: Fifty Asian patients with glabella-radix deficiency who received implantation and primary augmentation rhinoplasty were retrospectively evaluated in an 8-year period. Patients were assigned to categories based on brow-tip contour lines and symmetry patterns, and implant dimensions were ascertained from the contour type and from simulated post-operative results.

Results: Eleven men and 39 women were included in the study; the mean patient age was 27.22 years, and mean follow-up was 22.8 months. Seven of the patients were assigned to the type I/Ia category, 24 to type II/IIa, and 19 to type III/IIIa. Forty-five patients were considered to have satisfactory surgical results, with curved, symmetric, and normally spaced brow-tip lines on front view and a smooth frontonasal transition on profile view. Complications occurred in 5 patients and included infection (1 patient), inadequate augmentation (2), and palpable margin folding of the Gore-Tex device (2).

Conclusions: Deformities of brow-tip contour lines coincide with glabella-radix deficiencies in terms of severity. Knowledge of the patterns of brow-tip lines, combined with postoperative image simulation, can help the surgeon design an appropriate glabella-radix prosthesis. When placed in conjunction with other augmentation rhinoplasty procedures, the glabella-radix implant yields sufficient, predictable nasal projection and a harmonious facial aesthetic.

Level of Evidence: 4

Editorial Decision date: April 14, 2020; online publish-ahead-of-print April 18, 2020.



The glabella-radix is a crucial aesthetic component of the face.¹ The glabella is the most prominent point of the forehead at the midline between the eyebrows. The radix is the root of the nose or the lowest point of the nasal dorsum. In Asian individuals, the radix preferably occurs at the mid-pupil line.² The aesthetic contours of the glabella-radix subunit include (1) the brow-tip lines, also known as the dorsal

Dr RH Chang is an otolaryngologist in private practice in Taipei, Taiwan. Dr YL Chang is a plastic surgeon in private practice in Taipei, Taiwan.

Corresponding Author:

Dr Ray-Hon Chang, Toyoung Cosmetic Surgery Clinic, 4th Floor, No. 72, Sec. 2, Xin-Yi Road, Taipei, Taiwan.
E-mail: chang157@gmail.com

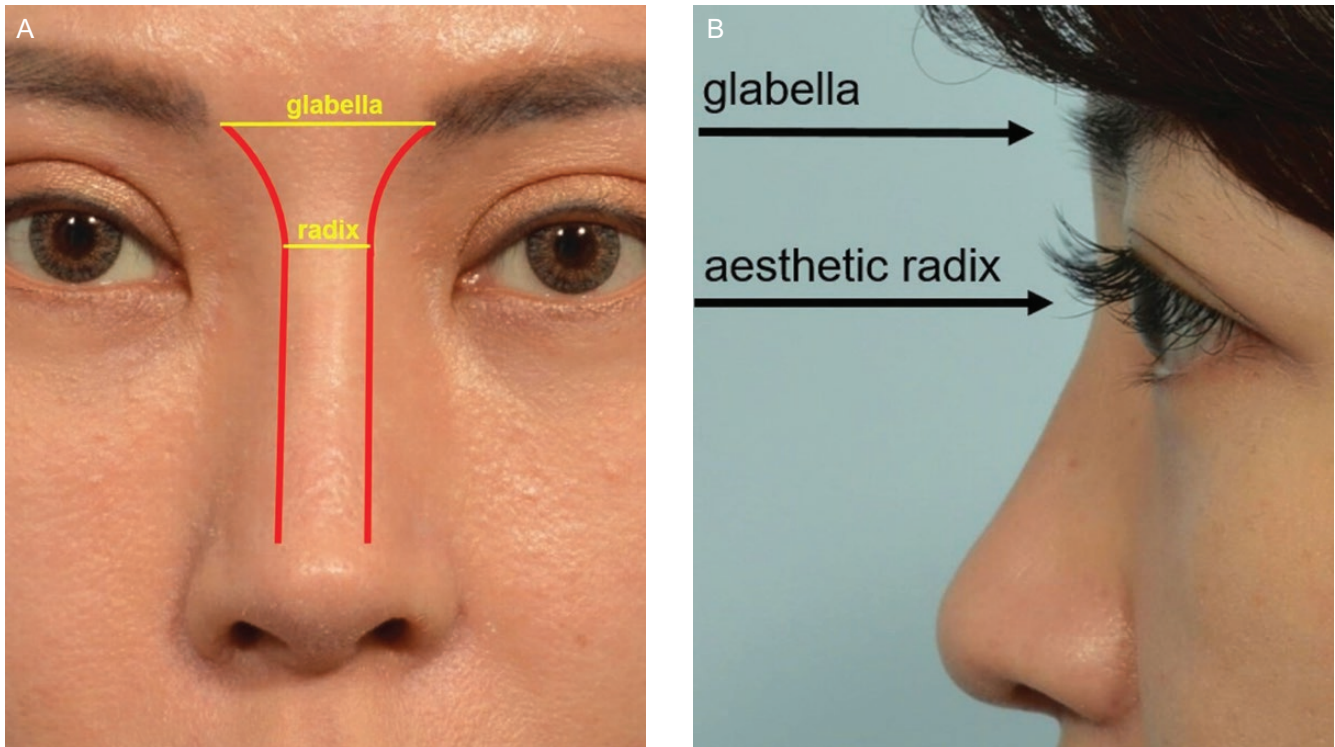


Figure 1. (A) The glabella and radix, as specified in this study and shown in this 33-year-old woman. The glabella is the most prominent point on the forehead at the midline between the eyebrows. The radix is the root of the nose. We define the glabella-radix subunit as the area above the nasal root and between the eyebrows. (B) The aesthetic nasal radix is the lowest point of the nasal dorsum as depicted in this 28-year-old woman, occurring at the mid-pupil line in Asian patients.

aesthetic lines²; (2) the softly curving forehead-dorsum transition (Figure 1); and (3) the aesthetic nasofrontal angle, which should be 135° to 140°.³ In the literature, investigators refer to the glabella-radix region in various terms, including the glabella,^{4,5} the central brow,⁶ the forehead/glabella/radix complex,⁷ and the radix.⁸⁻¹¹ In this study, we apply the terminology of Lee et al¹ and Naini,¹² who described “nasal aesthetic subunits” in 2011 and define the glabella-radix subunit as spanning the frontal bone above the radix and between the eyebrows.

Sheen and Sheen⁸ and Constantian¹¹ were among the first to demonstrate that a low glabella-radix area produces a structural imbalance of the nose. In patients with this anatomic variant, the upper nose appears disproportionately small compared with the lower nose. Augmenting the radix height extends the dorsal line, bringing it into proportion with the nasal base, even though tip projection is increased. Sheen¹³ described 3 favorable outcomes of increasing the radix height: (1) minimizing dorsal convexity, (2) preserving skeletal structure, and (3) diminishing the apparent projection of the nasal base. However, the challenges of correcting this deficient area are readily apparent,¹⁴ and as demonstrated by Constantian,¹¹ affected patients are predisposed to unfavorable results of rhinoplasty.

Among Asian patients in our practice, a common presenting concern is deficiency within the glabella-radix area and its extension into the dorsum. Treatment of glabella-radix hypoplasia should not be undertaken in isolation; instead, the glabella, radix, and dorsal limbs of the nasofrontal angle should be regarded as a congruous anatomic unit. The position of the radix affects the balance of the nasal contour and the length of the nose. Displacement of the radix position cephalically or caudally will lengthen or shorten the nasal bridge, respectively. The combination of a wide nasal base and an underprojected or caudally positioned radix yield a so-called bottom-heavy nose, in which the cephalic one-third and the caudal one-third of the nose are unbalanced. A low radix also may produce a pseudo-hump appearance on profile view.¹⁵

Brow-Tip Aesthetic Contour Lines

In an aesthetically pleasing nose, brow-tip contour lines appear symmetric, gently blended, and uninterrupted. The glabella-radix subunit determines the contour of these dorsal lines.¹² A glabella-radix deficiency results in variable, inharmonious patterns of brow-tip lines. A break or deviation in the brow-tip lines produces a cosmetically undesirable expression of anger or worry.¹⁶ Therefore, appropriate

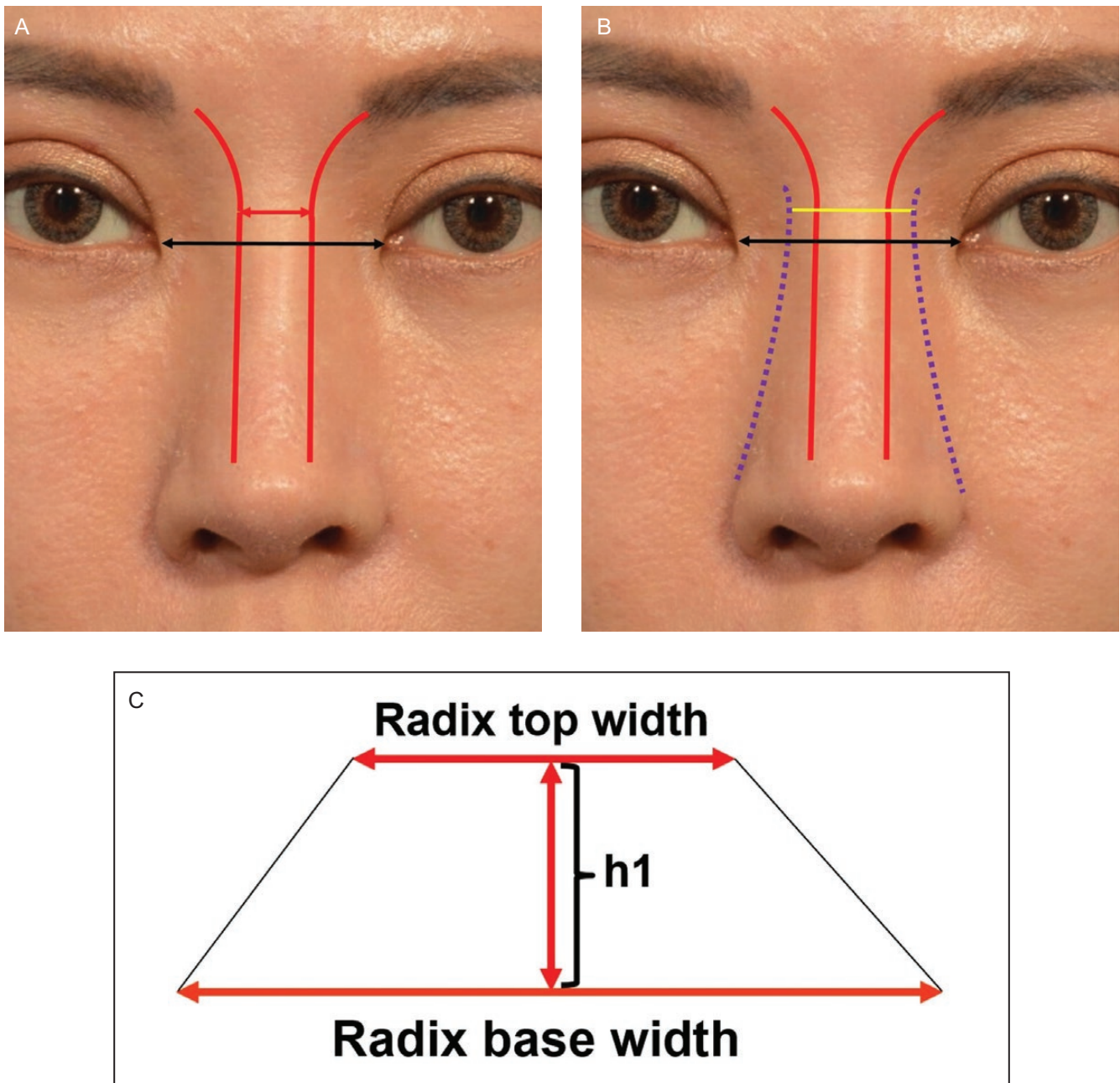


Figure 2. In this 28-year-old woman, the key features of 2-dimensional nasal radix were illustrated. (A) The ideal top width of the radix (red arrow) is approximately one-third of the intercanthal distance (ICD; black arrow), usually 10 to 12 mm. (B) The radix base width (yellow bar) is the distance between the nasal baselines (purple dotted lines, between the nasal pyramid and cheek on each side) and is approximately two-thirds of the ICD (black arrow). (C) Geometric depiction of a 2-dimensional axial cross section of the nasal radix. h1, radix height.

management of the glabella-radix aesthetic subunit is vital to achieving an attractive, harmonious nose.

Size of the Glabella-Radix Subunit

The 3-dimensional topology of the radix can be conceptualized as a trapezoid, with a top width and a base width.¹⁷

On the frontal view, the ideal top width is approximately one-third of the intercanthal distance (ICD)¹² and corresponds to the supraorbital curve of the brow-tip aesthetic lines. The base width of the radix is the distance between the nasal baselines (ie, the borderline between the nasal pyramid and cheek) and is approximately two-thirds of the ICD (Figure 2).^{2,12}

A glabella-radix deficiency results in an inharmonious nose shape; however, we have noticed that Asian patients who present to our clinic for augmentation rhinoplasty do not often point out the glabella-radix subunit as a cosmetic concern. Augmentation rhinoplasty with little or no correction of a deficient glabella-radix subunit can yield an “operated” appearance.¹⁰ In *Rhinoplasty: An Atlas of Surgical Techniques*, published in 2002, Daniel¹⁵ asked, “Why do most surgeons ignore the radix area in their preoperative planning and operations, when the final result can be seriously downgraded by this error of omission?” The author posed 3 possible reasons: (1) a lack of awareness about the importance of the glabella-radix area (especially the brow-tip aesthetic lines) for dictating aesthetic angles and proportional relationships of the nose; (2) an inability to geometrically analyze this area; and (3) a lack of confidence or experience in the management of radix height.¹⁵ Since then, little progress has been made toward systematically analyzing the nose and glabella-radix region to address cases of the glabella-radix deficiency. Herein, we describe a method of categorizing the glabella-radix deficiency and designing a customized Gore-Tex (ie, expanded polytetrafluoroethylene [ePTFE]; W.L. Gore & Associates, Flagstaff, AZ) implant. We report our findings in a series of Asian patients with glabella-radix deficiency who underwent this technique and augmentation rhinoplasty.

METHODS

Patients and Study Design

From February 2011 to February 2019, 50 Asian patients with glabella-radix deficiency who received treatment with Gore-Tex implantation combined with primary augmentation rhinoplasty were evaluated in a retrospective study. Exclusion criteria were previous nasal procedures, such as fat grafting or placement of non-dissolvable fillers, performed solely to reshape the nose. Patients who previously received hyaluronic acid in the glabella-radix region were included in the study but were treated with topically injected hyaluronidase 2 weeks before surgery. All included patients presented with a depression in the glabella-radix subunit, confirmed by physical examination, photographic analysis, and computer simulation. The patients were assigned to categories based on patterns of brow-tip contour lines: I, too widely spaced; II, normally spaced; and III, too narrowly spaced, angulated, or missing. When asymmetry also was present, the designator “a” was added, as in type Ia, type IIa, and type IIIa (Figure 3).

This study was approved by the ethics board of our clinic and was conducted in accordance with principles set forth in the Declaration of Helsinki. Approval from an Institutional Review Board was not required because all

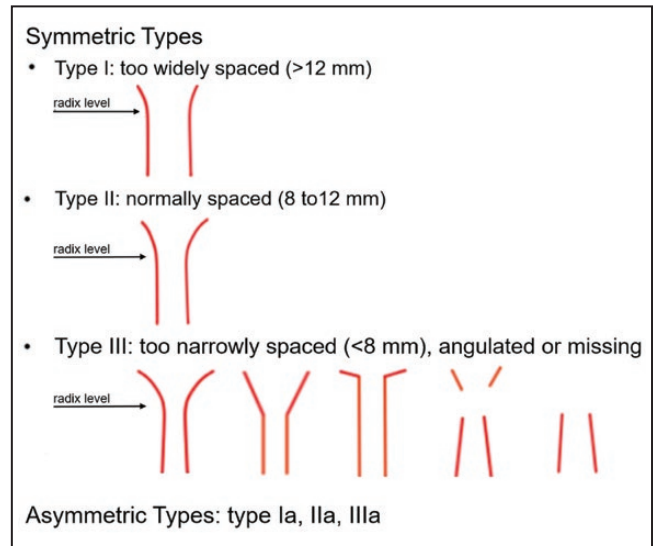


Figure 3. Types of brow-tip lines. More severe glabella-radix deficiency is associated with more deformed brow-tip lines. The pattern of types III and IIIa involves severe glabella-radix hypoplasia resulting in too narrowly spaced, angulated, or deficient brow-tip contour lines in the glabella-radix area.

products utilized were indicated for rhinoplasty. All patients in the study gave informed consent for the surgical procedures and to have their photographs published in the medical literature or for instructional purposes.

Preoperative Evaluation

Patients were photographed in the so-called natural head position¹⁸ in an upright posture with the visual axis at the horizontal plane. The eyelashes on each side were positioned in the same axial and coronal planes. Frontal and profile photographic views were uploaded to image analysis software (Mirror Medical Imaging, Canfield Scientific, Fairfield, NJ), and a simulation was run to assess the nasal surface and predict a surgically achievable outcome (Figure 4). Our aim was not to arrive at the best possible result, but rather to provide a simulated postoperative image that we could realistically achieve with augmentation rhinoplasty. Patients were asked to rank their preferences of various nasal root positions from a series of their simulated surgical outcomes, and the preferred image was superimposed on the preoperative photograph. The added nasal projection distances in the simulated outcome were measured along the frontonasal profile contour (ie, the glabella, radix, dorsum, and tip) to determine the implant thickness needed for augmentation. The simulated image in frontal view was utilized to estimate the size of the implant needed to achieve the planned top width and base width of the radix (Figure 4).

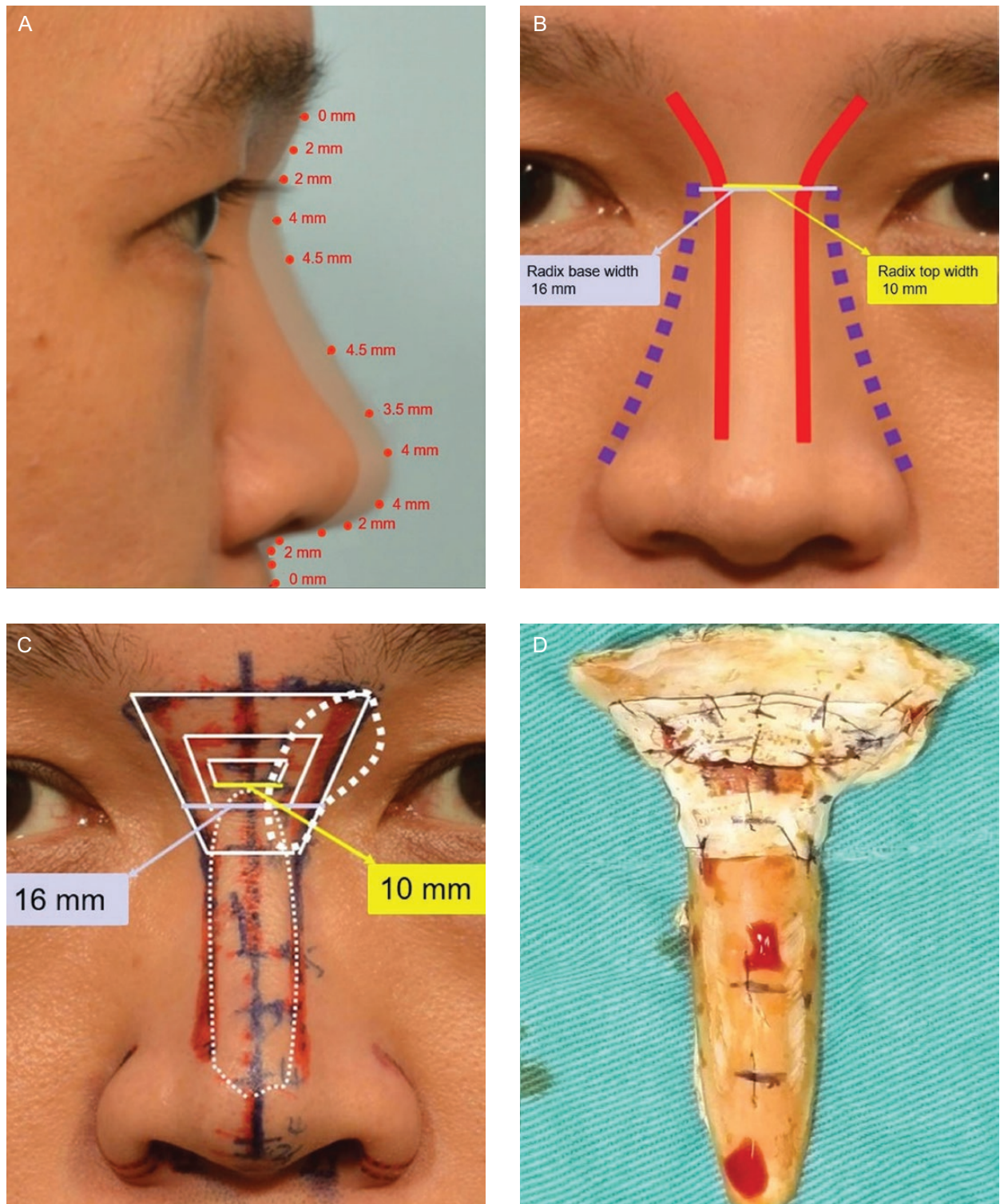


Figure 4. This 37-year-old man presented with type IIIa severe asymmetric hypoplasia of the glabella-radix region and requested rhinoplasty. (A) Results of a photographic simulation (superimposed on the preoperative photograph) confirmed the diagnosis. The aesthetic frontonasal contours were evaluated to determine the thickness of the implant required for augmentation rhinoplasty with Gore-Tex (ie, expanded polytetrafluoroethylene [ePTFE]). (B) Simulated image depicting the planned radix top width and base width. (C) Preoperative markings. The overlain illustration shows portions of the Gore-Tex implant: glabella-radix (white lines), dorsal (smaller dotted lines), and an additional piece to address asymmetry (larger dotted lines). The planned top width of the radix is 10 mm, and the base width is 16 mm. (D) The composite dorsal-glabbellar prosthesis (prepared from Gore-Tex and ePTFE-coated silicone) soaked in betadine solution and ready for implantation. (E, G, I, K) Preoperatively and (F, H, J, L) 3 years postoperatively. The patient was satisfied with the surgical results, and the investigators rated the outcome as “greatly improved.”

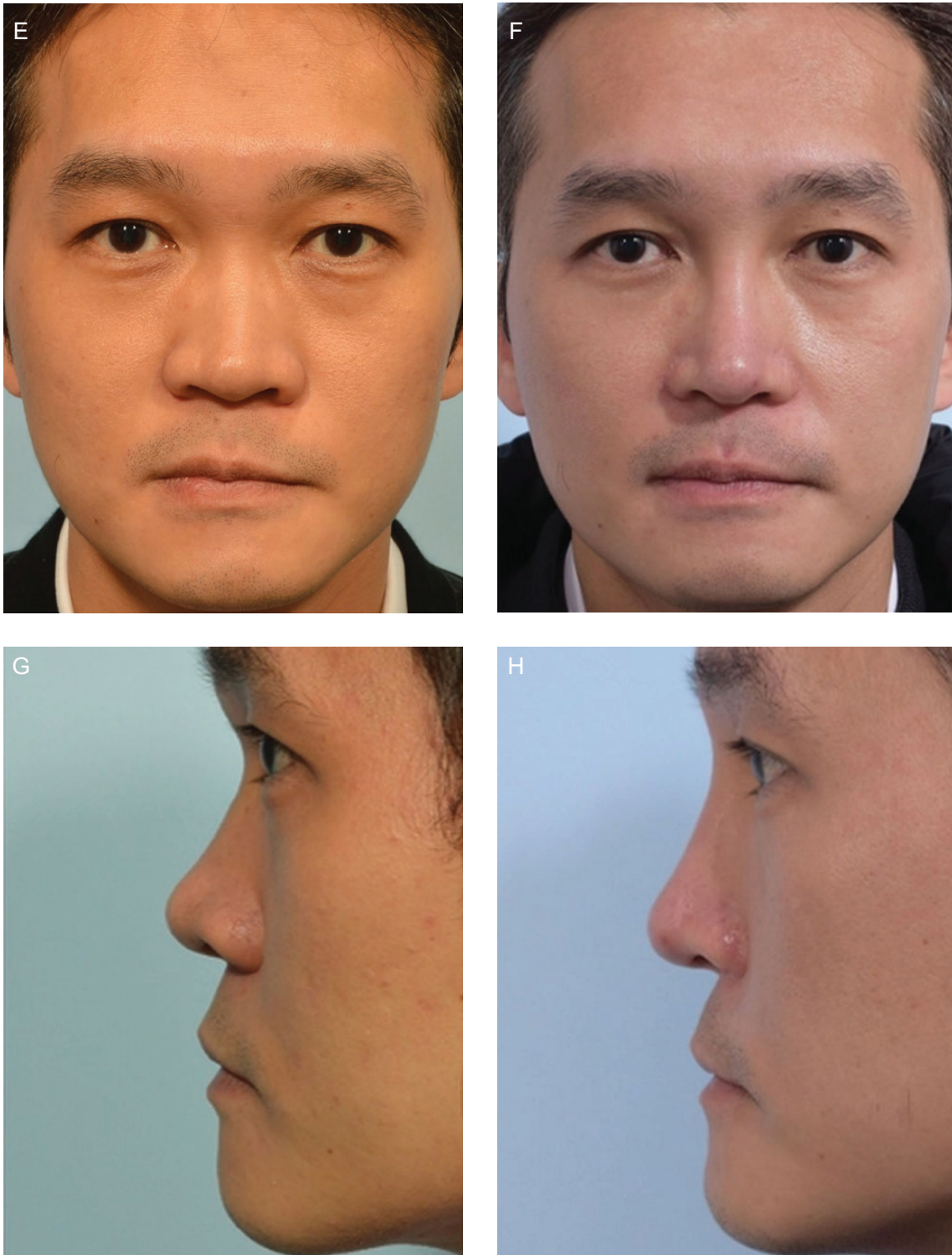

Figure 4. Continued.

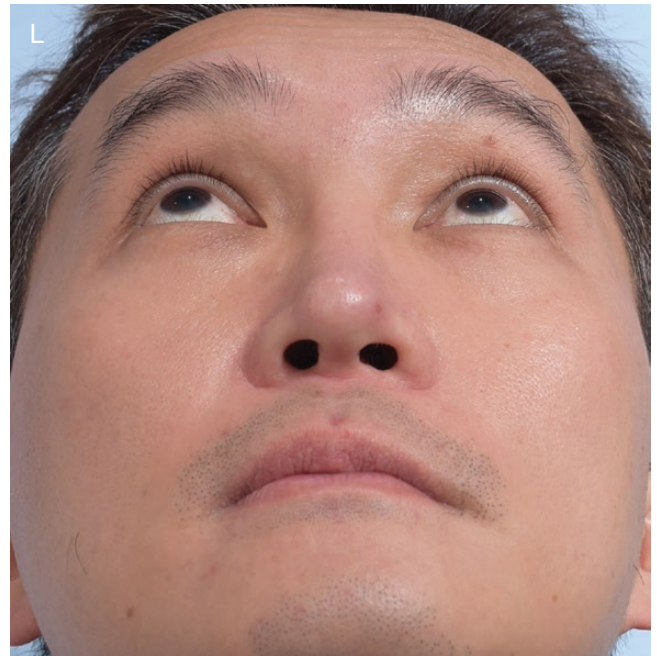
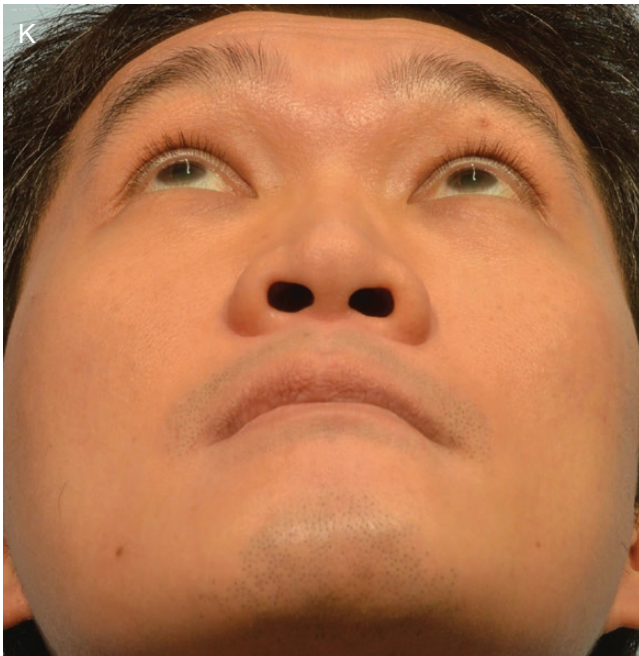
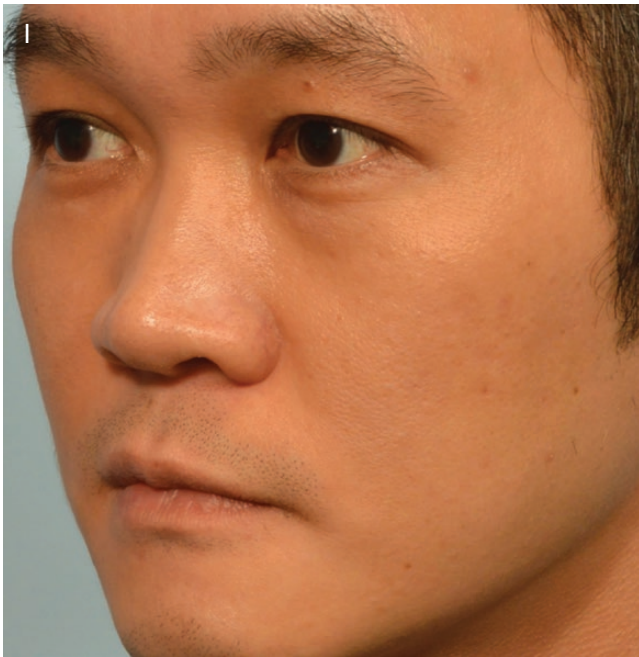Figure 4. Continued.

Implant Design

A Gore-Tex implant was prepared according to the planned projection lengths and radix dimensions determined in the simulation. One or more layers of soft Gore-Tex sheets were compressed (original thickness of 1 Gore-Tex sheet, 2 mm; compressed thickness, 1 mm) and sutured together.

For patients with nasal asymmetry, an additional piece of Gore-Tex (thickness, 0.5-1.0 mm) was sutured to the prosthesis on the more deficient side (Figure 4C,D). The implant then was trimmed to the desired shape. To achieve a smooth nasal contour, the Gore-Tex prosthesis was sutured to ePTFE-coated silicone (Implantech, Ventura, CA), as described previously.¹⁰

Surgical Procedures

All surgical procedures were conducted under general anesthesia, induced intravenously. Utilizing an open approach, the nasal skin envelope was undermined, and structural rhinoplasty procedures were carried out by standard techniques.¹⁹ The prosthesis, comprising Gore-Tex and ePTFE-coated silicone, was secured with suspension guiding sutures (4-0 nylon; Unik Surgical Sutures Mfg. Co., Taiwan, ROC).¹ Immediately after the operation, thermoplastic splinting was applied to the glabella-radix-dorsal area and left in place for 1 week. Two doses of perioperative antibiotics (cephazolin, 1000 mg) were administered intravenously, and patients were given oral antibiotics (augmentin or levofloxacin) for 7 days.

Postoperative Assessment

Patients were monitored 3 and 6 months postoperatively and at 6-month intervals thereafter. Patients who resided outside Taiwan were monitored by e-mail. At follow-up visits, patients were photographed, given a clinical examination, and asked to rate the surgical results as “satisfied,” or “unsatisfied” (which was regarded as requiring revision).

In addition, the investigators evaluated aesthetic improvement at the 6-month follow-up visit. Results were scored as “greatly improved,” “improved,” or “fair” according to the criteria in [Table 1](#). Specifically, patients in whom the brow-tip aesthetic lines were properly spaced and gently curved at the glabella-radix area were considered to have “greatly improved” results. Results of narrowly spaced or slightly angulated dorsal aesthetic lines were scored as “improved,” and the results needing revisional surgery were rated as “fair.”

RESULTS

A total of 11 men and 39 women were evaluated. The mean patient age (\pm standard deviation [SD]) was 27.22 (\pm 5.39) years (range, 18-42 years), mean follow-up time (\pm SD) was 22.8 (\pm 19.67) months (range, 6-96 months), and mean amount of radix augmentation (\pm SD) was 2.72 (\pm 1.18) mm (range, 1-8 mm). Seven of the 50 patients were assigned to the type I/Ia category, 24 to type II/IIa, and 19 to type III/IIIa ([Table 2](#)).

All patients underwent implantation and structural rhinoplasty procedures to augment the glabella-radix subunit and achieve a more attractive nose. Type I/Ia patients underwent augmentation with a relatively small Gore-Tex implant to the glabella-radix region, type II/IIa patients were treated with a slightly wider implant, and type III/

Table 1. Criteria of Aesthetic Evaluation

Scale	Implant edges	Patterns of brow-tip lines
Greatly improved	Invisible	Curved, normally spaced, uninterrupted
Improved	Invisible	Slightly narrowly spaced, mildly angulated
Fair	Visible	Infection or inadequate radix height

IIIa patients received a much wider prosthesis ([Table 3](#)). Surgical success was defined as achievement of curved brow-tip aesthetic lines on frontal view and a softly curving transition of the frontonasal profile, without the need for a subsequent procedure to further revise the glabella-radix contour ([Table 1](#)).

Forty-five of the 50 patients (90%) expressed satisfaction postoperatively. Representative images of patients who rated their results as satisfactory are shown in [Figures 4-7](#). These patients were rated as “greatly improved” ($n = 38$ patients [76%]) ([Figures 4, 5, and 7](#)) or “improved” ($n = 7$ [14%]) ([Figure 6](#)) by the investigators. Five patients (10%) rated their results as unsatisfactory and requested revisional procedures; these patients had results scored as “fair” (ie, needing revision) by the investigators. Representative images of a “fair” case are shown in [Figure 8](#). Of these 5 patients, 1 experienced infection, 2 had palpable folding of the Gore-Tex implant margin, and 2 indicated that the radix height was inadequate postsurgically ([Table 2](#)). The patient with infection underwent implant removal and revisional augmentation surgery, and those with palpable folding of the implant margin were treated by scraping the folded Gore-Tex edge with an 18-gauge needle in a direction perpendicular to the edge.

Of the 2 patients with inadequate augmentation, 1 received a second-stage operation in which additional radix height was achieved ([Figure 8](#)). The other patient had retrusive forehead contour preoperatively and received glabella-radix-dorsal augmentation as the primary surgery. She subsequently presented for forehead augmentation in a separate session. Following this, the patient expressed concerns that the nasal dorsum and radix appeared depressed compared with the enhanced forehead. Therefore, the patient underwent a third operation to further augment the glabella-radix-dorsum. Based on this case, the investigators suggest the following approach for treating patients with retrusive forehead contour who wish to receive glabella-radix-dorsum augmentation: (1) simultaneous enhancement of the forehead and glabella-radix-dorsum or (2) augmentation of the forehead followed by enhancement of the glabella-radix-dorsum in a second session. No other complications, including extensive hemorrhage,

Table 2. Patient Profiles and Surgical Outcomes

		Implant thickness, mm					Results		
		1	2	3	4	8	Greatly improved, no. (%)	Improved, no. (%)	Fair, no. (%)
No. of patients	50	5	22	13	9	1	38 (76)	7 (14)	5 (10)
Gender ratio (M:W), n (%)	11:39 (22:78)	5	22	13	9	1	38 (76)	7 (14)	5 (10)
Age (mean \pm SD), y	27.22 \pm 5.39	5	22	13	9	1	38 (76)	7 (14)	5 (10)
Follow-up (mean \pm SD), mo	22.8 \pm 19.67	5	22	13	9	1	38 (76)	7 (14)	5 (10)
Augmentation at radix (mean \pm SD), mm	2.72 \pm 1.18	5	22	13	9	1	38 (76)	7 (14)	5 (10)
Symmetry type, n (%)	30 (60)	2	15	8	5	0	23	4	3
Asymmetry type, n (%)	20 (40)	3	7	5	4	1	15	3	2
Type I + Ia, n (%)	5 + 2, 7 (14)	0	4	2	1	0	6	0	1
Type I + IIa, n (%)	13 + 11, 24 (48)	5	10	5	4	0	22	0	2
Type III + IIIa, n (%)	12 + 7, 19 (38)	0	8	6	4	1	10	7	2

M:W, men:women; SD, standard deviation.

Table 3. Recommendations for Implant Design

	Type I/Ia	Type II/IIa	Type III/IIIa
Distance of brow-tip lines at radix level	Too widely spaced	Normally spaced	Too narrowly spaced
Brow-tip line shape	Curved	Curved	Curved, angulated, or missing
Nasal profile and radix concavity	Shallow or depressed	Shallow or depressed	Shallow or depressed
Recommended implant size: top width of radix, mm	8 \pm 1	9 \pm 1	Approximately 8-12
Recommended implant size: base width of radix, mm	Option 1: simulation-assisted design		Option 1: simulation-assisted design
Recommended implant size: base width of radix, mm	Option 2: 1/3 the ICD or 10-12 mm		Option 2: (A \times h1 + B \times h2)/H

A, top width of radix implant; B, base width of radix implant; H, total radix height (ie, preoperative radix height + radix augmentation amount); h1, original radix height; h2, augmentation amount at radix level; ICD, intercanthal distance; SD, standard deviation.

prolonged edema, or implant extrusion, occurred during the follow-up.

DISCUSSION

Photographic Simulation

In our practice, we perform photographic analysis and simulation routinely to assess the spacing of the brow-tip aesthetic lines. We only show patients the simulation results that we believe we can achieve surgically. The simulated images help the patient visualize the postoperative aesthetic and guide our design and preparation of the implant. We utilize the simulated result along with

preoperative photographs to determine the implant dimensions (eg, top width and base width of radix, implant length, and contour lines) (Figures 4A, 5B, and 7C).

Implant Materials

Numerous implant materials have been described to treat the glabella-radix deficiency, including hydroxyapatite⁴ and grafts made from cartilage,⁵ autologous fat,⁷ and mastoid periosteum with bruised cartilage underlay.⁹ These materials have certain limitations and often yield suboptimal results.¹⁵ We avoid placing grafts of solid septal cartilage because this material can become visible through the skin over time.¹⁵ In addition, we have found fixation of solid septal cartilage

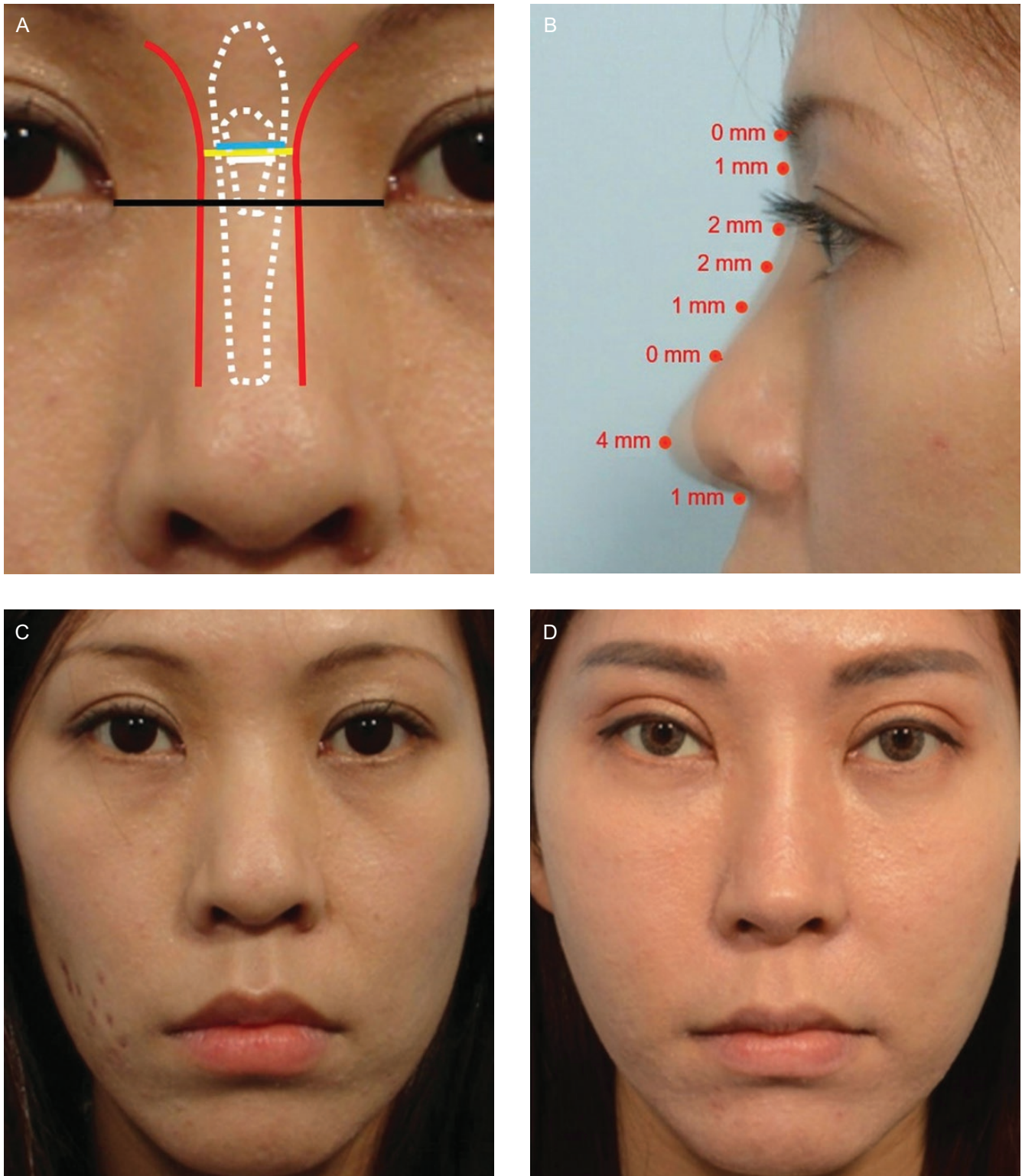


Figure 5. (A) This 30-year-old woman presented with a type I pattern of brow-tip lines (yellow line, radix top width [14 mm]) and received a small implant comprising 2 layers of Gore-Tex (larger area circumscribed by white dotted line, implant base dimension; smaller area, implant top dimension; white line, implant radix top width [9 mm]; blue line, implant radix base width [10 mm]; black line, ICD [35 mm]). (B) Photographic simulation (superimposed on preoperative photograph) depicting amounts of augmentation needed. The length of radix augmentation is 2 mm. (C, E, G, I) Preoperatively. In the same surgical session as the implantation, the patient also underwent several rhinoplasty procedures: double-level nasal osteotomy, autogenous costal spreader grafting, columella strut grafting, chimera dorsal augmentation, and tip plasty. The patient was satisfied with her surgical results, and the investigators rated the outcome as “greatly improved.” (D, F, H, J) Two years postoperatively.

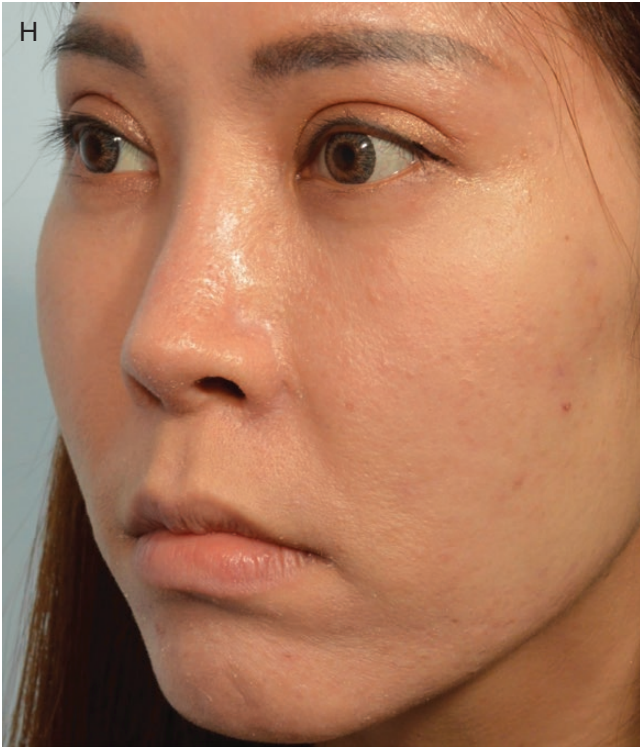
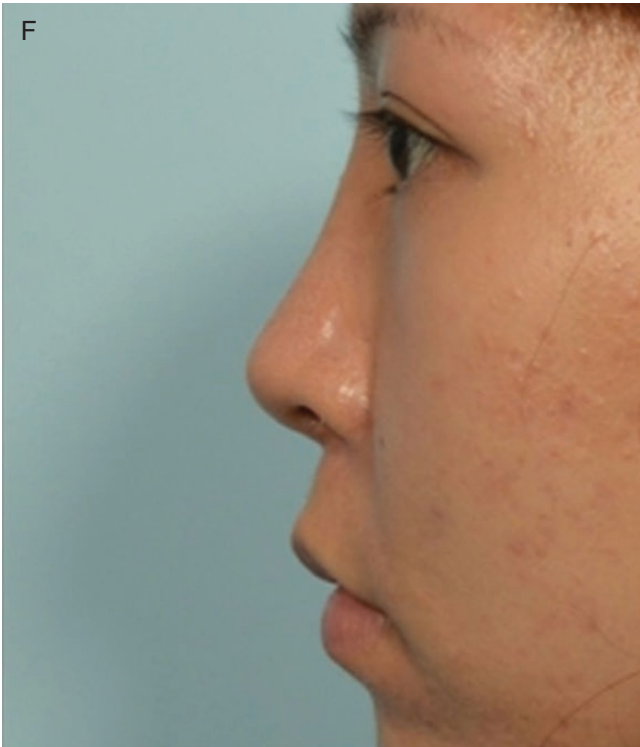
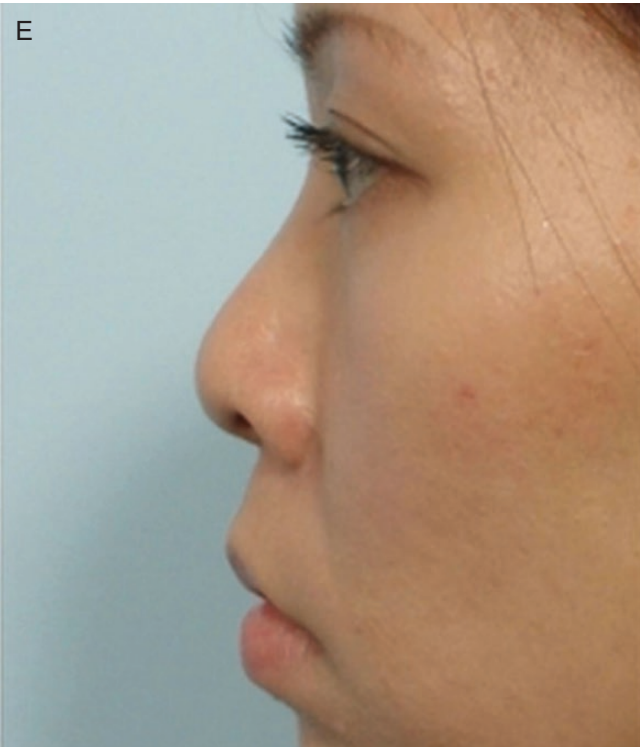Figure 5. Continued.

to be difficult, occasionally leading to the displacement of the graft and need for complex revisional surgery. Daniel¹⁵ described the placement of diced cartilage in fascia grafts,

and we have found that this procedure is not associated with graft visibility postoperatively. However, diced cartilage does not permit detailed recontouring of the brow-tip aesthetic

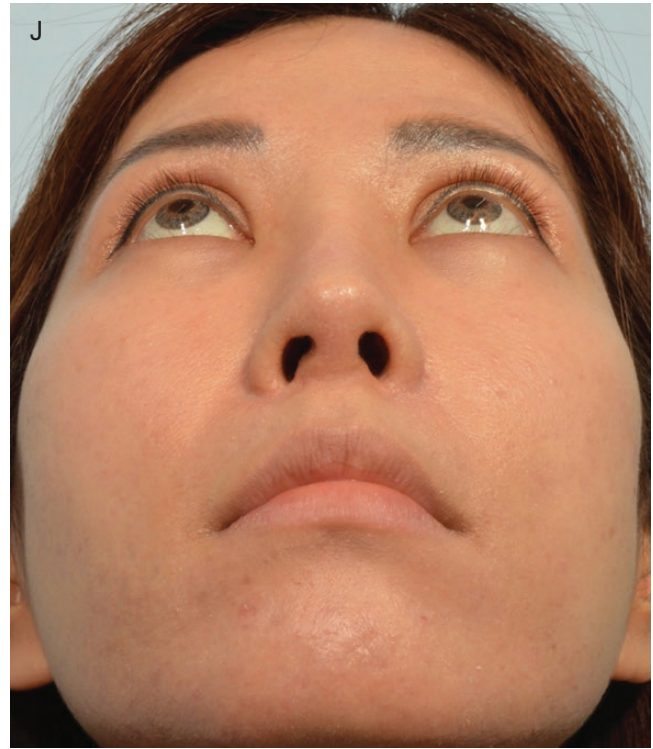
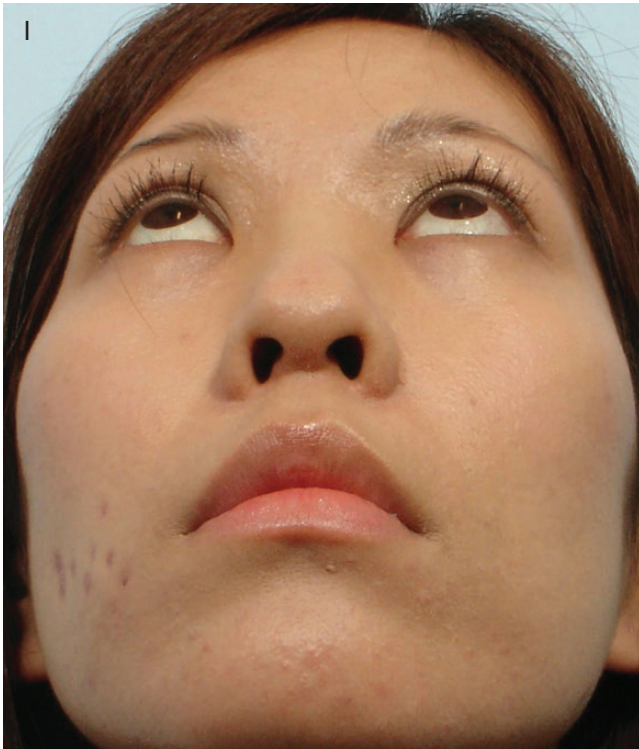
Figure 5. Continued.

lines.^{14,15} Similarly, autologous fat grafting does not allow for precise contouring, and the survival rate of grafted adipose tissue can be unpredictable. Placement of hyaluronic acid filler is temporary, and the patient must return for periodic maintenance injections. Silicone implants are not pliable enough to fit the curvature of the glabella-radix region. In light of these limitations, we performed augmentation with Gore-Tex. In the current study and others,^{1,10} Gore-Tex implantation has been shown to yield reliable, enduring results.

Classification

The brow-tip aesthetic line refers to the contour that begins at the inner eyebrow and follows the lateral nose to the nasal tip. A contour defect can attract negative attention to the nose. On the frontal view, a deficient glabella-radix subunit results in reduced shadows on the nasal sidewalls, less visible brow lines, and a flattened or faded appearance in this area. The goal of glabella-radix augmentation is to add structure, thereby creating more noticeable shadows and more prominent contours. When managing the glabella-radix region, careful attention must be given to the relationships among certain aesthetic subunits. The brow-tip lines are more deformed in the presence of a more severely hypoplastic glabella-radix subunit; defects of the brow-tip lines are

especially apparent in patients with type III/IIIa glabella-radix deficiency (Figure 3).

Determination of the Top and Base Widths of the Radix Implant

We have been performing photographic simulation for more than 15 years, and we have found that our technique allows us to precisely determine the implant dimensions—especially the top width and base width of the radix implant. For rhinoplasty surgeons who are not comfortable applying photographic simulation, we have summarized our recommendations for implant design in Table 3.

For patients with type I/Ia glabella-radix deficiency, we advocate preparing an implant with the following radix dimensions: top width, approximately 8 ± 1 mm; base width, either one-third the ICD or approximately 10 to 12 mm. For patients with type II/IIa deficiency, the radix implant should have a top width of approximately 9 ± 1 mm and a base width of approximately 10 to 12 mm, as in type I/Ia (Table 3). For patients with type III/IIIa deficiency, we prefer a radix top width of 8 to 12 mm; specifically, we recommend a top width of 10 to 12 mm for men and 8 to 10 mm for women. It can be challenging to determine the base width of the radix implant in patients with type III/IIIa deficiency. We start by defining the radix height as the distance from the corneal plane to

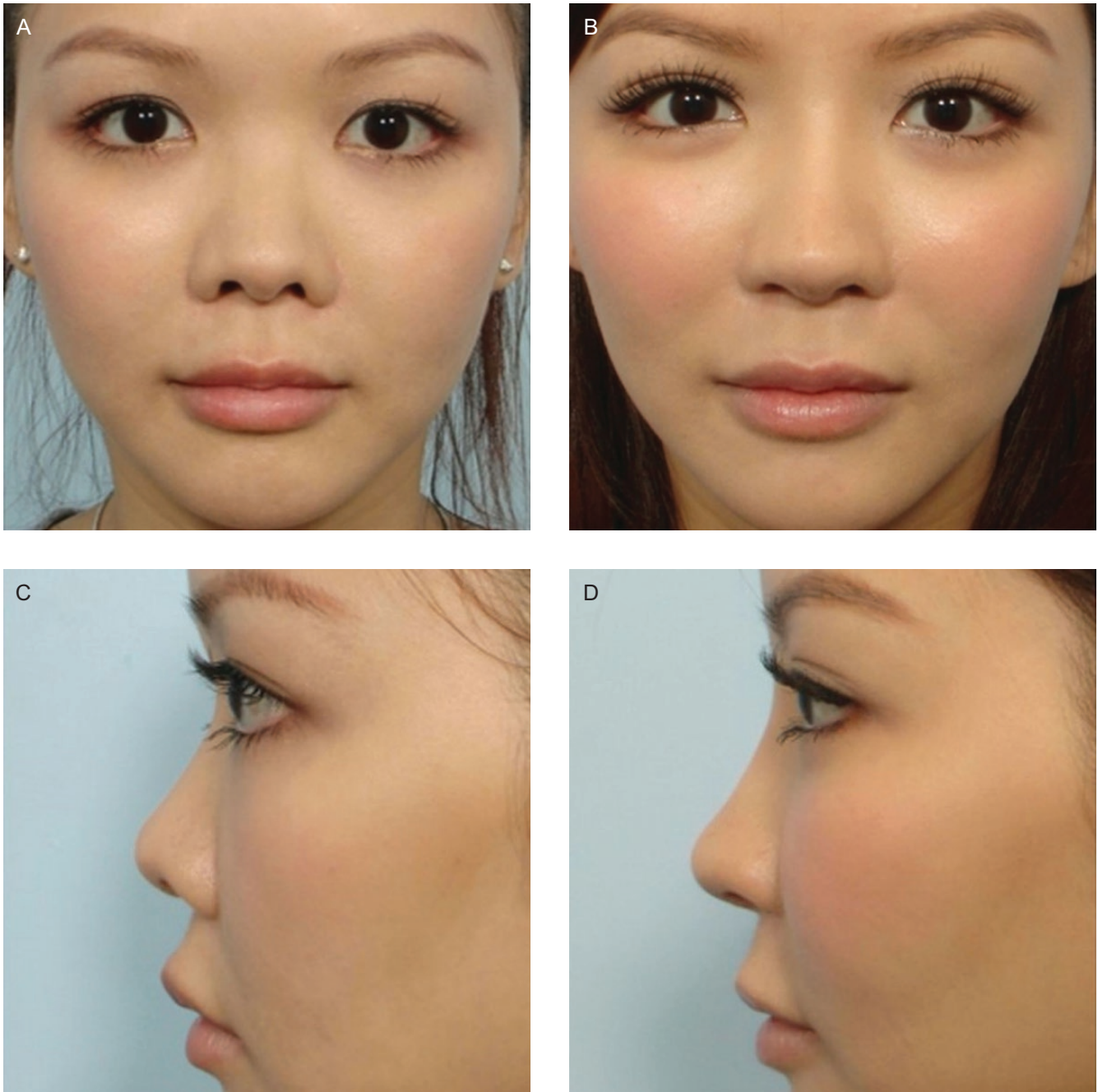

Figure 6. (A, C, E, G) This 35-year-old woman presented with a type III pattern of brow-tip lines and underwent nasal osteotomy, placement of an irradiated homologous costal spreader graft, columella strut grafting, chimera dorsal augmentation, and tip plasty as well as implantation of a glabella-radix prosthesis that later was determined to be smaller than needed, although the patient indicated that she was satisfied with the surgical results. Her results were rated as “improved” by the investigators. (B, D, F, H) Three years postoperatively, the brow-tip lines are narrowly spaced.

the radix plane (Table 3; Figure 7B).^{20,21} Other investigators²² have determined that the appropriate ratio of nasal length to radix height in Asians is 2:0.28 (± 0.11). That is, the radix height should be approximately one-fifth to one-tenth of the nasal length²² (measured along the dorsum from the radix to the point of intersection with a line from the nasolabial

angle).²³ To obtain the radix base width of the implant, we apply the equation $(A \times h1 + B \times h2)/H$, where $h1$ is defined as the preoperative (or original) radix height, A is the top width of the radix implant, $h2$ is the radix augmentation amount, B is the base width of the radix implant (and is approximately two-thirds of the ICD), and H is the total radix height (ie, the

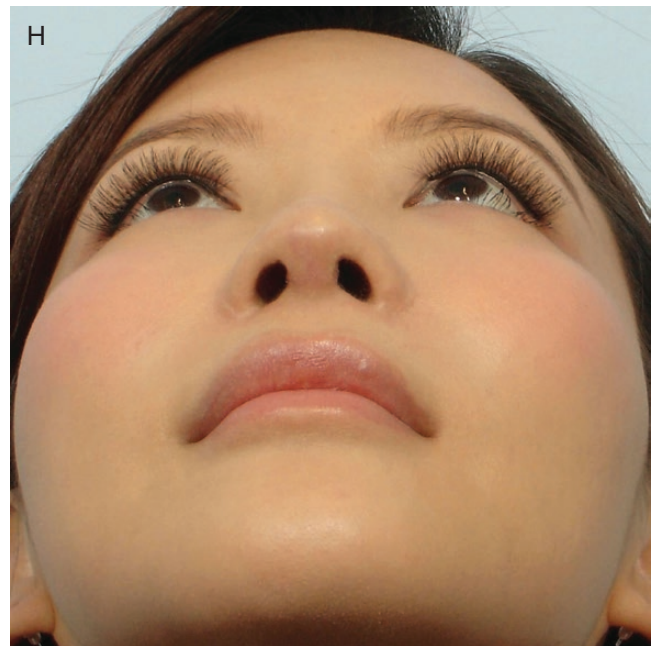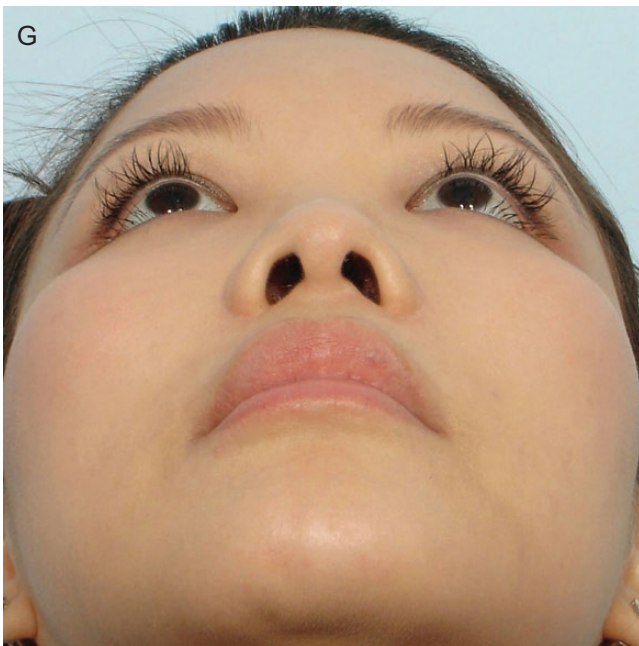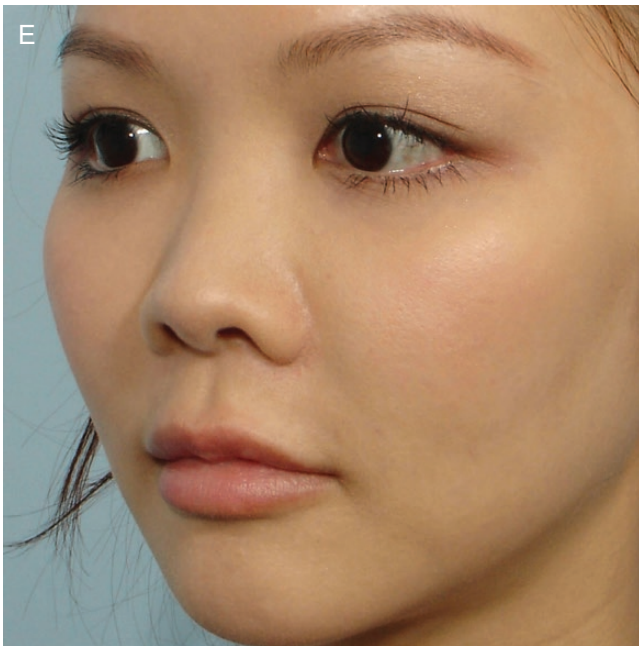


Figure 6. Continued.

preoperative radix height + the radix augmentation amount) (Table 3; Figure 7A).

Advantages of Combined Correction

When an implant is placed to augment the lower dorsum in the setting of a glabella-radix deficiency, the surgeon

must simultaneously correct both defects to produce an attractive nasal aesthetic. By our technique of placing an implant as part of the primary augmentation surgery, deeper shadows can be created along the nasal sidewall, and harmoniously smooth, unbroken, gently curved, and symmetric brow-tip contour lines can be produced in a single stage.

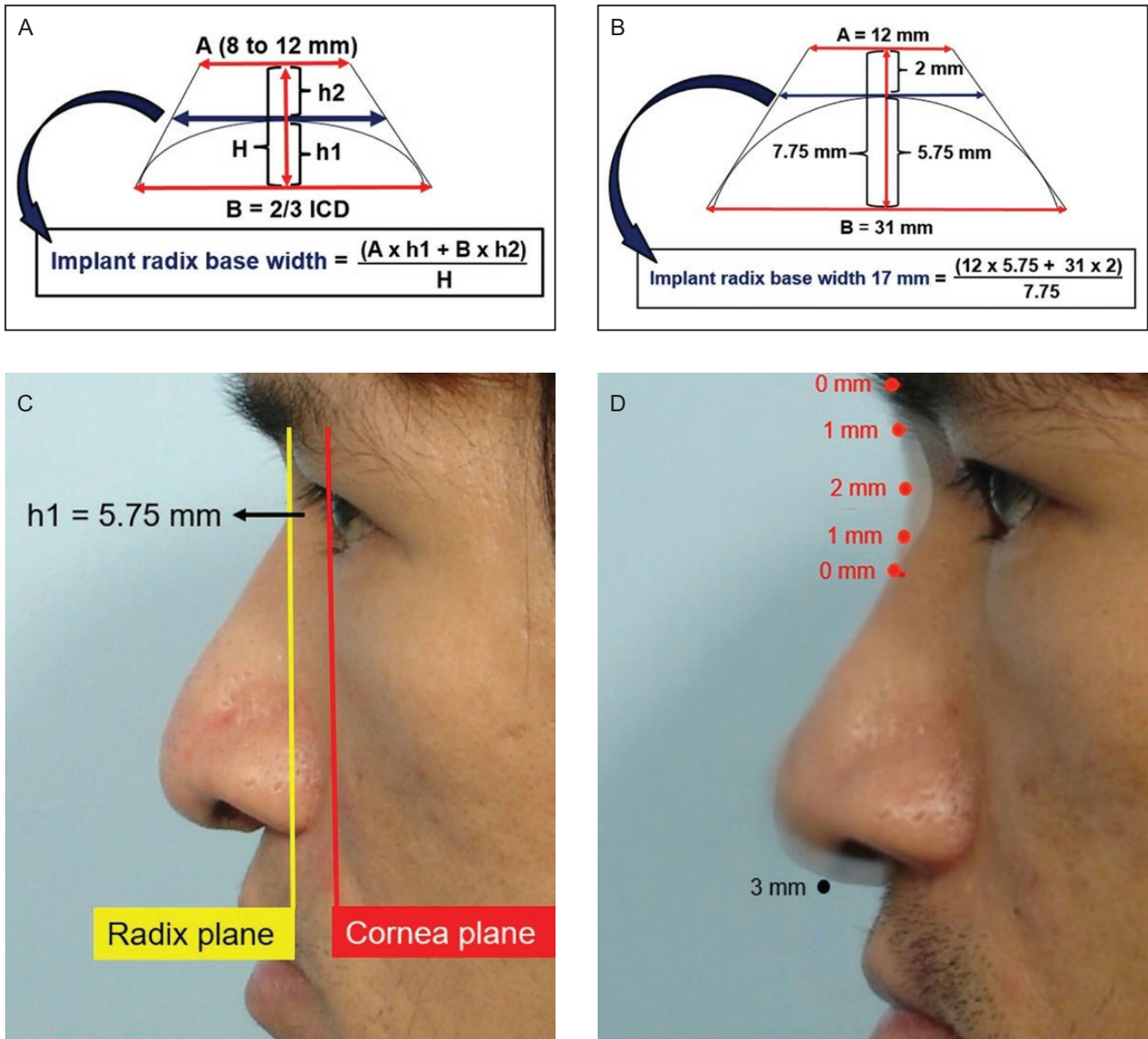


Figure 7. (A) Equation and schematic for calculating the implant radix base width. h2, length of radix to be augmented; h1, radix height (distance between the corneal plane and the radix plane); ICD, intercanthal distance. (C) Calculation of the implant radix base width in this 30-year-old man who presented with a glabella-radix deficiency. Preoperatively, the radix height (h1; ie, the distance between the corneal plane and the radix plane) was 5.75 mm. (D) Results of a photographic simulation confirmed the diagnosis. Red dots and numbers indicate areas needing augmentation; black dot and number indicate area requiring reduction; the length of radix augmentation (h2) is 2 mm. (G) Results of a physical examination and photographic analysis conducted preoperatively indicated a type III angulated pattern of brow-tip lines with an ICD of 46 mm and hence a radix base width of 31 mm (ie, 46 mm × 2/3). Taking into account that the patient is a man with a large nasal tip, the radix top width of the implant was prepared to the upper limit of normal: 12 mm. (B) Determination of the radix base width of the implant for this patient. (E, H, J, L) Preoperatively. (F, I, K, M) Four years postoperatively, the brow-tip lines are attractive and harmonious. Note the smoothly curved frontonasal transition on profile view. The patient indicated that he was satisfied with the surgical result, and the case was scored as “greatly improved” by the investigators.

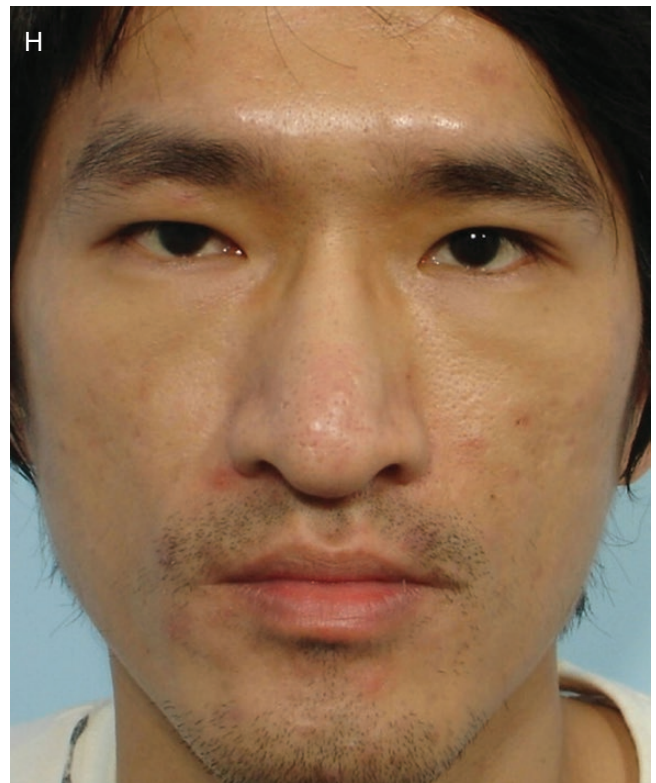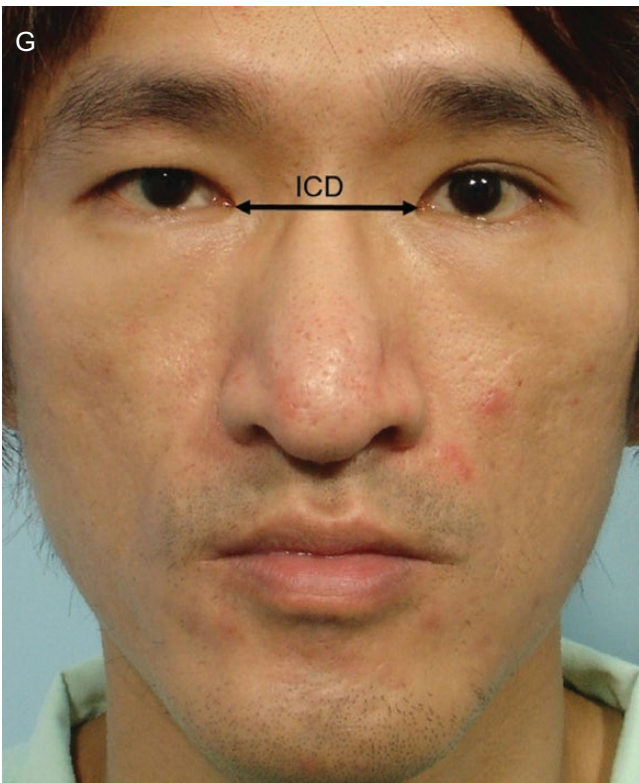

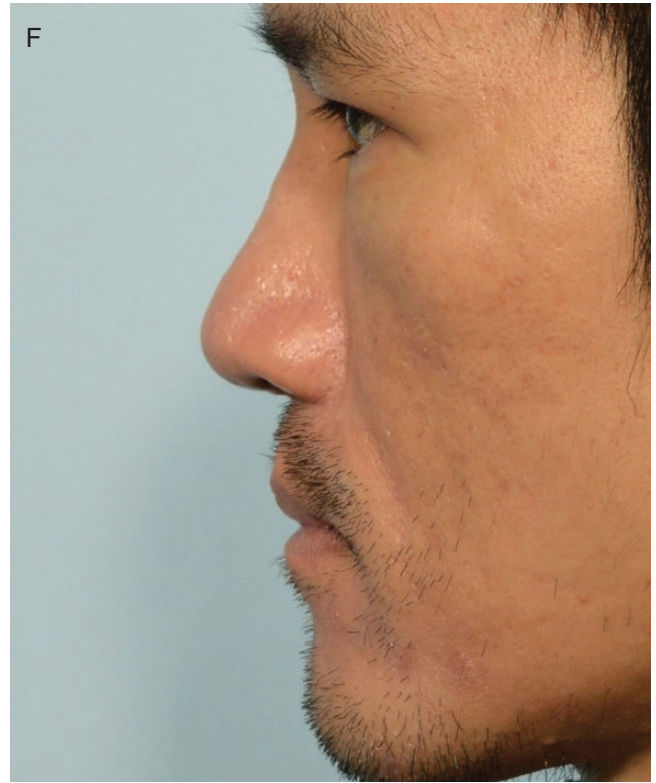
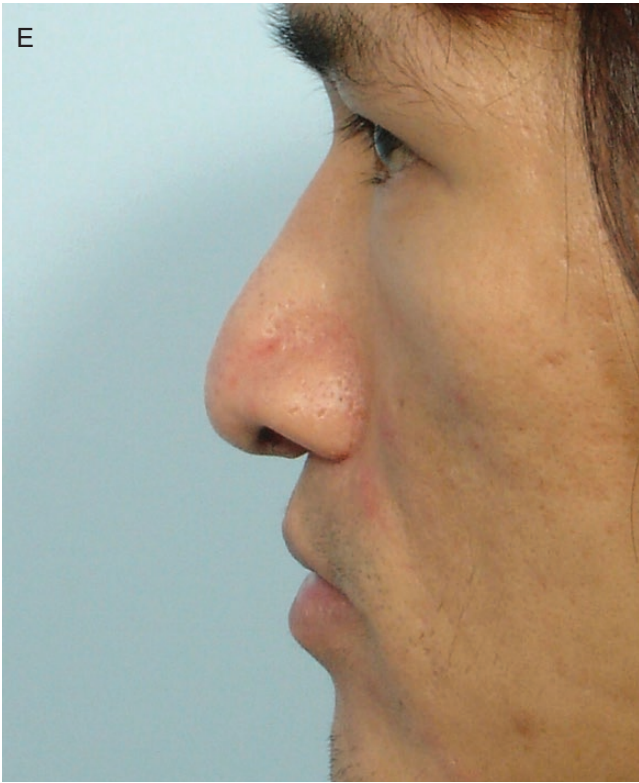Figure 7. Continued.

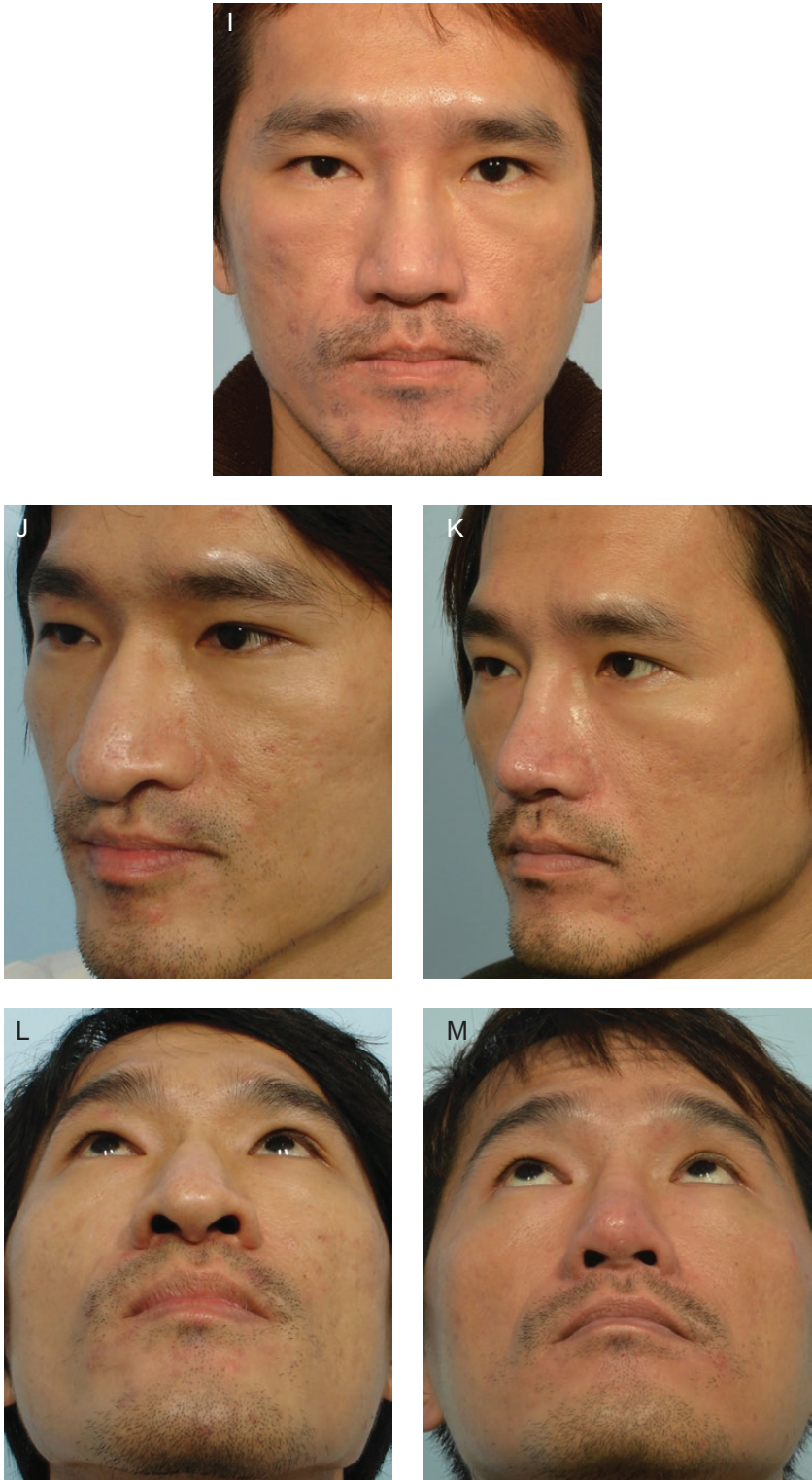

Figure 7. Continued.



Figure 8. (A, D, F, I) This 24-year-old man presented with a type III severely depressed glabella-radix area and underwent augmentation rhinoplasty with radix augmentation (to 8 mm). The implant was too large to insert into the glabella-radix space in a single-stage operation. Therefore, a 5-mm-thick implant was placed in the first stage in combination with nasal osteotomy, placement of an irradiated homologous costal spreader graft, columella strut grafting, chimera dorsal augmentation, alar plasty, and tip plasty. (B, E, G, J) One year after the first surgical session, the partially absent brow-tip lines had become narrowly spaced. The patient indicated that he was unsatisfied with the surgical results, and the investigators scored the case as “fair.” Therefore, the patient underwent placement of an additional 3-mm-thick implant in a second stage. (C, H) Four years after the second surgical session and upper blepharoplasty, the brow-tip contour lines are aesthetically pleasing. (This patient moved to the United States after the second surgical session, and we were unable to obtain additional follow-up photographs in lateral and inferior views.)

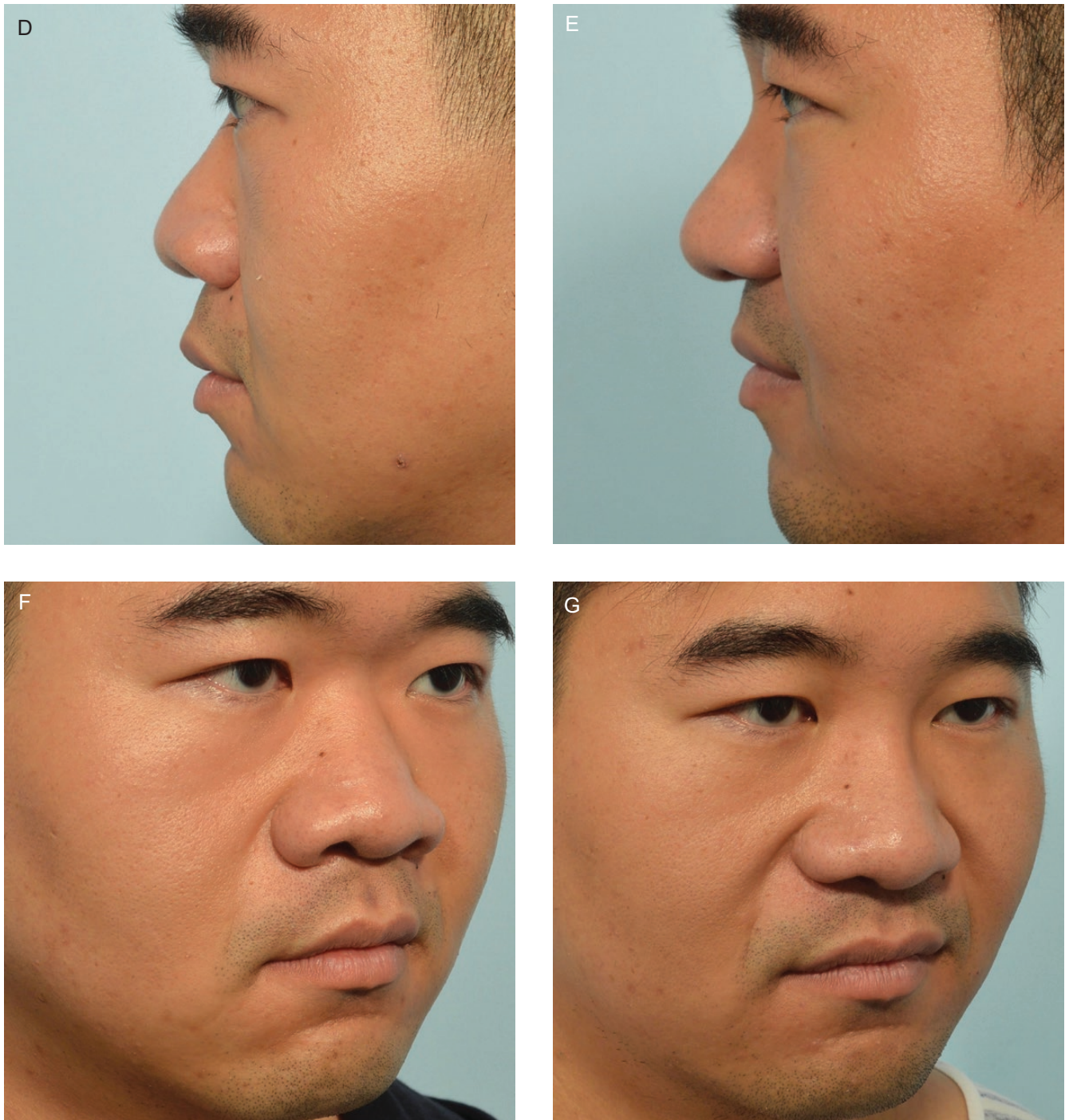

Figure 8. Continued.

Maximum Implant Thickness

Two patients in this study had inadequate augmentation postoperatively. One of these patients received a 5-mm-thick radix implant in the primary operation and then received an additional 3-mm-thick radix implant

1 year later (Figure 8). We found that a 2-stage operation was needed because the glabella-radix region was too depressed to insert an 8-mm-thick implant through the radix tunnel in a single session. We now advocate a maximum implant thickness (per session) of 5 mm.

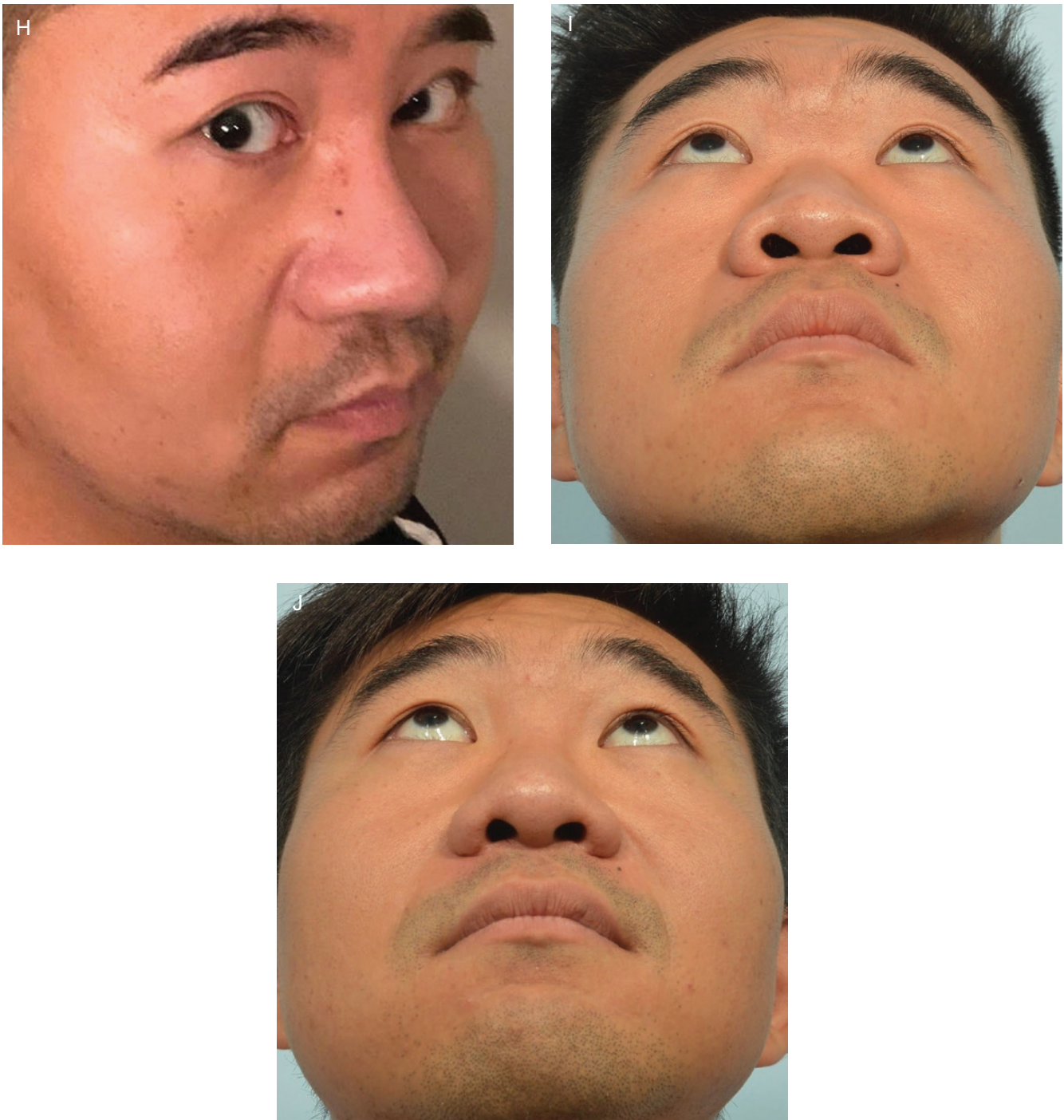

Figure 8. Continued.

Expanded Polytetrafluoroethylene Preference

Gore-Tex sheets have been shown to decrease proportionately in thickness after rhinoplasty.²⁴ Therefore, we routinely compress the Gore-Tex sheets to one-half of the original thickness while constructing the implant. Recently, an ePTFE material that does not

shrink postoperatively became commercially available (Surgiform Technology, Ltd., Lugoff, SC). Lee et al²⁵ demonstrated that the shape of Surgiform implants was maintained in augmentation rhinoplasty, enabling a predictable nasal height. Hence, we have transitioned to placing Surgiform devices in recent years; we sculpt these implants utilizing a similar technique to our method of preparing Gore-Tex implants.

Study Limitations

This study was limited by a relatively small sample size. Our findings will need to be verified by larger studies with longer follow-up periods. Since obtaining the findings of this study, we have expanded our application of glabella-radix implant placement to include patients who present with an “operated” appearance and wish to undergo a secondary procedure to address the glabella-radix deficiency that was overlooked in the primary augmentation rhinoplasty; we have observed satisfactory results in these patients as well.

CONCLUSIONS

We describe a method for grading the severity of a glabella-radix deficiency in terms of the brow-tip contour lines. The extent of glabella-radix augmentation needed is inferred from the type of brow-tip contour lines and from photographic analysis and simulation. We have found that these techniques yield predictable and attractive nasal outcomes in a series of Asian patients. Managing the glabella-radix subunit in conjunction with nasal augmentation produces more harmonious, natural-appearing results.

Acknowledgments

We thank Dr Chern CH, Department of Physics, National Taiwan University, for providing the equation for calculation of implant radix base width, and Dr Lee PC for assistance in the statistical analysis of patient demographics.

Disclosures

The authors declared no potential conflicts of interest with respect to the research, authorship, and publication of this article.

Funding

The authors received no financial support for the research, authorship, and publication of this article.

REFERENCES

- Lee PC, Chang RH, Chang YL. Treatment of nasal deviation with underlying bony asymmetry secondary to augmentation rhinoplasty in Asian patients. *Aesthet Surg J*. 2018;38(8):823-832.
- Suhk JH, Park JS, Nguyen AH. Nasal analysis and anatomy: anthropometric proportional assessment in Asians—esthetic balance from forehead to chin, part I. *Semin Plast Surg*. 2015;29(4):219-225.
- Park CW, Lee MJ, Jung YI. Photogrammetric facial analysis of attractive celebrities using the glabella for planning rhinoplasty and analyzing surgical outcomes. *Arch Aesthetic Plast Surg*. 2018;24(3):105-110.
- Gruber R, Kuang A, Kahn D. Asian-American rhinoplasty. *Aesthet Surg J*. 2004;24(5):423-430.
- Toriumi D. *Structure Rhinoplasty: Lessons Learned in 30 Years*. Indianapolis, IN: DMT Solutions; 2019:1398-1411.
- Daniel RK, Kosins A, Sajjadian A, Cakir B, Palhasi P, Molnar G. Rhinoplasty and brow modification: a powerful combination. *Aesthet Surg J*. 2013;33(7):983-994.
- Kornstein AN, Nikfarjam JS. Fat grafting to the forehead/glabella/radix complex and pyriform aperture: aesthetic and anti-aging implications. *Plast Reconstr Surg Glob Open*. 2015;3(8):e500.
- Sheen JH, Sheen AP. *Aesthetic Rhinoplasty*, 2nd ed. St. Louis, MO: Mosby; 1987:808-825, 1142-1165.
- Yi JS, Jin HR. Use of mastoid periosteum graft in primary and revision rhinoplasty. *Aesthetic Plast Surg*. 2019;43(5):1295-1300.
- Zelken JA, Hong JP, Broyles JM, Hsiao YC. Preventing elevated radix deformity in Asian rhinoplasty with a chimeric dorsal-glabellar construct. *Aesthet Surg J*. 2016;36(3):287-296.
- Constantian MB. Four common anatomic variants that predispose to unfavorable rhinoplasty results: a study based on 150 consecutive secondary rhinoplasties. *Plast Reconstr Surg*. 2000;105(1):316-331; discussion 332-333.
- Naini FB. *Facial Aesthetics: Concepts & Clinical Diagnosis*. Hoboken, NJ: Wiley-Blackwell; 2011.
- Sheen JH. Rhinoplasty: personal evolution and milestones. *Plast Reconstr Surg*. 2000;105(5):1820-1852; discussion 1853.
- Kim EK, Daniel RK. Operative techniques in Asian rhinoplasty. *Aesthet Surg J*. 2012;32(8):1018-1030.
- Daniel RK. *Rhinoplasty: An Atlas of Surgical Techniques*. New York, NY: Springer; 2002:1-14.
- Pousti SB, Jalessi M, Asghari A. Management of nasofrontal angle in rhinoplasty. *Iran Red Crescent Med J*. 2010;12(1):7-11.
- Sugawara Y. *A Practical Approach to Asian Rhinoplasty*. Tokyo, Japan: Springer; 2020:4.
- Meiyappan N, Tamizharasi S, Senthilkumar KP, Janardhanan K. Natural head position: an overview. *J Pharm Bioallied Sci*. 2015;7(Suppl 2):S424-S427.
- Chang YL. Correction of difficult short nose by modified caudal septal advancement in Asian patients. *Aesthet Surg J*. 2010;30(2):166-175.
- Mowlavi A, Meldrum DG, Wilhelmi BJ. Implications for nasal recontouring: nasion position preferences as determined by a survey of white North Americans. *Aesthetic Plast Surg*. 2003;27(6):438-445.
- Byrd HS, Hobar PC. Rhinoplasty: a practical guide for surgical planning. *Plast Reconstr Surg*. 1993;91(4):642-654; discussion 655.
- Wang JH, Jang YJ, Park SK, Lee BJ. Measurement of aesthetic proportions in the profile view of Koreans. *Ann Plast Surg*. 2009;62(2):109-113.
- McKinney P, Sweis I. A clinical definition of an ideal nasal radix. *Plast Reconstr Surg*. 2002;109(4):1416-1418; discussion 1419.
- Jung YG, Kim HY, Dhong HJ, et al. Ultrasonographic monitoring of implant thickness after augmentation rhinoplasty with expanded polytetrafluoroethylene. *Am J Rhinol Allergy*. 2009;23(1):105-110.
- Lee SJ, Rho BI, Nam SM, Lee JB, Park ES. Changes in implant thickness after rhinoplasty using Surgiform. *Arch Aesthetic Plast Surg*. 2018;24(1):1-5.