



Contents lists available at ScienceDirect

## Regenerative Therapy

journal homepage: <http://www.elsevier.com/locate/reth>

## Case report

## Clinical course of more than 10 years in a patient with extensive skin burns who received cultured epidermal autograft transplantation

Takanobu Kan, Shunsuke Takahagi, Daiki Matsubara, Emi Murakami, Mikio Kawai, Michihiro Hide, Akio Tanaka\*

Department of Dermatology, Graduate School of Biomedical and Health Sciences, Hiroshima University, Hiroshima, Japan

## ARTICLE INFO

## Article history:

Received 29 November 2021

Accepted 27 January 2022

## Keywords:

Cultured epidermal autograft

Extensive burns

Long-term observation

Skin surface hydration

Skin pigmentation

## ABSTRACT

Cultured epidermal autografts (CEAs) are used to treat extensive burns, giant congenital melanocytic nevi, and epidermolysis bullosa, but information about the long-term clinical course after CEA transplantation is scarce. Here we report 10 years' progress of a 7-year-old Japanese girl who suffered from a scald burn injury affecting 80% of her total body surface area and was treated with CEA transplantation. The skin of a child with extensive burns treated with CEAs appeared soft and of a good texture, even after 10 years, and recovery of skin pigmentation and scar condition were better at sites with a combination of CEAs and autologous skin grafts than those with CEAs alone.

© 2022, The Japanese Society for Regenerative Medicine. Production and hosting by Elsevier B.V. This is an open access article under the CC BY-NC-ND license (<http://creativecommons.org/licenses/by-nc-nd/4.0/>).

## 1. Introduction

Significant changes in appearance due to skin depigmentation and thickening and a reduced range of motion due to scar contracture always occur after skin grafts for extensive burns or congenital giant pigmented nevi. This can cause emotional distress and interfere with normal social activities for both patients and their families. Prediction of the long-term prognosis of the skin's condition after skin grafting could minimize these problems. Autologous skin grafts are a popular treatment for extensive skin defects but have the disadvantage of scarring at the donor site and a limited area of skin harvesting when there is little normal skin. This can be overcome using cultured epidermal autografts (CEAs) either alone or in combination with an autologous skin graft. In Japan, CEA

transplantation was approved for extensive burns from 2007, and its application was subsequently expanded to giant congenital pigmented nevi and epidermolysis bullosa. Therefore, it is expected that the use of CEAs will increase in pediatric cases. However, information on the long-term prognosis of the skin's condition after CEA transplantation in childhood is scarce. To this end, we evaluated the skin surface hydration (SSH), depigmentation, and scar condition of various body parts after more than 10 years in a pediatric patient with extensive burns who underwent a combination of autologous skin grafting and CEA transplantation.

## 2. Case report

A 7-year-old Japanese girl suffered a scald burn injury affecting almost her whole body (80% total body surface area) except for her head and upper left limb (superficial dermal burn, 7%; deep dermal burn, 18%; deep burn, 55%; burn index, 67.5; and prognostic burn index, 74.5) (Fig. 1a). We performed debridement of burn eschar and autologous patch skin grafts on days 8 and 19 of the injury. The entire chest, abdomen, and lower limbs were debrided to the depth of the adipose tissue, and autologous patch skin grafts (approximately 1 cm<sup>2</sup>) were performed on the abdomen and the front of both lower limbs (skin defect area:skin graft area = 1:0.3) (Table 1). On day 5 of the injury, a 5-cm<sup>2</sup> specimen of full-thickness normal skin was harvested from the upper left arm for the preparation of autologous cultured epidermis (JACE) by Japan Tissue Engineering

*Abbreviations:* CEA, Cultured epidermal autografts; SSH, skin surface hydration; SDB, superficial dermal burn; DDB, deep dermal burn; DB, deep burn;  $\mu$ S, micro Siemens.

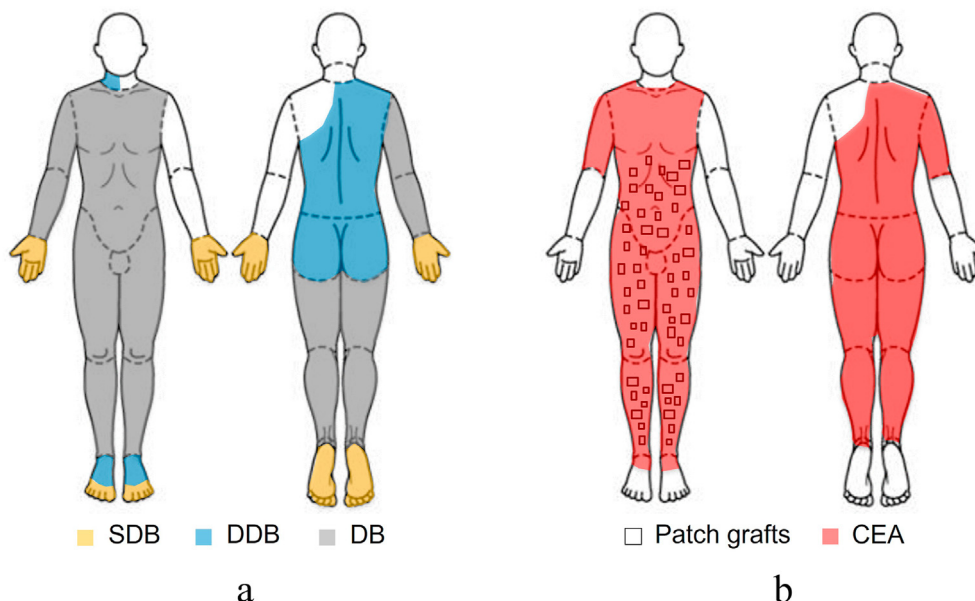
\* Corresponding author. Department of Dermatology, Graduate School of Biomedical and Health Sciences, Hiroshima University, 1-2-3 Kasumi, Minami-ku, Hiroshima 734-8551, Japan.

*E-mail addresses:* [fckantksa@gmail.com](mailto:fckantksa@gmail.com) (T. Kan), [takshuns@gmail.com](mailto:takshuns@gmail.com) (S. Takahagi), [daiki\\_matsubara\\_32\\_5@yahoo.co.jp](mailto:daiki_matsubara_32_5@yahoo.co.jp) (D. Matsubara), [emimm924@gmail.com](mailto:emimm924@gmail.com) (E. Murakami), [mkawai@kawai-hifuka-cl.com](mailto:mkawai@kawai-hifuka-cl.com) (M. Kawai), [ed1h-w1de-road@hiroshima-u.ac.jp](mailto:ed1h-w1de-road@hiroshima-u.ac.jp) (M. Hide), [tantanakiotan@yahoo.co.jp](mailto:tantanakiotan@yahoo.co.jp) (A. Tanaka).

Peer review under responsibility of the Japanese Society for Regenerative Medicine.

<https://doi.org/10.1016/j.reth.2022.01.007>

2352-3204/© 2022, The Japanese Society for Regenerative Medicine. Production and hosting by Elsevier B.V. This is an open access article under the CC BY-NC-ND license (<http://creativecommons.org/licenses/by-nc-nd/4.0/>).



**Fig. 1.** Patient burn condition and treatment. (a) Total body surface area and degree of burn. (b) Autologous skin patches and CEAs transplant site. SDB; superficial dermal burn, DDB; deep dermal burn, DB; deep burn, CEA; Cultured epidermal autograft.

Co., Ltd. (Gamagori, Japan). Subsequently, CEA transplantations were performed on days 32 and 46 of the injury (Fig. 1b). The abdomen and anterior surface of the lower limbs, where the autologous patch skin grafts were combined with the CEAs, showed good CEA take. However, a temporary CEA failure was observed in the regions where CEA was solely engrafted without autologous patch skin grafts, regardless of the debridement depth. The wounds where CEA failure was observed were healed using topical ointment treatment (Fig. 2a–d).

Skin pigmentation recovery at the CEA sites was observed early after CEA transplantation on the patient's back, where debridement was performed to the depth of the dermis. In regions where debridement was performed to the depth of the adipose tissue, depigmentation was observed early after CEA transplantation but recovered in the long term except on the posterior surface of the lower limbs. Good pigmentation recovery was observed on the abdomen and the anterior surface of the lower limbs with CEA and autologous patch skin grafting, but the pigmentation was mottled in the regions treated with CEA only (Table 1 and Fig. 2).

We evaluated the scar condition at each site 10 years after CEA transplantation using the Kyoto Scar Scale, which consists of an objective (redness and hardness of the scar) and a subjective (itching and pain) assessment [1]. The degree of scarring was graded as excellent on the patient's back, where the dermis had been preserved (Fig. 3). In the areas where debridement was to the depth of the adipose tissue, the score trended to be lower where both CEA transplantation and the autologous patch skin grafts were performed compared with the areas with CEA alone (Table 1).

The condition of the skin was assessed 12 years after the CEA transplantations (Table 1). SSH was measured using a Skicon-200EX hygrometer (Yayoi, Tokyo, Japan) at a room temperature of 24 °C with 60% humidity. The mean SSH values on the left shoulder, supraclavicular fossa, and upper arm (normal skin sites) were 108, 162, and 88 micro Siemens, respectively. The SSH values of the CEA sites were lower than those of the normal skin sites. Moreover, the SSH values of the CEA sites with autologous patch skin grafts were even lower than those of the sites without autologous patch skin grafts.

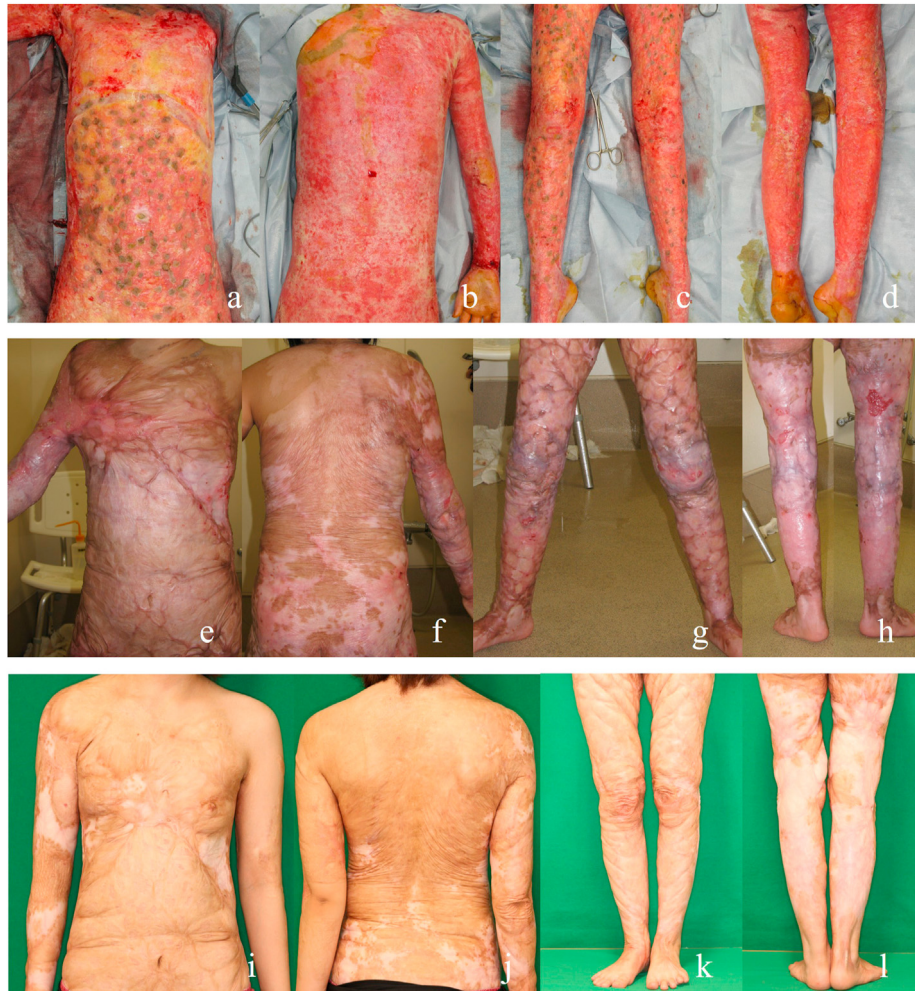**Table 1**  
Treatment and skin condition of the patient.

Region	Debridement depth	Patch graft	CEA engraftment	Depigmentation (1 year after CEA transplantation)	Depigmentation (10 years after CEA transplantation)	Skin surface hydration (μS) <sup>a</sup> (12 years after transplantation)	Kyoto Scar Scale <sup>b</sup> (10 years after CEA transplantation)
Back	Dermis	–	Temporary erosion after engraftment	+ (mottled)	+ (mottled)	58	0, excellent
Chest	Adipose tissue	–	Temporary erosion after engraftment	+ (mottled)	+ (mottled)	44	2, good
Abdomen	Adipose tissue	+	Good	+	–	39	0, excellent
Lower limb (anterior)	Adipose tissue	+	Good	+	–	32	1, good
Lower limb (posterior)	Adipose tissue	–	Temporary erosion after engraftment	+	+	52	3, fair
Right upper limb	Adipose tissue	–	Temporary erosion after engraftment	+	+ (mottled)	80	0, excellent

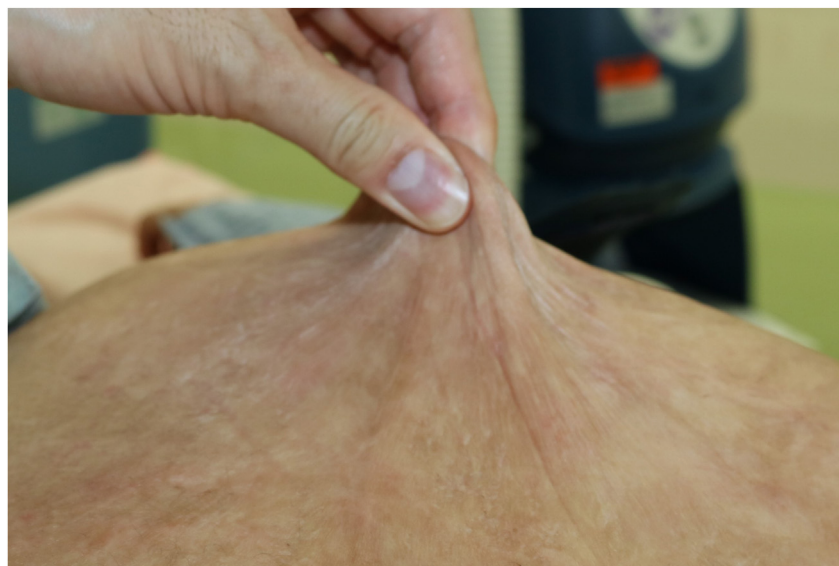CEA; cultured epidermal autograft; μS; micro Siemens.

<sup>a</sup> The skin surface hydration values represent the mean of three measurements.

<sup>b</sup> The Kyoto Scar Scale is a tool used to assess the condition of scars, classifying them as excellent (0 points), good (1–2 points), fair (3 points), or bad (4–8 points).<sup>1</sup>



**Fig. 2.** Clinical photographs of the patient from immediately after surgery to 10 years after surgery. (a–d) At the time of cultured epidermal autograft (CEA) transplantation after autologous patch skin grafting. (e–h) One year after CEA transplantation. (i–l) Ten years after CEA transplantation.



**Fig. 3.** Clinical photograph of pinched upper right back skin 11 years after cultured epidermal autograft transplantation.

### 3. Discussion

This is the first report to objectively evaluate the skin condition of a pediatric patient with extensive burns 10 years after surgery. The lifesaving treatment of extensive burns in children leads to many problems and challenges, including repeated ulcerations; scar contracture; dry skin; and physical, psychological, and social issues associated with growth [2]. The combination of CEA with autologous split-thickness skin grafts was suggested to improve the take of CEAs [3]. It is speculated that autologous split-thickness skin grafts provide a suitable niche for CEA take and growth [3]. In our case as well, a good CEA take occurred at the regions where the autologous skin patches were grafted. The Kyoto Scar Scale scores in the areas where debridement was to the depth of the adipose tissue tended to be lower in the areas with both CEA transplantation and autologous patch skin grafts than in those with CEA transplantation alone, suggesting that the combination of CEA and autologous patch skin grafts may control scarring 10 years after surgery. On the other hand, in areas where the dermis was preserved during debridement, the scarring after 10 years was graded as excellent, even with CEA transplantation alone (Fig. 3).

It makes sense that the SSH of the CEA sites was inferior to normal skin, but it is unclear why that of the CEA sites was superior to the sites where autologous patch skin grafts were used in combination with CEA. At the CEA site, there is a difference between the epidermis and the stratum corneum depending on the presence or absence of autologous patch skin grafting, which might have contributed to the result. Treatment with CEA alone may be advantageous for SSH, but this needs further investigation using a larger sample size.

Depigmentation at the site of a deep burn injury exerts not only a cosmetic burden but also a mental burden on patients. The development of melanin-containing CEAs has progressed [4] and is expected to improve depigmentation after deep burns. Additionally, our case suggests that the combined use of CEAs and autologous split-thickness skin grafts promotes pigment recovery in the skin more easily than treatment with CEA alone, even for wounds where the adipose tissue is exposed. There is a possibility that melanocytes of autologous patch skin grafts migrated to the CEA transplant site, but histological examination is required.

In summary, the skin of a child with extensive burns treated with CEA grafts appeared to be soft and of good texture, even after

10 years. However, depending on the site and the debridement depth, it is advisable to consider using autologous skin grafts in combination with CEA transplants. The skin condition in patients with epidermolysis bullosa or giant pigmented nevi treated with CEA is also expected to be good after surgery.

#### Funding

Not applicable.

#### Availability of data

The data that support the findings of this study are available from the corresponding author upon reasonable request.

#### Patient consent for publication

Written informed consent was obtained from the patient for publication of this case report.

#### Declaration of competing interest

The authors declare that they have no known competing financial interests or personal relationships that could have appeared to influence the work reported in this paper.

#### Acknowledgments

The authors would like to thank Enago ([www.enago.jp](http://www.enago.jp)) for the English language review.

#### References

- [1] Yamawaki S, Naitoh M, Ishiko T, Muneuchi G, Suzuki S. Keloids can be forced into remission with surgical excision and radiation, followed by adjuvant therapy. *Ann Plast Surg* 2011;67:402–6.
- [2] van Baar ME, Polinder S, Essink-Bot ML, van Loey NEE, Oen IMM, Dokter J, et al. Quality of life after burns in childhood (5–15 years): children experience substantial problems. *Burns* 2011;37:930–8.
- [3] Matsumura H, Matsushima A, Ueyama M, Kumagai N. Application of the cultured epidermal autograft “JACE(®)” for treatment of severe burns: results of a 6-year multicenter surveillance in Japan. *Burns* 2016;42:769–76.
- [4] Pianigiani E, Andreassi A, Andreassi L. Autografts and cultured epidermis in the treatment of vitiligo. *Clin Dermatol* 2005;23:424–9.