



Published in final edited form as:

Int J Cardiol. 2017 February 01; 228: 180–183. doi:10.1016/j.ijcard.2016.11.108.

Feasibility of low radiation dose retrospectively-gated cardiac CT for functional analysis in adult congenital heart disease★

Daniel W. Groves^a, Laura J. Olivieri^b, Sujata M. Shanbhag^a, Kathie C. Bronson^a, Jeannie H. Yu^a, Evan A. Nelson^a, Shirley F. Rollison^a, Michael S. Stagliano^a, Anitha S. John^b, Karen Kuehl^b, and Marcus Y. Chen^{a,*}

^aDepartment of Health and Human Services, Advanced Cardiovascular Imaging Laboratory, Cardiovascular and Pulmonary Branch, National Heart, Lung, and Blood Institute, National Institutes of Health, Bethesda, MD, USA

^bDepartment of Cardiology, Children's National Medical Center, Washington, DC, USA

Abstract

Background: The use of cardiac computed tomography (CT) in the evaluation of adult congenital heart disease patients is limited due to concerns of high radiation doses. The purpose of this study was to prospectively assess whether low radiation dose cardiac CT is feasible to evaluate ventricular systolic function in adults with congenital heart disease.

Methods: The study group included 30 consecutive patients with significant congenital heart disease who underwent a total of 35 ECG-gated cardiac CT scans utilizing a 320-detector row CT scanner. Each study included a non-contrast scan and subsequent contrast-enhanced retrospectively-gated acquisition. Effective radiation dose was estimated by multiplying the dose length product by a k-factor of 0.014 mSv/mGy cm.

Results: The mean age of the patients was 34.4 ± 8.9 years, 60% were men, and mean body mass index was 24.2 ± 4.3 kg/m². A majority of patients (n = 28, 93.3%) had contraindications to cardiac MRI. A tube potential of 80 kV was used in 27 (77.1%) of the contrast-enhanced scans. The mean signal-to-noise and contrast-to-noise ratios were 11.5 ± 3.9 and 10.3 ± 3.7 , respectively. The median radiation dose for non-contrast and contrast-enhanced images were 0.1 mSv (0.07–0.2 mSv) and 0.94 mSv (0.5–2.1 mSv), respectively. All 35 CT scans were successfully analyzed for ventricular systolic function.

Conclusions: A low radiation contrast-enhanced, retrospectively-gated cardiac CT with a median radiation dose of less than 1 mSv was successful in evaluating ventricular systolic function in 30 consecutive adult congenital heart disease patients who underwent a total of 35 scans.

★This author takes responsibility for all aspects of the reliability and freedom from bias of the data presented and their discussed interpretation.

This is an open access article under the CC BY-NC-ND license (<http://creativecommons.org/licenses/by-nc-nd/4.0/>).

*Corresponding author at: Advanced Cardiovascular Imaging Laboratory, Cardiovascular and Pulmonary Branch, National Heart, Lung, and Blood Institute, National Institutes of Health, 10 Center Dr, Building 10, Room B1D416, Bethesda, MD 20892-1061, USA. chenmy@nhlbi.nih.gov.

Conflicts of interest

The National Heart, Lung, and Blood Institute of the National Institutes of Health has an institutional research agreement with Toshiba Medical Systems.

Keywords

Adult congenital heart disease; Cardiac computed tomography; Systolic function; Radiation dose

1. Introduction

With advancements in pediatric cardiac care, there is a growing population of adults with congenital heart disease [1–5]. Transthoracic echocardiography is the first-line modality for diagnosis and serial assessment in congenital heart disease [6]. However, echocardiographic assessment of cardiac function in adult congenital heart disease can be challenging due to the complex anatomy, limited field of view, and poor echocardiographic windows following cardiac surgeries. Many of these patients have a single ventricle or a morphologic right ventricle that supports the systemic circulation. These ventricles deform under the altered hemodynamics, and functional assessment is critical for clinical care. The complex geometry of a single or right ventricle make accurate measurements of ventricular size and systolic function challenging with echocardiography. Echocardiographic assessments of single or right ventricular size and systolic function have meager reproducibility in congenital heart disease patients [7–8]. Often, only qualitative assessments of systolic function can be made, and volumetric imaging is required [9–10]. Cardiac magnetic resonance imaging (MRI) has been used as a complementary or alternative technique due to the ability to perform volumetric imaging with no ionizing radiation [6,11–12]. However, cardiac MRI may be contraindicated in patients with pacemakers or implantable cardioverter-defibrillators.

The use of cardiac computed tomography (CT) in congenital heart disease patients has been limited due to concerns over high radiation dose and associated cancer risks [13–16]. Cardiac CT has been compared favorably to MRI for ventricular volume and ejection fraction assessments, even among patients with congenital heart disease [17–24]. We hypothesized that a low radiation dose contrast-enhanced, retrospectively-gated cardiac CT would be feasible to evaluate ventricular systolic function in adult congenital heart disease patients.

2. Methods

The institutional review board approved this prospective study. The study protocol conformed to the ethical guidelines of the 1975 Declaration of Helsinki. All of the subjects provided written informed consent to participate. The study was registered on ClinicalTrials.gov (registration NCT01621594). Inclusion criteria consisted of patients at least 18 years old with congenital heart disease who were clinically referred for contrast-enhanced cardiac CT. Exclusion criteria were pregnancy or renal dysfunction, estimated glomerular filtration rate less than 30 mL/min/1.73 m² [25]. Patients were not excluded for weight, heart rate, or heart rhythm.

Overall, 30 consecutive patients underwent a total of 35 CT scans with axial imaging using a second-generation, 320 × 0.5-mm detector row CT unit (Aquilion ONE ViSION Edition; Toshiba Medical Systems, Otawara, Japan) with a gantry rotation time of 275 msec. There

were 5 patients with a second CT scan as part of a serial evaluation, not due to an inadequate initial scan. Tube potential and tube current were determined by automatic exposure control (SURE^{EX}posure3D, Toshiba Medical Systems, SD 150 for non-contrast and SD 110 for contrast-enhanced images) on the basis of the X-ray attenuation on scout images and reconstruction kernel [26]. Images were reconstructed with a 512 × 512 matrix, 0.5 mm thick sections, and 0.25-mm increments using kernel FC03, iterative reconstruction AIDR3D standard (Toshiba Medical Systems) [27].

Patients were eligible to receive either metoprolol orally and/or intravenously to reduce the resting heart rate, though the majority did not receive either (n = 27, 77.1%) due to being pacemaker-dependent. An initial non-contrast scan was performed to delineate prior surgical changes and determine the appropriate scan range for the contrast-enhanced acquisition. Typically, Iopamidol (Isovue 370, Bracco Diagnostics, Princeton, NJ; 370 mg of iodine per milliliter) was injected via an antecubital vein at 5 mL/s in a triphasic protocol: 75 mL of contrast followed by 30 mL of a 50% contrast-50% saline mixture and then 50 mL of saline. Breath-held retrospectively-gated contrast-enhanced images were triggered within 1 s of a threshold of 600 Hounsfield units in the left ventricular blood pool using bolus-tracking. If an evaluation for coronary artery disease was requested, patients received 0.4 mg of sublingual nitroglycerin prior to imaging. Effective radiation doses were estimated by multiplying the dose-length product (DLP) reported by the scanner by using a conversion factor of 0.014 mSv/mGy cm according to standard methodology [28]. Ventricular volumes and ejection fraction were quantified from 0.5 mm thick slices using 5% phase increments on a workstation (Vital Images, Minnetonka, MN). Fig. 1 shows an example of a contrast-enhanced CT scan with end-diastolic and end-systolic frames. Cine videos from a contrast-enhanced scan are available in the Supplementary material (Videos 1–3). Data are presented as means ± standard deviations or as median with interquartile range (IQR).

3. Results

In total, 30 patients with congenital heart disease underwent a total of 35 scans from July 2013 to April 2016. Table 1 describes the baseline characteristics of the patients, radiation doses, and image quality. The primary diagnosis for the referred patients were classified as D-transposition of the great arteries (n = 7), atrial or ventricular septal defect (n = 6), Tetralogy of Fallot (n = 5), double outlet right ventricle (n = 5), congenitally corrected transposition of the great arteries (n = 2), single ventricle (n = 2), congenital valve disease (n = 1), Shone's complex (n = 1), or anomalous coronary artery (n = 1). The patient's prior surgeries included atrial switch (n = 7), pulmonary valve replacement (n = 6), ventricular septal defect repair (n = 6), atrial septal defect repair (n = 5), transannular patch repair (n = 5), double outlet right ventricle repair (2 ventricles, n = 5), lateral tunnel Fontan (n = 2), prosthetic aortic valve replacement (n = 2), Ross procedure (n = 2), subaortic membrane resection (n = 1), mitral valve repair (n = 1), and anomalous coronary artery reimplantation (n = 1). The patients were primarily referred for cardiac CT to evaluate for ventricular size and function but additional secondary evaluations included: aortic size, main and branch pulmonary artery stenosis, baffle or Fontan obstructions, coronary artery anastomoses, and atherosclerotic coronary artery disease. The vast majority of patients (n = 28, 93.3%) had contraindications to cardiac MRI due to pacemaker/implantable cardioverter-defibrillator (n

= 27) or breast tissue expander (n = 1). The remaining two patients were referred in part for coronary artery disease evaluation.

The mean age was 34.4 ± 8.9 years (range 22–50 years) and 60% (n = 18) were men. The mean body mass index (BMI) was 24.2 ± 4.3 kg/m². Overall, 15 patients were overweight (n = 13, 43.3%) or obese (n = 2, 6.7%). Only 8 patients (22.9%) received metoprolol, oral or intravenous, prior to the CT scan. The mean heart rate during the contrast-enhanced retrospectively-gated acquisition was 61.1 ± 6.6 bpm.

A tube potential of 80 kV was used in 27 of the scans (77.1%) while a tube potential of 100 kV was used in the remaining 8 scans (22.9%). On the contrast-enhanced images, the mean signal-to-noise ratio (SNR) and contrast-to-noise ratio (CNR) were 11.5 ± 3.9 and 10.3 ± 3.7 , respectively. The median radiation dose for non-contrast scans was 0.1 mSv (0.07–0.2 mSv). The median radiation dose for contrast-enhanced scans was 0.94 mSv (0.5–2.1 mSv). For the 80 kV contrast-enhanced scans, the median radiation dose was 0.74 mSv (0.49–1.32 mSv). The radiation dose for the contrast-enhanced scans was less than 1 mSv in 19 scans (54.2%) and less than 0.5 mSv in 7 scans (20%). All scans were successfully analyzed for biventricular systolic function where 2 ventricles were present.

4. Discussion

With decreasing mortality rates in children with congenital heart disease, the number of adults with congenital heart disease is growing and now outnumbers children [1–5]. Serial non-invasive imaging is vital to clinical care as changes in ventricular volumes and systolic function may necessitate repeat operation [29–31]. Echocardiography is the clinical workhorse for non-invasive imaging in congenital heart disease patients, however volumetric imaging may be required [6,9–10]. Cardiac MRI is commonly utilized if transthoracic echocardiography is inadequate. However, adults with congenital heart disease may have contraindications to MRI, particularly due to cardiac devices which are increasingly required by this population prone to heart block, arrhythmias, and sudden cardiac death [32].

Cardiac CT is a viable alternative for these patients with a contraindication to MRI as there is excellent correlation in ventricular size and systolic function when compared to cardiac MRI in adults with congenital heart disease [23–24]. Cardiac CT is unable to provide flow quantification information that cardiac MRI can with velocity encoded phase contrast imaging, but cardiac CT has clear advantages in spatial resolution and fast acquisition time. CT is able to acquire volumetric coverage in a single acquisition rather than the stepwise acquisition of multiple volumes in cardiac MRI. Beyond assessment of ventricular size and function, cardiac CT allows for evaluation of the origins of coronary arteries, atherosclerotic coronary artery disease, patency of conduits or baffles, posteroinferior rim in ostium secundum atrial septal defects, and mediastinal adhesions prior to re-operation.

A clear concern when considering cardiac CT for serial evaluation is the cumulative radiation dose [33]. A mean radiation dose of 7.6 mSv was reported in an adult congenital heart disease population comparing quantitative assessment of right ventricular volumes between 256-slice CT and 3-Tesla MRI in 33 patients with surgically repaired Tetralogy of

Fallot [24]. A recent study reported a median radiation dose of approximately 1.1 mSv for ventricular function analysis when using a tube potential of 70 kV and tube current modulation [34]. However, the study group did not represent consecutive patients undergoing cardiac CT. In addition, 50% of the study population was less than 18 years of age and manual adjustments were performed to lower the tube potential if the recommended tube potential was higher than expected.

This study marks another step forward in the use of cardiac CT in the adult congenital heart disease population. The median radiation dose for 35 consecutive contrast-enhanced CT scans was less than 1 mSv. Notably, this represented 30 consecutive patients as no patients were excluded due to body size, heart rate, or heart rhythm. The use of a lower tube potential and a wide volume 320-detector row CT scanner significantly reduced the radiation dose for each scan [35]. There is the potential to underestimate the effective radiation dose by using the dose-length product and conversion factor of 0.014 mSv/mGy cm, but this value is the current standard [28,35]. All scan parameters were fully automated which could make wider implementation possible. The use of a triphasic contrast protocol (contrast, contrast:saline mix, saline) provided simultaneous opacification of the right and left ventricles (when present) to allow for the assessment of systolic function in both ventricles. All scans were able to successfully analyze biventricular systolic function where 2 ventricles were present.

5. Limitations

The main limitation of this study is the ventricular volumes were not validated against a reference standard such as cardiac MRI. However, most patients (93.3%) had clear contraindications to MRI and all had inadequate 2D/3D echocardiographic windows. Despite the study encompassing our experience over approximately 3 years, the total sample size was small but still represented a spectrum of patients with complex congenital heart disease. The current study utilized a 320-detector row CT scanner which is available in a limited number of centers, but we would advocate a similar approach using a low tube potential if using a different CT scanner.

6. Conclusions

A low radiation contrast-enhanced, retrospectively-gated cardiac CT with a median radiation dose of less than 1 mSv was successful in evaluating ventricular systolic function in 30 consecutive adult congenital heart disease patients who underwent a total of 35 scans.

Supplementary data to this article can be found online at <http://dx.doi.org/10.1016/j.ijcard.2016.11.108>.

Supplementary Material

Refer to Web version on PubMed Central for supplementary material.

Acknowledgments

Funding sources

This work was supported by the National Institutes of Health (grant number 1ZIAHL006138–05).

References

- [1]. Warnes CA, Liberthson R, Danielson GK, et al., Task force 1: the changing profile of congenital heart disease in adult life, *J. Am. Coll. Cardiol* 37 (2001) 1170–1175. [PubMed: 11300418]
- [2]. Marelli AJ, Mackie AS, Ionescu-Ittu R, Rahme E, Pilote L, Congenital heart disease in the general population: changing prevalence and age distribution, *Circulation* 115 (2007) 163–172. [PubMed: 17210844]
- [3]. Khairy P, Ionescu-Ittu R, Mackie AS, Abrahamowicz M, Pilote L, Marelli AJ, Changing mortality in congenital heart disease, *J. Am. Coll. Cardiol* 56 (2010) 1149–1157. [PubMed: 20863956]
- [4]. Mulder BJ, Epidemiology of adult congenital heart disease: demographic variations worldwide, *Neth. Hear. J* 20 (2012) 505–508.
- [5]. van der Bom T, Bouma BJ, Meijboom FJ, Zwinderman AH, Mulder BJ, The prevalence of adult congenital heart disease, results from a systematic review and evidence based calculation, *Am. Heart J* 164 (2012) 568–575. [PubMed: 23067916]
- [6]. Prakash A, Powell AJ, Geva T, Multimodality noninvasive imaging for assessment of congenital heart disease, *Circ. Cardiovasc. Imaging* 3 (2010) 112–125. [PubMed: 20086225]
- [7]. Puchalski MD, Williams RV, Askovich B, Minich LL, Mart C, Tani LY, Assessment of right ventricular size and function: echo versus magnetic resonance imaging, *Congenit. Heart Dis* 2 (2007) 27–31. [PubMed: 18377513]
- [8]. Margossian R, Schwartz ML, Prakash A, et al., Comparison of echocardiographic and cardiac magnetic resonance imaging measurements of functional single ventricular volumes, mass, and ejection fraction (from the Pediatric Heart Network Fontan Cross-Sectional Study), *Am. J. Cardiol* 104 (2009) 419–428. [PubMed: 19616678]
- [9]. Avitabile CM, Whitehead K, Fogel M, Mercer-Rosa L, Tricuspid annular plane systolic excursion does not correlate with right ventricular ejection fraction in patients with hypoplastic left heart syndrome after Fontan palliation, *Pediatr. Cardiol* 35 (2014) 1253–1258. [PubMed: 24840648]
- [10]. Lewis G, Thorne S, Clift P, Holloway B, Cross-sectional imaging of the Fontan circuit in adult congenital heart disease, *Clin. Radiol* 70 (2015) 667–675. [PubMed: 25818807]
- [11]. Fratz S, Chung T, Greil GF, et al., Guidelines and protocols for cardiovascular magnetic resonance in children and adults with congenital heart disease: SCMR expert consensus group on congenital heart disease, *J. Cardiovasc. Magn. Reson* 15 (2013) 51. [PubMed: 23763839]
- [12]. Kilner PJ, Geva T, Kaemmerer H, Trindade PT, Schwitler J, Webb GD, Recommendations for cardiovascular magnetic resonance in adults with congenital heart disease from the respective working groups of the European Society of Cardiology, *Eur. Heart J* 31 (2010) 794–805. [PubMed: 20067914]
- [13]. Einstein AJ, Moser KW, Thompson RC, Cerqueira MD, Henzlova MJ, Radiation dose to patients from cardiac diagnostic imaging, *Circulation* 116 (2007) 1290–1305. [PubMed: 17846343]
- [14]. Einstein AJ, Henzlova MJ, Rajagopalan S, Estimating risk of cancer associated with radiation exposure from 64-slice computed tomography coronary angiography, *JAMA* 298 (2007) 317–323. [PubMed: 17635892]
- [15]. Sadetzki S, Excess lifetime cancer mortality risk attributed to radiation exposure from pediatric computed tomography scan, *Isr. Med. Assoc. J* 9 (2007) 607–609. [PubMed: 17877069]
- [16]. Faletra FF, D’Angeli I, Klersy C, et al., Estimates of lifetime attributable risk of cancer after a single radiation exposure from 64-slice computed tomographic coronary angiography, *Heart* 96 (2010) 927–932. [PubMed: 20538668]
- [17]. Groen JM, van der Vleuten PA, Greuter MJ, Zijlstra F, Oudkerk M, Comparison of MRI, 64-slice MDCT and DSCT in assessing functional cardiac parameters of a moving heart phantom, *Eur. Radiol* 19 (2009) 577–583. [PubMed: 18953545]
- [18]. Brodoefel H, Kramer U, Reimann A, et al., Dual-source CT with improved temporal resolution in assessment of left ventricular function: a pilot study, *Am. J. Roentgenol* 189 (2007) 1064–1070. [PubMed: 17954641]

- [20]. Busch S, Johnson TR, Wintersperger BJ, et al., Quantitative assessment of left ventricular function with dual-source CT in comparison to cardiac magnetic resonance imaging: initial findings, *Eur. Radiol* 18 (2008) 570–575. [PubMed: 17909817]
- [21]. Takx RA, Moscariello A, Schoepf UJ, et al., Quantification of left and right ventricular function and myocardial mass: comparison of low-radiation dose 2nd generation dual-source CT and cardiac MRI, *Eur. J. Radiol* 81 (2012) e598–e604. [PubMed: 21831552]
- [22]. Sharma A, Einstein AJ, Vallakati A, Arbab-Zadeh A, Mukherjee D, Lichstein E, Meta-analysis of global left ventricular function comparing multidetector computed tomography with cardiac magnetic resonance imaging, *Am. J. Cardiol* 113 (2014) 731–738. [PubMed: 24355312]
- [23]. Raman SV, Cook SC, McCarthy B, Ferketich AK, Usefulness of multidetector row computed tomography to quantify right ventricular size and function in adults with either tetralogy of Fallot or transposition of the great arteries, *Am. J. Cardiol* 95 (2005) 683–686. [PubMed: 15721122]
- [24]. Yamasaki Y, Nagao M, Yamamura K, et al., Quantitative assessment of right ventricular function and pulmonary regurgitation in surgically repaired tetralogy of Fallot using 256-slice CT: comparison with 3-Tesla MRI, *Eur. Radiol* 24 (2014) 3289–3299. [PubMed: 25113649]
- [25]. Stevens LA, Coresh J, Greene T, Levey AS, Assessing kidney function—measured and estimated glomerular filtration rate, *N. Engl. J. Med* 354 (2006) 2473–2483. [PubMed: 16760447]
- [26]. Van der Molen AJ, Joemai RM, Geleijns J, Performance of longitudinal and volu-metric tube current modulation in a 64-Slice CT with difference choices of acquisition and reconstruction parameters, *Phys. Med* 28 (2012) 319–326. [PubMed: 22061446]
- [27]. Bedayat A, Rybicki FJ, Kumamaru K, et al., Reduced exposure using asymmetric cone beam processing for wide area detector cardiac CT, *Int. J. Card. Imaging* 28 (2012) 361–368.
- [28]. Halliburton SS, Abbara S, Chen MY, et al., SCCT guidelines on radiation dose and dose-optimization strategies in cardiovascular CT, *J. Cardiovasc. Comput. Tomogr* 5 (2011) 198–224. [PubMed: 21723512]
- [29]. Warnes CA, Williams RG, Bashore TM, et al., ACC/AHA 2008 guidelines for the management of adults with congenital heart disease: a report of the American College of Cardiology/American Heart Association Task Force on Practice Guidelines (Writing Committee to Develop Guidelines on the Management of Adults With Congenital Heart Disease). Developed in Collaboration With the American Society of Echocardiography, Heart Rhythm Society, International Society for Adult Congenital Heart Disease, Society for Cardiovascular Angiography and Interventions, and Society of Thoracic Surgeons, *J. Am. Coll. Cardiol* 52 (2008) e143–e263. [PubMed: 19038677]
- [30]. Silversides CK, Marelli A, Beaulac L, et al., Canadian Cardiovascular Society 2009 Consensus Conference on the management of adults with congenital heart disease: executive summary, *Can. J. Cardiol* 26 (2010) 143–150. [PubMed: 20352134]
- [31]. Baumgartner H, Bonhoeffer P, De Groot NM, et al., ESC guidelines for the management of grown-up congenital heart disease (new version 2010), *Eur. Heart J* 31 (2010) 2915–2957. [PubMed: 20801927]
- [32]. Opatowsky AR, Siddiqi OK, Webb GD, Trends in hospitalizations for adults with congenital heart disease in the U.S., *J. Am. Coll. Cardiol* 54 (2009) 460–467. [PubMed: 19628123]
- [33]. Hoffmann A, Engelfriet P, Mulder B, Radiation exposure during follow-up of adults with congenital heart disease, *Int. J. Cardiol* 118 (2007) 151–153. [PubMed: 16997400]
- [34]. Lesser AM, Newell MC, Samara MA, et al., Radiation dose and image quality of 70 kVp functional cardiovascular computed tomography imaging in congenital heart disease, *J. Cardiovasc. Comput. Tomogr* 10 (2016) 173–178. [PubMed: 26794867]
- [35]. Einstein AJ, Elliston CD, Arai AE, et al., Radiation dose from single-heartbeat coronary CT angiography performed with a 320-detector row volume scanner, *Radiology* 254 (2010) 698–706. [PubMed: 20177085]

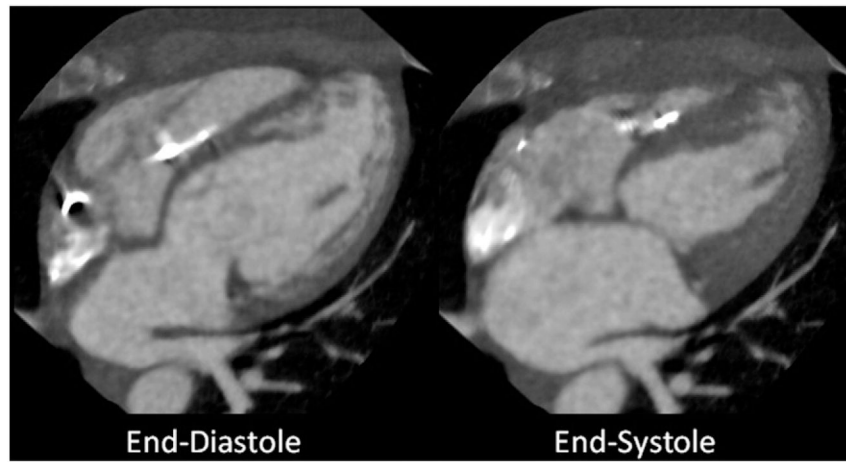


Fig. 1. 46 year old (BMI 19.6) with congenitally corrected transposition of the great arteries, complete heart block with dual chamber pacemaker and inadequate echocardiographic windows. Four-chamber view demonstrating typical image quality at end-diastole and end-systole with an effective radiation dose of 0.27 mSv.

Table 1

Patient characteristics, radiation dose estimates, and image quality.

	All studies (n = 35)
Mean age (years)	34.4 ± 8.9
Mean height (cm)	169.4 ± 9.4
Mean weight (kg)	70.2 ± 17
Mean body mass index (kg/m ²)	24.2 ± 4.3
No of underweight patients (<18 kg/m ²)	1 (3.3)
No of patients of normal weight (18–25 kg/m ²)	14 (46.7)
No of overweight patients (25–30 kg/m ²)	13 (43.3)
No of obese patients (30–40 kg/m ²)	2 (6.7)
No of patients with contraindications to MRI	28 (93.3)
No of patients receiving oral beta-blockers before imaging	3 (8.6)
No of patients receiving intravenous beta-blockers before imaging	7(20)
Non-contrast CT median effective mAs	70(45–115)
Non-contrast CT median DLP ^a (mGy cm)	7.2 (4.7–15.2)
Non-contrast CT median CTDIvol ^b (mGy)	0.6(0.4–1.3)
Non-contrast CT median radiation dose (mSv)	0.1 (0.07–0.2)
Mean heart rate (bpm) during contrast-enhanced CT	61.1 ± 6.6
No of contrast-enhanced CT with 80 kV tube potential	27 (77.1%)
No of contrast-enhanced CT with 100 kV tube potential	8 (22.9%)
Contrast-enhanced CT median effective mAs	120 (90–200)
Contrast-enhanced CT median DLP ^a (mGy cm)	66.9 (39–147.8)
Contrast-enhanced CT median CTDIvol ^b (mGy)	5.1 (3.1–10.8)
Contrast-enhanced CT median radiation dose (mSv)	0.94(0.5–2.1)
Contrast-enhanced CT mean signal-to-noise ratio	11.5 ± 3.9
Contrast-enhanced CT mean contrast-to-noise ratio	10.3 ± 3.7

^aDLP-dose length product.^bCTDIvol-computed tomography dose index volume.