



Refractory eosinophilic cystitis controlled with low-dose cyclosporine therapy: A case report

Olufunmilola Adeleye^a, John S. Trickett^b, Benjamin L. Wright^{c,d}, Aqsa Khan^{e,*}

^a Mayo Clinic Alix School of Medicine, Mayo Clinic Arizona, Scottsdale, AZ, USA

^b Internal Medicine Residency, Department of Medicine, Mayo Clinic Arizona, Phoenix, AZ, USA

^c Division of Allergy, Asthma, and Clinical Immunology, Department of Medicine, Mayo Clinic Arizona, Scottsdale, AZ, USA

^d Section of Allergy and Immunology, Division of Pulmonology, Phoenix Children's Hospital, Phoenix, AZ, USA

^e Division of Urology, Department of Surgery, Mayo Clinic Arizona, Phoenix, AZ, USA

ARTICLE INFO

Keywords:

Eosinophilic cystitis
Cyclosporine

ABSTRACT

Eosinophilic cystitis (EC) is a rare disease of the bladder with no clear inciting etiology, pathogenesis, or standard treatment. We present the case of a 78-year-old woman with a three-year history of refractory EC with symptoms characterized by urinary frequency, gross hematuria, dysuria, and suprapubic pain. Despite treatment with a silver nitrate instillation, antibiotics, alpha-1 blockers, antihistamines, antimuscarinics, beta-3 agonists, and intravesical steroid injections, her symptoms persisted. She was then trialed on systemic therapies including prednisone, montelukast, and cyclosporine. Upon follow-up after initiation of therapy with low-dose cyclosporine she had an excellent response, both symptomatically and anatomically via cystoscopy.

1. Introduction

Eosinophilic cystitis (EC) is a rare form of interstitial cystitis, in which eosinophils infiltrate all layers of the bladder wall, causing inflammation.¹ The potential chronicity of this condition can lead to significant morbidity, adversely impacting quality of life.² Since EC was first reported by Edwin Brown in 1960, there have been only about 200 cases documented.^{1,2} There is currently no clear consensus on its cause, pathogenesis, or treatment.²

EC has associations with infection, medication, bladder cancer, trauma, and allergies, but its etiology remains obscure.² It has a broad spectrum of clinical and pathologic manifestations, ranging from mild cystitis to chronic or recurrent inflammation.³ Symptoms can be debilitating in nature with frequency, urgency, dysuria, suprapubic pain, and hematuria as common presenting features.⁴ Therapy often involves systemic, intravenous, and intralesional steroid treatment alone or in combination with antibiotics, antihistamines, or in some cases, surgical intervention, including cystectomy.¹

The lack of consensus in the treatment of EC indicates that there is a knowledge deficit on this enigmatic disease and more exploration is needed. Previous cases have shown mixed results following treatment with prednisone.¹ Steroid-sparing therapies for long-term management have proven elusive, although successful results were observed with

cyclosporine in one adult and some pediatric cases.^{3,4} We aim to add to the medical literature by describing a patient with a long history of refractory EC successfully managed with low-dose cyclosporine.

2. Case presentation

A 78-year-old female presented with a three-year history of urinary symptoms characterized by urinary frequency, urgency, nocturia, gross hematuria, dysuria, and suprapubic pain. She had three prior biopsies confirming the diagnosis of EC.

Her past medical history included multiple comorbidities including primary biliary cholangitis with autoimmune hepatitis, type 2 diabetes, and hypertension. Her workup and histopathology were negative for malignancy. She reported no relevant exposures to parasites and had no history of chronic diarrheal illness. Other than frequent bacterial UTIs, she did not have any specific risk factors associated temporally with the onset of her symptoms. She had previously been treated with a silver nitrate instillation in the bladder without improvement.

Initial lab results showed mild peripheral eosinophilia with an absolute eosinophil count of 650 cells/ μ L. Cystourethroscopy demonstrated extensive cystitis cystica and regions of erythema and thickening of the urothelium along the left anterior bladder wall, left posterior bladder wall, and right posterior bladder wall (Fig. 1). On vaginal

* Corresponding author. Clinic Arizona 5779 East Mayo Blvd, Phoenix, AZ, 85054, USA.

E-mail address: khan.aqsa@mayo.edu (A. Khan).

<https://doi.org/10.1016/j.eucr.2021.101829>

Received 4 August 2021; Received in revised form 25 August 2021; Accepted 29 August 2021

Available online 2 September 2021

2214-4420/© 2021 Published by Elsevier Inc. This is an open access article under the CC BY-NC-ND license (<http://creativecommons.org/licenses/by-nc-nd/4.0/>).

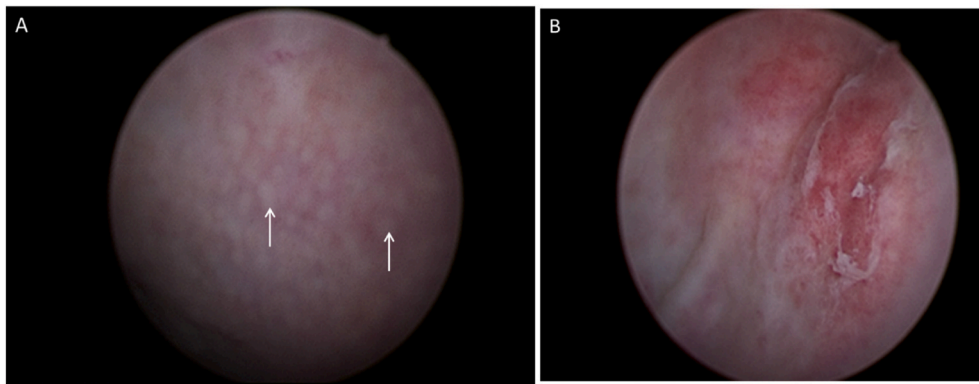


Fig. 1. Cystoscopic image of the bladder obtained at initial visit. There is a gross nodular appearance (white arrows) of the suburothelial tissue diffusely throughout the bladder which was friable and bled easily.

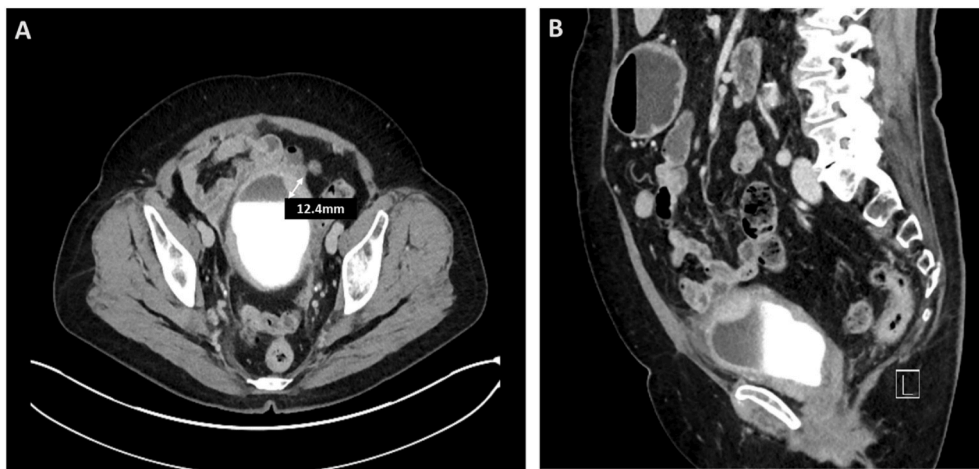


Fig. 2. Cross sectional (panel A) and sagittal (panel B) views of CT abdomen/pelvis obtained before cyclosporine therapy demonstrating mild diffuse bladder wall thickening. There is focal increased wall thickening and enhancement in the anterior left upper aspect (white arrow, panel A) measuring over 12.4mm in thickness.

examination, vaginal walls appeared normal and there was an area of erythema and excoriation noted just anterior to the urethral meatus. No other concerning masses or lesions were identified.

Preliminary investigation included physical exam, urine testing, and CT imaging. Midstream urinalyses consistently showed microscopic hematuria and pyuria. She had two positive urine cultures over the course of a year, both times growing *E. coli*. Urine cytology was negative for high-grade malignancy. CT urograms showed a progressive thickening of her bladder wall, particularly in the left anterior aspect (Fig. 2). Biopsies obtained in the operating room revealed dense eosinophilic infiltrate, consistent with a diagnosis of EC (Fig. 3).

Attempted medical treatments included loratadine, tamsulosin, oxybutynin, mirabegron, vaginal estrogen cream, as well as antibiotic treatments. She furthermore underwent bladder fulgurations with triamcinolone injections into the bladder lesions. Unfortunately, the benefits from these procedures were temporary. She was ultimately placed on a prolonged 20-day taper of prednisone + montelukast 10mg daily every night at bedtime. This resulted in resolution of her hematuria and dysuria; however, she had recurrence of her dysuria two weeks after discontinuing prednisone.

The patient was then started on a course of cyclosporine at 25 mg twice daily, titrating up to 50 mg three times daily (~2.3 mg/kg/day). The addition of cyclosporine to her treatment regimen drastically improved her symptoms and resolved her hematuria.

While on continuous systemic therapy, she was seen a year after, has had no bladder pain, and has seen significant improvement in her urinary frequency. Daytime voiding reduced from more than once per hour

to urination every 3–4 hours and her sleep disruption improved from waking every 2–3 hours to 1 episode of nocturia per night.

Bladder cystoscopy revealed one stellate lesion along the right posterior dome with mild bleeding. The remainder of her mucosa is free of ulcers, masses, and trabeculations. Although the patient was largely asymptomatic, this lesion was treated with fulguration and triamcinolone injection. The patient has been successfully weaned off cyclosporine and remains asymptomatic after 18 months of follow-up.

3. Discussion

To our knowledge, there are only a few reports of patients with EC that we managed with cyclosporine.^{3,4} In previous studies, recurrence of symptoms occurred due to early tapering or discontinuation of the steroids.¹ Our patient responded to oral steroids with a slow taper, however, symptoms recurred upon discontinuation of two separate courses of prednisone. Aleem et al. previously reported a case of successful management of EC using cyclosporine on a woman with multiple comorbidities and a 4-month history of EC.⁴ Cyclosporine has a narrow therapeutic index so close monitoring of blood concentration periodically is recommended to avoid adverse effects such as nephrotoxicity or neurotoxicity. This case further supports the efficacy and safety of cyclosporine in adult patients with a prolonged history of disease.

Treatment for EC is not always conservative. Rossanes et al. presented a criterion in which surgical intervention such as a partial or total cystectomy is necessitated: the presence of persistent severe lower urinary tract symptoms which adversely impact quality of life and that do

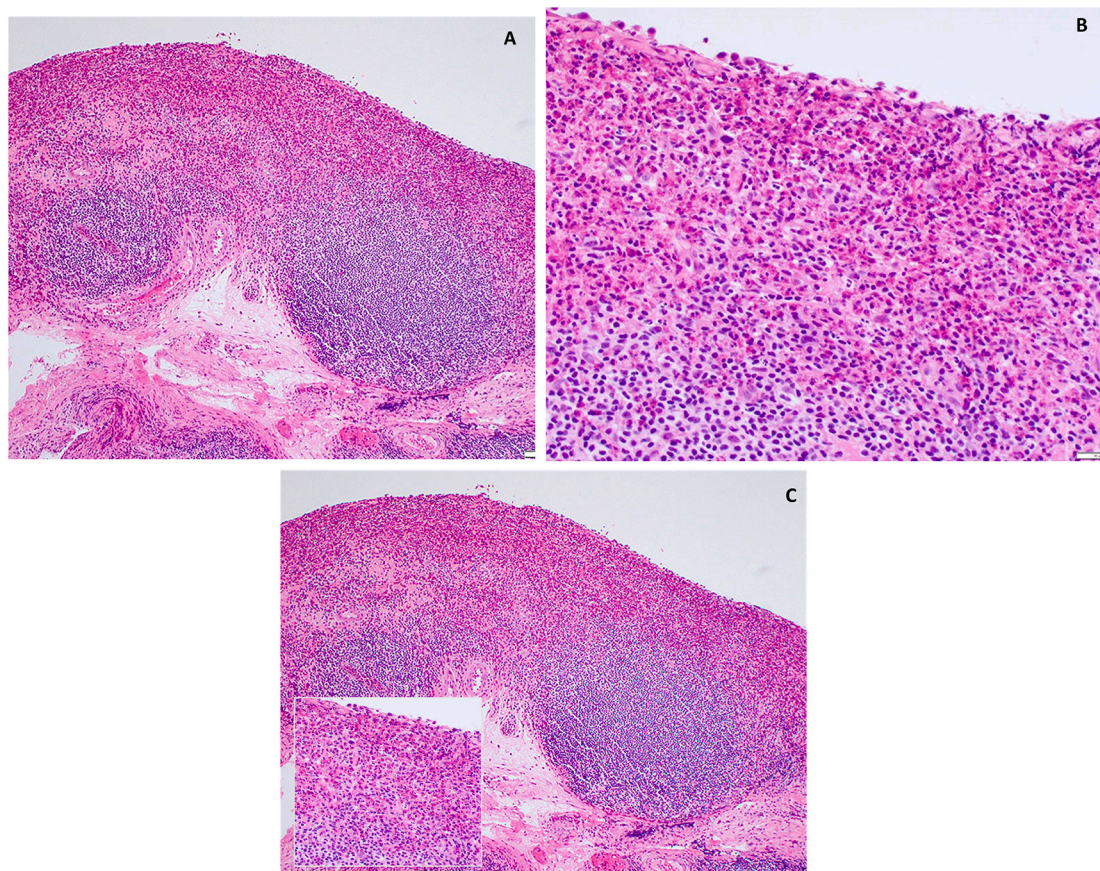


Fig. 3. Left posterior wall bladder mucosal biopsy showing inflammation; prominent lymphoid follicles with dense eosinophilic infiltrate. [H&E 400× tissue magnification superimposed on 100× magnification].

not resolve with conservative treatment.⁵ In this case, our patient presented with debilitating urinary symptoms that negatively impacted her quality of life including frequent UTIs. However, she was interested in pursuing conservative treatment options in the hopes of sparing her bladder. Her case demonstrates that low-dose cyclosporine can be an effective paradigm in the treatment of EC and formal clinical trials are needed to standardize treatment.

4. Conclusion

This case report demonstrating a complete resolution of symptoms and self-reported improved quality of life after initiation of cyclosporine therapy should motivate physicians and patients to explore the use of cyclosporine in managing refractory eosinophilic cystitis.

Informed consent statement

Written informed consent has been obtained from the patient to publish this case report.

Funding

This research did not receive any specific grant from funding agencies in the public, commercial, or not-for-profit sectors.

Declaration of competing interest

The authors declare no conflict of interest.

References

1. Mosholt KS, Dahl C, Azawi NH. Eosinophilic cystitis: three cases, and a review over 10 years. *BMJ Case Rep.* 2014;2014.
2. Schmitz-Dräger BJ, Skutetzki A, Rieker RJ, et al. Eosinophilic cystitis mimicking bladder cancer—considerations on the management based upon a case report and a review of the literature. *Virchows Arch*; 2021. <https://link.springer.com/content/pdf/10.1007/s00428-021-03049-x.pdf>, 2021. Accessed September 2, 2021.
3. Pomeranz A, Eliakim A, Uziel Y, et al. Eosinophilic cystitis in a 4-year-old boy: successful long-term treatment with cyclosporin A. *Pediatrics.* 2001;108(6):E113.
4. Aleem S, Kumar B, Fasano MB, Takacs E, Azar AE. Successful use of cyclosporine as treatment for eosinophilic cystitis: a case report. *World Allergy Organ J.* 2016;9:22.
5. Rossanese M, Palumbo V, Sioletti S, Crestani A, Giannarini G, Ficarra V. Surgical treatment of eosinophilic cystitis in adults: a report of two cases and a literature review. *Urol Int.* 2019;102(1):122–124.