

Favourable outcome in retinal macrovessel-related choroidal neovascularization

Waseem M. Al-Zamil, Moustafa S. Magliyah¹

Access this article online
Quick Response Code:

Website: www.saudijophthalmol.org
DOI: 10.4103/1319-4534.305037

Abstract:

Congenital retinal macrovessel (CRM) is an aberrant retinal blood vessel, which crosses the central macula and has tributaries extending on both sides of the horizontal raphe. It is a rare vascular condition, usually asymptomatic and incidentally discovered on routine fundus exam. This report describes a case of venous CRM associated with visual impairment secondary to choroidal nonvascular membrane (CNV). Treatment with intravitreal injection of aflibercept resulted in a favourable visual as well as anatomical outcome.

Keywords:

Aberrant retinal vessel, choroidal nonvascular membrane, congenital retinal macrovessel

INTRODUCTION

In 1869, Mauthner^[1] first described a large aberrant retinal blood vessel, frequently a vein, crossing the horizontal raphe in the region of the macula. Brown *et al.*^[2] reported the fluorescein angiographic and clinical features of congenital retinal macrovessel (CRM) in 1982. The condition is rare and usually unilateral. CRM is believed to originate from abnormal fetal development between the 15th and 16th weeks of embryogenesis.^[3]

CRM is often an incidental finding and often does not cause impairment in vision. Previous case reports have shown associations of CRM with cavernous hemangioma^[4], branch retinal artery occlusion^[5], vitreous hemorrhage^[6], central serous chorioretinopathy (CSCR)^[7,8], retinal ischemia^[9], macroaneurysm^[10] rhegmatogenous retinal detachments^[11] and reduced vision due to obscuration of the fovea by CRM.^[12] A recent study^[13] has shown an association between CRM and venous malformation of the brain. Here, we report a case of CRM complicated by choroidal nonvascular membrane (CNV). To our knowledge, this is the first case of CRM complicated by CNV.

This is an open access journal, and articles are distributed under the terms of the Creative Commons Attribution-NonCommercial-ShareAlike 4.0 License, which allows others to remix, tweak, and build upon the work non-commercially, as long as appropriate credit is given and the new creations are licensed under the identical terms.

For reprints contact: WKHLRPMedknow_reprints@wolterskluwer.com

CASE REPORT

A 41-year-old healthy male presented with decreased vision in his right eye of two weeks duration. His past and family medical histories were unremarkable. He was a non-smoker, wasn't exposed to a stressful events or use steroids before. On ophthalmic examination, the best corrected visual acuity (BCVA) was 20/100 in the right eye and 20/20 in the left eye. Intraocular pressures was 15 mmHg in the right eye and 16 mmHg in the left eye by tono-pen. Slit-lamp examination of the anterior segment of both eyes was normal. Fundus examination was normal in the left eye but revealed a superior aberrant retinal blood vessel which traverses the horizontal raphe adjacent to the fovea in the right eye [Figure 1]. Spectral domain optical coherence tomography (SD-OCT) of right eye was performed and showed subretinal fluid (SRF) and CNV complex [Figure 2a]. Fundus Fluorescein Angiography (FFA) has shown foveal leakage in the late venous phase with an adjacent area of blockage due to subretinal hemorrhage which was not manifest clinically [Figure 3]. Magnetic Resonance Imaging (MRI) of the brain was done to detect vascular malformations was performed and evaluated by a neuroradiologist and did not show vascular abnormalities.

How to cite this article: Al-Zamil WM, Magliyah MS. Favourable outcome in retinal macrovessel-related choroidal neovascularization. Saudi J Ophthalmol 2020;34:139-41.

Imam Abdulrahman Bin Faisal University, ¹Prince Mohammed Medical City, Saudi Arabia

Address for correspondence:
Dr. Moustafa Magliyah,
Vitreoretinal Division, King
Khaled Eye Specialist Hospital,
PO Box 7191 Riyadh 11462,
Kingdom of Saudi Arabia.
E-mail: mussam08@gmail.com

Submitted: 03-Oct-2018

Revised: 23-Jan-2019

Accepted: 22-Apr-2019

Published: 28-Dec-2020

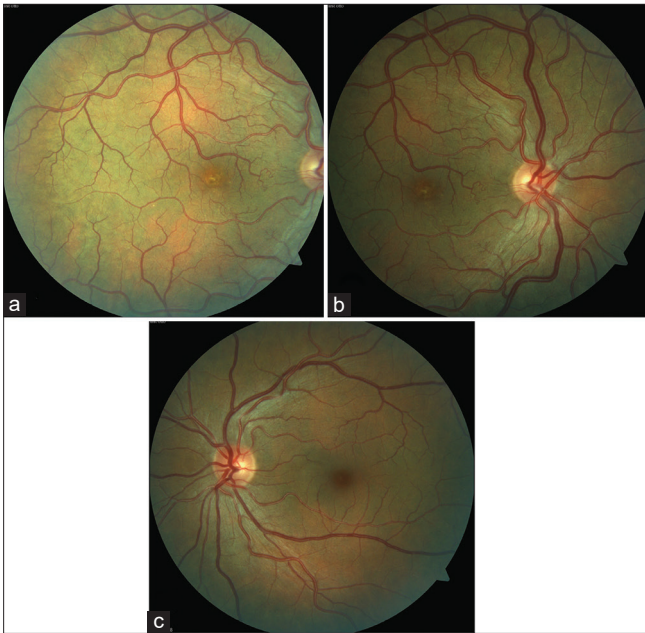


Figure 1: Fundus photograph at presentation shows (a) the retinal macrovessel which was a branch of the superotemporal vein with two tributaries crossing the horizontal raphe around the fovea in the right eye, (b) shows normal retinal vasculature nasal to the disc of the same eye. (c) shows normal retinal vasculature in the left eye

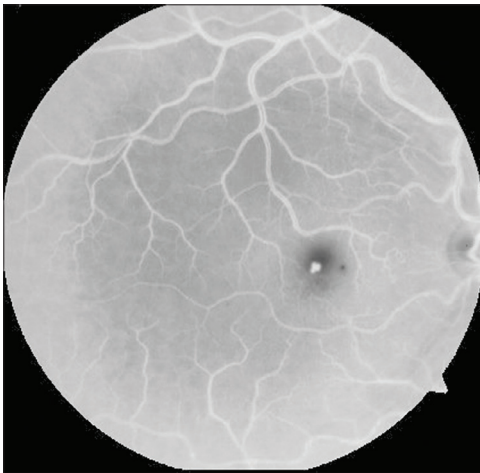


Figure 3: FFA of the right eye in the late venous phase showing foveal leakage with an adjacent area of blockage due to subretinal hemorrhage

After being informed about the risks and benefits of intravitreal aflibercept as a treatment option, the patient agreed to receive an injection of intravitreal aflibercept (2 mg/0.05 ml) under sterile conditions in his right eye. At one month follow up, BCVA improved to 20/40 with significant decrease in the subretinal fluid. A second intravitreal injection of aflibercept was administered one month later. One month following the second dose, BCVA improved to 20/25 in the right eye with complete resolution of subretinal fluid [Figure 2b]. This picture was maintained till 12 months follow up with no signs or symptoms of recurrences.

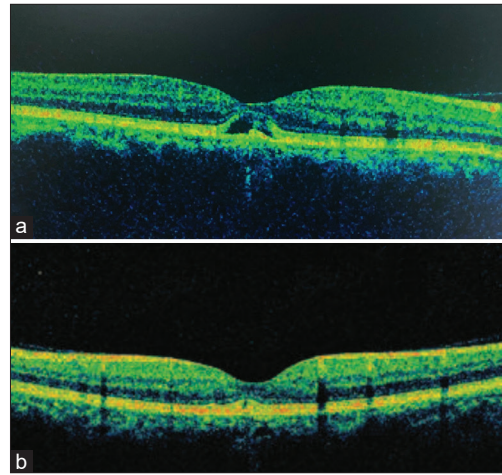


Figure 2: SD-OCT of the right eye on presentation (a) shows an active CNV complex with SRF. (b) shows complete resolution of SRF

DISCUSSION

Congenital retinal macrovessel is anomalous retinal blood vessel, which developed during embryogenesis. Usually, this lesion is considered to be isolated and asymptomatic. In this case, decreased vision was developed from CNV likely complicating a venous tributary branching off the macrovessel causing alterations in the Bruch's membrane and increased vascular permeability which was reduced by administration of intravitreal aflibercept injections. Patient's age, absence of risk factors and the presence of subretinal hemorrhage on FFA have made the diagnosis of CSCR unlikely in this case.

The occurrence of vitreous hemorrhage and rhegmatogenous retinal detachment expose the patient to the risks of retinal surgeries with vision not fully restored.^[6,11] Association of CRM with branch retinal artery occlusion or retinal ischemia results in irreversible retinal damage, decreased vision and visual field loss. The favourable outcome in our case indicates that decreased vision in cases with CRM due to CNV is reversible and carries a good prognosis, especially if it was discovered and treated early. It is very important for ophthalmologists who find CRM in patients who report recent decrease in visual acuity to look for CNV as it has a relatively good prognosis in these cases and prompt treatment with Anti-VEGF could improve vision in these patients. Brain MRI is also advisable for all patients who have CRM as there is 24% risk of associated venous malformations.^[12]

Financial support and sponsorship

Nil.

Conflicts of interest

There are no conflicts of interest.

REFERENCES

1. Mauthner L. Lehrbuch der ophthalmologie. Tendler, Vienna; 1869:249.
2. Brown GC, Donoso LA, Magargal LE, Goldberg RE, Sarin LK. Congenital retinal macrovessels. Arch Ophthalmol 1982;100:1430-6.
3. de Crecchio G, Alfieri MC, Cennamo G, Forte R. Congenital macular

- macrovessels. *Graefes Arch Clin Exp Ophthalmol* 2006;244:1183–7.
4. Thanos A, Randhawa S, Drenser KA. Macular retinal cavernous hemangioma associated with congenital retinal macrovessel. *JAMA Ophthalmol* 2016;134:e161683. <https://doi.org/10.1001/jamaophthalmol.2016.1683>.
 5. Goel N, Kumar V, Seth A, Ghosh B. Branch retinal artery occlusion associated with congenital retinal macrovessel. *Oman J Ophthalmol* 2014;7:96e97.
 6. Goel N, Kumar V, Ghosh B. Congenital retinal macrovessel associated with vitreous hemorrhage. *J AAPOS* 2017;21:83e85.
 7. Arai J, Kasuga Y, Koketsu M, Yoshimura N. Development and spontaneous resolution of serous retinal detachment in a patient with a congenital retinal macrovessel. *Retina* 2000;20:674e676.
 8. Kumar V, Ghosh B, Raina U, Goel N. Central serous chorioretinopathy in a patient with congenital retinal macrovessel. *Can J Ophthalmol* 2009;44:e57. <https://doi.org/10.3129/i09-146>, PubMed PMID:20051997.
 9. Hasegawa T, Ogata N. Retinal deep capillary ischemia associated with occluded congenital retinal macrovessel. *Retin Cases Brief Rep* 2017;11:277–80. <https://doi.org/10.1097/ICB.0000000000000343>, PubMed PMID: 28521331; Summer.
 10. Goel N, Kumar V, Seth A, Ghosh B. Intravitreal bevacizumab in congenital retinal macrovessel with retinal arteriolar macroaneurysm. *Saudi J Ophthalmol* 2015;29:292e294.
 11. Kumar V, Goel N. Congenital retinal macrovessel in a patient with rhegmatogenous retinal detachment. *Ind J Ophthalmol* 2018;66(12):1860–1.
 12. Chawla R, Bypareddy R, Tripathy K, Daggumili SS, Tomar AS. Optical coherence tomography angiography imaging of congenital retinal macrovessel. *Ophthal Surg Las Imag Retina* 2016;47:972e973.
 13. Pichi F, Freund KB, Ciardella A, et al. Congenital retinal macrovessel and the association of retinal venous malformations with venous malformations of the brain. *JAMA Ophthalmol* 2018;136:372–9. <https://doi.org/10.1001/jamaophthalmol.2018.0150>, PubMed PMID: 29494725; PubMed Central PMCID: PMC5876911.