



Long-term complete response to gefitinib after treatment termination in a patient with recurrent post-operative *EGFR*-mutated lung adenocarcinoma: case report and literature review

Kenji Watanabe¹, Naoki Haratake¹, Tomoyoshi Takenaka¹, Taichi Nagano¹, Yuka Oku¹, Keisuke Kosai¹, Yuki Ono¹, Mikihiro Kohno¹, Yoshinao Oda²

¹Department of Surgery and Science, Graduate School of Medical Sciences, Kyushu University, Fukuoka, Japan; ²Department of Anatomic Pathology, Graduate School of Medical Sciences, Kyushu University, Fukuoka, Japan

Correspondence to: Tomoyoshi Takenaka, MD, PhD. Department of Surgery and Science, Graduate School of Medical Sciences, Kyushu University, 3-1-1 Maidashi, Higashi-ku, Fukuoka 812-8582, Japan. Email: ttake@surg2.med.kyushu-u.ac.jp.

Abstract: Non-small-cell lung cancer (NSCLC) with epidermal growth factor receptor (*EGFR*) mutations is highly sensitive to *EGFR*-tyrosine kinase inhibitor (*EGFR*-TKI). However, few cases of advanced NSCLC completely cured by *EGFR*-TKIs have been reported. We present an extremely rare case of lung adenocarcinoma that was completely cured by gefitinib administration. A 36-year-old Japanese woman was diagnosed with clinical Stage IIIB (T2N3M0) lung adenocarcinoma originating from the left upper lobe in April 2006. After the two cycles of chemotherapy, it was down-staged to ycStage IA (T1N0M0). She underwent a thoracotomy with left upper lobectomy, pulmonary angioplasty, and mediastinal nodal dissection in July 2006 [ypStage IIIA (T3N1M0)]. Eighteen months later, she was found to have lymphadenopathy of the right supraclavicular nodes. Fine needle aspiration cytology of the lymph node indicated adenocarcinoma. She started gefitinib therapy for recurrent lung cancer with *EGFR* mutation (exon 19 deletion) in January 2008. Four months afterward, computed tomography (CT) showed her right supraclavicular nodes had shrunk dramatically. Treatment with gefitinib was continued. Thereafter, no disease progression was observed throughout her approximately 8-year gefitinib treatment, and gefitinib was terminated in November 2016. Although the patient received no other treatment, she has suffered no recurrence in the 4 years since. A review of the literature, including our case, is also presented.

Keywords: Lung cancer; epidermal growth factor receptor (*EGFR*); gefitinib; complete response; case report

Submitted Jul 01, 2021. Accepted for publication Aug 20, 2021.

doi: [10.21037/tcr-21-1140](https://doi.org/10.21037/tcr-21-1140)

View this article at: <https://dx.doi.org/10.21037/tcr-21-1140>

Introduction

Non-small-cell lung cancer (NSCLC) with epidermal growth factor receptor (*EGFR*) mutations is highly sensitive to *EGFR*-tyrosine kinase inhibitor (*EGFR*-TKI). However, few cases of advanced NSCLC completely cured by *EGFR*-TKIs have been reported. Here, we report a case of a post-operative recurrence of *EGFR*-mutated lung adenocarcinoma that achieved a clinically complete response to gefitinib that has continued for 4 years after terminating gefitinib treatment. We also present a literature review. We present the following case in accordance with

the CARE reporting checklist (available at <https://dx.doi.org/10.21037/tcr-21-1140>).

Case presentation

A 36-year-old Japanese woman was diagnosed with clinical Stage IIIB (T2N3M0) lung adenocarcinoma originating from the left upper lobe in April 2006. Computed tomography (CT) showed a 30-mm mass in the left upper lobe, enlarged right tracheobronchial nodes and left supraclavicular nodes. Mediastinoscopy with biopsy

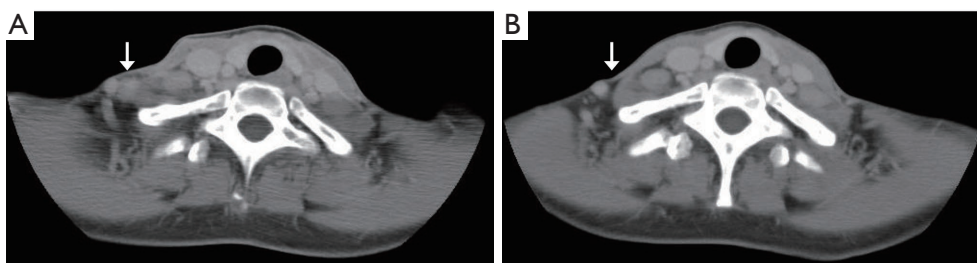


Figure 1 Cervical CT before and after initiating gefitinib. (A) Before initiating gefitinib, post-operative recurrence in the right supraclavicular nodes (shown by arrow) was observed. (B) After initiating gefitinib, the right supraclavicular nodes extremely shrank (shown by arrow). CT, computed tomography.

from the left supraclavicular nodes revealed metastatic adenocarcinoma; N3 disease was confirmed. After the two cycles of chemotherapy (cisplatin + gemcitabine + vinorelbine), it was down-staged to ycStage IA (T1N0M0). She underwent a thoracotomy with left upper lobectomy, pulmonary angioplasty, and mediastinal nodal dissection in July 2006 [ypStage IIIA (T3N1M0)]. Approximately 11 months after the surgery, post-operative oligo-recurrence of lung cancer with left supraclavicular nodes metastasis was observed. A left supraclavicular and both sides of cervical nodal dissection was performed in July 2007.

In December 2007, she was found to have lymphadenopathy of the right supraclavicular nodes. As fine-needle aspiration cytology showed adenocarcinoma, she was diagnosed with post-operative recurrence. The right supraclavicular nodes are observed 15mm in size, and no other sites of recurrence were observed in CT (*Figure 1A*). *EGFR* mutation (exon 19 deletion) was detected in the primary tumor specimens, so gefitinib was initiated in January 2008. Four months later, CT showed the right supraclavicular nodes had shrunk dramatically (*Figure 1B*), and the treatment with gefitinib was continued. Gefitinib initiation was reduced to once every 2 days in November 2011 due to seborrheic dermatitis (grade 3). After that, no disease progression was observed throughout the gefitinib treatment, for approximately 5 years. Positron emission tomography-CT showed no recurrence in June 2014. Gefitinib was terminated in November 2016 at the patient's wish. She received no other anti-tumor treatment. In May 2021, CT showed no signs of tumor progression or new lesion. As no recurrence has been observed for the 4 years since terminating gefitinib, gefitinib treatment has apparently cured her recurrent NSCLC.

All procedures performed in studies involving human participants were in accordance with the ethical standards of the institutional and/or national research committee(s)

and with the Helsinki Declaration (as revised in 2013). Written informed consent was obtained from the patient for publication of this case report and accompanying images. A copy of the written consent is available for review by the editorial office of this journal.

Discussion

We present here an extremely rare case of post-operative recurrence of *EGFR*-mutated lung adenocarcinoma that was evidently cured with gefitinib therapy. The right supraclavicular metastatic lymph nodes, in which adenocarcinoma was found with fine needle aspiration, shrank remarkably with gefitinib administration. Even after terminating gefitinib, disease progression has not been observed for 4 years.

To our knowledge, only two other cases of *EGFR*-mutated lung adenocarcinoma have achieved complete responses to *EGFR*-TKI with long-lasting progression-free survival (PFS) after terminating *EGFR*-TKI treatment (*Table 1*) (1,2). All of these cases were post-operative recurrences with exon-19 deletions. According to the results of the WJTOG3405 trial, overall survival of patients with recurrent lung cancers was better than that of patients with Stage IIIB/IV disease (3), which may reflect their differences in tumor volume. Post-operative recurrences are usually diagnosed at routine follow-ups, at intervals of several months after resections; treatment for recurrent disease therefore starts with lower tumor burden than that for Stage IIIB/IV disease. Thus, in the current case, the low tumor burden might have been associated with the dramatic response to *EGFR*-TKI. Adjuvant osimertinib significantly improved disease-free survival among patients with *EGFR* mutation-positive NSCLC in ADAURA trial [not related (NR) *vs.* 19.6 months; hazard ratio for disease recurrence

Table 1 Published case reports of clinically complete responses of *EGFR*-mutated NSCLC after terminating EGFR-TKI treatment

Case	Authors (published year)	Age	Gender	Diagnosis	rTNM	<i>EGFR</i> subtype	EGFR-TKI, administration period	PFS after terminating EGFR-TKI	Refs no.
1	Kuwata <i>et al.</i> [2016]	75	M	Post-operative recurrence in the right supraclavicular nodes	T0N3M0	Ex 19 del	Gefitinib, 18 months	More than 120 months	(1)
2	Yamanaka <i>et al.</i> [2019]	73	F	Post-operative liver metastases	T0N0M1c (HEP)	Ex 19 del	Afatinib, 24 months	More than 18 months	(2)
3	Current case	36	F	Post-operative recurrence in the right supraclavicular nodes	T0N3M0	Ex 19 del	Gefitinib, 107 months	54 months	–

EGFR, epidermal growth factor receptor; NSCLC, non-small-cell lung cancer; EGFR-TKI, EGFR-tyrosine kinase inhibitor; rTNM, recurrence tumor-node-metastasis classification; HEP, hepatic metastasis; ex 19 del, exon 19 deletion; PFS, progression-free survival.

or death, 0.17; 99.06% confidence interval (CI), 0.11 to 0.26; $P < 0.001$] (4). This also might suggest that tumor burden have a relationship with the efficacy of EGFR-TKI. Whether the *EGFR* subtype (exon 19 deletion) affected the result is unclear. No pattern was observed with respect to recurrence sites, EGFR-TKI type, or EGFR-TKI administration period.

Discontinuation of EGFR-TKI can cause some patients to suffer rapid disease progression within a short time, which has been called a disease flare (5). In the current case, disease flare was not observed, and complete response has persisted for 4 years after stopping gefitinib. This suggests that the tumor may have completely disappeared. Whether disease flare will occur in cases of complete response is unclear; however, when terminating an EGFR-TKI, switching to other treatments or careful follow-up is clearly advised. As predictive factors for successful discontinuation of EGFR-TKIs have not been determined, further research is warranted.

Conclusions

We report a patient with recurrent NSCLC that harbored activating *EGFR*-mutations, who had a long-enduring complete response after terminating gefitinib. Further research is needed to identify factors that indicate EGFR-TKI can be successfully discontinued.

Acknowledgments

The authors would like to thank Edanz Group (<https://en-author-services.edanz.com/ac>) for editing a draft of this manuscript.

Funding: None.

Footnote

Reporting Checklist: The authors have completed the CARE reporting checklist. Available at <https://dx.doi.org/10.21037/tcr-21-1140>

Peer Review File: Available at <https://dx.doi.org/10.21037/tcr-21-1140>

Conflicts of Interest: All authors have completed the ICMJE uniform disclosure form (available at <https://dx.doi.org/10.21037/tcr-21-1140>). The authors have no conflicts of interest to declare.

Ethical Statement: The authors are accountable for all aspects of the work in ensuring that questions related to the accuracy or integrity of any part of the work are appropriately investigated and resolved. All procedures performed in studies involving human participants were in accordance with the ethical standards of the institutional and/or national research committee(s) and with the Helsinki Declaration (as revised in 2013). Written informed consent was obtained from the patient for publication of this case report and accompanying images. A copy of the written consent is available for review by the editorial office of this journal.

Open Access Statement: This is an Open Access article distributed in accordance with the Creative Commons Attribution-NonCommercial-NoDerivs 4.0 International License (CC BY-NC-ND 4.0), which permits the non-

commercial replication and distribution of the article with the strict proviso that no changes or edits are made and the original work is properly cited (including links to both the formal publication through the relevant DOI and the license). See: <https://creativecommons.org/licenses/by-nc-nd/4.0/>.

References

1. Kuwata T, Yoneda K, Kobayashi K, et al. Achievement of cure with gefitinib in advanced lung adenocarcinoma harboring an activating *EGFR* mutation: a case report. *Case Rep Oncol* 2016;9:565-7.
2. Yamanaka Y, Seki Y, Ishikawa T, et al. Long-lasting response to afatinib that persisted after treatment discontinuation in a case of *EGFR*-mutated lung adenocarcinoma. *BMJ Case Rep* 2019;12:227383.
3. Yoshioka H, Shimokawa M, Seto T, et al. Final overall survival results of WJTOG3405, a randomized phase III trial comparing gefitinib versus cisplatin with docetaxel as the first-line treatment for patients with stage IIIB/IV or postoperative recurrent *EGFR* mutation-positive non-small-cell lung cancer. *Ann Oncol* 2019;30:1978-84.
4. Wu YL, Tsuboi M, He J, et al. Osimertinib in resected *EGFR*-mutated non-small-cell lung cancer. *N Engl J Med* 2020;383:1711-23.
5. Chaft JE, Oxnard GR, Sima CS, et al. Disease flare after tyrosine kinase inhibitor discontinuation in patients with *EGFR*-mutant lung cancer and acquired resistance to erlotinib or gefitinib: implications for clinical trial design. *Clin Cancer Res* 2011;17:6298-303.

Cite this article as: Watanabe K, Haratake N, Takenaka T, Nagano T, Oku Y, Kosai K, Ono Y, Kohno M, Oda Y. Long-term complete response to gefitinib after treatment termination in a patient with recurrent post-operative *EGFR*-mutated lung adenocarcinoma: case report and literature review. *Transl Cancer Res* 2021;10(11):5010-5013. doi: 10.21037/tcr-21-1140