

Successful bipolar ablation for ventricular tachycardia with potential substrate identification by pre-procedural cardiac magnetic resonance imaging

Kazuo Sakamoto
Masatsugu Nozoe
Yoshitomo Tsutsui
Nobuhiro Suematsu
Toru Kubota
Masanori Okabe
Yusuke Yamamoto

Division of Cardiology, Cardiovascular and Aortic Center, Saiseikai Fukuoka General Hospital, Fukuoka, Japan

Abstract: Cardiac magnetic resonance imaging (MRI) is a useful tool for detecting the arrhythmogenic substrate in cardiac sarcoidosis. We herein present a case of bipolar radiofrequency catheter ablation for ventricular tachycardia (VT) complicated with cardiac sarcoidosis, guided by pre-procedural cardiac MRI. Neither echocardiography nor endocardial voltage mapping suggested a septal VT substrate. However, MRI alone detected intramural lesions in the septum. Although application of endocardial energy failed to treat the VT, bipolar ablation targeting the potential substrate identified by MRI successfully eliminated the VT. Even when no abnormalities are depicted on echocardiography and endocardial voltage mapping, intramural scar tissue identified by cardiac MRI could be critical for VT.

Keywords: cardiac sarcoidosis, VT, MRI, bipolar ablation

Introduction

Catheter ablation is effective in terminating ventricular tachycardia (VT) storm in cardiac sarcoidosis.¹ Identification of scar tissue and low voltage area is important for detecting critical VT circuit.² Echocardiography, ventricular angiography, and cardiac magnetic resonance imaging (MRI) provide ample information about damaged tissue.³⁻⁵ We report a case of successful VT ablation targeting the potential substrate identified only by MRI in a patient with cardiac sarcoidosis. Written informed consent has been provided by the patient to have the case details and accompanying images published for this report.

Case presentation

A 41-year-old female patient with a history of aborted sudden death was admitted to our hospital for the third time due to repeated episodes of monomorphic VT (135 bpm, left bundle branch block morphology) and frequent implantable cardioverter defibrillator (ICD) shocks (Figure 1). Three years earlier, she was admitted to our hospital due to ventricular fibrillation (VF) for the first time. She had no family history of sudden cardiac death and QT prolongation. The patient was diagnosed with cardiac sarcoidosis based on a histological diagnosis of pulmonary sarcoidosis, reduced left ventricular ejection fraction (LVEF), and sustained VT without manifestation of other causes.⁶ An ICD was implanted, and pharmacological therapy with corticosteroid (prednisolone 10 mg/day) and amiodarone 100 mg/day was started. One year later, she received ICD shock for VF, and the dose of amiodarone was increased to 200 mg/day. As she

Correspondence: Kazuo Sakamoto
Division of Cardiology, Cardiovascular and Aortic Center, Saiseikai Fukuoka General Hospital, 1-3-46 Tenjin, Chuo-ku, Fukuoka 810-0001, Japan
Tel +81 92 771 8151
Fax +81 92 716 0185
Email kazuos@cardiol.med.kyushu-u.ac.jp

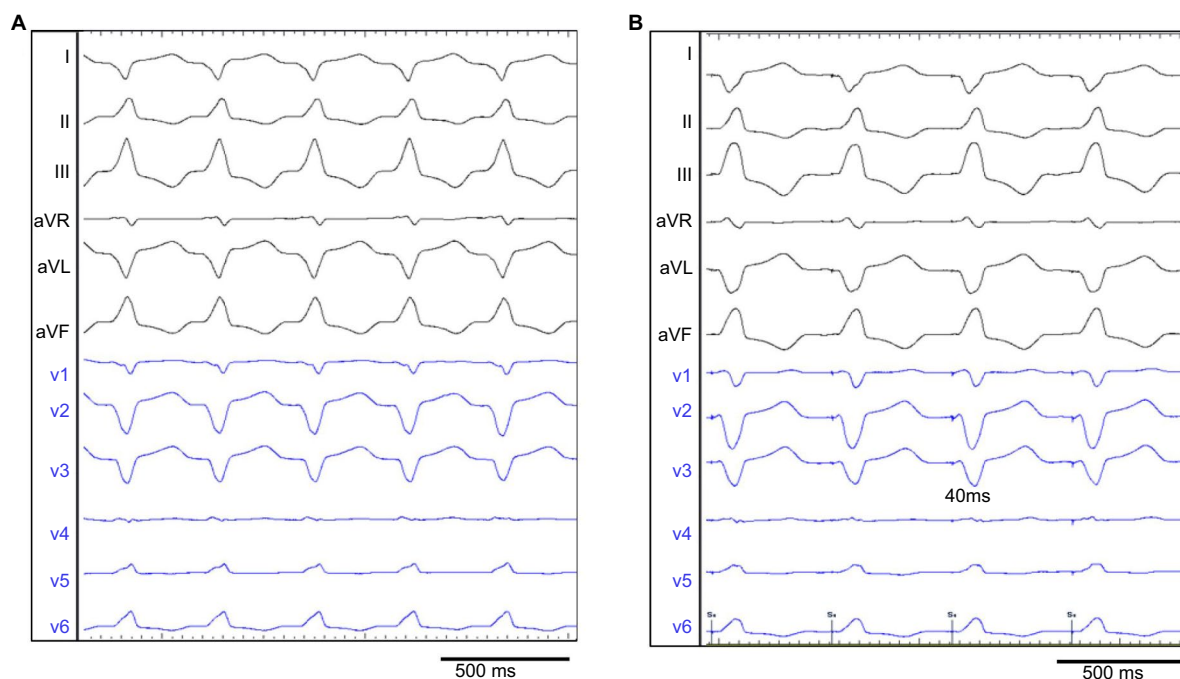


Figure 1 Twelve-lead electrocardiograms during VT (**A**). The VT manifests a left bundle branch block configuration and an inferior axis with a QS pattern in the v1 lead. The Pace mapping from the RV of the RV–LV hinge point (**B**). The latter matches the clinical VT perfectly, with short pacing-QRS intervals (40 ms). Black lines are limb leads and blue lines are precordial leads.

Abbreviations: LV, left ventricle; RV, right ventricle; VT, ventricular tachycardia.

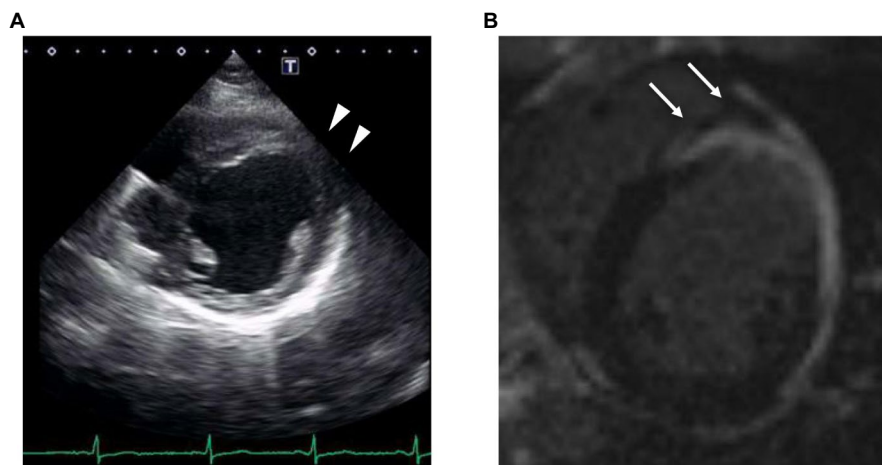


Figure 2 Focal aneurysm (arrow head) at the anterior left ventricle on echocardiography (**A**). Transmurial extension of delayed gadolinium enhancement (arrows) on cardiac magnetic resonance imaging (**B**).

developed lethal arrhythmia despite adequate doses of corticosteroid and antiarrhythmic drugs, we decided to perform catheter ablation for drug-refractory VT. Echocardiography and cardiac MRI revealed a focal aneurysm in the anterior left ventricle (LV) due to cardiac sarcoidosis (Figure 2A and B). Therefore, we suspected the aneurysm to be the VT substrate.

The predetermined strategy was 1) to detect the arrhythmogenic substrate and the VT circuit and 2) to deliver radiofrequency (RF) energy to the critical isthmus and the arrhythmogenic substrate. Detailed endocardial mapping was performed using diagnostic catheters placed in the coronary sinus, right ventricle (RV), and His bundle

region. During RV pacing, a voltage map from RV to LV was acquired using a multipolar catheter (PentaRay NAV; Biosense Webster) and CARTO3 (Biosense Webster). The voltage map revealed a low voltage area (<1.5 mV) consistent with the anterior focal aneurysm (Figure 3A and B). Local potentials outside the aneurysm, including that in the RV, were preserved, and there were no identifiable delayed or fractionated electrograms. Although significant delayed or fractionated electrograms were observed inside the aneurysm, pace map inside the aneurysm did not match with the clinical VT. Then, the clinical VT was induced by extra stimulation from the RV apex. Local potentials within

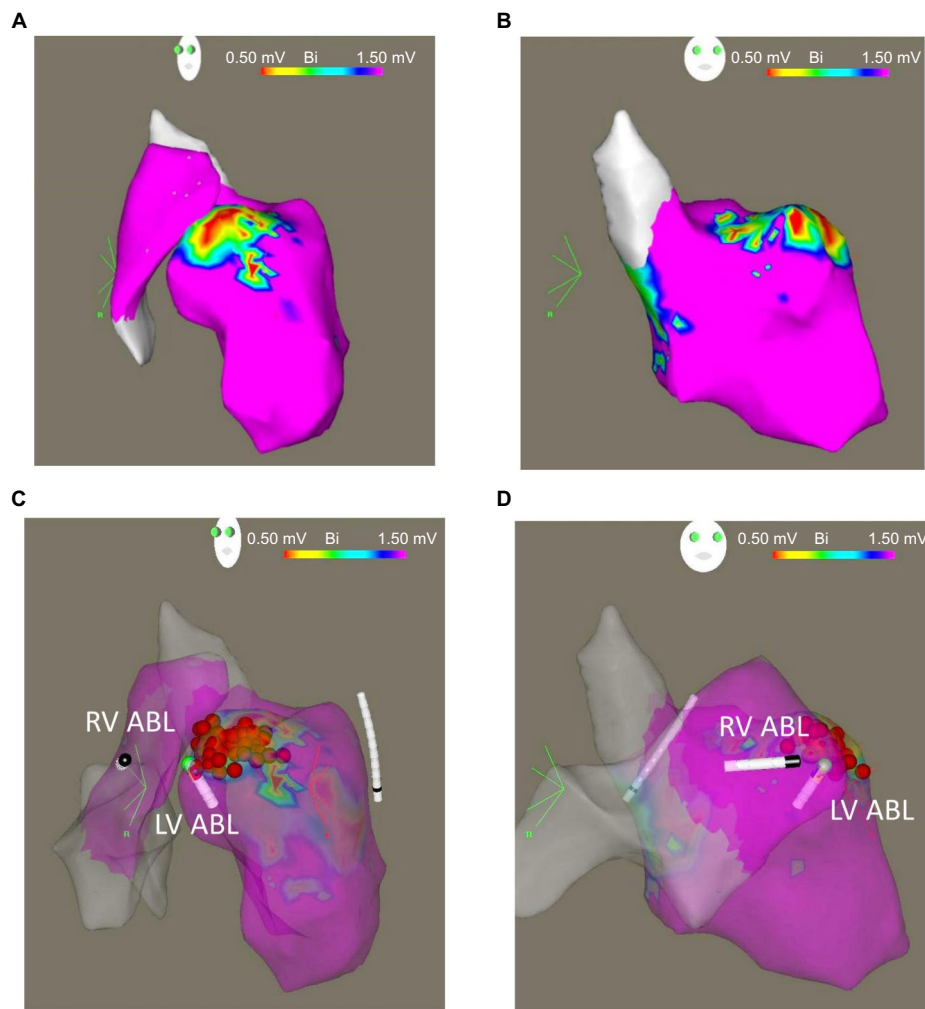


Figure 3 Voltage maps showing a localized low voltage area in the left ventricular aneurysm in LAO (A, with RV) and RAO (B, without RV) view. The voltage maps of the successfully ablated site and ablation catheters in LAO (C) and RAO (D).

Abbreviations: LAO, left anterior oblique; LV, left ventricle; LV ABL, left ventricular ablation catheter; RAO, right anterior oblique; RV, right ventricle; RV ABL, right ventricular ablation catheter.

the aneurysm during VT were fractionated, but entrainment pacing inside the aneurysm failed without local capture. Thereafter, the hemodynamics deteriorated because of VT. We decided to deliver RF energy to the aneurysm as potential arrhythmogenic substrate, despite unmatched pace mapping and unsuccessful entrainment study there. Although VT was terminated within 10 s of a single RF application (35 W) to the aneurysm, the same VT was induced after repeated RF delivery.

As the application of endocardial energy failed to eliminate the VT, we considered the epicardial approach as the next step. The pre-procedural cardiac MRI showed transmural extension of delayed gadolinium enhancement inside the aneurysm, suggesting that the epicardial myocardium could be the arrhythmogenic substrate. As coronary angiography revealed that the left anterior descending artery ran across the focal aneurysm, we decided against a direct epicardial approach in view of the risk of injury to the coronary artery.

Meanwhile, a short axis view of the delayed gadolinium enhancement image revealed myocardial scarring extending to the upper part of the ventricular septum across the aneurysm (Figure 2B). Furthermore, pace mapping from the RV side of the RV–LV hinge point matched the clinical VT, with short pacing QRS intervals (40 ms; Figure 1B). Taking these data into account, we hypothesized that the VT reentrant circuit could include the intramural upper septum and the VT exit at the RV–LV hinge point. Although we initially delivered RF energy with a unipolar system at the RV–LV hinge point from the LV side to make continuous ablation areas, the unipolar ablation was ineffective. In addition, as the voltage map from the RV was completely normal, we suspected that the VT reentrant circuit might be located partially in the depth of the ventricular septum, as was also suggested by cardiac MRI. Therefore, we subsequently chose the bipolar system. The first catheter (NAVISTAR THERMOCOOL; Biosense Webster) was placed at the anterior aneurysm in the

LV and the second irrigation catheter (CoolFlex, Saint Jude Medical) at the RV side of the RV–LV hinge point (Figure 3C and D). The RV ablation catheter was connected as a return electrode to the RF generator instead of to a dispersive patch. Intracardiac electrograms recorded from both sides of the upper septum during VT showed fragmented potentials at the endocardium of the focal aneurysm and a single sharp potential at the RV–LV hinge point. After delivering 35 W of RF energy between the two catheters, the rate of VT slowed during delivery and then terminated. We delivered additional bipolar energy to the intramural lesions during sinus rhythm. After treatment, VT was no longer inducible by any programmed stimulation.

Since the catheter ablation, neither sustained VT nor any ICD therapy has been recorded for 1.5 years. The dose of amiodarone has been able to be reduced from 200 mg/day to 100 mg/day.

Discussion

We successfully treated sustained monomorphic VT using bipolar ablation targeting the upper septum in a patient with cardiac sarcoidosis. Although neither echocardiography nor endocardial voltage mapping suggested a septal VT substrate, MRI alone detected the critical arrhythmogenic substrate.

Cardiac MRI is a useful tool for detecting the scar tissue in patients with cardiac sarcoidosis. Delayed gadolinium enhancement on cardiac MRI has been shown to be a predictor of adverse clinical outcome in cardiac sarcoidosis.⁷ The regions of granulomatous infiltration are thought to evolve into scar tissue that serves as a substrate for reentrant VT.⁸ Patients with cardiac sarcoidosis typically have septal involvement. In the present case, echocardiography and left ventricular angiography showed a focal aneurysm at the anterior LV, but we could not find any abnormalities at the ventricular septum (including thinning of the basal septum). Previous studies have shown that delayed gadolinium enhancement is more sensitive than electrocardiogram or echocardiography in detecting substrates of lethal ventricular arrhythmias.^{9,10} Although 12-lead electrocardiogram during VT suggested that the interventricular upper septum might be the VT origin or circuit, delayed gadolinium enhancement on cardiac MRI confirmed the intramural septal involvement.

From the viewpoint of electrophysiological approaches, several techniques may be considered. Previous studies have found that varying the threshold of bipolar signal amplitude may be useful to identify arrhythmogenic substrates.^{11,12} In

addition, endocardial unipolar voltage mapping has been reported to be useful to detect epicardial substrates.¹³ Furthermore, the critical isthmus of the VT circuit is more often located in the border zones than in the dense scar.¹⁴ Therefore, cardiac MRI and CartoSound (Biosense Webster) scar mapping are of great utility to identify lesions in these areas, which are often unrecognized on traditional angiography or transthoracic echocardiography.¹⁵

Simultaneous unipolar ablation is another option for delivering sufficient energy to intramural lesions.¹⁶ Furthermore, bipolar ablation has been reported to be useful for the elimination of refractory arrhythmias.¹⁷ Bipolar ablation with clinically employed ablation catheters has the theoretical advantage of achieving a more effective power transfer from the tip of one catheter to that of the other catheter, which provides the basis for deeper lesion formation compared to two separate unipolar applications.

In our case, cardiac MRI alone revealed myocardial scarring extending to the upper part of the ventricular septum across the epicardium of the anterior aneurysm. Although we did not perform epicardial ablation because of the risk of injury to the coronary artery, bipolar ablation between the LV and RV delivered energy to the site of gadolinium enhancement and eliminated the VT.

Acknowledgment

The authors are grateful to the technical staff of the catheter laboratory for their cooperation.

Disclosure

The authors report no conflicts of interest in this work.

References

1. Kumar S, Barbhaya C, Nagashima K, et al. Ventricular tachycardia in cardiac sarcoidosis: characterization of ventricular substrate and outcomes of catheter ablation. *Circ Arrhythm Electrophysiol.* 2015;8(1):87–93.
2. Soejima K, Suzuki M, Maisel WH, et al. Catheter ablation in patients with multiple and unstable ventricular tachycardias after myocardial infarction: short ablation lines guided by reentry circuit isthmuses and sinus rhythm mapping. *Circulation.* 2001;104(6):664–669.
3. Hussein A, Jimenez A, Ahmad G, et al. Assessment of ventricular tachycardia scar substrate by intracardiac echocardiography. *Pacing Clin Electrophysiol.* 2014;37(4):412–421.
4. Indik JH, Wichter T, Gear K, Dallas WJ, Marcus FI. Quantitative assessment of angiographic right ventricular wall motion in arrhythmogenic right ventricular dysplasia/cardiomyopathy (ARVD/C). *J Cardiovasc Electrophysiol.* 2008;19(1):39–45.
5. White JA, Fine NM, Gula L, et al. Utility of cardiovascular magnetic resonance in identifying substrate for malignant ventricular arrhythmias. *Circ Cardiovasc Imaging.* 2012;5(1):12–20.
6. Diagnostic standard and guidelines for sarcoidosis. *Jpn J Sarcoidosis Granulomatous Disord.* 2007;27:89–102.

7. Greulich S, Deluigi CC, Gloekler S, et al. CMR imaging predicts death and other adverse events in suspected cardiac sarcoidosis. *JACC Cardiovasc Imaging*. 2013;6(4):501–511.
8. Naruse Y, Sekiguchi Y, Nogami A, et al. Systematic treatment approach to ventricular tachycardia in cardiac sarcoidosis. *Circ Arrhythm Electrophysiol*. 2014;7(3):407–413.
9. Tadamura E, Yamamuro M, Kubo S, et al. Effectiveness of delayed enhanced MRI for identification of cardiac sarcoidosis: comparison with radionuclide imaging. *AJR Am J Roentgenol*. 2005;185(1):110–115.
10. Murtagh G, Laffin LJ, Beshai JF, et al. Prognosis of myocardial damage in sarcoidosis patients with preserved left ventricular ejection fraction: risk stratification using cardiovascular magnetic resonance. *Circ Cardiovasc Imaging*. 2016;9(1):e003738.
11. de Chillou C, Lacroix D, Klug D, et al. Isthmus characteristics of reentrant ventricular tachycardia after myocardial infarction. *Circulation*. 2002;105(6):726–731.
12. Cano O, Hutchinson M, Lin D, et al. Electroanatomic substrate and ablation outcome for suspected epicardial ventricular tachycardia in left ventricular nonischemic cardiomyopathy. *J Am Coll Cardiol*. 2009;54(9):799–808.
13. Hutchinson MD, Gerstenfeld EP, Desjardins B, et al. Endocardial unipolar voltage mapping to detect epicardial ventricular tachycardia substrate in patients with nonischemic left ventricular cardiomyopathy. *Circ Arrhythm Electrophysiol*. 2011;4(1):49–55.
14. Verma A, Marrouche NF, Schweikert RA, et al. Relationship between successful ablation sites and the scar border zone defined by substrate mapping for ventricular tachycardia post-myocardial infarction. *J Cardiovasc Electrophysiol*. 2005;16(5):465–471.
15. Fernández-Armenta J, Berruezo A, Andreu D, et al. Three-dimensional architecture of scar and conducting channels based on high resolution ce-CMR: insights for ventricular tachycardia ablation. *Circ Arrhythm Electrophysiol*. 2013;6(3):528–537.
16. Iyer V, Gambhir A, Desai SP, Garan H, Whang W. Successful simultaneous unipolar radiofrequency ablation of septal ventricular tachycardia using 2 ablation catheters. *Heart Rhythm*. 2014;11(4):710–713.
17. Sivagangabalan G, Barry MA, Huang K, et al. Bipolar ablation of the interventricular septum is more efficient at creating a transmural line than sequential unipolar ablation. *Pacing Clin Electrophysiol*. 2010;33(1):16–26.

International Medical Case Reports Journal

Publish your work in this journal

The International Medical Case Reports Journal is an international, peer-reviewed open-access journal publishing original case reports from all medical specialties. Previously unpublished medical posters are also accepted relating to any area of clinical or preclinical science. Submissions should not normally exceed 2,000 words or

4 published pages including figures, diagrams and references. The manuscript management system is completely online and includes a very quick and fair peer-review system, which is all easy to use. Visit <http://www.dovepress.com/testimonials.php> to read real quotes from published authors.

Submit your manuscript here: <https://www.dovepress.com/international-medical-case-reports-journal-journal>

Dovepress