

# Efficacy of Collagen Membrane Graft in Intraoral Surgery - An Evaluative Study

Pratap N. Movaniya, Tushar R. Makwana, Nimisha N. Desai, Kalpesh G. Makwana, Hirakben B. Patel

Department of Oral and Maxillofacial Surgery, Karnavati School of Dentistry, Gandhinagar, Gujarat, India

## Abstract

**Introduction:** Bovine-derived collagen membrane is usually and regularly used as a temporary cover or dressing for extraoral wounds and burns. It has wide applications because of its usefulness and biocompatibility. This has provoked us to do a study with the use of collagen membrane even for minor intraoral surgical defects. The aim of this evaluative study was to evaluate the clinical efficacy of collagen membrane in intraoral wounds created by removal of various soft tissue lesions. **Materials and Methods:** A total of 25 healthy patients (16 males and 9 females) were taken for this study. This study was confined to secondary defects of the oral mucosa, which occur after excision of premalignant lesions and other conditions, such as benign lesions, reactive proliferations, and incisional biopsy wounds. Only those lesions that were sufficiently large and could not be closed primarily were included in the study. **Results:** The results were evaluated on the day of surgery and in the postoperative period. The usefulness of collagen membrane as an intraoral temporary wound dressing material to promote haemostasis, relieve pain, induce granulation, and assist in rapid epithelialization at the wound site and prevent infection, contracture, scarring, and donor-site morbidity was evaluated, and finally, the efficacy of collagen membrane was tested by the use of Chi-square test and  $P < 0.001$ , which is a statistically and clinically significant value. **Discussion:** Collagen membrane was observed as both biological dressing material and drug carrier. It was found to be a suitable alternative to other graft materials mentioned for the repair of defects in the mucous membrane created by surgical excision of lesions. Therefore, when used judiciously in a controlled clinical situation, collagen membrane is biologically acceptable in nature. It is an alternative to autologous grafts rather than a replacement of other grafts used in the oral cavity.

**Keywords:** Collagen membrane, grafting, oral mucosa, wound healing

## INTRODUCTION

Oral and maxillofacial surgical procedures often result in open wounds. A dressing material should cover these wounds to prevent microbial infection, foreign material contamination, wound contracture and to improve healing. The existence of a variety of wound types with varied healing modes and phases led to the evolution of different types of wound dressings.<sup>[1-4]</sup> Wound dressings before the 1960s were considered passive products that had a minimum role in the healing process.<sup>[1]</sup>

Currently, a variety of approaches have been used including split and full-thickness skin grafts, oral mucosa free grafts, oral connective tissue grafts, and the tissue-engineered grafts.<sup>[1-4]</sup> One of these materials is collagen which is extensively used as temporary dressing material in a lot of surgical fields.<sup>[5-7]</sup>

Various uses of collagen in intraoral surgeries are as an interpositional graft material during palatoplasty, for guided

bone regeneration during maxillary sinus lift for inducing bone formation along with/without certain medicaments, bone augmentation of posterior atrophic mandibular ridge for placement of dental implants. It can also be used as a reconstructive material for orbital floor fractures, in treatment of localized gingival recession, as a scaffold in tissue engineering to generate dental pulp, for coverage of small intraoral soft tissue defects of the oral cavity, and much more. Collagen is also used as a medium for culturing cells such as osteoblasts.<sup>[8,9]</sup>

**Address for correspondence:** Dr. Pratap N. Movaniya,  
Department of Oral and Maxillofacial Surgery, Karnavati School of Dentistry,  
Uvardsad, Gandhinagar - 382 422, Gujarat, India.  
E-mail: drpratapm@gmail.com

Received: 21-05-2020

Last Revised: 04-12-2020

Accepted: 14-12-2020

Published: 24-07-2021

This is an open access journal, and articles are distributed under the terms of the Creative Commons Attribution-NonCommercial-ShareAlike 4.0 License, which allows others to remix, tweak, and build upon the work non-commercially, as long as appropriate credit is given and the new creations are licensed under the identical terms.

**For reprints contact:** WKHLRPMedknow\_reprints@wolterskluwer.com

**How to cite this article:** Movaniya PN, Makwana TR, Desai NN, Makwana KG, Patel HB. Efficacy of collagen membrane graft in intraoral surgery - An evaluative study. *Ann Maxillofac Surg* 2021;11:42-8.

### Access this article online

#### Quick Response Code:



Website:  
www.amsjournal.com

DOI:  
10.4103/ams.ams\_192\_20

It can also be used in leukoplakia,<sup>[6,7,10]</sup> in Oral Submucous Fibrosis (OSMF)<sup>[8,10-15]</sup> in palatal defects,<sup>[16,17]</sup> in perforation of maxillary sinus membrane<sup>[18-20]</sup> and in palatal fistula closure.<sup>[21-23]</sup>

The aims and objectives of the study were based on clinical parameters. The intentions were to make the technique as simple as possible and to determine whether a collagen graft was a suitable dressing material for oral wounds. This study reflects the usefulness of collagen membrane dressing over the surgical defects of the oral mucosa, which would otherwise require other means to close the defects.

## MATERIALS AND METHODS

After approval of the protocol by the institutional review board, 25 consenting healthy adult patients who were free of any systemic disease were enrolled in this evaluative study from the year 2017 to 2019, who required intraoral dressing for the raw surfaces resulting from excision of leukoplakia, oral submucous fibrosis, tumour removal, perforation of sinus membrane, and fistula closure were included in the study. Written informed consent was obtained from all the patients included in this study. Postoperatively, healing was assessed by taking five clinical parameters of haemostasis, pain, granulation tissue, epithelialization, and contracture. Assessment criteria were followed as given in Table 1.

### Study design

The sample size of this evaluative study was 25 patients. Both male and female patients were included. Patients ranging in age between 20 and 60 years were included in the study. This study was confined to secondary defects of the oral mucosa, which occur after excision of premalignant lesions and other conditions, such as benign lesions, reactive proliferations,

and incisional biopsy wounds. Only those lesions that were sufficiently large and could not be closed primarily were included in the study. Patients with uncontrolled systemic disease, for example, American Society of Anesthesiologists III–IV patients, when primary closure is possible, in major resective surgery and with evidence of systemic or local infection were excluded from the study.

### Surgical procedure

In all cases, surgical procedure was done under local/general anaesthesia and lesion was excised. After surgical excision, haemostasis was attained. Collagen membrane was thoroughly washed in sterile saline solution. The membrane was trimmed according to the wound size. The collagen membrane was stabilized by the use of No. 3 silk sutures at the periphery of the defect. No pressure dressing was used. None of the patients required antibiotic coverage.

### Cases in study

#### *Collagen dressing in leukoplakia*

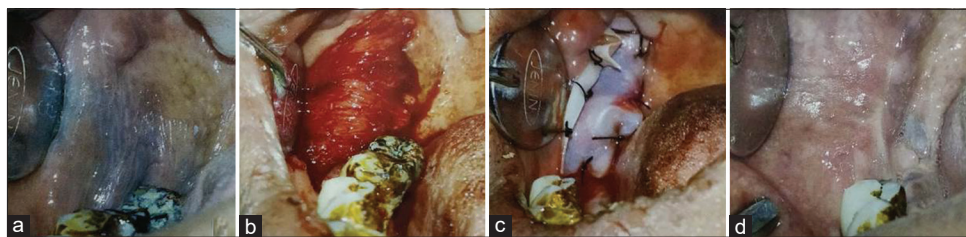
Collagen membrane was used after removal of leukoplakia as temporary grafting in this case. The defect was large and suturing was noted as possible and mucosal healing was achieved [Figure 1].

#### *Oral submucous fibrosis*

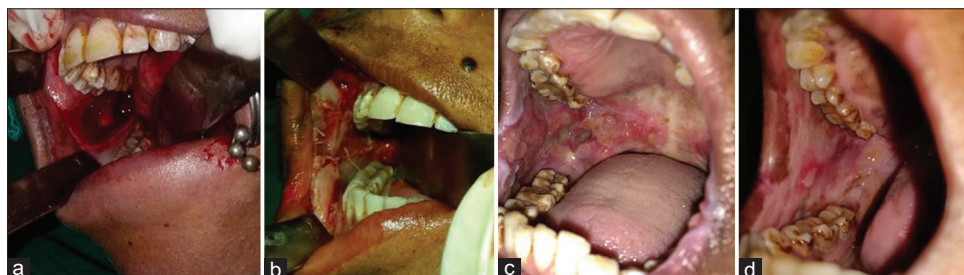
In this study, 10 OSMF patients were managed with bilateral fibrotomy with coronoidotomy and grafted with collagen membrane impregnated with dexona and placental extract. Good mucosal healing and postoperative mouth opening were achieved [Figure 2].

#### *Closure of palatal defect after removal of tumour*

Collagen membrane was used in palatal defect closure which occurred after excision of pleomorphic adenoma without any postoperative complications [Figure 3].



**Figure 1:** Use of collagen membrane in leukoplakia (a) Leukoplakia over right buccal mucosa (b) Excision of leukoplakia (c) Collagen membrane suture over defect (d) Healing after 1 month



**Figure 2:** (a) Defect after fibrectomy in oral submucous fibrosis (b) Collagen grafted over defect (c) Healing after 7 days (d) Healing after 1 month

***In perforation of sinus membrane followed by tumour removal***  
Collagen membrane was used in sinus membrane perforation followed by osteoma removal and healing was achieved without any postoperative complication [Figure 4].

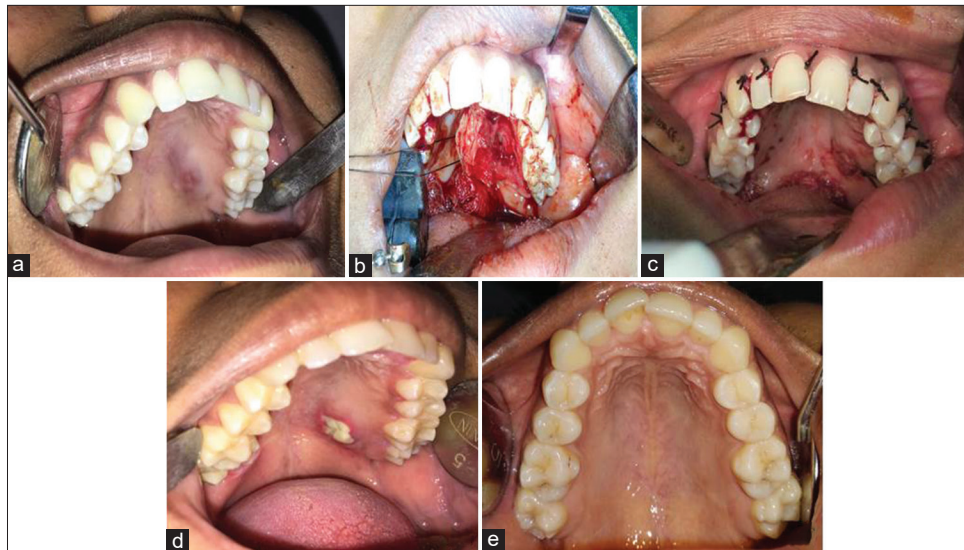
***In palatal (oronasal) fistula closure secondary to trauma***  
Collagen membrane was used in closure of palatal fistula secondary to trauma and good closure achieved without recurrence [Figure 5].

## RESULTS

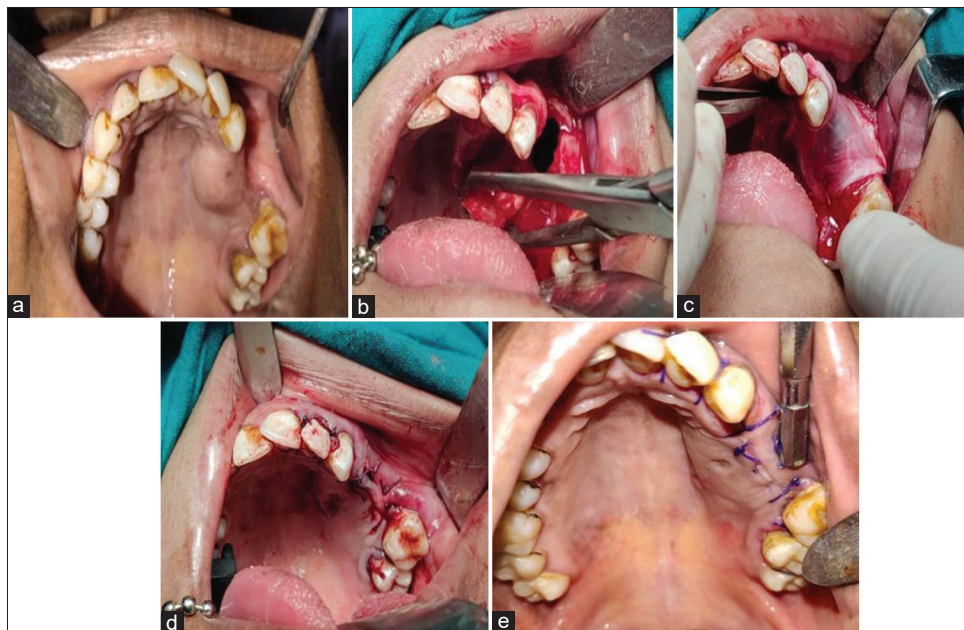
We selected 25 patients (both male and female) between the ages of 20 and 60 years for inclusion in the study. Of the

patients, 10 patients had leukoplakia, 10 patients had oral submucous fibrosis, two patients had benign tumour involving palatal mucosa, two patients had a perforation of the maxillary sinus membrane, and one patient had an oroantral fistula. All the patients were comfortable with intraoral grafting of collagen. None complained about the sensation of a foreign body or any odor. Allergy (systemic or local) to graft material was not seen in any of the cases.

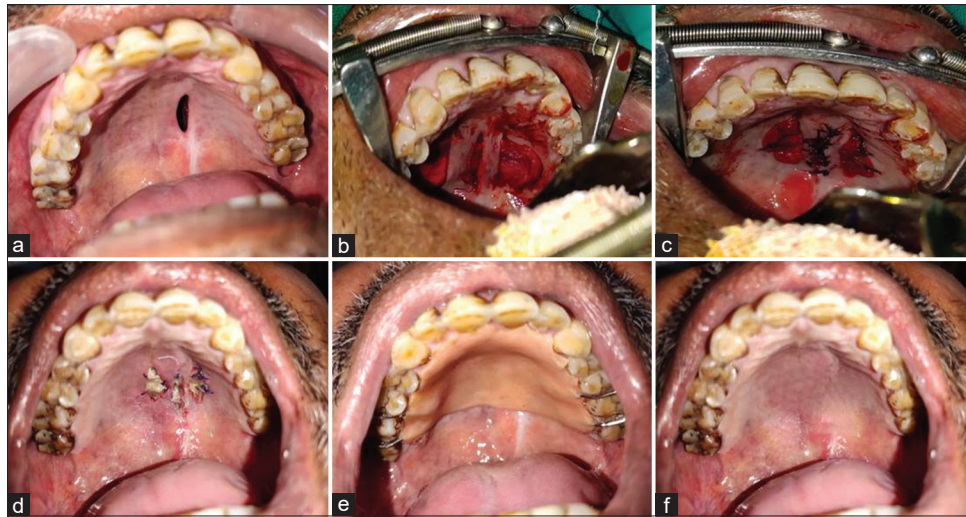
Haemostasis was good when used on the buccal mucosa of 23 (92%) patients and fair when used on the maxillary alveolus in 2 (8%) patients [Figure 6]. Pain relief was good in 15 (60%) cases, fair in 6 (24%) cases, and poor in only



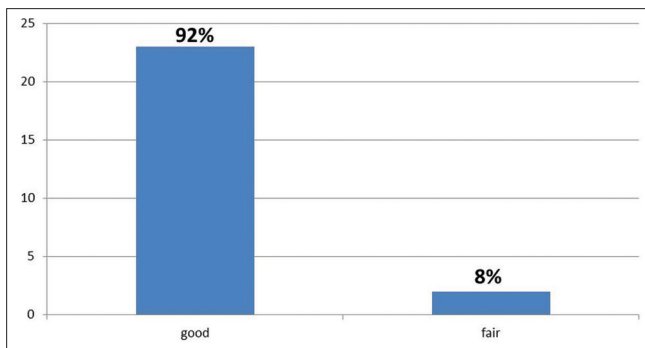
**Figure 3:** (a) Palatal tumour (b) Palatal mucosal defect after excision of tumour (c) Defect grafted with collagen and suturing (d) Healing 15 days (e) Healing after 1 month



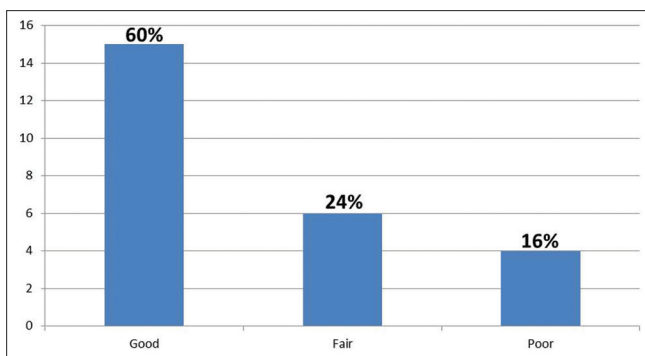
**Figure 4:** (a) Osteoma of left-side palatal area (b) Excision of osteoma and perforation of sinus encountered (c) Defect close with collagen membrane (d) Healing after 7 days (e) Healing after 15 days



**Figure 5:** (a) Palatal fistula (b) Collagen membrane interpositioned between flaps (c) Suturing of membrane and flap (d) Healing after 7 days (e) Acrylic palatal plate (f) Healing after 1 month



**Figure 6:** Observation of haemostasis



**Figure 7:** Evaluation of pain

4 (16%) cases [Figure 7] where the collagen membrane got sloughed off within the first 4 days after grafting. In these 4 (16%) cases, the membrane was used in dynamic areas of the oral cavity where it was subjected to constant movements and masticatory forces.

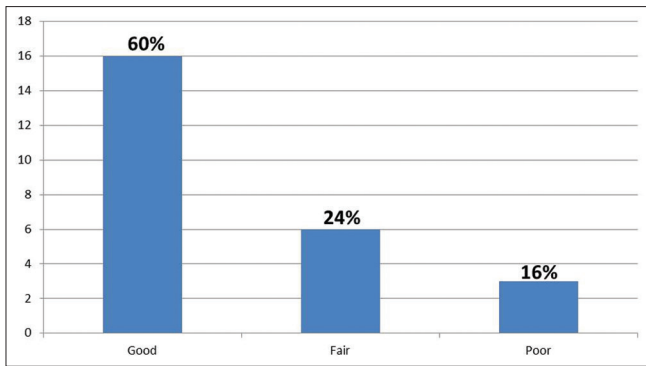
Granulation was good in 16 (64%) cases, fair in 6 (24%) cases, and poor in 3 (12%) cases [Figure 8]. Epithelialization was good in 17 (68%) cases, fair in 4 (16%), and poor in 4 (16%) cases [Figure 9]. Wound contracture was good in

**Table 1: Assessment criteria<sup>[24]</sup>**

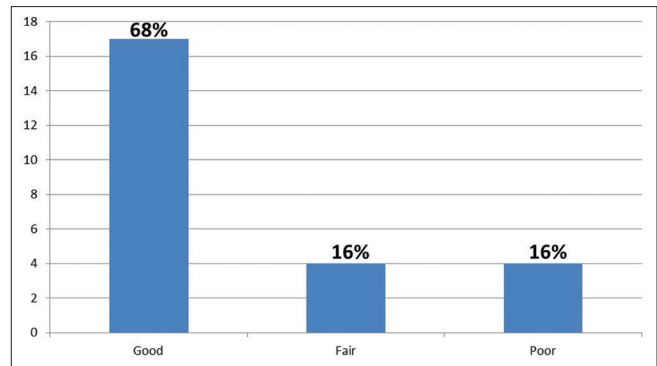
Haemostasis effect (intraoperative and postoperative)
2 - GOOD - no bleeding
1 - FAIR - slight bleeding; no haemostasis required
0 - POOR - bleeding requiring haemostasis
Pain being subjective, (4 <sup>th</sup> postoperative day), based on patients own words
2 - GOOD (none to mild)
1 - FAIR (moderate)
0 - POOR (severe)
Presence of granulation tissue noted at the end of 2 weeks as
2 - GOOD (entire wound)
1 - FAIR (nearly the entire wound)
0 - POOR (inadequate)
Epithelialization noted at the end of the month as
2 - GOOD (entire wound)
1 - FAIR (nearly the entire wound)
0 - POOR (inadequate)
Contracture of the wound at the end of the month was recorded (%)
2 - GOOD (<25)
1 - FAIR (25-50)
0 - POOR (severe i.e., >50)
Effectiveness
Very effective score of 8-10
Effective score of 5-7
Ineffective score of 0-4

19 (76%) cases, fair in 4 (16%), and poor contracture was noted in 2 (8%) cases [Figure 10]. The membrane was very effective in 6 (24%) patients, effective in 16 (64%), and ineffective in 3 (12%). The membrane was very useful in 19 (76%) patients and useful in 6 (24%) [Figure 11].

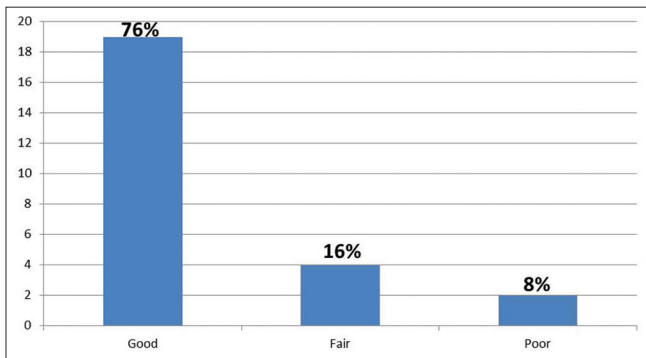
Efficacy of collagen membrane was tested by the use of Chi-square test and  $P < 0.001$ , which is a statistically and clinically significant value.



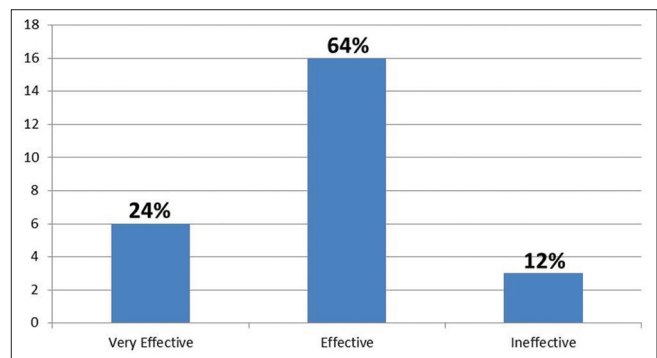
**Figure 8:** Evaluation of granulation tissue



**Figure 9:** Evaluation of epithelialization



**Figure 10:** Evaluation of wound contracture



**Figure 11:** Evaluation of effectiveness

## DISCUSSION

Raw wounds of the oral cavity, like any other wounds, heal by epithelialization and granulation. However, in the oral cavity, the healing of raw wounds presents some special problems. The environment is always moist with contamination from salivary secretion and food ingestion. This, compounded by poor oral hygiene and constant movements of the cheek and tongue and masticatory forces, may interfere with graft adherence and acceptance.<sup>[25]</sup>

Wounds that are left uncovered are prone to infection and scarring with attendant clinical problems. It has been well-documented that the incidence of infection and degree of contraction are considerably reduced when wounds are dressed with biologic materials rather than left exposed or dressed with nonbiologic materials during healing.<sup>[25,26]</sup>

The fact that grafted wounds heal faster with fewer complications than open wounds has been recognized in general surgery for almost a century.

Mucosal grafts may offer the solution because they come nearest to fulfilling the requirements of an ideal graft material. There is, however, a limited quantity of oral mucosa available for grafting, and thick mucosa taken from the cheek may result in scar formation, whereas a uniform thin graft removed with a microtome from the cheek is costly and complicated.<sup>[7,27]</sup> Skin graft is the next solution, but such graft used in the mouth will always retain the colouration of the skin and never attain the

texture or the resiliency of the oral mucosa, also seen is the growth of hair and sweat glands. Collagen can be used as an alternative to the skin and mucosal graft materials to cover the intraoral surgical defects.<sup>[7,27]</sup>

Clinically, collagen is well tolerated with no adverse effects. Pain, edema, and infection were negligible, and wounds healed uneventfully. The appearance of the areas of operation was seen to be restored to normal texture within about 1 month of grafting. There is also a morbidity associated with donor-site healing; this reflects the effectiveness of collagen membrane as a suitable graft material, whereas the usefulness of the collagen graft in this study refers to the material devoid of any allergic reaction despite being xenogenic with minimal morbidity to the patient.<sup>[7,27]</sup>

All collagen membranes, with time, slowly underwent collagenolysis and were eventually sloughed off. The weakening of collagen membranes, compounded by the oral environment and its movements, is the most probable reason why adhered collagen membranes sloughed off. This lysis of collagen was the result of an inflammatory reaction. Collagen lysis can be controlled by cross-linking, which also helps in reducing or suppressing antigenicity.<sup>[7]</sup>

In our study, collagen dressings showed an effective healing process. A similar result is seen in studies of Singh *et al.*, Thoma *et al.*, and Sharma V *et al.* This may be explained through the formation of a gelatinized coagulum containing an abundant amount of fibrinogen and fibronectin which contains

high concentrations of chemoattractants. Growth factors help in deposition and organization of freshly formed fibers. Granulation tissue facilitates the migration of fibroblasts into the wound bed.<sup>[28-30]</sup>

In our study, none of the cases showed adverse or allergic reactions to the collagen proving its safety as a grafting material for closing intraoral defects. This result is in accordance with the result of Reddy *et al.*'s study.<sup>[14]</sup>

As there is a large body of evidence that collagen is a common denominator in all stages of wound healing, it serves as the key extracellular component for repair and remodeling.<sup>[31]</sup>

Rastogi *et al.* did a prospective study of 60 patients where he used collagen membrane in surgical defects and found it to be a very suitable alternative to other graft materials for the repair of defects in the mucous membrane of the oral cavity. Therefore, when used judiciously in a controlled clinical situation, collagen membrane is biologically acceptable to the oral mucosa and is, from the clinical point of view, an excellent wound graft material.<sup>[7]</sup>

Herford AS used collagen membrane in 30 consecutive patients with surgical defects and its results concluded that collagen matrix provides a biocompatible surgical material as an alternative to an autogenous transplant, thus obviating the need to harvest soft-tissue autogenous grafts from other areas of the oral cavity.<sup>[33]</sup>

Vastani *et al.* reviewed that collagen is one such biomaterial that can be safely and effectively used for coverage of oral defects following surgery of oral cancer and precancer owing to a number of benefit.<sup>[6]</sup>

Unique features of collagen membranes include:

- Collagen membrane has an inherent property of haemostatic effect as it is a specific activator of platelets and helps in their adhesion to collagen fiber, aggregation<sup>[32]</sup>
- It has a guiding characteristic with stabilize the coagulum and enhances the early epithelial proliferation from the surrounding tissues<sup>[14,33]</sup>
- It is chemotactic to various cell types such as endothelial cells, fibroblasts and leads to reduced inflammatory process which reduces pain and burning sensation<sup>[12,14,31]</sup>
- Collagen acts as a temporary coverage for sensitive nerve endings, thereby diminishing the degree of pain<sup>[12,14,31]</sup>
- Collagen dressings encourage wound healing through early deposition and organization of granulation tissue and hastened the healing process<sup>[12]</sup>
- Can resist masticatory forces for sufficient time
- Easily obtainable and does not require a second operation and its associated morbidity.

Advantages of collagen membrane:<sup>[13,32,34]</sup>

- Biocompatible
- Nonimmunogenic
- Easy availability
- Convenience of application

- Good tolerance of oral tissue
- No adverse effects
- No second surgery required
- No morbidity associated with the use of grafts
- No problems associated with donor site healing.

### Limitations of this study

Limitations in this study are that in four cases of our study (one on palate, second one in retromolar area), there was loss of collagen membrane because of continuous movements of the tongue and membrane in the line of occlusion. Stabilization of the membrane to the surgical defect in this present study was done by suturing the membrane to the edges of the defect, which was a time consuming and delicate procedure. It should be done without damaging the membrane. It can be recommended that the use of biological glue such as cyanoacrylates for this purpose can be tried in a future study.

### CONCLUSION

Oral and maxillofacial surgeons treat various pathologies in and around the oral cavity. Collagen is one such biomaterial that can be safely and effectively used for coverage of oral defects following surgery. Its application in the oral cavity is easy because of the simple chairside application and good tolerance of the membrane by oral tissues; it can therefore be advocated as a temporary biologic dressing material in the oral cavity devoid of mucous membrane. It is an alternative to autologous grafts rather than a replacement of other grafts used in the oral cavity.

### Financial support and sponsorship

Nil.

### Conflicts of interest

There are no conflicts of interest.

### REFERENCES

1. Bagheri SC, Bell RB, Khan HA. Current Therapy in Oral and Maxillofacial Surgery. Philadelphia: Elsevier Saunders; 2011.
2. Mokal NJ, Raje RS, Ranade SV, Prasad JS, Thatte RL. Release of oral submucous fibrosis and reconstruction using superficial temporal fascia flap and split skin graft – A new technique. *Br J Plast Surg* 2005;58:1055-60.
3. Lai DR, Chen HR, Lin LM, Huang YL, Tsai CC. Clinical evaluation of different treatment methods for oral submucous fibrosis. A 10-year experience with 150 cases. *J Oral Pathol Med* 1995;24:402-6.
4. Mariappan N. Collagen dressing for thermal burns. *Sch J Appl Med Sci* 2015;3:58.
5. Shankar N, Eligar R, Ramesh H, Hebsur NI. A comparative study of collagen granule dressing versus conventional dressing in deep wounds. *IOSR J Dent Med Sci* 2017;14:23-8.
6. Vastani A, Chourasia N, Pahlajani V, Choubey S. Collagen membrane for reconstruction of soft tissue defects after surgery of oral cancer and precancer: A brief review. *Plast Aesthet Res* 2016;3:100-5.
7. Rastogi S, Modi M, Sathian B. The efficacy of collagen membrane as a biodegradable wound dressing material for surgical defects of oral mucosa: A prospective study. *J Oral Maxillofac Surg* 2009;67:1600-6.
8. Kamath VV. Surgical interventions in oral submucous fibrosis: A systematic analysis of the literature. *J Maxillofac Oral Surg* 2015;14:521-31.
9. Edelmayr M, Wehner C, Ulm C, Zechner W, Shafer D, Agis H, *et al.* Which substances loaded onto collagen scaffolds influence oral tissue

- regeneration? – An overview of the last 15 years. *Clin Oral Investig* 2020;24:3363-94.
10. Jasthi VC, Shamim T. Data regarding clinical evaluation of collagen membrane in oral mucosal defects due to oral submucous fibrosis and leukoplakia. *Data Brief* 2018;18:607-12.
  11. Pradhan H, Gupta H, Sinha V, Gupta S, Shashikanth M. Two wound-covering materials in the surgical treatment of oral submucous fibrosis: A clinical comparison. *J Oral Biol Craniofac Res* 2012;2:10-4.
  12. Nataraj S, Guruprasad Y, Shetty JN. A comparative clinical evaluation of buccal fat pad and collagen in surgical management of oral submucous fibrosis. *Arch Dent Sci* 2011;2:17-24.
  13. Chauhan A. Role of collagen membrane for reconstruction of buccal defects following fibrotic band excision and coronoidectomy in oral submucous fibrosis. *IOSR J Dent Med Sci* 2017;16.7:74-8.
  14. Reddy YR, Srinath N, Nandakumar H, Kanth MR. Role of collagen impregnated with dexamethasone and placetrin in patients with oral submucous fibrosis. *J Maxillofac Oral Surg* 2012;11:166-70.
  15. Pandey A, Sharma NK, Dhiman NK, Jaiswara C, Tiwari P, Singh AK, *et al.* Comparative evaluation of buccal pad of fat with and without bovine collagen membrane in the management of oral submucous fibrosis: A prospective clinical study. *Natl J Maxillofac Surg* 2020;11:57-63.
  16. Alkan A, Inal S. Closure of palatal defects following excision of palatal pleomorphic adenomas. *J Contemp Dent Pract* 2008;9:99-107.
  17. Patigaroo SA, Patigaroo FA, Ashraf J, Mehfooz N, Shakeel M, Khan NA, *et al.* Pleomorphic adenoma of hard palate: An experience. *J Maxillofac Oral Surg* 2014;13:36-41.
  18. Lee CY. An alternative strategy to manage a large perforation of the schneiderian membrane by staged re-entry into the maxillary sinus: Observed clinical and histological changes of the regenerated schneiderian membrane. *Int J Oral Dent Health* 2017;3:043.
  19. Yu SJ, Na IC, Jang HW, Jung MJ, Kim BO. The increase of keratinized and attached gingiva using collagen wound dressing in dogs: A clinical and histomorphometric comparative study. *Oral Biology Research* 2015;39:10-7.
  20. Lee JY, Kwon JJ, Sándor G, Kim YD. Effectiveness of collagen membrane in the treatment of schneiderian membrane perforation. *Appl Sci* 2019;9:1514.
  21. Reddy GS, Reddy GV, Sree PK, Reddy KS, Reddy PA. Membrane assisted palatal fistula closure in a cleft palate patient: A novel technique. *J Clin Diagn Res* 2016;10:22-6.
  22. Ha JH, Jeong Y, Koo YT, Jeon S, Chung J, Kim S. Effect of collagen matrix on postoperative palatal fistula in cleft palate repair. *Sci Rep* 2020;10:15236.
  23. Hudson JW, Pickett DO. A 5-year retrospective review of primary palatoplasty cases utilizing an Acellular Collagen Interpositional graft. *J Oral Maxillofac Surg* 2015;73:1393.e1-3.
  24. Bessho K, Muramaki K, Iizuka T. The use of a new bilayer artificial dermis for vestibular extension. *Br J Oral Maxillofac Surg* 1998;36:457-9.
  25. Doillon EJ. Porous collagen sponge wound dressing; *in vivo* and *in vitro* studies. *J Biomaterial Appl* 1988;2:562.
  26. Chung KM, Salkin LM, Stein MD, Freedman AL. Clinical evaluation of a biodegradable collagen membrane in guided tissue regeneration. *J Periodontol* 1990;61:732-6.
  27. Ueda M, Kaneda T, Oka T. Experimental study of dermal grafts for reconstruction of oral mucosa. *J Oral Maxillofac Surg* 1984;42:213.
  28. Singh O, Gupta SS, Soni M, Moses S, Shukla S, Mathur RK. Collagen dressing versus conventional dressings in burn and chronic wounds: A retrospective study. *J Cutan Aesthet Surg* 2011;4:12-6.
  29. Thoma DS, Sancho-Puchades M, Ettl DA, Hämmerle CH, Jung RE. Impact of collagen matrix on early healing, aesthetics and patient morbidity in oral mucosal wounds. *J Clin Periodontol* 2012;39:157-65.
  30. Sharma V, Kumar A, Puri K, Bansal M, Khatri M. Application of platelet-rich fibrin membrane and collagen dressing as palatal bandage for wound healing: A randomized clinical control trial. *Indian J Dent Res* 2019;30:881-8.
  31. Kshirsagar AY, Pandey Y, Baur S, Deka H, Verma A, Kesarwani A, *et al.* Efficacy of type 1 bovine collagen particles in the topical management of diabetic foot ulcer. *J. Evolution Med. Dent. Sci.* 2016;5:4769-73. DOI: 10.14260/jemds/2016/1087.
  32. Sowjanya NP, Rao N, Bhushan NV, Krishnan G. Versatility of the use of collagen membrane in oral cavity. *J Clin Diagn Res* 2016; 10:ZC30-3.
  33. Herford AS, Akin L, Cicciu M, Maiorana C, Boyne PJ. Use of a porcine collagen matrix as an alternative to autogenous tissue for grafting oral soft tissue defects. *J Oral Maxillofac Surg* 2010;68:1463-70.
  34. Mohd. Kamran Farooqui. Role of Collagen membrane in the treatment of advanced stage of Oral submucous fibrosis: A case report Saudi J. Oral Dent Res 2017;2:155-9.