

Arthroscopic Diagnosis and Treatment of Chronic Hip Pain After Total Hip Arthroplasty and the Role of Anterior Capsule Disruption in Iliopsoas Tendinopathy

Mark R. Nazal,* MPH, Ali Parsa,*^{†‡} MD, and Scott D. Martin,* MD

Investigation performed at Massachusetts General Hospital, Boston, Massachusetts, USA

Background: The use of hip arthroscopic surgery in patients suffering from chronic hip pain after total hip arthroplasty (THA) has a limited presence in the literature, with most studies having limited follow-up.

Purpose: The first goal of this study was to evaluate hip arthroscopic surgery in the diagnosis and management of patients with chronic hip pain after THA. The second goal was to describe a new cause of iliopsoas tendinopathy (IPT) involving disruption of the anterior capsule.

Study Design: Case series; Level of evidence, 4.

Methods: We conducted a retrospective analysis with prospectively collected clinical outcomes of patients after THA who underwent hip arthroscopic surgery for chronic hip pain without an identifiable cause. The patients were at least 18 years old and had a minimum follow-up of 24 months.

Results: The retrospective analysis found that hip arthroscopic surgery led to new diagnostic information in 8 patients (80%). Of the 10 patients diagnosed with IPT, 4 (40%) lacked an anatomic cause; however, these patients had a history of difficult exposure of the anterior capsule and/or a lack of capsular repair during index THA. The mean modified Harris Hip Score (mHHS) was 71.9 ± 15.6 , and the mean 6-month postoperative visual analog scale (VAS) pain score was 0.8 ± 2.2 , which was significantly lower than preoperatively ($P = .0055$). There was also significantly improved forward flexion range of motion ($P = .0183$) and straight leg raise (SLR) strength test results ($P = .0263$). Hip arthroscopic surgery resulted in 8 patients (80%) continuing to be pain-free at a mean follow-up of 6.8 ± 1.4 years, while 2 patients (20%) progressed to revision arthroplasty. There were no major or minor complications.

Conclusion: Hip arthroscopic surgery was found to have an important role in the diagnostic and therapeutic management of patients with chronic hip pain after THA, with good clinical outcomes at a mean follow-up of 6.8 years and no complications. We believe that disruption of the anterosuperior acetabular capsule, including the reflected head of the rectus femoris, can allow the iliopsoas tendon to move intra-articularly and precipitate IPT. This disruption may be appreciated on the SLR strength test. Although this study presents a small sample size that cannot substantiate a cause-effect relationship, orthopaedic surgeons performing THA should consider minimizing disruption and/or ensuring repair of the anterior capsule to decrease this potential cause of IPT.

Keywords: anterior capsule; chronic pain; hip; iliopsoas tendinopathy; total hip arthroplasty

Total hip arthroplasty (THA) offers patients the opportunity to improve pain, functionality, and mobility, which may significantly improve quality of life.²⁷ Unfortunately, the postoperative expectations of some patients are not met, with a subset of patients experiencing hip pain after surgery. It is estimated that 5.3% to 12.5% of patients develop a chronically painful hip after THA.^{5,20}

In this subset of patients, an in-depth evaluation is needed to assess the cause of the pain. Chronic hip pain has a broad differential diagnosis that includes both intrinsic and extrinsic causes. The initial diagnostic approach is focused on evaluating the most common causes of hip pain after THA: periprosthetic joint infection (PJI), aseptic loosening, or periprosthetic fracture (Figure 1). If the initial assessment fails to confirm the diagnosis or if a physical examination finding is compatible with impingement of the iliopsoas, many authors recommend that iliopsoas tendinopathy (IPT; also known as iliopsoas impingement) be considered.^{3,8,14,25} If the cause of the

The Orthopaedic Journal of Sports Medicine, 7(6), 2325967119854362
DOI: 10.1177/2325967119854362
© The Author(s) 2019

This open-access article is published and distributed under the Creative Commons Attribution - NonCommercial - No Derivatives License (<http://creativecommons.org/licenses/by-nc-nd/4.0/>), which permits the noncommercial use, distribution, and reproduction of the article in any medium, provided the original author and source are credited. You may not alter, transform, or build upon this article without the permission of the Author(s). For article reuse guidelines, please visit SAGE's website at <http://www.sagepub.com/journals-permissions>.

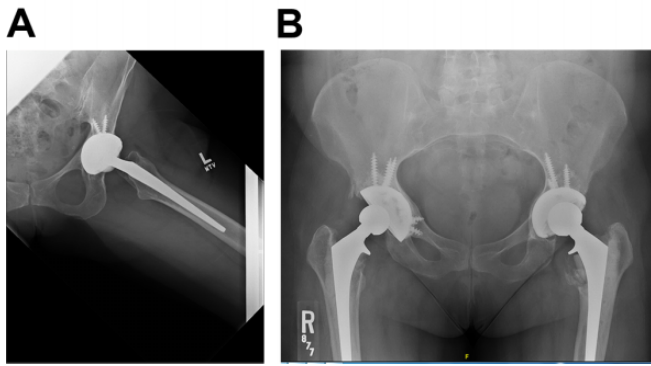


Figure 1. (A) In assessing the preoperative anteroposterior pelvic radiograph in patients after total hip arthroplasty, it is important to evaluate cup position, medial wall integrity, and new bone formation, particularly in relation to the anterior rim of the acetabulum. (B) Preoperative lateral pelvic radiograph showing anterior undercoverage of the prosthetic cup.

painful hip is provisionally determined to be IPT or if the cause is still unclear, the patient typically undergoes a trial of conservative treatment, consisting of short-term rest, nonsteroidal anti-inflammatory drugs, physical therapy, and analgesic injections into the iliopsoas tendon sheath.

If conservative treatment fails, operative management may be pursued. Arthroscopic management may lead to the resolution of hip pain while avoiding the morbidity and higher complications of an open hip procedure. Furthermore, an arthroscopic examination can serve as a final diagnostic step, providing more direction on whether open surgery is warranted.^{1,3,8} In particular, with regard to the management of IPT, a 2018 systematic review showed significantly higher efficacy for arthroscopic iliopsoas tenotomy versus open tenotomy in patients after THA, with a 92% and 78% success rate, respectively.¹⁸

Heaven et al¹⁰ performed a systematic review on hip arthroscopic surgery after THA that showed a limited amount of literature on the topic, with only 18 articles written between 1980 and 2013. Furthermore, those studies (1) had predominantly small sample sizes (6 of the 18 articles were single case reports); (2) focused on a single cause of hip pain, such as prosthesis infections; (3) consisted of cohorts not restricted to THA (index procedures included resurfacing, hemiarthroplasty, or arthroplasty procedures); or (4) had limited follow-up. There was only 1 study that achieved a mean follow-up of longer than 24 months.¹²

Therefore, the first goal of this study was to build on the limited body of literature by providing a further evaluation of hip arthroscopic surgery in the diagnosis and treatment

of patients with chronic hip pain after THA, while also being the first study to attain midterm follow-up. The second goal was to describe a new cause for IPT that has not been previously reported: Disruption of the anterosuperior acetabular capsule, including the reflected head of the rectus femoris, may allow the iliopsoas tendon to move intra-articularly and precipitate IPT.

METHODS

This study utilized a retrospective database with prospectively collected clinical outcomes to evaluate the midterm results of the arthroscopic diagnosis and treatment of patients with chronic hip pain after THA. After obtaining institutional review board approval, all patients who underwent hip arthroscopic surgery between June 2007 and June 2013 by a single surgeon (the senior author; S.D.M.) were identified. A subset of patients diagnosed with chronic hip pain after THA were subsequently identified. Inclusion criteria were the following: age at least 18 years, reported hip pain lasting longer than 3 months after THA without an identifiable cause, failure of the painful hip to respond to conservative management, hip arthroscopic surgery performed on the painful hip by the senior author, and minimum follow-up of 24 months. Patients were excluded if they were younger than 18 years; had an identifiable cause of hip pain, such as a PJI; or had less than 24 months of follow-up.

Patient Selection

A retrospective analysis of clinic notes was conducted to confirm a presenting chief complaint of chronic hip pain and a surgical history of THA of the painful hip. Among the 541 records of hip arthroscopic surgery performed by the senior author between June 2007 and June 2013, we identified 10 hips in 10 unique patients; none were excluded, as all patients met the aforementioned inclusion and exclusion criteria.

All patients were assessed by the senior author, with patients typically presenting with hip pain located anteriorly, particularly when the hip was flexed and externally rotated. In addition, patients often reported a snapping or clicking sensation when flexing and extending the hip. On examination, tenderness to palpation was elicited on the femoral triangle and less commonly on the lesser trochanter. The snapping hip extension test was performed with the patient supine, beginning with the hip flexed, abducted, and externally rotated and moving the leg into hip extension while observing for a snap or click in the anterior hip.

[†]Address correspondence to Ali Parsa, MD, Sports Medicine Center, Department of Orthopaedic Surgery, Massachusetts General Hospital, 175 Cambridge Street, Suite 400, Boston, MA 02118, USA (email: aliparsadr@yahoo.com).

^{*}Sports Medicine Center, Department of Orthopaedic Surgery, Massachusetts General Hospital, Boston, Massachusetts, USA.

[‡]Orthopedic Research Center, Mashhad University of Medical Sciences, Mashhad, Iran.

One or more of the authors has declared the following potential conflict of interest or source of funding: This study was supported by the Conine Family Fund for Joint Preservation. S.D.M. has received hospitality payments from Smith & Nephew and Kairos Surgical, has received educational support from Kairos Surgical, and has received research funding from Smith & Nephew. AOSSM checks author disclosures against the Open Payments Database (OPD). AOSSM has not conducted an independent investigation on the OPD and disclaims any liability or responsibility relating thereto.

Ethical approval for this study was obtained from Partners HealthCare (Protocol 2011P000053).

Provocation testing of resisted hip flexion, including the seated hip flexion test and straight leg raise (SLR) strength test, led to anterior hip pain.

All patients underwent standard hip radiography and hip magnetic resonance imaging (MRI) to identify potential causes of the chronic hip pain. If version of the acetabular cup warranted further investigation, a computed tomography scan of the hip was obtained. All patients were treated with conservative therapy, consisting of nonsteroidal anti-inflammatory drugs and analgesic injections into the iliopsoas tendon sheath, followed by 1 month's rest and then a 2-month trial of physical therapy. A positive response of pain relief to the iliopsoas tendon sheath injection supported the diagnosis of IPT.

For each patient, the following information was obtained: demographic characteristics (age, sex, laterality, body mass index), descriptive data of the index arthroplasty procedure (surgical approach, type of procedure, component specifications, exposure of anterior capsule, capsular repair), time from THA to hip arthroscopic surgery, symptomatic duration of hip pain before surgery, preoperative diagnostic information, intraoperative findings and procedures, postoperative diagnostic information, and postoperative visit data. Retrospective clinical outcome data were analyzed for the visual analog scale (VAS) pain score, SLR strength test finding, range of motion (ROM), complications, and progression to revision surgery. Prospective clinical outcome data were collected using the modified Harris Hip Score (mHHS).

Iliopsoas Tendon Sheath Injection

To rule out iliopsoas bursitis, all patients received an iliopsoas tendon sheath injection as part of their conservative treatment. Fluoroscopy guidance was used as opposed to ultrasound guidance because ultrasound is highly technician dependent and postoperative changes distort the native anatomy, making ultrasonography more complex and difficult to interpret. The patient was placed in the supine position on the fluoroscopy table. First, a suitable site for needle insertion into the iliopsoas tendon sheath was identified with the help of fluoroscopic identification of the lateral femoral head. The hip was prepared and draped in the usual sterile fashion. Approximately 5 mL of 1% lidocaine was used for local anesthesia of the skin, subcutaneous tissue, and deep soft tissue. Under fluoroscopic guidance, a 22-gauge, 5.0-inch spinal needle was directed toward the acetabulum overlaying the center of the femoral head. Next, 2 mL of iopromide (Ultravist; Bayer) was injected, with confirmation of proper placement based on visualization of the outline of the iliopsoas bursa¹⁵ (Figure 2). Then, 1 mL (40 mg) of Depo-Medrol (Pfizer) and 5 mL of 0.25% bupivacaine were injected.

Hip Arthroscopic Procedure

The patient was placed in the standard supine position on the hip arthroscopic table against a well-padded perineal post. Both feet were placed in protective foam boots and

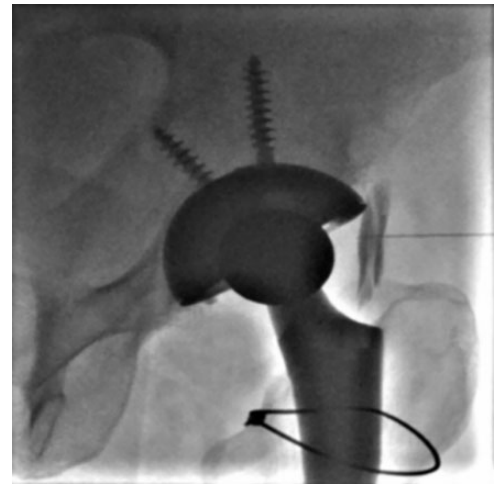


Figure 2. Left iliopsoas bursa injection under fluoroscopy guidance. Proper placement of the iopromide (Ultravist; Bayer) injection was confirmed based on visualization of the bursa outline.

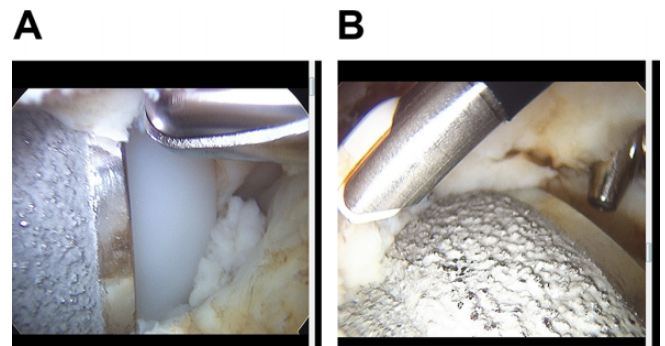


Figure 3. (A) Intraoperative evaluation of the relationship between the femoral head, polyethylene liner, and metallic cup. (B) Intraoperative soft tissue release around the cup. Note the large undercovered prosthetic cup.

secured in a supine hip distractor apparatus (Smith & Nephew); with the operative leg in neutral rotation, the joint was placed under tension to hold positioning against the post without utilizing any traction. Fluoroscopy was used to verify adequate traction of the hip by evaluating the amount of joint space distraction, in conjunction with anatomic landmarks. The arthroscope was inserted through the anterolateral portal, while the anterior portal primarily served as a utility portal.

A puncture capsulotomy technique was utilized instead of the commonly performed T-capsulotomy or interportal capsulotomy.⁶ As expected, there was typically significant scar tissue surrounding the hip. The scar tissue was debrided using a 5.5-mm shaver along with a vaporizer (DePuy Synthes). The integrity of the acetabular shell and polyethylene rim was assessed, and any gap between the polyethylene liner and cup was evaluated. Then, the position of the cup was assessed both anteriorly and laterally to identify any

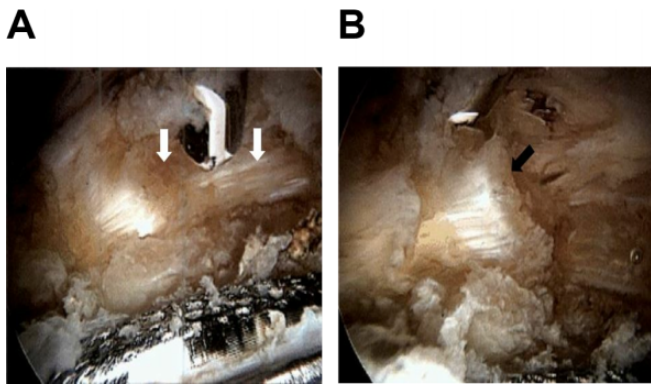


Figure 4. (A) Intraoperative visualization of the iliopsoas tendon (white arrow), which is inflamed and thickened. (B) Recession of the iliopsoas tendon to alleviate impingement (black arrow).

prominent portion or malpositioning (Figure 3). Finally, the head-neck junction typically required some debridement.

The iliopsoas tendon was isolated and assessed for inflammation or tendinosis. When indicated, iliopsoas recession was performed to attenuate the tendon; however, full-thickness tenotomy was not utilized in any of the patients (Figure 4). Complete peripheral and central compartment arthroscopic surgery was performed to debride fibrotic tissue. Several samples, including synovial fluid and soft tissue biopsies, were taken to evaluate for a PJI. The procedure concluded with a thorough evaluation of the cup, liner, and femoral head during hip ROM testing.

Statistical Analysis

Statistical analysis was performed using R statistical software version 3.5.2 (R Foundation for Statistical Computing). Categorical variables are represented as the number and percentage; ordinal variables are represented as the median and range; and continuous variables are represented as the mean, standard deviation, and range. The Wilcoxon signed-rank test was used to evaluate the statistical significance of matched preoperative and postoperative VAS pain and SLR strength test results. To evaluate mean differences in ROM results, a paired *t* test was utilized. *P* values <.05 were considered statistically significant.

RESULTS

Of the 10 patients in the study cohort, 7 were female and 3 were male (Table 1). Five of the cases were performed on the right hip, and 5 were performed on the left hip. The mean age at the time of hip arthroscopic surgery was 60.4 ± 8.4 years (range, 51-80 years). Eight patients (80%) had a body mass index over 25 kg/m^2 at the time of surgery. The mean duration of chronic hip pain before presenting to our institution was 12.9 ± 8.3 months (range, 4-30 months).

Operative notes of the index THA procedures were reviewed of which 2 were not available. Nine patients (90%) had undergone primary, cementless arthroplasty, with 1 patient (10%) having undergone revision, cemented arthroplasty (Table 1). All 10 THA procedures were performed using a posterior approach. Three patients' (30%) operative notes stated that obtaining exposure of the anterior capsule was difficult or required more than normal effort, and 5 patients (50%) underwent anatomic capsular repair. The mean time between index THA and hip arthroscopic surgery was 36.3 ± 25.6 months (range, 5-90 months).

Based on the preoperative evaluation, the most common provisional diagnosis was suspected IPT, which was found in all 10 patients, followed by cup prominence in 3 patients (30%) (Figure 5). The most common postoperative arthroscopic findings were IPT ($n = 10$), capsular fibrosis ($n = 10$), and loose bodies ($n = 6$) (Table 2). In most patients, capsular fibrosis was difficult to isolate to the iliopsoas, iliocapsularis, or reflected head of the rectus femoris. The mean operative time was 76.4 ± 25.8 minutes (range, 30-110 minutes). Intermittent traction was used during all 10 surgical procedures, with a mean cumulative traction time of 44.9 ± 20.6 minutes (range, 15-69 minutes). Beyond IPT or capsular fibrosis, arthroscopic surgery provided new diagnostic information in 8 patients (80%), including loose bodies, cup prominence, cement piece, and pincer lesion (Table 2). There were no cases of metallosis or subluxation/dislocation. The most common arthroscopic procedure performed was capsular release in which a limited amount of scar tissue around the region of iliopsoas impingement was released, performed in all 10 patients, along with proximal iliopsoas recession in all 10 patients and loose body removal in 6 patients (Table 3).

The mean follow-up period was 6.8 ± 1.4 years (range, 47-110 months). Prospectively collected mHHS values were available for all 10 patients (Table 4). The mean mHHS was 71.9 ± 15.6 (range, 45-91). There was a statistically significant improvement on the postoperative SLR strength test, with 6 patients (60%) improving compared with the preoperative strength test ($P = .0263$) (Table 4). Furthermore, there was a significant improvement in forward flexion, from a preoperative mean of $91.5^\circ \pm 11.8^\circ$ to a postoperative mean of $99.0^\circ \pm 6.6^\circ$ ($P = .0183$). There were improvements in internal rotation from a preoperative mean of $5.0^\circ \pm 3.3^\circ$ to a postoperative mean of $8.5^\circ \pm 3.4^\circ$ ($P = .0886$) and in external rotation from a preoperative mean of $38.5^\circ \pm 7.8^\circ$ to a postoperative mean of $42.0^\circ \pm 5.4^\circ$ ($P = .1108$), but neither was significant.

The mean preoperative VAS pain score was 8.5 ± 1.7 (range, 5-10), compared with the mean 6-month postoperative VAS pain score of 0.8 ± 2.2 (range, 0-7), which was statistically significant ($P = .0055$). At final follow-up, 8 patients (80%) had a VAS pain score of 0 with maintained prosthesis integrity, without signs of loosening or significant osteolysis, and did not require further interventions.

Two patients (20%) underwent revision surgery because of persistent hip pain. One patient underwent acetabular cup revision 37 months after hip arthroscopic surgery. The indication was suspected loosening of the acetabular

TABLE 1
Patient Demographics and Index THA Characteristics^a

Patient	Age, y	Sex	Laterality	BMI, kg/m ²	Time After THA, mo	Type of THA	Approach of THA	Difficult Exposure of Anterior Capsule	Anatomic Capsular Repair	Symptom Duration, mo
1	56.1	Female	Left	19	24	Primary, cementless	Posterior	No	Yes	8
2	51.4	Female	Left	33	90	Revision, cemented	Posterior	Yes	No	12
3	63.1	Male	Left	28	38	Primary, cementless	Posterior	Yes	Yes	24
4	54.7	Male	Left	32	20	Primary, cementless	Posterior	Yes	Yes	15
5	80.4	Male	Right	29	67	Primary, cementless	Posterior	No	Yes	6
6	54.1	Female	Left	39	44	Primary, cementless	Posterior	No	No	12
7	61.8	Female	Right	34	15	Primary, cementless	Posterior	No	No	6
8	55.3	Female	Right	33	5	Primary, cementless	Posterior	No	Yes	12
9	61.2	Female	Right	26	36	Primary, cementless	Posterior	No	No	30
10	65.6	Female	Right	24	24	Primary, cementless	Posterior	No	No	4
Overall ^b	60.4 ± 8.4 (51.4-80.4)	Male: 30%; female: 70%	Left: 50%; right: 50%	29.7 ± 5.7 (19.0-39.0)	36.3 ± 25.6 (5.0-90.0)					12.9 ± 8.3 (4.0-30.0)

^aBMI, body mass index; THA, total hip arthroplasty.

^bData reported as mean ± SD (range) unless otherwise indicated.

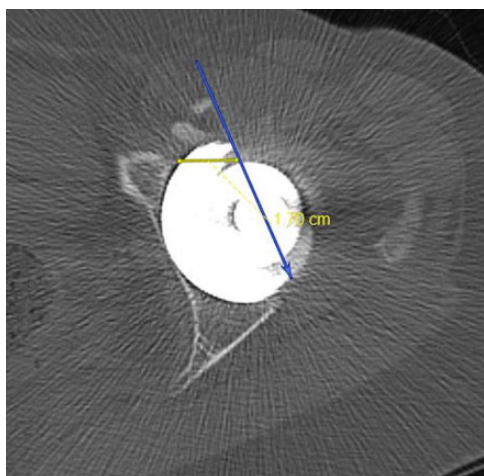


Figure 5. Axial pelvic computed tomography scan showing acetabular cup prominence with a large, overhanging edge. Note the new bone formation near the anterior rim of the acetabulum, in proximity to the iliopsoas.

component based on increased uptake on a technetium-99m bone scan. At 14-month follow-up after revision, the patient reported significant improvement with only mild residual discomfort with prolonged activity. The other patient underwent complete revision 11 months after hip arthroscopic surgery. The indication for revision was taper corrosion due to elevated serum cobalt levels and MRI with metal suppression sequencing showing the progression of periarticular soft tissue thickening that extended laterally to the greater trochanter. At 38-month follow-up after revision, the patient continued to exhibit severe pain and was being evaluated by neurology for automatic dysfunction, regional pain syndrome, or small fiber neuropathy.

Finally, there were no major perioperative complications, including septic arthritis, hip dislocations, extra-articular fluid extravasation, fractures, or thromboembolism.²⁴ There

were also no minor complications, including neurapraxia, broken instrumentation, superficial wound infections, or heterotopic ossification.

DISCUSSION

We analyzed a cohort of 10 patients who underwent hip arthroscopic surgery for chronic hip pain after THA. The cohort had a mean follow-up of 6.8 years, which to our knowledge makes this study the first report with mid-term follow-up in this subset of patients. The first goal of this study was to evaluate the diagnostic and therapeutic management of patients with chronic hip pain after THA. Hip arthroscopic surgery led to new diagnostic information in 8 patients (80%) and therapeutically led to 8 patients (80%) achieving sustained relief of hip pain with a VAS pain score of 0, with 2 patients (20%) converting to revision arthroplasty. Finally, there were no major or minor perioperative complications.

Hip arthroscopic surgery confirmed the provisional preoperative diagnosis of IPT in all 10 patients. In addition, an arthroscopic examination confirmed or found capsular fibrosis, a common surgical change after THA, in all 10 patients. This finding is comparable with that of McCarthy et al,¹⁷ who reported anterior scar tissue in 9 (64%) of 14 patients with chronic hip pain after hip arthroplasty. Beyond those 2 diagnoses, arthroscopic surgery provided new diagnostic information in 8 patients (80%) with chronic hip pain, demonstrating that it is an excellent diagnostic tool in the assessment of potential causes of chronic hip pain in this complex subset of patients. When considering that MRI has limited diagnostic utility because of imaging artifacts created by the prosthetic hardware, the importance of hip arthroscopic surgery for a definitive diagnosis is further magnified in the workup of hip pain after THA.²¹

Furthermore, 5 patients (50%) were diagnosed with cup prominence postoperatively. In 2 of these patients, preoperative imaging, including computed tomography scans, failed to diagnose this abnormality. This finding is

TABLE 2
Preoperative and Postoperative Diagnostic Information^a

Patient	Provisional Preoperative Diagnosis	Postoperative Diagnosis							
		IPT	Capsular Fibrosis	Loose Bodies	Cup Prominence	Synovitis	Pincer Lesion	Cement Piece	Trochanteric Bursitis
1	IPT, capsular fibrosis	x	x	x ^b	x (17 mm) ^b				
2	IPT	x	x	x ^b				x ^b	
3	IPT	x	x						
4	IPT	x	x				x ^b		
5	IPT, cup prominence	x	x	x ^b	x (5 mm)		x ^b		
6	IPT, cup prominence	x	x	x ^b	x (3 mm)				
7	IPT	x	x	x ^b	x (7 mm) ^b	x ^b			
8	IPT, cup prominence	x	x		x (10 mm)	x ^b			
9	IPT, trochanteric bursitis	x	x	x ^b					x
10	IPT	x	x						
Total, n (%)		10 (100)	10 (100)	6 (60)	5 (50)	2 (20)	2 (20)	1 (10)	1 (10)

^aIPT, iliopsoas tendinopathy.

^bNew diagnostic information, other IPT, or capsular fibrosis.

TABLE 3
Arthroscopic Procedures Performed

Procedure	n (%)
Capsular release	10 (100)
Proximal iliopsoas recession	10 (100)
Loose body removal	6 (60)
Polyethylene debris removal	3 (30)
Synovectomy	2 (20)
Acetabular osteoplasty	2 (20)
Osteophyte removal	2 (20)
Cement piece removal	1 (10)

comparable with those seen by Cyteval et al⁷ and Dora et al,⁸ and it underlies another advantage of arthroscopic surgery: the precise dynamic evaluation of anatomic interfaces for evidence of impingement, instability, or other abnormalities.²

Hip arthroscopic surgery allowed for numerous therapeutic procedures to address various causes of chronic hip pain. The most common procedure performed was capsular release in which a limited amount of scar tissue near the iliopsoas was released, followed by proximal iliopsoas recession in which the iliopsoas tendon was carefully attenuated, both potentially relieving IPT. Other treatments that could address the causes of chronic hip pain included loose body removal, cement piece removal, polyethylene debris removal, synovectomy, and acetabular osteoplasty. At the latest follow-up, postoperative VAS pain scores were significantly reduced and forward flexion and SLR strength test results were significantly improved compared with preoperatively, and the mean mHHS value was 71.9.

In this study, the relief of hip pain to prevent or delay the need for revision arthroplasty was the primary goal of hip arthroscopic surgery, as revision arthroplasty is invasive and involves a significant recovery time. Overall, 2 patients (20%) converted to revision arthroplasty because of

persistent hip pain. Bajwa and Villar² performed the only case-control study in the literature, comparing hip arthroscopic surgery in patients who had undergone previous arthroplasty with the same procedure in patients with a native hip. The authors found that 42% (10/24) of patients in the case group were pain-free at 1-year follow-up after arthroscopic surgery, with 29% (7/24) converting to revision arthroplasty.² Yet, of the 24 patients in the case group, only 4 had undergone THA, while the rest of the patients had undergone either partial resurfacing or resurfacing procedures before the arthroscopic surgery. In the current study, the survivability of 8 patients (80%) at 6.8-year follow-up supports the use of hip arthroscopic surgery in the treatment of chronic hip pain after THA. In addition, there were no major or minor complications, including extra-articular fluid extravasation, hip dislocations, thromboembolism, or neurapraxia. Overall, hip arthroscopic surgery resulted in good midterm clinical outcomes with no complications.

The second goal of this study was to describe a new cause for IPT that has not been previously reported: disruption of the anterosuperior acetabular capsule. Of the 10 patients, all of whom were found to have IPT, only 6 (60%) had a pincer lesion, cup prominence, or both. The other 4 patients (40%) lacked one of these anatomic causes. Furthermore, a review of the index THA operative notes demonstrated that 2 of the 4 patients had difficult exposure of the anterior capsule. Also, 3 of the 4 patients did not undergo capsular repair.

One potential cause of dynamic IPT could be disruption of the anterosuperior acetabular capsule, including the reflected head of the rectus femoris. This disruption of the capsule could result from aggressive exposure, overrelease, lack of capsular repair, or atrophy of the rectus femoris after arthroplasty. This may allow the iliopsoas tendon, an extra-articular structure, to move into the intra-articular space, placing the tendon in close proximity to the acetabular component and causing impingement.¹⁴ Although numerous causes of hip pain

TABLE 4
Patient Outcomes Before and After Arthroscopic Surgery^a

Patient	mHHS	Conversion to Revision Arthroplasty	VAS		SLR Strength Test		FF, deg		IR, deg		ER, deg	
			Pre	Post	Pre	Post	Pre	Post	Pre	Post	Pre	Post
1	87	No	9	0	+4	+4	90	95	5	5	35	40
2	80	No	6	0	3	5	80	100	10	10	25	35
3	82	No	5	0	+4	+4	90	100	5	10	35	35
4	59	Yes	10	1	3	+4	95	100	5	10	40	50
5	63	No	9	0	+4	5	90	100	5	5	40	45
6	45	No	8	0	+4	5	95	95	5	5	55	45
7	91	No	10	0	+4	5	100	95	10	5	45	45
8	65	Yes	9	7	5	5	70	90	0	10	35	45
9	59	No	10	0	3	3	90	100	0	15	40	45
10	88	No	9	0	4	5	115	115	5	10	35	35
Mean ± SD (range)	71.9 ± 15.6		8.5 ± 1.7	0.8 ± 2.2	+4 (3-5)	+4 (3-5)	91.5 ± 11.8	99.0 ± 6.6	5.0 ± 3.3	8.5 ± 3.4	38.5 ± 7.8	42.0 ± 5.4
or median (range)	(45.0-91.0)		(5.0-10.0)	(0.0-7.0)			(70.0-115.0)	(90.0-115.0)	(0.0-10.0)	(5.0-15.0)	(25.0-55.0)	(35.0-50.0)
P value			.0055		.0263		.0183		.0886		.1108	

^aNone of the patients experienced any major or minor complications. ER, external rotation; FF, forward flexion; IR, internal rotation; mHHS, modified Harris Hip Score; post, postoperative; pre, preoperative; SLR, straight leg raise; VAS, visual analog scale.

in patients after THA have been described in the literature, to our knowledge, disruption of the anterosuperior acetabular capsule as a precipitating factor of IPT has not been mentioned.

The diagnosis of acetabular capsule disruption is primarily based on a clinical examination of the rectus femoris and hip instability. The reflected head of the rectus femoris contributes to the anterosuperior acetabular rim, providing anterior hip stability.¹³ The anterior capsule and reflected head of the rectus femoris may be disrupted during THA or during postoperative healing and scarring. For example, this disruption could occur while gaining exposure of the acetabular cup by placing a retractor over the superior acetabular ridge to push the proximal femur out of the way.

Anatomic studies have shown that the rectus femoris has an important secondary role in hip flexion: supporting the iliopsoas, the primary hip flexor. If the anterior capsule and reflected head of the rectus femoris have been disrupted during index THA, the remaining hip flexion strength is largely dependent on the iliopsoas.^{4,26} Physical examination maneuvers that compare hip flexion strength in different positions can be used to modulate the flexion contribution of the iliopsoas, allowing the clinician to identify a weakened rectus femoris.

Comparing hip flexion strength elicited during the SLR (or Stinchfield) strength test versus the seated hip flexion test can be used to identify a weakened rectus femoris. The SLR strength test is performed with the patient in the supine position, with the knee locked in full extension and the patient instructed to perform a straight leg raise to 30° of hip flexion while the examiner applies a downward force near the knee. On the other hand, the seated hip flexion test is performed with the patient in a normal seated position, with the hip and knee flexed to 90° and the patient instructed to raise the knee toward the chest while the examiner applies a downward force on the proximal knee.^{16,19,23}

In patients with a disrupted acetabular capsule and reflected head, there may be decreased hip flexion strength on the SLR strength test compared with normal strength on

the seated hip flexion test. A possible explanation for these differing levels of hip flexion strength could be explained by the Blix length-force curve.²² While the patient is seated, the iliopsoas muscle is near its resting length and can produce a large contractile force. On examination, this presents as normal hip flexion strength regardless of the contribution by the reflected head of the rectus femoris. Yet, when the patient is supine as in the SLR strength test, the iliopsoas is stretched to near its maximal length and is able to generate only a minimal contractile force. Thus, hip flexion is almost entirely dependent on the rectus femoris, which would expose the disrupted anterior capsule and reflected head.

Besides a clinical examination, ultrasound could be used preoperatively to identify the thickness and echogenic intensity of the rectus tendon to assess for a weakened rectus femoris. However, there is no evidence regarding the use of ultrasound in patients who have undergone hip replacement. Furthermore, ultrasound is highly user dependent; Ishida et al¹¹ reported in a 2017 study that even a little difference in tilting the transducer while measuring the rectus femoris can lead to missing significant changes in the tendon. An additional study evaluating the value of ultrasonography in the diagnosis of IPT after THA found that despite ultrasound findings, an iliopsoas tendon sheath injection is necessary in most cases for a provisional preoperative diagnosis.⁹

Limitations

There are important limitations to this study. First, the index THA operative notes for 2 of the patients were not available, as the surgical procedures had been performed at another institution. Second, because all 10 patients were found to have IPT, this limited our ability to statistically analyze associated risk factors, such as prosthetic head size. Third, despite a longer follow-up compared with similar existing studies, this study has a small sample size, limiting the interpretation of the results. Further investigation with larger sample sizes is needed. However, we

believe that this study adds to the small body of literature regarding hip arthroscopic surgery in patients with chronic hip pain after THA, while being the first study to attain midterm follow-up. In addition, this study describes a new cause of IPT involving the role of disruption of the anterior capsule and reflected head of the rectus femoris.

CONCLUSION

Hip arthroscopic surgery was found to have an important role in the diagnostic and therapeutic management of patients with a chronic painful hip after THA, with good clinical outcomes at a mean follow-up of 6.8 years and no complications. We believe that disruption of the anterosuperior acetabular capsule, including the reflected head of the rectus femoris, can allow the iliopsoas tendon to move intra-articularly and precipitate IPT. This disruption may be appreciated on the SLR strength test. Although this study presents a small sample size that cannot substantiate a cause-effect relationship, orthopaedic surgeons performing THA should consider minimizing disruption and/or ensuring repair of the anterior capsule to decrease this potential cause of IPT.

ACKNOWLEDGMENT

The authors thank John Stelzer for his assistance in data collection.

REFERENCES

- Ala Eddine T, Remy F, Chantelot C, Giraud F, Migaud H, Duquenoey A. Anterior iliopsoas impingement after total hip arthroplasty: diagnosis and conservative treatment in 9 cases. *Rev Chir Orthop Reparatrice Appar Mot.* 2001;87(8):815-819.
- Bajwa AS, Villar RN. Arthroscopy of the hip in patients following joint replacement. *J Bone Joint Surg Br.* 2011;93(7):890-896.
- Bricteux S, Beguin L, Fessy MH. Iliopsoas impingement in 12 patients with a total hip arthroplasty. *Rev Chir Orthop Reparatrice Appar Mot.* 2001;87(8):820-825.
- Brown AM, Zifchock RA, Hillstrom HJ. The effects of limb dominance and fatigue on running biomechanics. *Gait Posture.* 2014;39(3):915-919.
- Classen T, Zaps D, Landgraeber S, Li X, Jäger M. Assessment and management of chronic pain in patients with stable total hip arthroplasty. *Int Orthop.* 2013;37(1):1-7.
- Conaway WK, Martin SD. Puncture capsulotomy during hip arthroscopy for femoroacetabular impingement: preserving anatomy and biomechanics. *Arthrosc Tech.* 2017;6(6):e2265-e2269.
- Cyteval C, Sarraière MP, Cottin A, et al. Iliopsoas impingement on the acetabular component: radiologic and computed tomography findings of a rare hip prosthesis complication in eight cases. *J Comput Assist Tomogr.* 2003;27(2):183-188.
- Dora C, Houweling M, Koch P, Sierra RJ. Iliopsoas impingement after total hip replacement: the results of non-operative management, tenotomy, or acetabular revision. *J Bone Joint Surg Br.* 2007;89(8):1031-1035.
- Guillin R, Bertaud V, Garetier M, Fantino O, Polard J-L, Lambotte J-C. Ultrasound in total hip replacement: value of anterior acetabular cup visibility and contact with the iliopsoas tendon. *J Ultrasound Med.* 2018;37(6):1439-1446.
- Heaven S, de Sa D, Simunovic N, Williams DS, Naudie D, Ayeni OR. Hip arthroscopy in the setting of hip arthroplasty. *Knee Surg Sports Traumatol Arthrosc.* 2016;24(1):287-294.
- Ishida H, Suehiro T, Suzuki K, Yoneda T, Watanabe S. Influence of the ultrasound transducer tilt on muscle thickness and echo intensity of the rectus femoris muscle of healthy subjects. *J Phys Ther Sci.* 2017;29(12):2190-2193.
- Jerosch J, Neuhäuser C, Sokkar SM. Arthroscopic treatment of iliopsoas impingement (IPI) after total hip replacement. *Arch Orthop Trauma Surg.* 2013;133(10):1447-1454.
- John Cooper H, Walters BL, Rodriguez JA. Anatomy of the hip capsule and pericapsular structures: a cadaveric study. *Clin Anat.* 2015;28(5):665-671.
- Lachiewicz PF, Kauk JR. Anterior iliopsoas impingement and tendinitis after total hip arthroplasty. *J Am Acad Orthop Surg.* 2009;17(6):337-344.
- Maher P, Cardozo E, Singh JR. Technique for fluoroscopically guided injection for iliopsoas bursitis. *Am J Phys Med Rehabil.* 2014;93(12):1105-1106.
- Maslowski E, Sullivan W, Forster Harwood J, et al. The diagnostic validity of hip provocation maneuvers to detect intra-articular hip pathology. *PM R.* 2010;2(3):174-181.
- McCarthy JC, Jibodh SR, Lee JA. The role of arthroscopy in evaluation of painful hip arthroplasty. *Clin Orthop Relat Res.* 2009;467(1):174-180.
- O'Connell RS, Constantinescu DS, Liechti DJ, Mitchell JJ, Vap AR. A systematic review of arthroscopic versus open tenotomy of iliopsoas tendonitis after total hip replacement. *Arthroscopy.* 2018;34(4):1332-1339.
- Pacheco-Carrillo A, Medina-Porqueres I. Physical examination tests for the diagnosis of femoroacetabular impingement: a systematic review. *Phys Ther Sport.* 2016;21:87-93.
- Petis SM, Howard JL, McAuley JP, Somerville L, McCalden RW, MacDonald SJ. Comparing the long-term results of two uncemented femoral stems for total hip arthroplasty. *J Arthroplasty.* 2015;30(5):781-785.
- Potter HG, Nestor BJ, Sofka CM, Ho ST, Peters LE, Salvati EA. Magnetic resonance imaging after total hip arthroplasty: evaluation of periprosthetic soft tissue. *J Bone Joint Surg Am.* 2004;86(9):1947-1954.
- Rassier DE, MacIntosh BR, Herzog W. Length dependence of active force production in skeletal muscle. *J Appl Physiol.* 1999;86(5):1445-1457.
- Reiman MP, Goode AP, Cook CE, Hölmich P, Thorborg K. Diagnostic accuracy of clinical tests for the diagnosis of hip femoroacetabular impingement/labral tear: a systematic review with meta-analysis. *Br J Sports Med.* 2015;49(12):811.
- Sochacki KR, Jack RA, Safran MR, Nho SJ, Harris JD. There is a significant discrepancy between "big data" database and original research publications on hip arthroscopy outcomes: a systematic review. *Arthroscopy.* 2018;34(6):1998-2004.
- Trousdale RT, Cabanela ME, Berry DJ. Anterior iliopsoas impingement after total hip arthroplasty. *J Arthroplasty.* 1995;10(4):546-549.
- Valente G, Taddei F, Jonkers I. Influence of weak hip abductor muscles on joint contact forces during normal walking: probabilistic modeling analysis. *J Biomech.* 2013;46(13):2186-2193.
- Varacallo M, Johanson NA. *Hip, Replacement.* Treasure Island, Florida: StatPearls Publishing; 2018.