

## C A S E R E P O R T

## Ceramic on ceramic total HIP arthroplasty and liner fracture. Two case reports and review of literature

*Claudio Goretti, Federico Polidoro, Stefania Paderni, Alberto Belluati*

Department of Orthopaedic and Traumatology, "Santa Maria Delle Croci Hospital", Ravenna, Italy

**Summary.** *Background and aim of the work:* Ceramic on ceramic bearing surfaces in total hip arthroplasty are rising in number with the purpose of reducing debris osteolysis in young patients. New generation ceramics drastically reduced the well known problem of liner's fracture associated with this material but this still represents a complication. *Methods:* We present the only two cases of acetabular liner fracture we had in our department, on a total of 252 patients, since we use CoC bearing surfaces in THR (2005-2019) analyzing symptoms and causes of this complication. Review of recent literature focused on symptoms and causes of liners fracture, well matched our cases. *Results:* In line with the analysis of literature, the major cause of liner fracture is neck-cup impingement resulting in the "edge-loading" effect, followed by other factors like prosthesis design, traumas and patient weight. From data also emerge the role of acoustic phenomena (e.g. squeaking) and CT scan in the diagnostic process. *Conclusions:* Last generation ceramics should be used in CoC THR, implant malposition and prosthesis design have a dominant role in liner fracture, squeaking should always be investigated. CT scan have an important role in diagnosis. Implant revision with substitution of the bearing surfaces is mandatory in case of fracture or impending fracture signs. ([www.actabiomedica.it](http://www.actabiomedica.it))

**Key words:** THR, ceramic, fracture, squeaking

### Background and aim of the work

Ceramic-on-ceramic (CoC) bearing surfaces in total hip arthroplasty (THA) were developed with the purpose of reducing wear-induced osteolysis in young and active patients undergoing total hip replacement, thus theoretically decreasing the need for early aseptic loosening revision of the implant. Indeed, the use of other bearing surfaces routinely used in hip replacement surgery are demonstrated to produce a much higher rate of debris particles (1000 times more for metal-on-polyethylene and 40 times more for metal-on-metal surfaces(1)) and to be more related to bone resorption (2) around the implant than ceramic-on-ceramic surfaces. The typical low rate of debris production in CoC implants seems to be related to their extremely hard scratch-resistant surfaces and their hy-

drophilic characteristics that improve lubrication over the bearing surfaces (3).

A still present problem with this kind of implant, however, is the risk of liner and femoral head prosthetic fractures, though the introduction of new generation ceramics (e.g. Biolox-Delta®), decreased the rate of this complications to a 0,004% for femoral head and 1,12%-3,3% for liners (4-6).

Proposed causes of ceramic components fracture are the neck-cup impingement due to excessive acetabular cup anteversion especially during squatting, kneeling, and sitting cross-legged (5, 7, 8), dislocation, microseparation, trauma with implantation, and malposition of the implant (9, 10). In fact, the ideal abduction and anteversion angles for the acetabular cup appear to be respectively 45° to 55° and 10° to 15° (5), higher angles relating to neck-cup impingement.

The typical kinematics regarding neck-cup impingement seems to be referred to two mechanisms: the so called “edge-loading” effect, in which the contact between the neck of the femoral component and the edge of the cup produce the head subluxation on the opposite side causing a stress rise at this level where the fracture line starts; and a chipping ceramic mechanism due to repetitive neck-cup contact on the same side of the contact (11).

Clinical presentation of ceramic liner fracture can vary from audible noise (squeaking) during walking, or anyhow during active hip movement, to local instability, and in some cases can even remain undiagnosed for long time. Otherwise ceramic femoral head fracture is always a catastrophic event (12) presenting with acute pain and hip impairment.

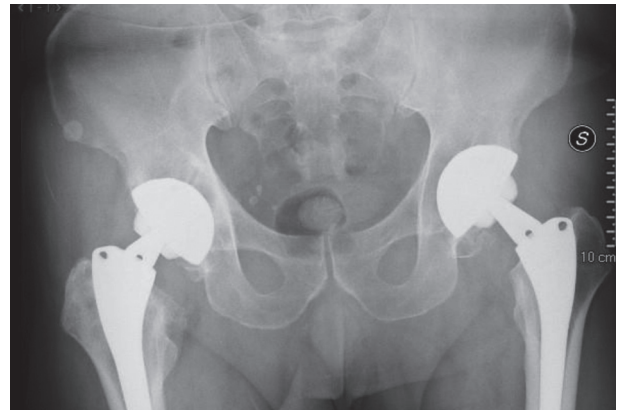
Investigation of a noisy-unsafe CoC THR should include standard pelvis and hip X-rays and a CT scan of the involved hip to detect any ceramic periarticular fragments or a major fracture line; and a needle aspiration of the articular synovial fluid to be analyzed looking for ceramic fragments around or  $>5 \mu\text{m}$  (12).

Considering the above, we review our CoC THR registry, looking for ceramic fracture cases, diagnostic process and treatment.

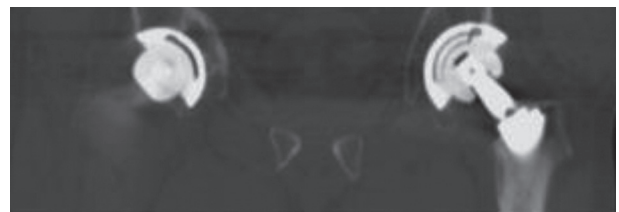
## Materials and methods

We report the only 2 cases of ceramic fracture on a total of 252 patients treated with CoC THR in the period 2001-2019 in our department.

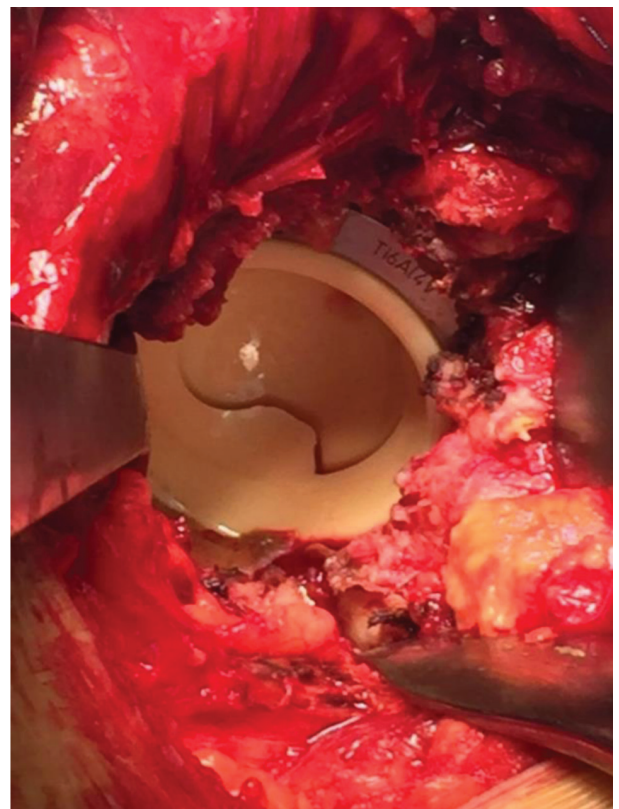
Case 1: 58 y.o. male with bilateral uncemented THR implanted 9 years earlier. He presented to us complaining a noise in the left hip began two weeks earlier apparently causeless and audible during walking and active range of motion of the interested hip, without any other symptoms like pain or swelling. Standard X-rays of pelvis and left hip were taken, without any sign of aseptic loosening or periarticular foreign bodies. A CT scan proved a fracture line involving the liner component. Revision surgery was then performed with substitution of femoral head and liner with a new generation ceramic of the same sizes. No chipping was



Case 1: no radiographic signs of periarticular ceramic bodies or aseptic loosening



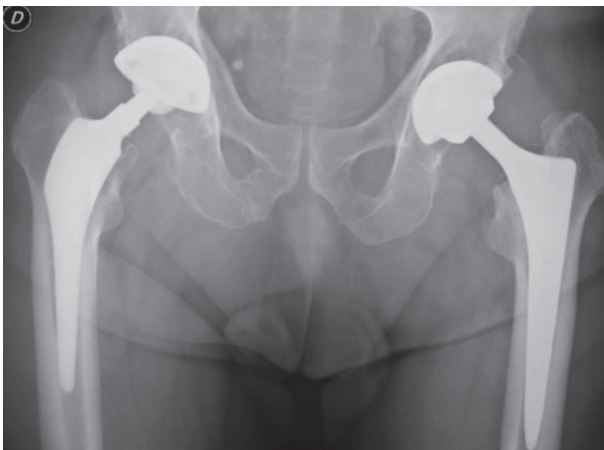
Case 1: TC sign of left THR liner fracture



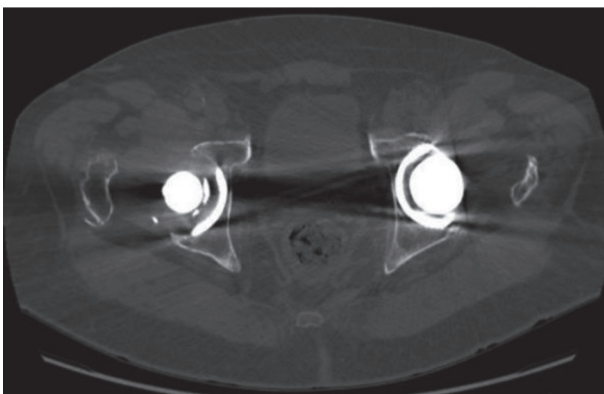
Case 1: intraoperative finding of left THR liner fracture

found on liner and no instability of the implant was present so we supposed the cause of fracture was the low resistance of the old generation ceramic used in the previous implant, allowing us to let the metal-back in place, verifying no neck-cup impingement after component substitution.

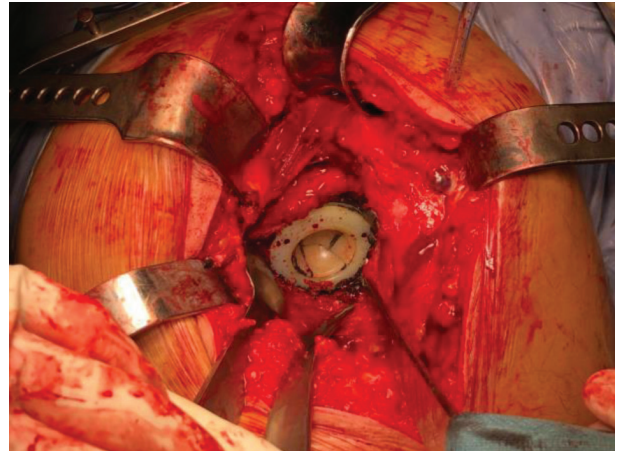
Case 2: 82 y.o. male with bilateral uncemented THR implanted 11 years earlier. He presented to us complaining noise and pain in the right hip during walking, began 6 weeks earlier apparently causeless. Also in this case standard X-rays of pelvis and left hip were taken, without any sign of aseptic loosening or periarticular foreign bodies. CT scan confirmed the suspect of a fracture line involving the liner component. Revision surgery was performed. Liner inspection revealed a moderate chipping on the opposite side



Case 2: no radiographic signs of periarticular ceramic bodies or aseptic loosening



Case 2: TC sign of right THR liner fracture



Case 2: intraoperative finding of left THR liner fracture

of the fracture line, and a corresponding mark on the femoral neck in the same position, demonstrating a low-grade neck-cup impingement. A substitution of femoral head and liner with a metal-on-polyethylene component was performed. We chose this option considering the age of the patient and his low-demanding condition at the time of surgical procedure, to reduce surgical related morbidity.

## Results

Both patient healed without surgical related complications and returned to the previous activity level in a relatively short time: one month for the 58 y.o. man and 50 days for the 82 y.o. man. At long term follow-up (at least 2 years), we reported no limitations in daily life activity in both patient, with a complete return to his working activity for the youngest one. No new symptoms or signs like squeaking or pain were found in the revised hips.

## Discussion and conclusions

THR can be considered a successful surgery and patient and surgeon satisfaction is growing up year after year with the improvement in surgical techniques and implant materials. Anyway complications, although decreasing in rate, are still present. A typical complication of ceramic-on-ceramic implants is ceramic frac-



ture, partially solved with the use of new generation ceramics, more durable and resistant to load; the other side of the problem however can be related to surgical technique errors like incorrect positioning of the acetabular cup, causing neck-cup impingement and subsequent abnormal loading of the bearing surfaces. In this regard, the ideal cup position seems to be 45° to 55° of abduction and 10° to 15° of antiversión (5). Audible noise during ambulation, like squeaking, should always alert the patient and the surgeon for possible ceramic fracture and an early diagnostic protocol consisting in X-rays, CT scan and synovial aspiration and analysis should promptly be undertaken. Hip revision surgery should be considered when a noisy CoC THR presents radiographic or synovial fluid signs of ceramic chipping or clear fracture lines (12).

Our experience with ceramic THR fracture is in line with similar cases reported in literature; in the here presented case reports we chose to revision the implants in a minimally invasive way, by the only substitution of the old compromised ceramic components with a new one in the first case and changing the tribologic setup to a more favorable one in the second case.

Our choice of a minimally invasive procedure depended on the absence of major impingement signs in the first case and in the advanced age of the patient (suitable for a metal on polyethylene implant) in the second one, also considering that the fractured ceramics belonged to an old generation material, allowing us to avoid a complete revision of the acetabular cup.

In case of major impingement signs otherwise a formal implant revision should be undertake.

**Conflict of interest:** Each author declares that he or she has no commercial associations (e.g. consultancies, stock ownership, equity interest, patent/licensing arrangement etc.) that might pose a conflict of interest in connection with the submitted article

## References

1. Sedel L. Evolution of alumina-on-alumina implants: a review. *Clinical Orthopaedics and Related Research*®, 2000; 379, 48-54.
2. Willert HG, Bertram H, Buchhorn GH. Osteolysis in alloarthroplasty of the hip: the role of ultra-high molecular weight polyethylene wear particles. *Clinical Orthopaedics and Related Research*®, 1990; 258, 95-107.
3. Skinner HB. Ceramic bearing surfaces. *Clinical Orthopaedics and Related Research*®, 1999; 369, 83-91.
4. Massin P, Lopes R, Masson B, Mainard D, Hip F. Does Biolox® Delta ceramic reduce the rate of component fractures in total hip replacement?. *Orthopaedics & Traumatology: Surgery & Research*, 100(6), 2014; S317-S321.
5. Ha YC, Kim SY, Kim HJ, Yoo JJ, Koo KH. Ceramic liner fracture after cementless alumina-on-alumina total hip arthroplasty. *Clinical Orthopaedics and Related Research*®, 2007; 458, 106-110.
6. Park YS, Hwang SK, Choy WS, Kim YS, Moon YW, Lim S. Ceramic failure after total hip arthroplasty with an alumina-on-alumina bearing. *JBJS*, 88(4), 2006; 780-787.
7. Steinhoff A, Hakim V, Walker RH, Colwell CW, Copp SN. Ceramic liner fracture and impingement in total hip arthroplasty. *HSS Journal*®, 11(1), 2015; 50-55.
8. Min BW, Song KS, Kang CH, Bae KC, Won YY, Lee KY. Delayed fracture of a ceramic insert with modern ceramic total hip replacement. *The Journal of arthroplasty*, 2007; 22(1), 136-139.
9. D'Antonio J, Capello W, Manley M, Bierbaum B. New experience with alumina-on-alumina ceramic bearings for total hip arthroplasty. *The Journal of arthroplasty*, 2002; 17(4), 390-397.
10. Nevelos J, Ingham E, Doyle C, Streicher R, Nevelos A, Walter W, Fisher, J. Microseparation of the centers of alumina-alumina artificial hip joints during simulator testing produces clinically relevant wear rates and patterns. *The Journal of arthroplasty*, 2000; 15(6), 793-795.
11. Elkins JM, Pedersen DR, Callaghan JJ, Brown TD. Fracture propagation propensity of ceramic liners during impingement-subluxation: a finite element exploration. *The Journal of arthroplasty*, 2012; 27(4), 520-526.
12. Toni A, Traina F, Stea S, Sudanese A, Visentin M, Bordini B. Early diagnosis of ceramic liner fracture: guidelines based on a 12-year clinical experience with 3710 modern ceramic prostheses. 2006; In Exhibited at the Annual Meeting of the American Academy of Orthopaedic Surgeons (pp. 22-24).

Received: 1 October 2019

Accepted: 3 November 2019

Correspondence:

Polidoro Federico

UO di Ortopedia e Traumatologia

Viale Vincenzo Randi, 5 - 48121 Ravenna RA

Tel. +39 3286786599

Fax +39 0544286063;

E-mail: federicopolidoro@hotmail.it