

# Colon capsule endoscopy: an innovative method for detecting colorectal pathology during the COVID-19 pandemic?

C. MacLeod\*, P. Wilson† and A. J. M. Watson\*

\*Department of Surgery, Raigmore Hospital, Inverness, UK, and †Institute of Applied Health Sciences, University of Aberdeen, Aberdeen, UK

Received 27 April 2020; accepted 6 May 2020; Accepted Article online 13 May 2020

## Abstract

**Aim** The coronavirus pandemic has led to significant challenges for healthcare delivery across the globe. Non-emergency endoscopic activity in the UK has been postponed, raising concerns of increased delays in the diagnosis of colorectal cancer and a surge in demand once services resume. Measures to mitigate this risk must be considered.

**Method** This paper reviews various investigative modalities for colorectal disease which could be deployed during cessation of colonoscopy services. We focus on colon capsule endoscopy (CCE) due to its relevance during the COVID-19 pandemic and its ability to triage patients effectively to further endoscopic investigations.

**Results** CT of the abdomen and pelvis has been suggested as a triage tool while access to colonoscopy is limited. However, CT may lead to the spread of COVID-19 as patients attend the hospital, and it exposes them to the risks of radiation. Faecal immunochemistry tests have been demonstrated as a good predictor of colonic pathology and could be safely used to risk stratify patients when prioritizing colonoscopy.

CCE is a safe and innovative technology for investigating the colon. Procedures can be carried out in the community and can be conducted safely during the coronavirus pandemic. It has been shown to be an accurate detector of colonic neoplasia and can reduce demand for colonoscopy.

**Conclusion** As colonoscopy services resume, they will probably experience high demand leading to further delays for patients. CCE could be used to reduce the number of patients requiring colonoscopy and triage those requiring further endoscopic investigations appropriately.

**Keywords** Colon Capsule Endoscopy, colonoscopy, COVID-19

### What does this paper add to the literature?

The COVID-19 pandemic has curtailed non-emergency colonoscopy activity potentially leading to delayed diagnosis of colorectal cancer and anticipated high demand once services resume. Colon capsule endoscopy is a promising technology which could be used to reduce colonoscopy demand and effectively triage patients to colonoscopy with appropriate urgency.

Since the emergence of the novel coronavirus (SARS-CoV-2) in December 2019, COVID-19 infection has developed into a global pandemic [1]. To date, over 247 000 deaths have been attributed to COVID-19 across the world and healthcare systems have been placed under immense pressure [2]. Health services have been forced to focus on the challenges of caring for patients acutely affected by the virus but must also consider mitigation of the risk of delayed diagnoses and treatment of non-coronavirus related conditions. The management of many benign conditions can be safely deferred given the pressures on medical facilities during the pandemic but delivering early diagnosis and timely

care for patients with cancer or time-critical disease is challenging [3].

For colorectal surgery in the UK, the pandemic has led to the curtailment of elective procedures and postponement of all non-emergency endoscopic work, including investigation of positive colorectal cancer screening results received prior to the suspension of screening services [4]. Where possible, elective colorectal cancer surgery continues but, in some units, this may be challenging due to the expansion of critical care units into theatres and the redeployment of surgical staff to other areas [5,6]. Outpatient consultation continues via telemedicine technologies unless emergency face-to-face review is necessary [7].

Timely diagnosis of colorectal cancer is generally reliant on colonoscopy to establish tumour location and to

Correspondence to: Professor Angus J M Watson, Department of Surgery, Raigmore Hospital, NHS Highland, Old Perth Road, Inverness IV2 3UJ, UK.  
E-mail: Angus.watson@nhs.net

obtain a histopathology sample [8]. Reduced colonoscopy activity is likely to delay the diagnosis of colorectal cancer for many patients and, given already substantial waiting times, diagnostic delay and disease progression is a concern [9]. CT colonography is an alternative investigation for colorectal disease but concerns regarding faecal transmission of the virus and the need for lengthy decontamination of equipment have limited its use [10].

Faecal immunochemistry tests have been introduced to help risk stratify patients referred to secondary care with gastrointestinal symptoms. Patients are required to provide a single stool sample which is tested for the presence of occult human blood. The result provided gives a quantitative value proportional to the amount of blood detected. Faecal immunochemistry tests have been shown to be an accurate detector of significant bowel pathology (colorectal cancer, high-risk adenomas or inflammatory bowel disease) and a useful risk stratifying test [11]. Given the ability to carry out the test in the community and its high level of accuracy, it will be a valuable test to prioritize patients waiting for further investigation during the coronavirus pandemic. Carrying out any further investigation during the pandemic must take into consideration the risk to patients and healthcare staff related to viral exposure. CT of the abdomen and pelvis has been suggested as a triage tool for use during the coronavirus pandemic [6]. This would allow patients to be effectively prioritized for colonoscopy once services resume. However, CT carries the inherent risk of radiation to patients and increases footfall within hospitals potentially increasing the spread of COVID-19. There is a paucity of evidence supporting a CT of the abdomen and pelvis as the primary method of detection of colorectal cancer but small studies have demonstrated its sensitivity to range from 72.4% to 100% and specificity from 83.6% to 95.7% [12,13]. Conventional CT abdomen–pelvis is currently the radiological diagnostic modality recommended by the British Society of Gastrointestinal and Abdominal Radiology during the current pandemic.

Colon capsule endoscopy (CCE) is an innovative technology for visualizing the colon which can be carried out in the community, reducing hospital attendance [14]. Telephone consultations are used for pre-procedure patient checks and to explain the bowel preparation regime. Bowel preparation regimes vary but commonly consist of 4 l of polyethylene glycol solution split into 2 l doses taken prior to the procedure and augmented by small volume prokinetic boosters following capsule ingestion. In addition, patients are required to consume a liquid diet on the day prior to and on the day of the procedure to ensure optimum visualization

of the bowel. All bowel preparation medications can be posted directly to patients.

The procedure can be carried out by one healthcare professional in a simple clinic room. It involves fitting a receiver belt to the patient and oral administration of the disposable capsule. Following completion of the procedure, patients can return receiver belts for decontamination according to local arrangements. Following review of the capsule report, clinicians can triage patients to follow-up investigations, if necessary, with appropriate urgency (Fig. 1).

The published literature has shown CCE to be an accurate technology for the detection of clinically significant polyps greater than 10 mm in size [15]. In all concurrent validity studies comparing CCE to colonoscopy, it has detected all colorectal cancers (100% sensitivity/specificity). A recent Danish surveillance study has used CCE as a filter to colonoscopy and demonstrated a reduction in the number of colonoscopies required [16]. Given CCE's high sensitivity for detection of pathology, we suggest its use as a triaging tool, particularly when pressure on endoscopy units is likely to be high. This would allow more appropriate prioritization of patients for colonoscopy. Preliminary results of the current ScotCAP study suggest that CCE can reduce the requirement for colonoscopy in up to 70% of symptomatic patients referred to colorectal services (private communication). Further utility and assessment of CCE will come when the initial results of the ScotCAP study are available later in 2020.

CCE is a safe procedure with a low rate of adverse events [15]. The most serious complication is capsule retention which, although rare, requires clinician awareness. Most occurrences of capsule retention will result in delayed passage, but in some patients it may result in intestinal obstruction necessitating surgical removal. Clinicians should also be aware that, despite the higher volume of preparation needed for CCE over colonoscopy, not all patients will have an adequately visualized colon. While research has been carried out to identify the optimal bowel preparation regime, an inadequate CCE examination is a recognized limitation of this technology [17]. Incomplete CCE examination usually results in patients requiring further colonoscopic evaluation necessitating additional bowel preparation.

Given the relative simplicity of CCE service delivery, existing healthcare staff would require minimal training to deliver this investigation. The volume of patients that could be investigated is likely to be limited by the number of staff available to carry out procedures. Initial investment to scale up CCE delivery could be offset by the potential savings gained by reducing colonoscopy demand. In establishing a CCE service, further consideration would need to be given to CCE video reading

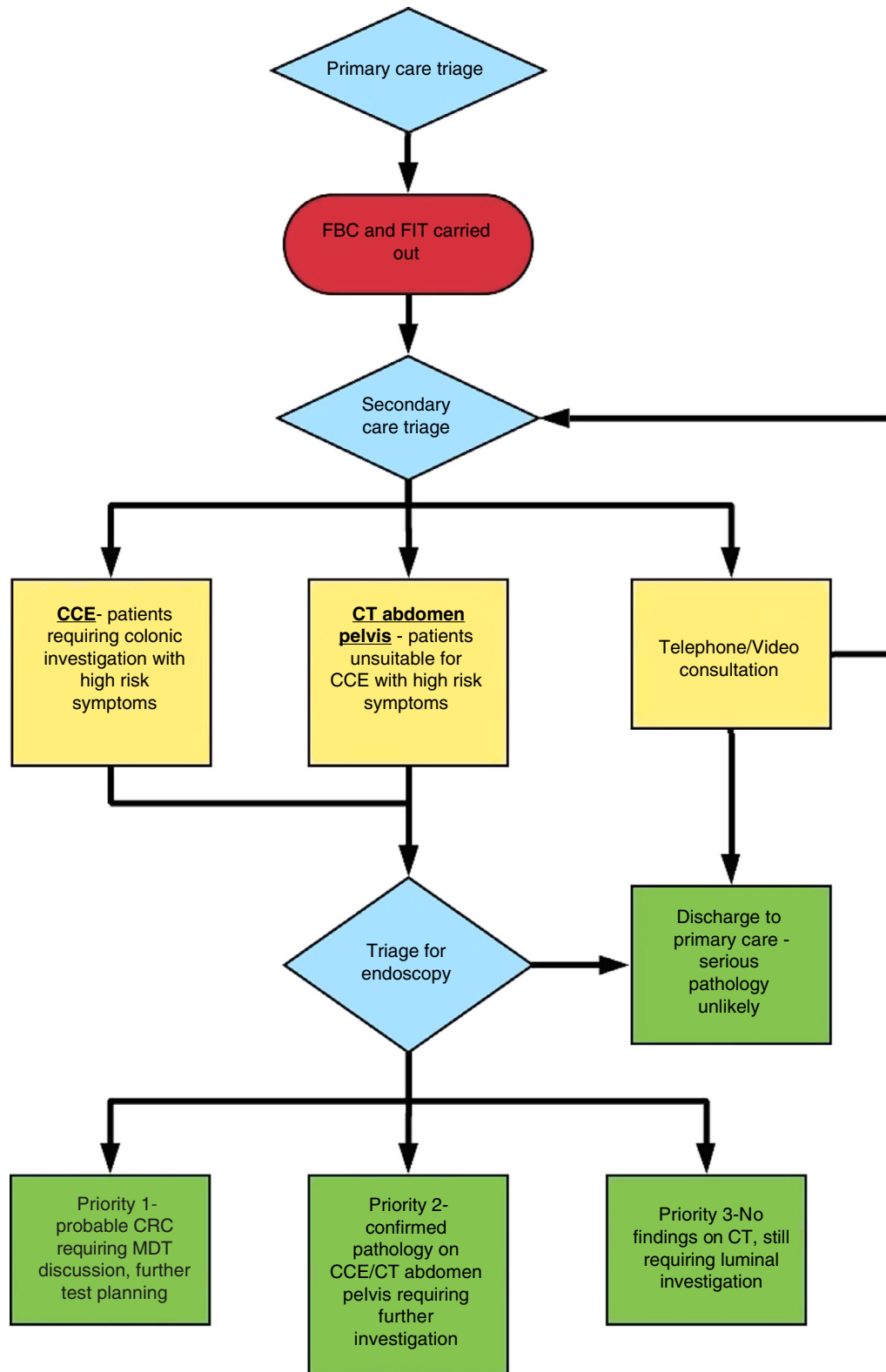


Figure 1 Visualization of the clinical pathway.

which requires specialist readers [18]. There is currently a lack of training for these readers in the UK which would need to be addressed for any expansion of CCE use.

Unfortunately, there is no published work comparing the cost effectiveness of CCE to colonoscopy. However, an economic evaluation comparing CCE to CT colonography in a Canadian population has been carried out [19]. This study calculated that replacing CT colonography with CCE would have moderate cost implications. A CCE procedure was reported to cost \$1120 in this study which included all direct costs and those incurred by potential complications. Further work is needed to establish whether CCE will be cost effective considering the likely reduction in hardware cost and the savings associated with a reduction in colonoscopy requirements.

During any post COVID-19 recovery phase we anticipate traditional colonoscopy services will experience a period of high demand as waiting lists will grow during the current period of reduced activity. CCE is a potentially beneficial method for investigating colorectal patients by reducing the burden on reinstated endoscopy units. Significant planning and innovation will be required to guide the healthcare service back to normality through any recovery phase. The current coronavirus pandemic offers surgeons an opportunity to optimize the interface with primary care, to reconfigure current surgical services, to evaluate changes to colorectal practice and to realize the potential of cutting edge innovation to enable safe and timely investigation and treatment for patients during the era of COVID-19.

## Funding

No funding has been received by any author in relation to this article.

## Conflicts of interest

We declare no conflicts of interest related to this article. Accepted Article online 13 May 2020

## References

- 1 WHO. Novel Coronavirus – China. WHO, 2020.
- 2 Home – Johns Hopkins Coronavirus Resource Center [Internet]. <https://coronavirus.jhu.edu/> (accessed May 2020).
- 3 Clinical guide to surgical prioritisation during the coronavirus pandemic [Internet], 2020. <https://www.england.nhs.uk/coronavirus/wp-content/uploads/sites/52/2020/03/C0221-specialty-guide-surgical-prioritisation-v1.pdf> (accessed April 2020).
- 4 NHS England. Clinical guide for the management of patients requiring endoscopy during the coronavirus pandemic, 2020.
- 5 Burki TK. Cancer guidelines during the COVID-19 pandemic. *Lancet Oncol* 2020; **21**: 629–30.
- 6 Association of Coloproctology of Great Britain and Ireland Considerations for Multidisciplinary Management of Patients with Colorectal Cancer during the COVID-19 Pandemic, 2020. <https://www.acpghi.org.uk/content/uploads/2020/03/ACPGBI-statement-on-CRC-treatment-during-COVID-19-FINAL.pdf> (accessed April 2020).
- 7 Gunner CK, Oliphant R, Watson AJM. Crises drive innovation. *Colorectal Dis* 2020. <https://doi.org/10.1111/codi.15043>. published online ahead of print (accessed March 2020).
- 8 Rees CJ, Gibson ST, Rutter MD *et al.* UK key performance indicators and quality assurance standards for colonoscopy. *Gut* 2016; **65**: 1923–9.
- 9 NHS diagnostic waiting times and activity data 2: NHS diagnostic waiting times and activity data monthly report, 2019. <https://www.england.nhs.uk/statistics/wp-content/uploads/sites/2/2020/04/DWTA-Report-February-2020-4Yae7.pdf> (accessed April 2020).
- 10 CT colonography activity and COVID-19: British Society of Gastrointestinal and Abdominal Radiology guidance [Internet]. [https://www.bsgar.org/static/uploads/CT%20Colonography%20activity%20and%20Covid\\_v2\\_\(25th%20March%202020\).pdf](https://www.bsgar.org/static/uploads/CT%20Colonography%20activity%20and%20Covid_v2_(25th%20March%202020).pdf) (accessed April 2020).
- 11 Mowat C, Digby J, Strachan JA *et al.* Faecal haemoglobin and faecal calprotectin as indicators of bowel disease in patients presenting to primary care with bowel symptoms. *Gut* 2016; **65**: 1463–9.
- 12 Ozel B, Pickhardt PJ, Kim DH, Schumacher C, Bhargava N, Winter TC. Accuracy of routine nontargeted CT without colonography technique for the detection of large colorectal polyps and cancer. *Dis Colon Rectum* 2010; **53**: 911–8.
- 13 Johnson CD, Chen MH, Toledano AY *et al.* Accuracy of CT colonography for detection of large adenomas and cancers. *N Engl J Med* 2008; **359**: 1207–17.
- 14 MacLeod C, Monaghan E, Banerjee A *et al.* Colon capsule endoscopy. *Surgeon* 2020 <https://doi.org/10.1016/j.surge.2020.01.008>. published online ahead of print, (accessed April 2020).
- 15 Spada C, Pasha SF, Gross SA *et al.* Accuracy of first- and second-generation colon capsules in endoscopic detection of colorectal polyps: a systematic review and meta-analysis. *Clin Gastroenterol Hepatol* 2016; **14**: 1533–43.e8.
- 16 Kroijer R, Kobaek-Larsen M, Qvist N, Knudsen T, Baatrup G. Colon capsule endoscopy for colonic surveillance. *Colorectal Dis* 2019; **21**: 532–7.
- 17 Buijs M, Ramezani M, Herp J *et al.* Assessment of bowel cleansing quality in colon capsule endoscopy using machine learning: a pilot study. *Endosc Int Open*. 2018; **06**: E1044–E1050.
- 18 Fernandez-Urien I, Panter S, Carretero C *et al.* International core curriculum for capsule endoscopy training courses. *Endosc Int Open* 2017; **05**: E526–E538.
- 19 Palimaka S, Blackhouse G, Goeree R. Colon capsule endoscopy for the detection of colorectal polyps: an economic analysis. *Ont Health Technol Assess Ser* 2015; **15**: 1–43.