

# SUPRAPUR®: Safe and convenient percutaneous suprapubic catheterisation in high-risk patients

Maximilian Christian Kriegmair<sup>1</sup>, Philipp Mandel<sup>2</sup>, Manuel Ritter<sup>1</sup>

<sup>1</sup>Department of Urology, University Medical Center Mannheim, Mannheim, Germany

<sup>2</sup>Department of Urology, University Hospital Hamburg-Eppendorf, Hamburg, Germany

**Citation:** Kriegmair MC, Mandel P, Ritter M. SUPRAPUR®: Safe and convenient percutaneous suprapubic catheterisation in high-risk patients. Cent European J Urol. 2015; 68: 478-483.

## Article history

Submitted: May 11, 2015

Accepted: June 16, 2015

Published on-line: Nov. 25, 2015

## Corresponding author

Maximilian Kriegmair  
University Medical  
Center Mannheim  
Department of Urology  
Theodor-Kurzer-Ufer 1-3  
68167 Mannheim, Germany  
phone: +49 151 190 90 062  
maximilian.kriegmair@  
medma.uni-heidelberg.de

**Introduction** Ultrasound-guided percutaneous placement of a suprapubic cystostomy is a common and generally safe procedure in everyday surgery. In case of adverse patient characteristics such as small bladder capacity or high body mass index, however, the procedure carries an increased risk of severe complications, including bowel perforation. The Suprapur® cystostomy set is supposed to enable a safer procedure. The aim of our work was to evaluate the safety and ease of use of the Suprapur® cystostomy set.

**Material and methods** We prospectively evaluated the Suprapur® set in high-risk patients, having either a small bladder capacity below 250 ml or a BMI above 30 kg/m<sup>2</sup>. Complications and surgical outcome were monitored. In addition, patients' contentment and pain during the procedure was assessed with a visual analogue scale (VAS). Possible drawbacks and ease of use were evaluated by customized questionnaires for the operating physician.

**Results** In total, 26 cystostomies were performed by 15 different physicians, 40% (n = 6) of whom were inexperienced first or second year residents. No complications occurred. Mild gross haematuria occurred in 11.5% (n = 4) of cases. Average VAS for pain during and two hours after the procedure was 2.1 (±1.2) and 0.3 (±0.5) respectively. In 91% (n = 20) of the procedures, the physicians claimed to have felt safe using SUPRAPUR® and more comfortable (82%, n = 18) than with a conventional cystostomy set.

**Conclusions** SUPRAPUR® allows a safe and simple placement of a suprapubic cystostomy even in high-risk patients or in inexperienced hands. It might help to reduce the complications of a common and frequent surgical procedure.

**Key Words:** suprapubic cystostomy <> complications <> bladder drainage <> high-risk patients

## INTRODUCTION

Percutaneous suprapubic cystostomy (SPC) is a common procedure in urological surgery and is used in a wide range of disorders [1]. It allows drainage of the bladder in case of urinary retention when subvesical obstruction, due to benign prostrate hyperplasia, urethral strictures or phimosis, prevents transurethral catheterization. Furthermore, SPC can be applied as a simple solution for indwelling catheterization in patients with severe incontinence or neurogenic bladder outlet dysfunctions [2, 3, 4]. Generally, SPC is a safe procedure, which can be performed un-

der local anaesthesia and ultrasound-guidance in the majority of cases. After a suprapubic stab incision, a punch trocar is inserted into the bladder, which is used to guide the catheter to its destination [5]. Despite this simple mechanism, placing a SPC harbours a not inconsiderable risk of complications such as bleeding and gross haematuria, infection or malpositioning. The most dreaded complication, however, is perforation of the intestine, observed in around 2.5% of cases [6, 7]. In patients who present additional risk factors such as obesity, small bladder capacity or previous abdominal surgery and radiotherapy, the hazard of severe complications might even be higher.

In 1990, McMullin first described an advanced technique to enable the safe insertion of SPC using the Seldinger technique [8]. The Suprapur® cystostomy set (REF 3047, Uromed, Oststeinbek, Germany) comprises all components for SPC placement by the respective technique. The aim of our study was to prospectively evaluate the clinical usability and value of Suprapur® in high-risk patients.

## MATERIAL AND METHODS

### Patient selection and assessment

The study was approved by the local ethical committee (2014-426-M-MA). We prospectively identified possible high-risk patients, as those who fulfilled one of the study inclusion criteria: BMI >30 kg/m<sup>2</sup>, bladder capacity <250 ml, previous abdominal surgery or radiotherapy. After giving informed consent, the patients underwent SPC by either a urologist or radiologist at our university medical centre. Patient characteristics as well as surgical outcome, such as procedure time or complications using the Clavien classification, were assessed [9]. Bladder capacity was directly measured while filling the bladder *via* a transurethral catheter (TUC). Customized questionnaires were employed to evaluate the usability of Suprapur®, as well as patients' contentment. The questionnaire for the operating surgeon contained one question on general convenience: surgeons were asked to assess, on an analogue scale from 1-5, how secure they felt using Suprapur® in the respective high-risk patients. Three further questions prompted the physician to compare Suprapur®

to standard punch trocar cystostomy sets in terms of feeling of security, usability and time exposure. Using a visual analogue scale (VAS) from 1–10, patients were asked to indicate their pain level during and 2 hours after placement of the SPC. They were also asked to state the level of inconvenience posed by the procedure compared to their expectations.

### The Suprapur® set

As shown in Figure 1, the Suprapur® set contains a puncture cannula 17.5 GA with a needle length of 18.5 cm, a Lunderquist guidewire (70 cm length) with an insertions guide, two facial dilators (Ch 10 and Ch 14) and a dilation balloon catheter (Ch 12.5 ml balloon) with a cylindrical tip.

### Placement of the suprapubic cystostomy using the Suprapur® set

Prior to the procedure, informed consent to the surgery and the participation in this study was obtained. Microbiological testing of the urine was performed at least 3 days prior to SPC placement and antibiotic therapy was initiated in case of a positive urine culture. If the operating surgeon was a resident, an experienced urologist supervised the procedure. If possible, transurethral catheterization was performed to fill the bladder with saline solution. Local anaesthesia was performed with 10 ml 0.5% scandicain. On patient request, analgosedation with piritramid and midazolam was given. General anaesthesia was performed only in case of severe pain or anxiety. A 17.5 GA cannula was used to puncture the bladder under ultrasound guidance. Advanced imaging with fluoroscopy or computed tomography was employed only in the case of an unfavourable sonographic condition that prohibited safe puncture under ultrasound guidance. After extraction of the core, the guidewire was inserted into the bladder. Subsequent dilation and the insertion of the catheter were carried out *via* the tensioned guide wire. In the case of haematuria, the catheter was set under gentle traction to compress the access course as described before [5]. After confirmation of correct catheter placement using ultrasound, patients were observed for at least two hours.

## RESULTS

Of the 96 possible candidates assessed for SPC placement during the study period, 26 met our inclusion criteria. Table 1 presents the patient characteristics of the study population. Mean patient age was 65.2 (±17.9) years and mean BMI 28.8 (±3.8) kg/m<sup>2</sup>. The average maximum bladder capacity was 210



**Figure 1.** Content of the Suprapur® cystostomy set (from left): dilation balloon catheter (Ch12, 5 ml balloon) with a cylindrical tip, a Lunderquist guidewire (70 cm length) with an insertions guide, a puncture cannula 17.5 GA with a needle length of 18.5 cm, two facial dilators (Ch 10 and Ch 14) and a catheter plug.

**Table 1.** Patient characteristics of the 26 high-risk patients. Mean and standard deviation are given, unless noted otherwise

Age, yrs	67.5 ±17.9
BMI, kg/m <sup>2</sup>	29.5 ±3.8
Max. bladder capacity, ml	210 ±56
ASS, % (n)	11.5 (3)
Previous abdominal surgery, % (n)	42.3 (11)
Previous abdominal radiotherapy, % (n)	15.4 (4)
Previous cystostomy, % (n)	11.5 (3)
Indications, % (n)	
BPH	38.5 (10)
Prostatitis	7.7 (2)
Incontinence	30.7 (8)
Prostate cancer	26.9 (7)
Urethral stricture	0 (0)
Neurogenic bladder dysfunction	3.8 (1)

**Table 2.** Speciality and experience of the 15 operating physicians are presented as a percentage and absolute value

Physicians, n=15	
Specialty	
Urologist, % (n)	86.6 (13)
Radiologist, % (n)	13.3 (2)
Work Experience	
Resident, % (n)	73.3 (11)
Attending, % (n)	26.6 (4)
Work experience, yrs	3.3 ±2.9
Physicians with <1 yr work experience	40.0 (6)
Physicians with <10 cystostomies	40.0 (6)
Physicians with <30 cystostomies	73.3 (11)

**Table 3.** Surgical outcome and complications of the 26 suprapubic cystostomy placements are shown. Mean and standard deviation are given, unless noted otherwise

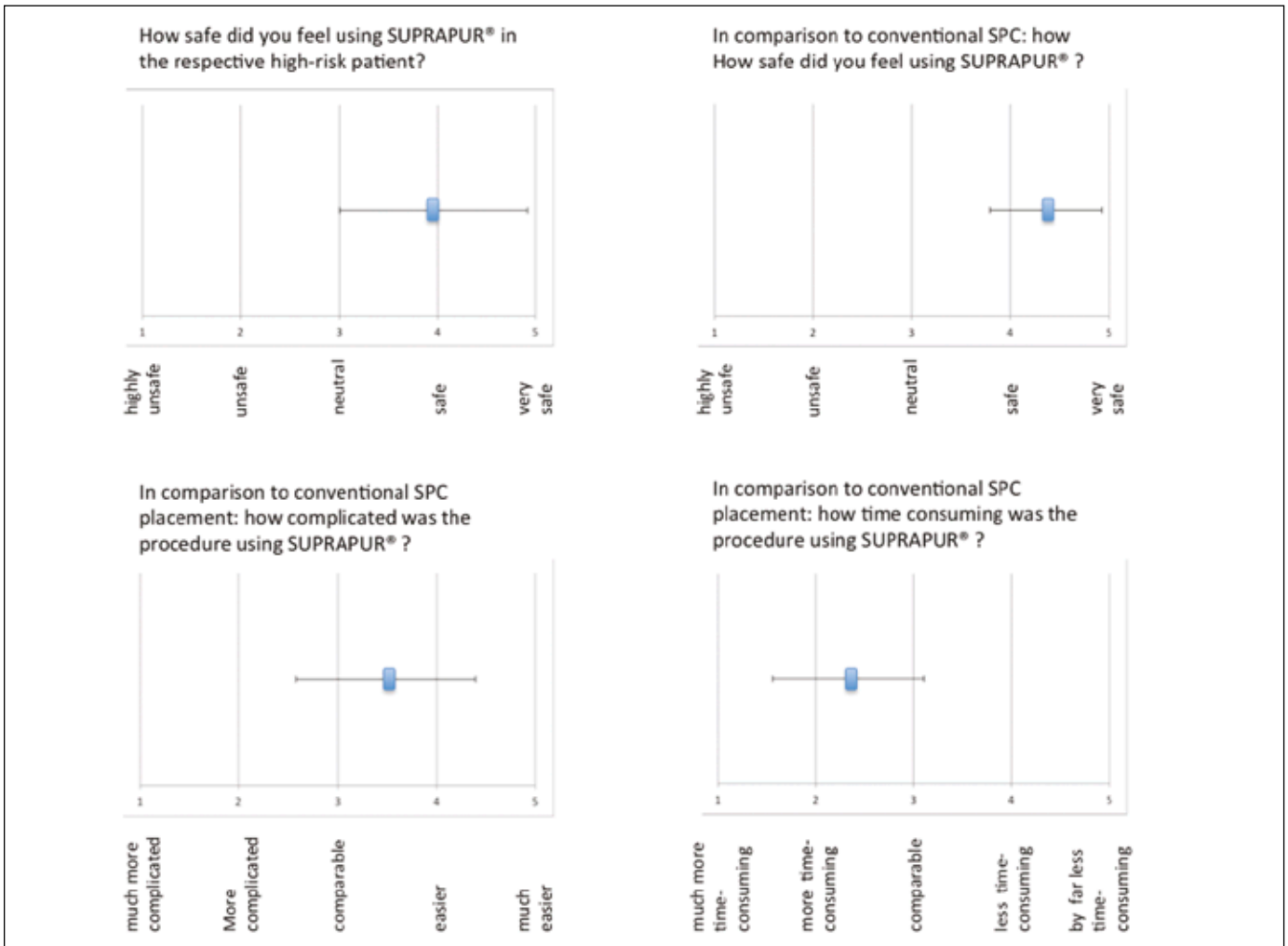
Surgical outcome	
Preparation time, min	10.2 ±3.5
Surgical time, min	9.3 ±4.7
Surgical time residents, min	9.75 ±4.9
Surgical time attending, min	8.8 ±4.8 (p=0.32)
Imaging, % (n)	
Ultrasound	77.0 (20)
Ultrasound and Fluoroscopy	11.5 (3)
Computed tomography	11.5 (3)
Anaesthesia, % (n)	
Local anaesthesia	88.5 (23)
Analgesedation	7.7 (2)
General anaesthetic	3.8 (1)
VAS	
During procedure	2.3 ±1.2
2h after procedure	0.3 ±0.5
Haematuria, % (n)	
None	84.6 (22)
Mild gross haematuria	15.4 (4)
Strong gross haematuria	0 (0)
Complications	0 (0)

(±56.0) ml. SPC placement was performed due to obstructive BPH in 38.5% (n = 10) and prostate cancer in 26.9% (n = 7) of the cases. Two patients with obstructive symptoms were suffering from acute prostatitis. Indwelling SPCs were applied due to severe incontinence in 30.7% (n = 8) and neurogenic bladder outlet dysfunction in 3.8% (n = 1) of the cases. Previous abdominal radiotherapy was reported by 15.4% (n = 4) of the patients, while 42.3% (n = 11) had a history of abdominal surgery. In 11.5% (n = 3) of the cases, SPC placement had been performed previously. Aspirin intake was noted in 11.5% (n = 3) of the patients.

The procedures were performed by 15 different physicians, of whom 13 were urologists or residents in urology and two were radiologists. As given in Table 2 the majority (73.3%, n = 11) of the surgeons were residents and 40.0% (n = 6) had less than 1 year work experience or had performed fewer than 10 SPC placements, respectively. Only 26.4% (n = 4) of attending physicians had performed more than 30 SPC placements.

Surgical outcome is shown in Table 3. Mean preparation time in the operation theatre was 10.2 (±3.5) minutes and mean procedure time was 9.4 (±4.7) minutes. There was no significant difference between experienced and inexperienced users (p = 0.32). Almost all cases (88.5%, n = 23) were performed under local anaesthesia. Analgesedation was requested by two patients, whereas general anaesthesia was required in one case due to strong pain during bladder filling. Despite the small bladder capacities, ultrasound guidance was sufficient in 77.0% (n = 20) of the SPC placements. In three cases, fluoroscopy or computed tomography were required respectively due to very limited and unfavourable sonographic conditions. In all cases, the first puncture was successful. There was no catheter displacement or any reported complications. In two cases, the balloon of the transurethral catheter was damaged during the suprapubic puncture. Mild gross haematuria occurred in 15.4% (n = 4) of the cases during the first two hours after SPC placement.

Patients' statement of pain during and 2 hours after surgery yielded mean VAS scores of 2.3 (±1.1) and 0.3 (±0.5) respectively. Concerning the question of how inconvenient the procedure was in comparison to their preoperative expectation, 73.0% (n = 19) of patients claimed that the placement of the SPC was more tolerable or even distinctively more tolerable than anticipated. Figure 2 illustrates the outcome of the survey among the 15 physicians. The majority of physicians felt safe when placing the SPC with Suprapur in the high-risk patients. Even more obvious was the result when physicians were



**Figure 2.** Results of the survey among the operating surgeons: mean value and standard deviation are illustrated for the four different questions.

asked to compare Suprapur® to conventional punch trocar SPC sets. Almost all (93.3%,  $n = 14$ ) claimed to feel safer using Suprapur® in the respective patient. Concerning the level of complexity the results were not as distinct. However, there was still a clear trend towards the statement that Suprapur® was easier to use than conventional sets. The downside was the fact that the procedure was experienced to be more time consuming by the operating physicians.

## DISCUSSION

SPC is a common and frequently performed procedure. It can be applied to treat acute urinary retention when transurethral access is obstructed. Some studies even regard SPC superior to TUC, by reducing the risk of urethral strictures when treating urinary retention due to BPH or performing transurethral resection of the prostate [10, 11]. SPC should

also be given preference over TUC in patients suffering from prostatitis with significant post-voiding residual urine [12]. For indwelling catheterization, for instance in patients with neurogenic bladder outlet dysfunction due to spinal cord injury, SPC has also been proven to be associated with fewer urethral and scrotal complications and urinary infections than TUC [13]. Similar results were found for perioperative bladder drainage [14].

Despite its high acceptance and prevalence, SPC harbours some drawbacks especially in terms of possible complications during its placement. There has been little published regarding the safety of SPC insertion, but it is generally seen as a safe and easy procedure that can be performed under local anaesthesia in the outpatient setting [2]. However, SPC placement carries a not insignificant risk of perioperative complications that often offset their advantages over TUC [13]. These are indeed often minor, such as hae-

maturia or catheter displacement, but may also lead to severe complications such as bowel perforation or even death [6, 7].

Haematuria or SPC exit site bleeding are common problems within the first hours following SPC insertion. In our study, mild haematuria occurred in 15.4% (n = 4) of cases, with no exit site bleeding reported. Although our population contained patients with platelet inhibition due to intake of acetylsalicylic acid, bleeding occurred less commonly than in other studies [15]. Suprapur® allows placement of a SPC by Seldinger's technique. The puncture cannula is notably smaller than in conventional sets (17.5 GA vs. 10 GA). Hence the likelihood of vessel injury is smaller, although guide wire irrigation may lead to vesical mucosa bleeding. Reducing the risk of bleeding is also a concern in respect of an increasing proportion of patients on anticoagulant therapy, such as aspirin [16].

The use of a guide wire in the insertion of a SPC certainly leads to a safer procedure, in terms of catheter misplacement, a technical complication that was not observed in this study. After bladder puncture with trocar cystostomies, urine efflux may result in bladder decompression and possible cannula displacement, which was previously observed in 3% of the cases [5, 6]. A guide wire on the other hand may help to secure the initial access to the bladder.

Our study population presented with risk factors that made SPC insertion more difficult. A high BMI leads to unfavourable conditions for ultrasound guidance due to sound wave scattering in subcutaneous fat [17]. Furthermore, a small bladder capacity, below 300 ml, was shown to significantly increase the rate of complications during SPC insertion [18]. Previous abdominal surgery leads to abdominal wall adhesions in almost 60% of cases and consequently might increase the risk of bowel perforation during SPC placement [19]. In our population the average BMI was 28.8 kg/m<sup>2</sup> and the mean maximum bladder capacity was 210 ml. More than 40% of the patients had previous abdominal surgery. Despite the adverse patient characteristics, we did not observe any complications except for mild gross haematuria. Two larger series on SPC placement under cystoscopic guidance reported a complication rate of more than 10% with around 2.5% blown injuries and a mortality rate of 1.8% respectively 0.8% [6, 7]. Admittedly, we examined fewer cases, but adversely selected patients in terms of risk factors. Since virtually no complications were observed, one may assume that applying Seldinger's technique for SPC placement with the Suprapur® set allows a generally safe procedure. Accordingly, the survey of the operating physicians showed that SPC placement by Seldinger's

technique was largely seen as a safe procedure. It was found to be more convenient and easier to perform than the conventional technique. Most physicians felt more assured with Suprapur® than with a punch trocar cystostomy set. However, using Suprapur was also stated to be more time consuming, which doubtfully carries much weight with respect to operation times of approximately only 10 minutes. SPC placement is often performed in emergency situations and by physicians with less experience. In our study, 40% of the performing surgeons were either 1<sup>st</sup> or 2<sup>nd</sup> year residents. Admittedly, surgery was performed under the supervision of a senior physician, but, nevertheless, even in inexperienced hands, Suprapur® allowed for safe SPC insertion.

Generally, SPC offers high patient satisfaction [6, 7]. In our study, SPC placement was experienced as less inconvenient than initially expected by the majority of the patients. Most cases were performed under local anaesthesia and patients stated very low pain levels during and after the procedure. Since different techniques of SPC placements often require analgesation or general anaesthesia [5, 6, 7], in this regard, Suprapur® permits indulgent SPC insertion. There are several important limitations to our study. First and foremost, our study population is composed of a relatively small number of patients. However, the patients were carefully selected, forming a relevant high-risk population. Furthermore, this study makes no comparison to conventional SCP placement in terms of a randomized controlled trial. The comparison to standard SPC insertion has been conducted by customized questionnaires. Finally, there has been insufficient follow-up with regard to relevant long-term complications. Nevertheless, our work consists of a prospective series with carefully selected patients and constitutes a profound evaluation of the Suprapur® cystostomy set.

## CONCLUSIONS

Placement of SPC is a common procedure in everyday medicine. Insertion of the catheter by Seldinger's technique using the Suprapur cystostomy set allows a safe and convenient procedure without considerable complications, even in high-risk patients and in inexperienced hands. As such, it may be a valuable alternative to conventional sets in selected patients.

## CONFLICTS OF INTEREST

The authors declare no conflicts of interest.

## ACKNOWLEDGMENTS

We are grateful to Uromed (Oststeinbek, Germany) for providing the Suprapur® cystostomy sets.

## References

1. Irby PB 3<sup>rd</sup>, Stoller ML. Percutaneous suprapubic cystostomy. *J Endurol.* 1993; 7: 125-130.
2. Mahmalji W, Masood S. British association of urological surgeons' suprapubic catheter practice guidelines. *BJU Int.* 2011; 107: 1510-1511.
3. Geng V, Cobussen-Boekhorst H, Farrell J, et al. Catheterisation. Indwelling catheters in adults. Urethral and suprapubic. Evidence-based guidelines for best practice in urological health care. Arnhem (The Netherlands): European Association of Urology Nurses (EAUN); 2012.
4. Feifer A, Corcos J. Contemporary role of suprapubic cystostomy in treatment of neuropathic bladder dysfunction in spinal cord injured patients. *Neurourol Urodyn.* 2008; 27: 475-479.
5. Goyal NK, Goel A, Sankhwar SN. Safe percutaneous suprapubic catheterisation. *Ann R Coll Surg Engl.* 2012; 94: 597-600.
6. Ahluwalia RS, Johal N, Kouriefs C, Kooiman G, Montgomery BS, Plail RO. The surgical risk of suprapubic catheter insertion and long-term sequelae. *Ann R Coll Surg Engl.* 2006; 88: 210-213.
7. Sheriff MK, Foley S, McFarlane J, Nauth-Misir R, Craggs M, Shah PJ. Long-term suprapubic catheterisation: clinical outcome and satisfaction survey. *Spinal Cord.* 1998; 36: 171-176.
8. McMullin RI. Suprapubic catheterisation using a guidewire and dilators. *Br J Urol.* 1990; 66: 554.
9. Clavien PA, Barkun J, de Oliveira ML, et al. The Clavien-Dindo classification of surgical complications: five-year experience. *Ann Surg.* 2009; 250: 187-196.
10. Hammarsten J, Lindqvist K. Suprapubic catheter following transurethral resection of the prostate: a way to decrease the number of urethral strictures and improve the outcome of operations. *J Urol.* 1992; 147: 648-651.
11. Horgan AF, Prasad B, Waldron DJ, O'Sullivan DC. Acute urinary retention. Comparison of suprapubic and urethral catheterisation. *Br J Urol.* 1992; 70: 149-151.
12. Grabe M, Bjerklund-Johansen TE, Botto H, et al. Guidelines on urological infections. European Association of Urology 2013.
13. Katsumi HK, Kalisvaart JF, Ronningen LD, Hovey RM. Urethral versus suprapubic catheter: choosing the best bladder management for male spinal cord injury patients with indwelling catheters. *Spinal Cord.* 2010; 48: 325-329.
14. McPhail MJ, Abu-Hilal M, Johnson CD. A meta-analysis comparing suprapubic and transurethral catheterization for bladder drainage after abdominal surgery. *Br J Surg.* 2006; 93: 1038-1044.
15. Hasan AT, Fasihuddin Q, Sheikh MA. Suprapubic cystostomy: urinary tract infection and other short term complications. *J Pak Med Assoc.* 2002; 52: 557-560.
16. Bermüller C, Bender M, Brögger C, Petereit F, Schulz M. Epistaxis and anticoagulation- a medical and economic challenge? *Laryngorhinotologie.* 2014; 93: 249-255.
17. Hinkelman LM, Mast TD, Metlay LA, Waag RC. The effect of abdominal wall morphology on ultrasonic pulse distortion. Part I. Measurements. *J Acoust Soc Am.* 1998; 104: 3635-3649.
18. Albrecht K, Oelke M, Schultheiss D, Tröger HD. The relevance of urinary bladder filling in suprapubic bladder catheterization. *Urologe A.* 2004; 43: 178-184.
19. Levrant SG, Bieber EJ, Barnes RB. Anterior abdominal wall adhesions after laparotomy or laparoscopy. *J Am Assoc Gynecol Laparosc.* 1997; 4: 353-356. ■