




# Use of Exogenous Hyaluronic Acid for the Treatment of Patellar Chondropathy—A Six-Month Randomized Controlled Trial\*

## *Uso do ácido hialurônico exógeno no tratamento da condropatia patelar – Ensaio clínico randomizado com acompanhamento de seis meses*

Diego Costa Astur<sup>1</sup>  Felipe Berteli Angelini<sup>1</sup> Marcelo Abdulchlek Santos<sup>1</sup> Gustavo Gonçalves Arliani<sup>1</sup>  
Paulo Santoro Belangero<sup>1</sup> Moisés Cohen<sup>1</sup>

<sup>1</sup> Knee Group, Sports Traumatology Center, Orthopedics and Traumatology Department, Escola Paulista de Medicina, Universidade Federal de São Paulo, São Paulo, Brazil

Address for correspondence Diego Costa Astur, MD, PhD, Departamento de Ortopedia e Traumatologia da Escola Paulista de Medicina, Universidade Federal de São Paulo, Rua Estado de Israel 636, Vila Clementino, São Paulo, SP, Brasil (e-mail: mcastur@yahoo.com).

Rev Bras Ortop 2019;54:549–555.

### Abstract

**Objective** To evaluate the clinical and radiological benefits of intra-articular exogenous hyaluronic acid for the treatment of chondral patellar injury.

**Method** Randomized clinical trial with 70 patients divided into 2 groups: those submitted to physical therapy for 3 months, and those submitted to physical therapy associated with the intra-articular administration of 2 mL of hyaluronic acid for the same period, who had anterior knee pain and patellar cartilage injury of grades II or III with no significant bone abnormalities. The functional scores and the characteristics of the physical and imaging exams were evaluated before and 3 and 6 months after the treatment.

**Result** The average age of the patients was  $32 \pm 7.6$  years. Patients from the hyaluronic acid group had better Kujala et al and Lysholm scores, and lower pain scores after 3 and 6 months of treatment when compared to the control group. The incidence of positive Clarke maneuver was lower in the treated group, but there was no difference in the magnetic resonance imaging classification.

**Conclusion** Patients with patellar chondropathy of grades II or III treated with hyaluronic acid and physical therapy had less pain (visual analogue scale, VAS), and better functional results in the Lysholm and Kujala et al questionnaires after 3 and 6 months of treatment compared to patients undergoing physical therapy alone. In addition, the number of cases with a negative Clarke maneuver was larger in the treated group after 6 months of treatment.

### Keywords

- ▶ cartilage diseases
- ▶ hyaluronic acid
- ▶ chondrocytes
- ▶ patella

\* Work developed by the Knee Group, Sports Traumatology Center, Orthopedics and Traumatology Department, Escola Paulista de Medicina, Universidade Federal de São Paulo, São Paulo, Brazil.



**Resumo**

**Objetivo** Avaliar os benefícios clínicos e radiológicos do uso do ácido hialurônico exógeno intra-articular para o tratamento da lesão condral da patela.

**Método** Ensaio clínico randomizado com 70 pacientes divididos em dois grupos: o de tratamento fisioterápico por 3 meses, e o de tratamento fisioterápico associado à aplicação de 2 ml de ácido hialurônico intra-articular pelo mesmo período, composto por pacientes com dor na região anterior do joelho e lesão de graus II ou III da cartilagem da patela, sem anormalidades ósseas significativas. Foram avaliados os escores funcionais, e as características do exame físico e de imagem antes, após 3 e 6 meses de tratamento.

**Resultado** A idade média dos pacientes foi de  $32 \pm 7.6$  anos. Os pacientes do grupo submetido a aplicação de ácido hialurônico apresentaram melhores escores de Kujala et al e de Lysholm, e menor pontuação de dor após 3 e 6 meses de tratamento quando comparados ao grupo controle. A manobra de Clarke positiva foi menor no grupo em que foi feita a aplicação do ácido, mas não houve diferença na classificação da imagem obtida pela ressonância magnética.

**Conclusão** Pacientes com condropatia patelar de graus II ou III do joelho tratados com ácido hialurônico e fisioterapia apresentaram menos dor (escala visual analógica, EVA), e melhores resultados funcionais nos questionários de Lysholm e de Kujala et al após 3 e 6 meses de tratamento quando comparados com os pacientes submetidos apenas a fisioterapia. Além disso, estes pacientes apresentaram manobra de Clarke negativa em maior número após 6 meses de tratamento.

**Palavras-chave**

- ▶ doenças das cartilagens
- ▶ ácido hialurônico
- ▶ condrocitos
- ▶ patela

**Introduction**

Patellar cartilage injury is common in athletes, especially females.<sup>1</sup> It usually results from an anomalous bone anatomy between the patella and the femoral trochlea, or an imbalance of the quadriceps musculature that can increase patellofemoral pressure. Abnormal repetition of joint movement leads to adjacent chondral or osteochondral injuries.<sup>2,3</sup>

The most common symptom is anterior knee pain resulting from the inflammatory process generated by the cartilaginous injury. Although physical therapy rehabilitation aids in the rebalancing of the quadriceps muscle, it cannot minimize the localized effects of the chondral injury.<sup>4-7</sup>

Hyaluronic acid (HA) acts by maintaining viscoelasticity, regulating cartilage osmolarity, assisting in extracellular matrix proteoglycans synthesis, and improving the immune and inflammatory response.<sup>8-10</sup> Chronic knee injuries may alter intra-articular HA homeostasis, compromising the favorable evolution of the lesion.<sup>10</sup> The intra-articular administration of exogenous HA helps in impact absorption, joint mobility, analgesia and reduction of the inflammatory process.<sup>11,12</sup> Its use in the treatment of mild knee osteoarthritis has been described in the literature with beneficial results.<sup>8,13-16</sup>

The use of exogenous HA in the treatment of isolated chondral patellar injury has not yet been elucidated. The aim of the present study is to evaluate and compare the symptoms of knee pain and function before and after three and six months of treatment in patients undergoing usual physical therapy alone or associated with exogenous HA administra-

tion. The hypothesis is that the treatment of patellar chondropathy with no subchondral bone involvement may benefit from the intra-articular use of exogenous HA, improving pain and functional knee symptoms.

**Material and Methods**

This is an *interventional study* – a prospective randomized clinical trial that was evaluated and approved by the Ethics in Research Committee of our institution (CEP 1670/2016).

A total of 70 patients with anterior knee pain diagnosed with patellar chondropathy between July 2016 and July 2017 were included in the study. The inclusion criteria were the following: patients aged between 18 and 45 years; who practiced physical activity at least 3 times a week (*soccer, running, workout, volleyball, and basketball*); with anterior knee pain; whose physical examination was suggestive of painful patellar syndrome (Clarke maneuver, and/or Rabet sign);<sup>17</sup> with good knee alignment ( $-1^\circ$  to  $-3^\circ$  of tibiofemoral angulation);<sup>18</sup> with patellar cartilage lesion of grades II or III according to the International Cartilage Repair Society (ICRS) classification;<sup>19</sup> *with lesion size < 2 cm<sup>2</sup>; and who signed the informed consent form.* The exclusion criteria were the following: increased trochlear groove angle; increased patellar deviation; abnormal patellar height;<sup>20</sup> types III and IV patella according to the Wiberg classification;<sup>21</sup> *marked quadriceps hypotrophy*; other associated knee injuries; previous surgery on the same knee; and autoimmune or infectious diseases.

The patients included in the present study underwent radiography, computed tomography (CT), and knee magnetic

resonance imaging (MRI) examinations. The type, height, and weight of the patella were assessed and measured through knee anteroposterior (AP) and profile (P) and axial patella radiographs.<sup>22</sup> The knee alignment was measured from panoramic radiographs of the lower limbs. Patellar deviation was assessed according to the distance between the tibial tuberosity and the trochlear groove sulcus (TT-TG) at the CT (*normal value* < 20 mm).<sup>21</sup> The cartilage lesions were classified per MRI: grade II represents an abnormal lesion involving less than 50% of the thickness of the cartilage, whereas grade III represents severe lesions involving more than 50% of the cartilage, but not affecting the subchondral bone.<sup>19</sup>

The patients were randomly divided into 2 groups by draw with sealed envelopes according to the proposed treatment. The patients in group 1 were submitted to the administration of 2 mL of exogenous, intra-articular HA (Osteonil Plus, TRB Chemedica International, Geneva, Switzerland) in the affected knee, and participated in a rehabilitation protocol for a 12-week period. *This HA is of non-avian origin, has an intermediate molecular weight ( $1-1.8 \times 10^6$  Da), and it is composed of 20 mg of sodium hyaluronate (viscoelastic agent), sodium chloride (ionizing agent), sodium phosphate (buffering agent), mannitol (sequestering agent), and water.* The patients in group 2 underwent only physical therapy for the same period (► **Figure 1**)

The intra-articular HA administration was performed at the time of the inclusion of the patient in the study, and the physical therapy began one week later. The Lysholm,<sup>23</sup> Kujala

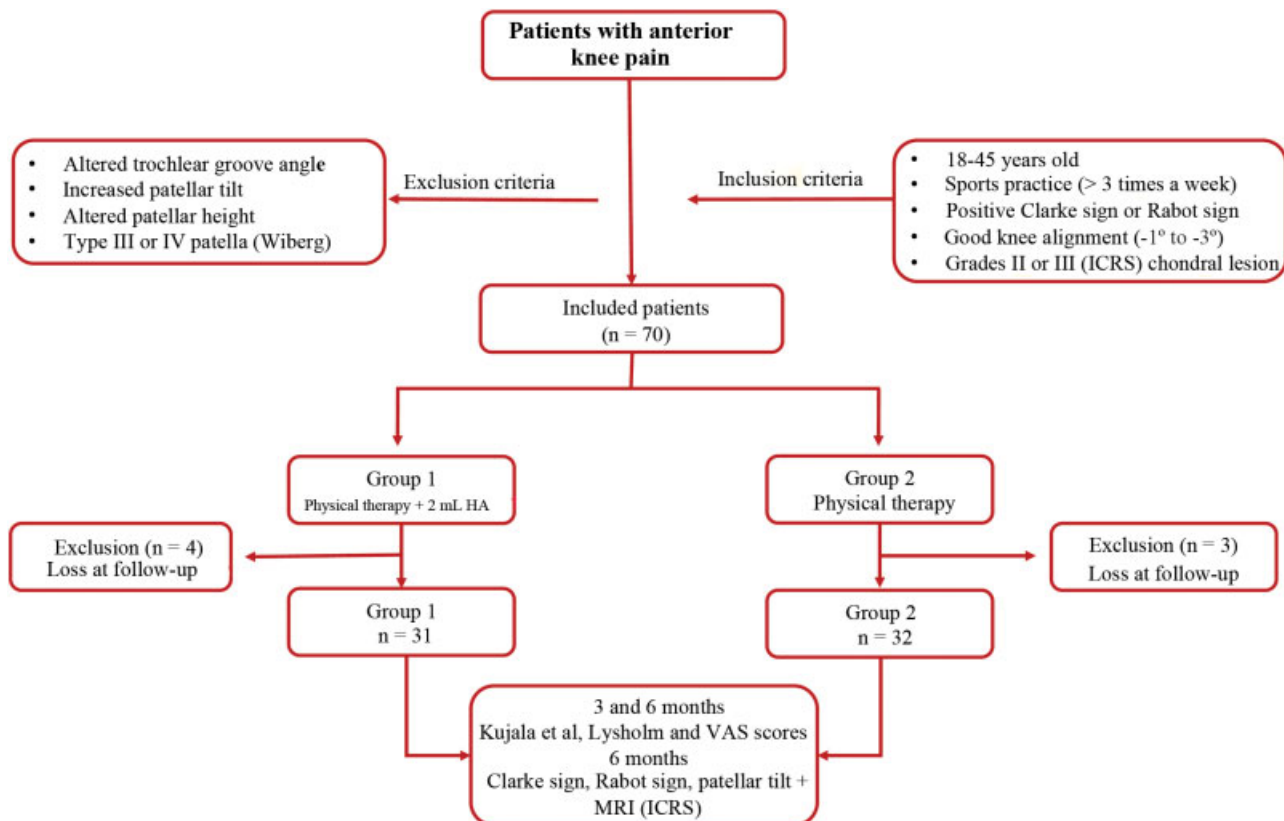
et al,<sup>24</sup> and pain visual analogue scale (VAS) questionnaires were used at the time of the inclusion, and 3 and 6 months after the treatment. In addition, changes found on the physical examination (Clarke maneuver, Rabot sign and apprehension) and on the imaging examination (lesion type at the MRI and patellar tilt at the axial patella radiograph) after six months of the treatment were evaluated. *The professional who administered the HA (DCA) had no contact with the patients during the application of the questionnaires and the physical examination (FBA and MAS).*

#### HA Administration

An anterolateral arthroscopic portal was used for the administration of the anesthetic (3 mL of lidocaine without vasoconstrictor) followed by the HA (2 mL of Osteonil Plus). The knee was hanging from the stretcher, positioned at 90 degrees of flexion. The patients were allowed to walk without restrictions, and were only told to avoid physical activity for 48 hours. They were also advised of the possible complications, such as pain and local edema after the administration.

#### Rehabilitation

Stretching and strengthening exercises, mainly of the quadriceps medial muscles and external hip rotators, were performed. In addition, proprioception was stimulated, including isometric, concentric and eccentric exercises of these same muscle groups. The rehabilitation protocol was maintained during the first three months of the treatment.



**Fig. 1** Flowchart of patient inclusion. Characteristics of the evaluated patients and comparison according to the therapeutic outcomes. Abbreviations: ICRS, International Cartilage Repair Society; MRI, magnetic resonance imaging.

### Statistical Analysis

The baseline personal, clinical and radiological characteristics were described using summary measures (mean, standard deviation, median, minimum and maximum values) for the quantitative variables, and absolute and relative frequencies for the qualitative variables. The Mann-Whitney test was used to evaluate the radiographic characteristics and the Kujala et al, Lysholm and VAS scores between the groups. The Chi-squared test was used to compare the results of the maneuvers of the physical examination, the MRI image classification, and the presence of patellar tilt between the groups. The tests were performed with a 5% significance level and a 95% confidence interval (95%CI). The sample was calculated to achieve a power of 80%.

### Results

The average age of the patients who completed the study was  $32 \pm 7.6$  years (range: 18 to 45 years). A total of seven patients either failed to follow the treatment or were lost at follow-up. There was no significant difference between the groups regarding age, gender, affected side, and *lesion location* ( $p > 0.05$ ). Patient characteristics are shown in ► **Table 1**.

There was a significant improvement in pain (VAS), and in the Lysholm and Kujala et al scores when comparing the baseline values and those obtained three and six months after the treatment for both groups ( $p < 0.05$ ). There was also

a decrease in pain and a significant increase in the Lysholm and Kujala et al scores among patients submitted to HA administration when compared to the control group after 3 and 6 months of the treatment ( $p < 0.05$ ) (► **Table 2**).

After six months of the treatment, the number of patients with positive Clarke maneuver was significantly lower in the HA group ( $p = 0.02$ ). There was no difference between the groups for the occurrence of the *Rabot* sign, as well as for patellar tilt at the Merchant radiographic view after this period ( $p > 0.05$ ). There was no difference between the groups for the type of lesion observed on the MRI according to the ICRS classification (► **Table 3**).

### Discussion

The treatment of grades II and III patellar chondral lesion with exogenous, intra-articular HA associated with physical therapy rehabilitation showed better results for knee pain and function when compared with physical therapy alone after three and six months of the diagnosis. While physical therapy helps correct the abnormal position of the patella during joint movement, stimulating the quadriceps muscles and external hip rotators, the medication assists in the rearrangement of the environment homeostasis of the joint, favoring a decrease in the local inflammatory process and better patellar cartilage absorption and mobility near the femur.<sup>25</sup>

**Table 1** Patient data<sup>a</sup>

	Group 1 (n = 31)	Group 2 (n = 32)	p-value
Age, mean $\pm$ standard deviation (minimum-maximum)	30.8 $\pm$ 5.9 (18-45)	33.2 $\pm$ 7.15 (18-45)	0.22
Gender, n (%)			
Female	15 (48.4)	17 (53.1)	0.72
Male	16 (51.6)	15 (46.9)	
Side, n (%)			
Right	16 (51.6)	16 (50)	0.89
Left	15 (48.4)	16 (50)	
Trochlear groove angle ( $^{\circ}$ ), mean $\pm$ standard deviation (minimum-maximum)	132.1 $\pm$ 7.5 (119-147)	131 $\pm$ 9.5 (110-147)	0.77
Patellar height (Caton-Deschamps), mean $\pm$ standard deviation (minimum-maximum)	1.09 $\pm$ 0.12 (0.9-1.2)	1.08 $\pm$ 0.12 (0.9-1.2)	0.72
Patellar type (Wiberg), n (%)			
I	4 (12.9)	8 (25)	0.18
II	27 (87.1)	24 (75)	
Alignment, mean $\pm$ standard deviation	0.34 $\pm$ 0.12	1.2 $\pm$ 0.08	0.22
TT-TG, mean $\pm$ standard deviation (minimum-maximum)	15.8 $\pm$ 2.2 (12-19)	15.4 $\pm$ 2.3 (12-19)	0.5
Lesion location, n (%)			
Lateral aspect	16 (51.6)	16 (50)	0.89
Medial aspect	15 (48.4)	16 (50)	

Abbreviation: TT-TG, distance between the tibial tuberosity and the trochlear groove sulcus.

Notes: <sup>a</sup>Values presented as n (%) or mean  $\pm$  standard deviation; <sup>†</sup>Mann-Whitney test; <sup>‡</sup>Chi-squared test.

**Table 2** Kujala et al, Lysholm and VAS scores<sup>a</sup>

	Group 1 (n = 31)	Group 2 (n = 32)	p-value
Kujala et al			
Baseline	66.5 ± 19 (23-94)	64.3 ± 15.3 (25-90)	0.43
3 months	79.3 ± 13 (42-100)	69.2 ± 11.5 (40-90)	<b>0.001</b>
6 months	79.7 ± 15 (43-100)	71.3 ± 10.8 (50-91)	<b>0.01</b>
Lysholm			
Baseline	72.6 ± 18.1 (25-90)	70.8 ± 17.9 (30-92)	0.75
3 months	82.6 ± 14.7 (36-100)	74.3 ± 15.3 (43-93)	<b>0.02</b>
6 months	81.5 ± 16.7 (41-100)	75.9 ± 12.7 (47-95)	<b>0.02</b>
VAS			
Baseline	5.3 ± 2.1 (2-9)	5.9 ± 1.8 (2-8)	0.31
3 months	2.8 ± 2.3 (0-7)	3.8 ± 1.3 (2-6)	<b>0.02</b>
6 months	2.7 ± 2.1 (0-8)	3.5 ± 0.9 (2-6)	<b>0.01</b>

Abbreviation: VAS, visual analogue scale.

Notes: <sup>a</sup>Values presented as n (%) or mean ± standard deviation; Mann-Whitney test; Chi-squared test.

Wobig et al<sup>15</sup> evaluated the effects of HA administration among 110 patients with knee osteoarthritis, noting a considerable improvement in pain and daily activities between 10 and 24 weeks.<sup>15</sup> Assessing only patients with patellofemoral joint osteoarthritis (PFOA), Clarke observed an improvement in pain 4 to 26 weeks after an intra-articular HA administration. However, 18.6% of the cases presented some type of adverse reaction.<sup>26</sup> Fosco and Dagher<sup>27</sup> also evaluated patients with PFOA, observing an improvement in pain (VAS) and Kujala et al scores in 28 knees submitted to lateral patellar release associated with knee viscosupplementation with HA. A systematic

review involving 44 studies with PFOA patients also found favorable results for short-term pain control with the intra-articular administration of HA.<sup>28</sup>

However, few studies have evaluated the effects of this treatment on isolated patellar cartilage lesions, such as patellar chondropathy.<sup>16,29</sup> The goal of the association of the usual physical therapy with intra-articular HA administration was to protect and restore the homeostatic balance at an established patellar injury, not necessarily expecting lesion remission, but assisting in symptom remission.<sup>27</sup> Bellamy et al<sup>16</sup> concluded, in a systematic review involving

**Table 3** Clarke test, Rabot sign, patellar tilt and ICRS classification of chondral lesions

	Before the treatment			6 months of treatment		
	Group 1	Group 2	p-value	Group 1	Group 2	p-value
Clarke test, n (%)						
Negative	2 (6.5)	3 (9.3)	0.66	19 (61.3)	10 (31.3)	<b>0.02</b>
Positive	29 (93.5)	29 (90.7)		12 (38.7)	22 (68.7)	
Rabot sign, n (%)						
Negative	7 (22.6)	12 (37.5)	0.16	22 (71)	17 (53.1)	0.14
Positive	24 (77.4)	19 (62.5)		9 (29)	15 (46.9)	
Tilt (axial patella), n (%)						
Negative	0 (0)	0 (0)		18 (58.1)	20 (62.5)	0.7
Positive	31 (100)	32 (100)		13 (41.9)	12 (31.5)	
ICRS classification (MRI)						
I	0 (0)	0 (0)	0.68	2 (6.5)	2 (6.2)	0.53
II	12 (38.7)	14 (43.8)		10 (32.3)	14 (43.8)	
III	19 (61.3)	18 (56.2)		17 (54.7)	12 (37.5)	
IV	0 (0)	0 (0)		2 (6.5)	4 (12.5)	

Abbreviations: ICRS, International Cartilage Repair Society; MRI, magnetic resonance imaging.

Notes: <sup>a</sup>Values presented as n (%); <sup>†</sup>Chi-squared test.



76 studies, that the beneficial effects on pain (24-54%) and function (9-32%) improvement of the knee treated with viscosupplementation occurred on average after 5 to 13 weeks, with durability superior to that of the steroid treatment. Comparing with the results obtained in our study, we conclude that, in many cases, the effect of the medication occurs in a period longer than the one evaluated. Wenz et al<sup>29</sup> evaluated the effect of HA in patellar chondropathy in dogs, noting a decrease in the degenerative process of the cartilage.

In addition, it is known that the physical examination of patellar chondropathy is very sensitive, but not very specific.<sup>30</sup> In the present study, the relationship between Clarke maneuver positivity, apprehension, and Rabot sign before and after six months of the treatment was evaluated. There was no difference between groups regarding Rabot sign and apprehension ( $p > 0.05$ ). However, the difference in the positivity of the Clarke test before and after the treatment was significant ( $p = 0.02$ ). Considering the anti-inflammatory and lubricating effect of intra-articular HA, we can infer that this medication reduced pain.

The healing capacity of the injured cartilage is known to be limited.<sup>30</sup> Poor vascularization associated with poor chondrocyte adhesion minimizes the chance that an already consolidated lesion will be fully healed. The purpose of HA administration is not to promote healing, but to improve the conditions for cell differentiation and to control the local inflammatory process. Nevertheless, the present study compared the imaging characteristics of the lesion at the MRI before and after six months of treatment in both groups. There was no difference in the degree of the injury before and after the treatment in patients from both groups, as well as no difference after the treatment between the groups ( $p > 0.05$ ). However, Magarelli et al<sup>31</sup> observed an improvement in the aspect of the lesion at the MRI after three and six months of the treatment. Regardless of the appearance of the lesion on the imaging examination, it is known that its clinical improvement is not necessarily proportional to an improvement observed at the MRI.

Finally, it is worth mentioning the limitations of the present study: its short follow-up period, of only six months after the inclusion. However, we consider it the most appropriate period, because, in the clinical practice, the patient usually completes the entire rehabilitation protocol and return to physical activity in a shorter period of time. However, in only six months of follow-up, the results were quite satisfactory in order to evaluate the improvement of the symptoms, which encouraged the authors to divulge the results obtained. The evaluation of the image of the cartilage at the MRI was performed only at six months, which is known to be a short period to observe changes. *The control group was treated with physical therapy alone, and saline solution (placebo) was not administered to minimize the bias of the product administration. In addition, the study evaluated the effects of only one commercial intra-articular HA product. We encourage further studies with other available brands, or studies comparing the benefits of each one.* Lastly, this is a complex pathology with many possible different changes among patients with the

same symptoms. We tried to homogenize the evaluated sample as much as possible.

## Conclusion

When compared to patients undergoing physical therapy alone, patients with grades II or III patellar chondropathy of the knee treated with HA and physical therapy showed improvement in pain and functional scores according the Lysholm and Kujala questionnaires after 3 and 6 months of treatment. In addition, when the HA was administered, the Clarke maneuver was negative for a larger number of patients after 6 months of treatment.

## Conflicts of Interest

The authors have none to declare.

## Acknowledgments

The authors would like to thank TRB Pharma for donating the hyaluronic acid vials (Osteonil Plus) for the study; there was no intervention or influence on the results obtained on the part of the aforementioned company.

## References

- Heintjes E, Berger M, Bierma-Zeinstra S, Bernsen R, Verhaar J, Koes B. Exercise therapy for patellofemoral pain syndrome. Hoboken, NJ: John Wiley & Sons; 2005
- Collins NJ, Bierma-Zeinstra SM, Crossley KM, van Linschoten RL, Vicenzino B, van Middelkoop M. Prognostic factors for patellofemoral pain: a multicentre observational analysis. *Br J Sports Med* 2013;47(04):227-233
- Lankhorst NE, van Middelkoop M, Crossley KM, et al. Factors that predict a poor outcome 5-8 years after the diagnosis of patellofemoral pain: a multicentre observational analysis. *Br J Sports Med* 2016;50(14):881-886
- Loudon JK, Gajewski B, Goist-Foley HL, Loudon KL. The effectiveness of exercise in treating patellofemoral-pain syndrome. *J Sport Rehabil* 2004;13:323-342
- Irrgang JJ, Anderson AF, Boland AL, et al. Development and validation of the international knee documentation committee subjective knee form. *Am J Sports Med* 2001;29(05):600-613
- Coppack RJ, Etherington J, Wills AK. The effects of exercise for the prevention of overuse anterior knee pain: a randomized controlled trial. *Am J Sports Med* 2011;39(05):940-948
- Barton CJ, Lack S, Hemmings S, Tufail S, Morrissey D. The 'Best Practice Guide to Conservative Management of Patellofemoral Pain': incorporating level 1 evidence with expert clinical reasoning. *Br J Sports Med* 2015;49(14):923-934
- Plánka L, Starý D, Srnec R, Necas A, Gál P. [New options for management of posttraumatic articular cartilage defects]. *Rozhl Chir* 2008;87(01):42-45
- Richette P, Chevalier X, Ea HK, et al. Hyaluronan for knee osteoarthritis: an updated meta-analysis of trials with low risk of bias. *RMD Open* 2015;1(01):e000071
- Mathieu P, Conrozier T, Vignon E, Rozand Y, Rinaudo M. Rheologic behavior of osteoarthritic synovial fluid after addition of hyaluronic acid: a pilot study. *Clin Orthop Relat Res* 2009;467(11):3002-3009
- van der Heijden RA, Lankhorst NE, van Linschoten R, Bierma-Zeinstra SM, van Middelkoop M. Exercise for treating patellofemoral pain syndrome. *Cochrane Database Syst Rev* 2015;1: CD010387

- 12 Lisignoli G, Grassi F, Zini N, et al. Anti-Fas-induced apoptosis in chondrocytes reduced by hyaluronan: evidence for CD44 and CD54 (intercellular adhesion molecule 1) involvement. *Arthritis Rheum* 2001;44(08):1800–1807
- 13 McAlindon TE, Bannuru RR, Sullivan MC, et al. OARSI guidelines for the non-surgical management of knee osteoarthritis. *Osteoarthritis Cartilage* 2014;22(03):363–388
- 14 Kim SE, Lee JY, Shim KS, et al. Attenuation of inflammation and cartilage degradation by sulfasalazine-containing hyaluronic acid on osteoarthritis rat model. *Int J Biol Macromol* 2018; 114:341–348
- 15 Wobig M, Dickhut A, Maier R, Vetter G. Viscosupplementation with hylan G-F 20: a 26-week controlled trial of efficacy and safety in the osteoarthritic knee. *Clin Ther* 1998;20(03): 410–423
- 16 Bellamy N, Campbell J, Robinson V, Gee T, Bourne R, Wells G. Viscosupplementation for the treatment of osteoarthritis of the knee. *Cochrane Database Syst Rev* 2006;(02):CD005321
- 17 Doberstein ST, Romeyn RL, Reineke DM. The diagnostic value of the Clarke sign in assessing chondromalacia patella. *J Athl Train* 2008;43(02):190–196
- 18 Nakayama H, Iseki T, Kanto R, et al. Physiologic knee joint alignment and orientation can be restored by the minimally invasive double level osteotomy for osteoarthritic knees with severe varus deformity. *Knee Surg Sports Traumatol Arthrosc* 2018;•••. Doi: 10.1007/s00167-018-5103-3
- 19 International Cartilage Repair Society Clinical Cartilage Injury Evaluation System. Available from: [www.cartilage.org/society/publications/icrs-score](http://www.cartilage.org/society/publications/icrs-score)
- 20 Gracitelli GC, Pierami R, Tonelli TA, et al. Assessment of patellar height measurement methods from digital radiography. *Rev Bras Ortop* 2015;47(02):210–213
- 21 Schueda MA, Astur DC, Bier RS, Bier DS, Astur N, Cohen M. Use of computed tomography to determine the risk of patellar dislocation in 921 patients with patellar instability. *Open Access J Sports Med* 2015;6:55–62
- 22 Bhattacharya R, Kumar V, Safawi E, Finn P, Hui AC. The knee skyline radiograph: its usefulness in the diagnosis of patellofemoral osteoarthritis. *Int Orthop* 2007;31(02):247–252
- 23 E Albuquerque RP, Giordano V, Calixto A, et al. Analysis on the modified lysholm functional protocol among patients with normal knees. *Rev Bras Ortop* 2015;46(06):668–674
- 24 Kujala UM, Jaakkola LH, Koskinen SK, Taimela S, Hurme M, Nelimarkka O. Scoring of patellofemoral disorders. *Arthroscopy* 1993;9(02):159–163
- 25 He WW, Kuang MJ, Zhao J, et al. Efficacy and safety of intraarticular hyaluronic acid and corticosteroid for knee osteoarthritis: A meta-analysis. *Int J Surg* 2017;39:95–103
- 26 Clarke S, Lock V, Duddy J, Sharif M, Newman JH, Kirwan JR. Intra-articular hylan G-F 20 (Synvisc) in the management of patellofemoral osteoarthritis of the knee (POAK). *Knee* 2005;12(01):57–62
- 27 Fosco M, Dagher E. Proposal of a therapeutic protocol for selected patients with patellofemoral knee osteoarthritis: arthroscopic lateral retinacular release followed by viscosupplementation. *Musculoskelet Surg* 2016;100(03):171–178
- 28 van Jonbergen HP, Poolman RW, van Kampen A. Isolated patellofemoral osteoarthritis. *Acta Orthop* 2010;81(02):199–205
- 29 Wenz W, Graf J, Brocai DR, et al. [Effectiveness of intra-articular application of hyaluronic acid on early forms of femoropatellar arthrosis—an experimental study in dogs]. *Z Orthop Ihre Grenzgeb* 1998;136(04):298–303
- 30 Kon E, Filardo G, Gobbi A, et al. Long-term Results After Hyaluronan-based MACT for the Treatment of Cartilage Lesions of the Patellofemoral Joint. *Am J Sports Med* 2016;44(03):602–608
- 31 Magarelli N, Palmieri D, Ottaviano L, et al. Evaluation of magnetic resonance signal modification induced by hyaluronic acid therapy in chondromalacia patellae: a preliminary study. *J Biol Regul Homeost Agents* 2008;22(04):247–252