








# Degenerative Cervical Myelopathy: Development and Natural History [AO Spine RECODE-DCM Research Priority Number 2]

Aria Nouri, MD, MSc<sup>1</sup> , Enrico Tessitore, MD<sup>1</sup>, Granit Molliqaj, MD<sup>1</sup>, Torstein Meling, MD, PhD<sup>1</sup>, Karl Schaller, MD<sup>1</sup>, Hiroaki Nakashima, MD, PhD<sup>2</sup> , Yasutsugu Yukawa, MD, PhD<sup>3</sup>, Josef Bednarik, MD, PhD<sup>4</sup>, Allan R. Martin, MD, PhD<sup>5</sup>, Peter Vajkoczy, MD<sup>6</sup>, Joseph S. Cheng, MD, MS<sup>7</sup>, Brian K. Kwon, MD, PhD<sup>8</sup>, Shekar N. Kurpad, MD, PhD<sup>9</sup>, Michael G. Fehlings, MD, PhD<sup>10</sup> , James S. Harrop, MD, MSHQS<sup>11</sup>, Bizhan Aarabi, MD<sup>12</sup>, Vafa Rahimi-Movaghar, MD<sup>13</sup>, James D. Guest, MD, PhD<sup>14</sup>, Benjamin M. Davies, MRCS, BSc, MPhil<sup>15,16</sup> , Mark R. N. Kotter, MD, MPhil, PhD<sup>15,16</sup>, and Jefferson R. Wilson, MD, PhD<sup>10</sup> 

## Abstract

**Study Design:** Narrative review.

**Objectives:** To discuss the current understanding of the natural history of degenerative cervical myelopathy (DCM).

**Methods:** Literature review summarizing current evidence pertaining to the natural history and risk factors of DCM.

**Results:** DCM is a common condition in which progressive arthritic disease of the cervical spine leads to spinal cord compression resulting in a constellation of neurological symptoms, in particular upper extremity dysfunction and gait impairment. Anatomical factors including cord-canal mismatch, congenitally fused vertebrae and genetic factors may increase individuals' risk for DCM development. Non-myelopathic spinal cord compression (NMSCC) is a common phenomenon with a prevalence of 24.2% in the healthy population, and 35.3% among individuals >60 years of age. Clinical radiculopathy and/or electrophysiological signs of cervical cord dysfunction appear to be risk factors for myelopathy development. Radiological progression of incidental Ossification of the Posterior Longitudinal Ligament (OPLL) is estimated at 18.3% over 81-months and development of myelopathy ranges between 0-61.5% (follow-up ranging from 40 to 124 months between studies) among studies. In patients with symptomatic DCM undergoing non-operative treatment, 20-62% will experience neurological deterioration within 3-6 years.

<sup>1</sup> Division of Neurosurgery, Geneva University Hospitals, University of Geneva, Geneva, Switzerland

<sup>2</sup> Department of Orthopedic Surgery, Nagoya University Graduate School of Medicine, Nagoya, Japan

<sup>3</sup> Department of Orthopedic Surgery, Wakayama Medical University, Wakayama, Japan

<sup>4</sup> Department of Neurology, University Hospital Brno and Faculty of Medicine, Masaryk University, Brno, Czech Republic

<sup>5</sup> Department of Neurosurgery, University of California Davis, Sacramento, CA, USA

<sup>6</sup> Department of Neurosurgery, Charité Universitätsmedizin, Berlin, Germany

<sup>7</sup> Department of Neurosurgery, University of Cincinnati, Cincinnati, OH, USA

<sup>8</sup> Vancouver Spine Surgery Institute, Department of Orthopedics, The University of British Columbia, Vancouver, British Columbia, Canada

<sup>9</sup> Department of Neurosurgery, Medical College of Wisconsin, Wauwatosa, WI, USA

<sup>10</sup> Division of Neurosurgery and Spine Program, University of Toronto, Ontario, Canada

<sup>11</sup> Department of Neurological Surgery, Thomas Jefferson University, Philadelphia, PA, USA

<sup>12</sup> Department of Neurosurgery, University of Maryland, Baltimore, MD, USA

<sup>13</sup> Department of Neurosurgery, Sina Trauma and Surgery Research Center, Tehran University of Medical Sciences, Tehran, Iran

<sup>14</sup> Department of Neurosurgery and The Miami Project to Cure Paralysis, The Miller School of Medicine, University of Miami, FL, USA

<sup>15</sup> Department of Neurosciences, University of Cambridge, Cambridge, United Kingdom

<sup>16</sup> Myelopathy.org, International Charity for Degenerative Cervical Myelopathy, United Kingdom

## Corresponding Author:

Aria Nouri, Division of Neurosurgery, Geneva University Hospitals, University of Geneva, Geneva, Switzerland.  
Email: arianouri9@gmail.com



**Conclusion:** Current estimates surrounding the natural history of DCM, particularly those individuals with mild or minimal impairment, lack precision. Clear predictors of clinical deterioration for those treated with non-operative care are yet to be identified. Future studies are needed on this topic to help improve treatment counseling and clinical prognostication.

### Keywords

cervical spondylotic myelopathy (CSM), cord compression, ossification of the posterior longitudinal ligament (OPLL), progression, risk factors

## Introduction

Degenerative Cervical Myelopathy (DCM) occurs when progressive arthritic/spondylotic changes narrow the cervical spinal canal, leading to spinal cord compression and progressive spinal cord impairment.<sup>1-3</sup> The clinical manifestations of this disease exist on a spectrum of severity; while severely affected patients may be unable to walk or use their hands, mildly affected patients may experience only minor symptoms and have a good quality of life. Understanding of the rate at which patients move along this continuum without operative treatment—the so-called natural history of DCM—remains limited.

Knowledge regarding prognosis for progression is vital in the context of DCM since the goal of operative intervention is to arrest symptomatic progression and functional decline. In evaluating whether to perform surgery on a DCM patient with relatively mild symptoms, the risks of cervical spine surgery are justified if that individual is at high-risk for deterioration if managed non-operatively. Conversely, if the risks of deterioration are low, it makes sense to avoid upfront surgery and closely follow the patient. Therefore, our knowledge surrounding natural history and prognosis is essential for DCM-related treatment decision making.

Apart from patients with symptomatic myelopathy, another critical question relates to the prognosis of individuals with cervical spinal cord compression but without myelopathy or with minimal impairment. In such individuals—who are increasingly recognized due to the ubiquity of neuroimaging—it is important to understand the risk of myelopathy development, or potentially catastrophic spinal cord injury, for purposes of patient counseling and treatment planning. The lack of clear clinical guidance in this regard was highlighted in a series of systematic review and practice guidelines on DCM published in 2017.<sup>4</sup>

Here, we provide an overview of topics pertaining to the natural history of DCM to inform prognosis and decision-making. We have summarized the existing evidence and highlighted key knowledge gaps and important opportunities for research. Wherever possible, we focus discussions on more recent and higher quality (prospective) studies. A summary of key natural history studies is highlighted in Table 1.

### Natural History of the Cervical Degenerative Process

As with all osteoarthritic disease, cervical spine related degeneration is principally a function of use-intensity, genetics,

environmental/lifestyle factors and time.<sup>1,26</sup> This process begins at the intervertebral disc (IVD), wherein decreased compliance occurs secondary to a reduction of nucleus pulposus hydration and fibrous transformation. The early phase of this transformation, highlighted by intranuclear cleft formation, a precursor to future more extensive degenerative disease, is seen frequently in young asymptomatic individuals as early as the third decade.<sup>26-30</sup> In addition to fibrous transformation, the height of the IVD progressively decreases, often in asymmetric fashion, leading to an unequal distribution of forces across the endplates, ultimately resulting in remodeling of the vertebral bones.<sup>31</sup> This remodeling takes the form of increased anteroposterior length and decreased vertebral height, osteophyte/bone spur formation, and in certain circumstances can lead to disc herniation into the vertebrae (Schmorl's node) and adjacent vertebral autofusion.<sup>27</sup> These disc related degenerative changes can have a number of downstream consequences contributing to eventual myelopathy: 1) ligamentous changes including in-folding of the ligamentum flavum, reactional hypertrophy, calcification, and ossification of the posterior longitudinal ligament and ligamentum flavum; 2) cervical alignment changes, including development of kyphosis, scoliosis, hyperlordosis or listhesis, and; 3) reduction in cervical canal size, with progressive decrease in the space available for the spinal cord,<sup>27,31,32</sup> Figure 1. In addition, it has also been recently shown that aberrations in the paraspinal muscle morphology, including fatty infiltration, presents as part of the degenerative process.<sup>33</sup>

While most individuals will develop some degree of degenerative change within the cervical spine with increased age, most experience few symptoms. However, in a limited proportion of the general population, severe forms of the aforementioned changes can result in spinal cord compression and myelopathy development. Another group may experience significant degenerative changes at a localized level, such as a single disc, with otherwise global preservation of cervical anatomy.

### Risk Factors for Cervical Spine Degeneration and DCM Development

Given that the development of degenerative disc disease is an age-dependent process, the principle risk factor for DCM development is age, with an average age of onset in the largest cohorts is typically approximating the mid 50s to 60s years of age.<sup>35-37</sup> In addition, males seem to be relatively overrepresented in many

**Table 1.** Summary Table of Natural History Studies. Adapted and Modified From Karadimas, Erwin<sup>87</sup> and Tetreault, Karadimas.<sup>5</sup>

Authors & study design	Demographics	Follow-up, mean (%)	Inclusion criteria	Outcome measure	Prognostic factors noted (Significant factors)	Natural history estimate
Barnes and Saunders <sup>6</sup> Retrospective cohort	N = 76 Mean age = 65yr Male = 71%	8.2 yr (59%)	1. Myelopathy with evidence of corticospinal tract dysfunction in the legs with or without sensory involvement or radiculopathy 2. Plain radiological changes of cervical spondylosis 3. Myelographic evidence of a complete or partial block to the flow of contrast medium in the cervical spine 4. No other reasonable diagnosis that had manifested itself on follow-up examination	Change in Nurick grade Better, same or worse Nurick grade	Patients that deteriorated: - Were more often women (P = .01) - Range of neck movement is greater (P < .05) - Range of head movement is also higher (P < .01). - Had greater range of head and neck motion (P < .01)	At follow-up (n = 45): - 13.3% of patients deteriorated - 66.67% of patients same - 20.0% of patients improved Of note, 10 deaths at study follow-up with 1 patient death attributed to CSM.
Bednarik et al <sup>7</sup> Kadanka <sup>8-11</sup> RCT	N = 33 Mean Age = 54 yr Male = 74%	2 yr (NR) 3 yr (90%) 10 yr (78%)	1. Clinical signs and symptoms of cervical cord dysfunction 2. MRI criteria for cervical mono- and multisegmental cord compression and/or myelopathy due to spondylosis (including soft disc herniations) with or without developmentally narrow spinal canal 3. Age < 75 yr 4. mJOA score > 12 5. Patient's consent to surgery	Change in mJOA score Subjective patients own evaluation 10m walk test Score of daily activities Electrophysiology	Deterioration or non-response to conservative treatment at 3-years (P < .05): - Younger age - Lower Torq-Pavlov ratio - higher mJOA - taller height - longer CMCT (abductor digiti quinti)	Follow-up at (based on mJOA): 1-year 15.1% deteriorated 2-year 34.5% deteriorated 3-year 26.7% deteriorated Subjective deterioration: 10-year: 56% vs 45.5%(surgical) Of note, 17 deaths at 10-years with no death attributed to CSM.
Lees and Turner <sup>12</sup> Prospective cohort	N = 44 Mean age = NR (Range, 21-80 yr) Male = 68%	5 yr (100%)	1. Radiological and myelographic evidence of cervical spondylosis with signs of cord damage 2. Extensor plantar responses 3. All patients with other neurological diseases such as disseminated sclerosis, even if spondylosis was also present, were excluded	No scale used	Not assessed	14.3% (4/28) with collar treatment worsened and 3/4 were eventually operated (conversion to surgery 10.7%) Of note, 10 deaths during study period with 2 deaths attributed to CSM.
Matsumoto et al <sup>3,14</sup> Retrospective cohort	N = 52, N = 27 Mean age = 55 yr Male = 75%	3 yr (NR) 4 yr (NR)	1. Diagnosed to have cervical compressive myelopathy based on both neurological examination and MRI findings showing spinal cord compression 2. Mild paresis 3. JOA ≥ 10	JOA MRI factors	No MRI factors predicted outcome	Follow-up at (based on JOA): 3-year 31% deteriorated 4-year 37% deteriorated
Nakamura et al <sup>15</sup> Retrospective cohort	N = 64 Mean age = 52 yr (Range, 32-73) Male = 72%	6 yr (83%)	Motor function disability in the upper or lower extremity or in both (Based on the motor function evaluation of the JOA)	Motor JOA	Assessed, but no significant factors associated with worsening	Follow-up at 6 years -3% Deterioration of Lower limb motor function

(continued)

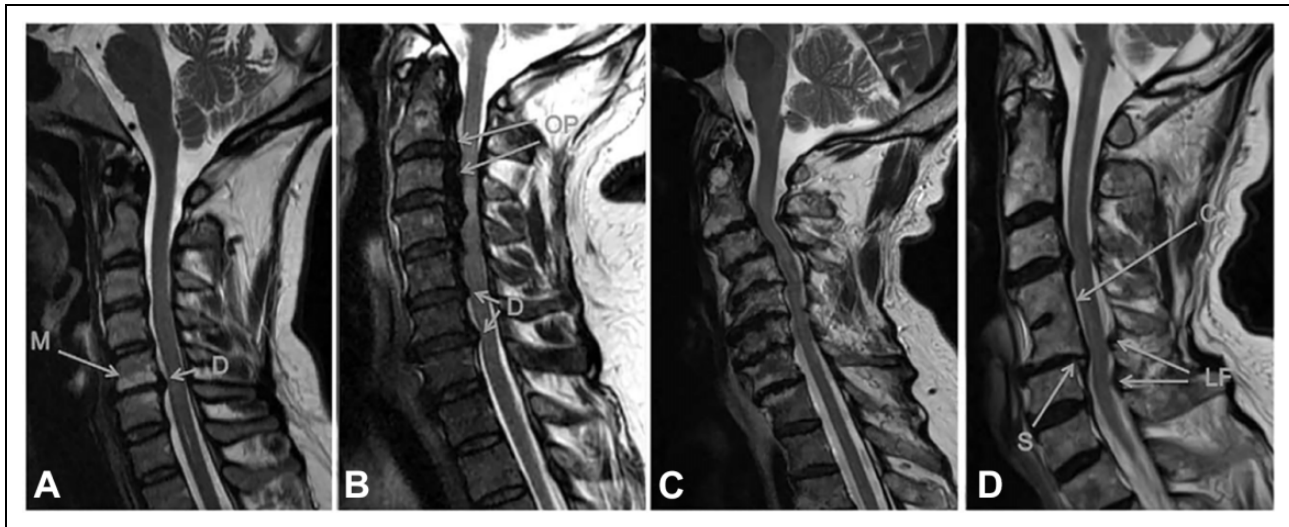
Table 1. (continued)

Authors & study design	Demographics	Follow-up, mean (%)	Inclusion criteria	Outcome measure	Prognostic factors noted (Significant factors)	Natural history estimate
Oshima et al <sup>16</sup> Retrospective cohort	N = 45 Mean age = 59 yr (Range, 35-76) Male = 60% ** N = 24	6.5 yr (82%)	1. Motor function JOA scores of $\geq 3$ in both upper and lower extremities 2. Cervical spinal cord compression with ISI on T2-weighted MRI	Motor JOA	More likely to undergo surgery - Local Slip OR 4.7 (1.67-13.0) - Segmental lordotic angle $<0^\circ$ OR 4.5 (1.59-12.8)	Follow-up at 6.5 years -40% Deterioration of motor function
Roberts <sup>17</sup> Retrospective cohort	Mean age = 54.2 yr (Range, 41-69) Male = 75%	3 yr (86%)	1. Myelography diagnosis 2. Immobilization of the neck in a plastic or metal frame collar preceded by 2- to 3-wk bed rest in hospital	Motor disability: 1 = moderate inconvenience in normal daily activity 2 = activities severely limited but able to get about alone 3 = inability to get about without help 4 = bed- or chair-bound. Number of symptoms Patient satisfaction Pain severity Activities of daily living	-No patient without improvement within 5 months of starting treatment improved with continued collar immobilization.	33% (n = 8) worsened, 37.5% unchanged, 29.2% (n = 7) improved based on motor disability grading.
Sampath et al <sup>18</sup> Prospective cohort	N = 31* Mean age = 48.7 yr (Range, 21-75) Male = 48%	1 yr (74%)*	1. Consultation sought for treatment, not second opinion 2. $\geq 8$ weeks of symptoms consistent with cervical spondylosis 3. Radiographical evidence of spondylosis 4. $\leq 1$ prior surgical or intradiscal procedures 5. Able to read English at $\geq 8$ th grade level and fluent in spoken English 6. Age $> 18$ yr 7. Absence of ailment preventing participation 8. Legal US residence, no incarceration, signed informed consent	Not assessed	Follow up at 1-year: - Average worsening of activities of conservatively treated patients (P $< .05$ )	
Shimomura et al <sup>19</sup> Sumi et al <sup>20</sup> Prospective cohort	N = 70 ††, N = 60 †† Mean age = 55.1 +/- 11.8 yr Male = 70% N = 69*	3 yr (80%) †† 6.5 yr (79%) ††	Mild CSM (mJOA $\geq 13$ )	JOA MRI factors	Extent of cord compression predicted worsening OR 26.6 (1.7-421.5)	Follow-up at 3-year (JOA): -19.6% deterioration
		2.5 yr (NR)		JOA	Increased duration of symptoms was related with clinical	Follow-up at 2.5-year (JOA): -62% deterioration

(continued)

**Table 1.** (continued)

Authors & study design	Demographics	Follow-up, mean (%)	Inclusion criteria	Outcome measure	Prognostic factors noted (Significant factors)	Natural history estimate
Yoshimatsu et al <sup>21</sup> Retrospective cohort	Mean age = 67 yr (Range, 42-87) Male = 51%		1. CSM based on clinical signs and the presence of compression on the spinal cord by MRI 2. Patients self-selected to be in the conservative treatment group after treatment opinions were explained to them 3. All patients except 2 had an initial JOA score $\geq$ 13		deterioration of symptoms ( $P = .001$ ) Patient who did not follow rigorous conservative treatment were more likely to deteriorate ( $P < .025$ )	
Wu et al <sup>22</sup> Retrospective cohort	N = 14140; mean age = NR; % male NR	> 1 year; % NR	Subjects hospitalized and discharged with the diagnostic ICD-9 code for CSM (721.1) (National Health Research Institute of Taiwan)	Incidence of Spinal Cord Injury	Not assessed	- Incidence Risk for hospitalization for SCI 13.9/1000 person-years (11.6-16.6) for patients with CSM
Wu et al <sup>23</sup> Retrospective cohort	N = 5604; mean age = 60.35 $\pm$ 14 years; 70% male	> 3 years; % NR	Subjects hospitalized within the study period with a first-time discharge summary containing the diagnostic ICD-9 code for OPLL (723.7x) (National Health Research Institute of Taiwan) Patients hospitalized for OPLL who have not received spinal intervention within the previous 6 months (National Health Research Institute of Taiwan)	Incidence of Spinal Cord Injury	Not assessed	- Incidence Risk for hospitalization for SCI of 4.8/1000 person-years with OPLL. - Rate of hospitalization for SCI in patients with DCM from OPLL was higher than the rate observed in a healthy population (0.18/1000 person-years; hazard ratio = 32.2; 10.4-99.0; $P < .001$ ).
Matsunaga et al <sup>24</sup> Prospective cohort	N = 36; mean age = 61.8 years; 59% male	17.6 years (Range = 10-30 years); % NR	Patients with DCM from OPLL	JOA Nurick	Not assessed	- Increased myelopathy was observed in 64% (23/36) patients
Martin et al <sup>25</sup> Ambispective Cohort	N = 117; mean age = 54.6 years; 54% male	2.6 years (100%)	Patients seen in surgical consultation with DCM with: 1) newly diagnosed (N = 95) or 2) recurrent myelopathy (N = 22) after previous surgery	Surgeon's assessment mJOA QuickDASH JAMAR grip GRASSP- Myelopathy Electronic gait analysis Berg balance Anatomical MRI	mJOA severity category	- Neurological deterioration observed in 57% patients with primary DCM; 73% with recurrent DCM.



**Figure 1.** Spectrum of changes in DCM represented by T2 anatomical MRIs. A, A single-level disc degeneration resulting in spinal cord compression (D). Also shown here are hyperintensity changes of the vertebral body endplates consistent with type I or II modic changes (M). B, A patient with ossification of the posterior longitudinal ligament (OP) and disc degeneration (D). C, A patient with severe multi-level bone and disc degeneration and kyphotic deformity. D, A patient with congenital fusion between C4-5 (C). In addition, there is a retrolisthesis evident at the inferior end of the fused vertebrae (S) as well as enlargement of the ligamentum flavum (LF). Taken from Nouri et al.<sup>34</sup>

of the largest DCM cohorts (representing approximately 2/3rds of patients in the global AOSpine study of operated DCM patients),<sup>36</sup> suggesting that males may be at an elevated risk for DCM development. This is supported by a large Taiwanese study showing that the highest incidence of DCM for both males and females occurred in their 70s, but with a significant difference in incidence rates between the genders (28.9 for males vs 15.3 for females per 100 000 person-years).<sup>22</sup> Some research has suggested this may be due to anatomical variations in canal/vertebral-body ratio, but studies on this subject are sparse.<sup>38</sup> Clinical series of surgically treated DCM patients have shown that males more commonly present with more severe degenerative states, more commonly have multilevel compression, and T2 hyperintensity changes.<sup>34</sup> The nature of this association, however, is not completely clear and may be explained by multiple factors including exposure to certain work-related or environmental factors in males as compared to females.

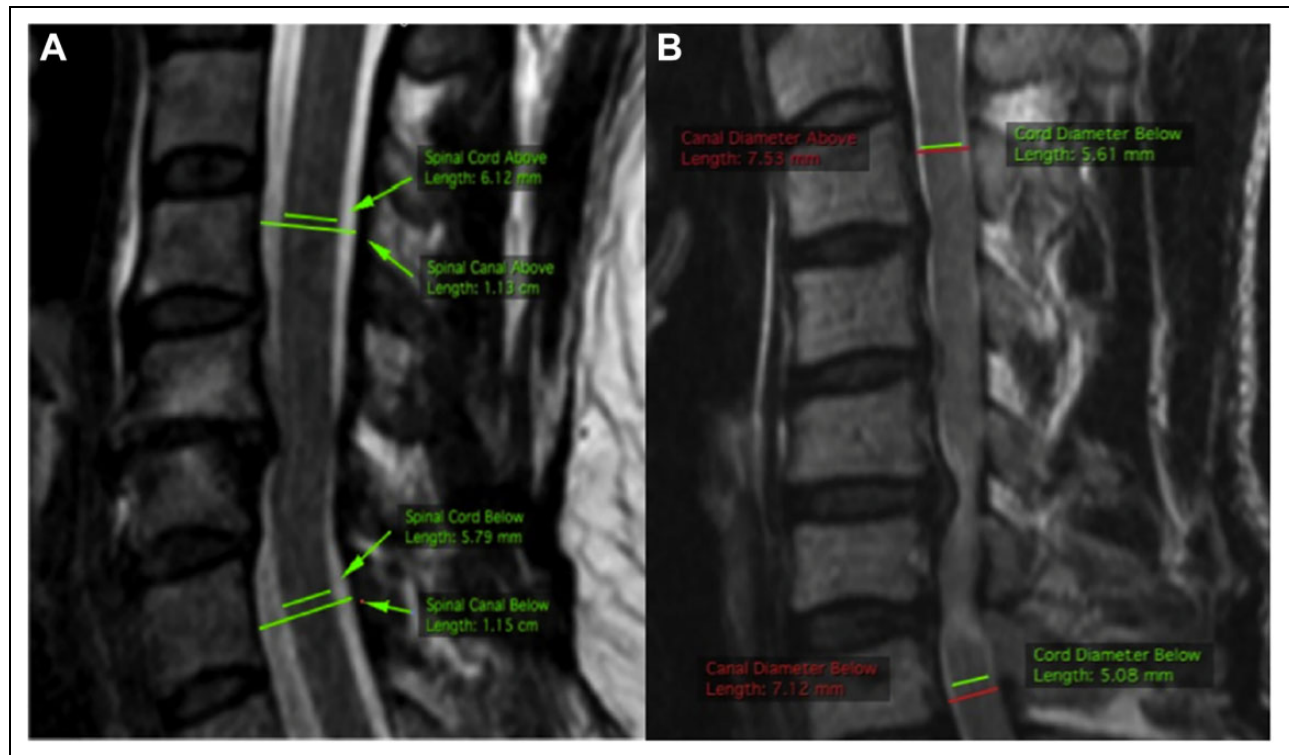
Several other risk factors for cervical spine degeneration and DCM development have been investigated in the literature, with definitive evidence for causal factors remaining limited.<sup>1,39</sup> The most relevant of these factors are discussed in further detail below.

**Anatomical cervical cord-canal mismatch.** Intuitively, the congenital presence of a narrow spinal canal, also known as “congenital stenosis” or “developmental canal stenosis” should predispose individuals to the development of DCM. However, evidence supporting a clear association between congenital stenosis and myelopathy development remains sparse.<sup>39</sup> Older criteria for defining a narrow canal anatomically based on radiographs and cadaver studies set a sagittal width of <12-13mm or a Torg-Pavlov ratio <0.80-0.82 for the diagnosis.<sup>40-43</sup>

While previous research has focused primarily on canal size, recent studies have recognized that spinal cord size also varies and have thus argued that relative size of the canal and cord should be assessed.<sup>44,45</sup> The basis of a cord-canal size mismatch is that both a narrow canal and a large spinal cord can predispose patients to cervical spinal cord compression and potential myelopathy development.<sup>44,46</sup> This knowledge has resulted in the development of relative parameters based on MRI that incorporate the size of the spinal cord, including: space available for the cord (SAC) and spinal cord occupation ratio (SCOR), Figure 2. Depending on the technique, a cord-canal mismatch can be defined as a SCOR  $\geq 70\%$  when measured on the midsagittal plane,<sup>47</sup>  $\geq 80\%$  on the axial plane,<sup>48</sup> or  $<5\text{mm}$  of SAC.<sup>49</sup> While it has been shown that both the large cord and smaller canal are risk factors for DCM, it has likewise been shown that there is greater anatomical variability in canal size compared to spinal cord size in the population, indicating that this will be the more common reason for a cord-canal mismatch.<sup>44</sup>

The risk of spinal cord compression in patients with a cord-canal mismatch has been attributed to 1) less space within the canal, which lowers the amount of degenerative changes or migration of spine structures into the canal that are necessary for spinal cord compression to occur, 2) less cerebrospinal fluid cushion that surrounds the spinal cord, which decreases the ability of the fluid to absorb kinetic forces directed at the spine throughout movement of the head and neck.<sup>44</sup>

In the sub-analysis of the international and multicenter AOSpine studies on patients with DCM surgically treated, the prevalence of a cord-canal mismatch using a sagittal SCOR  $\geq 70\%$  was found to be 8.4%, and patients diagnosed with a cord-canal mismatch at non-compressed sites were found to be



**Figure 2.** Cord-Canal mismatch measurement in 2 different patients based on sagittal T2 MRI. A, Represents a patient without a cord-canal mismatch with a SCOR calculated at 52.2%  $([6.12 + 5.79]/[1.13 + 1.15]) \times 100$ . B, The patient has a cord-canal mismatch as evidenced by an SCOR of 73.0%  $([5.61 + 5.08]/[7.53 + 7.12]) \times 100$ . Taken from Nouri et al.<sup>44</sup>

5.4 years younger and presented reduced baseline neurological function and quality of life.<sup>47</sup>

Future research is needed to understand the role of genetic causes of cord-canal mismatch and to gain increased insight into how mismatch influences myelopathy development and/or progression.

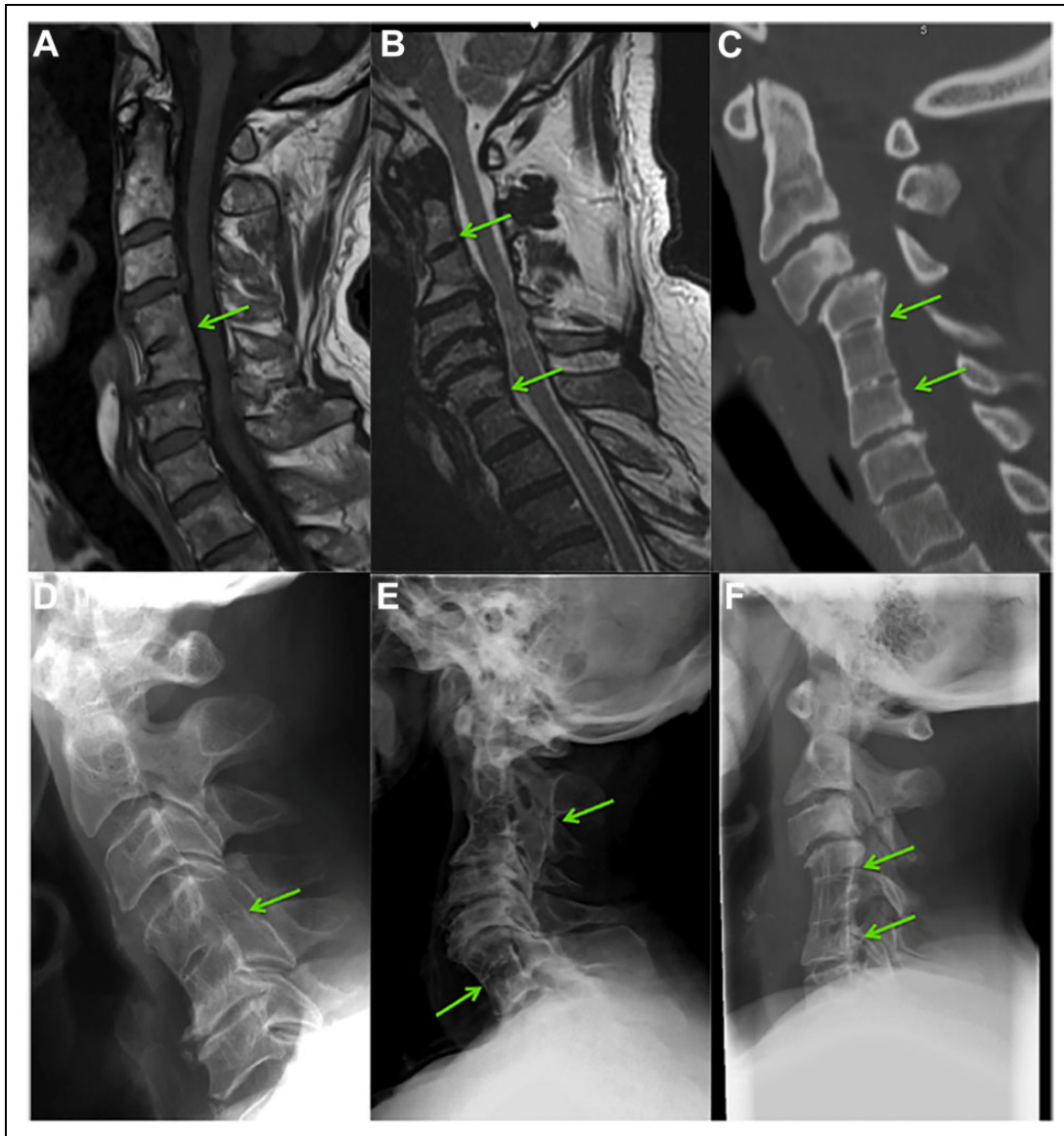
**Congenital cervical fusion (Klippel-Feil syndrome).** Congenital fusion of cervical vertebrae, which can be seen in the context of Klippel-Feil Syndrome (KFS) Figure 3, has a reported prevalence of between 0.5 and 0.7% based on cadaver and imaging studies.<sup>50,51</sup> Although KFS is classically associated with the triad of a short neck, lower posterior hairline, and restriction of neck movement, all three of these features are only present in a minority of cases.<sup>51,52</sup> Most commonly, congenital cervical fusion is encountered incidentally without any of the other classical clinical features of KFS.

It has been previously hypothesized that patients with congenital fusions are at an increased risk for myelopathy development at the segments adjacent to fusion<sup>53-55</sup> because fusion may increase the biomechanical stress on the adjacent discs and accelerate degeneration.<sup>56,57</sup> A small study has shown a relatively high prevalence rate of congenital fusions among DCM patients (2.4%) compared to the general population.<sup>53</sup> However, no definitive studies exist to establish a clear link between congenital cervical fusions and increased predisposition to DCM. The same study also showed that in patients with

congenital fusions, adjacent segment disease was preferentially present at segments toward the center of the cervical spine; however, despite the higher prevalence rates among DCM patients, and considering the limited size of the patient population with congenital fusion, no difference in duration of symptoms or age was found.<sup>53</sup>

**Genetic factors.** Alterations in gene structure and expression are known to contribute to disease. Several studies have investigated for genetic factors associated with DCM, with the current evidence supporting a genetic basis for development of this condition. The most convincing study of an underlying genetic predisposition was undertaken by Patel et al<sup>58</sup> who utilized population-based data and cross referenced a genealogic database of over 2 million Utah residents with 10 years of clinical diagnosis data from a large tertiary hospital. They showed, using the Genealogical Index of Familiarity, a significant excess relatedness for disease with the relative risk for DCM among first-degree relatives to be 5.21. While this study did not identify specific genes of interest, it demonstrated that heritability plays a role in DCM development.

Systematic reviews on genetic factors have supported the principle of a genetic predisposition to both DCM development and clinical severity.<sup>59,60</sup> Some genetic polymorphisms have been linked to disc degeneration and spondylosis, while others are linked to OPLL development. The most recent systematic



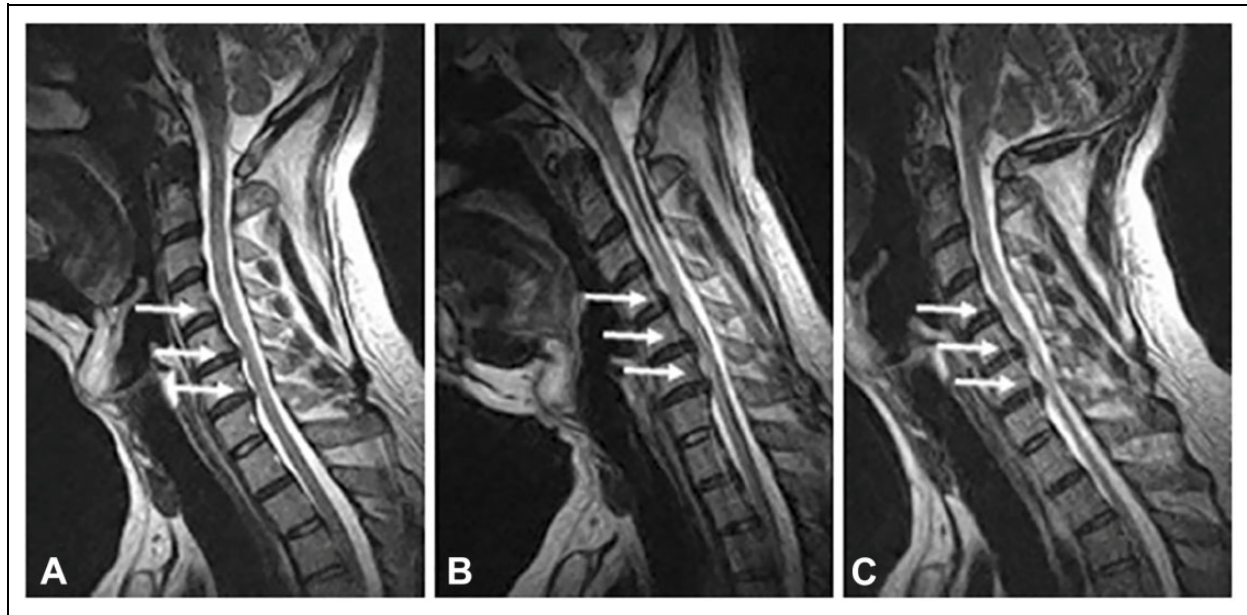
**Figure 3.** Klippel-Feil syndrome and degenerative cervical myelopathy. A and D, A single fusion of C4-5 seen on T1 MRI and lateral radiograph of the same patient. B and E, Two non-contiguous fusions between C2-3 and C6-7 on T2 MRI and lateral radiograph. C and F, Two contiguous fusions between C4-5 and C5-6 on CT and lateral radiograph. Adapted from Nouri et al.<sup>53</sup>

review and meta-analysis has identified 28 genes of interest with regards to DCM, including those affecting collagens,<sup>27,30,32</sup> Interlukins,<sup>1,37,34</sup> Transforming growth factor,<sup>1,2,3</sup> Vitamin D binding protein, Bone morphogenic protein,<sup>2,4,30</sup> Fibroblast growth factor (1, 2) as well as many others.<sup>60</sup> From these, 22 genes were found to be associated with radiologically defined spinal pathology, predominantly OPLL, 12 associated with clinical DCM development, 8 were found to have an effect on the radiological severity, 3 had an effect on clinical severity, and 6 on the clinical response to surgery in spinal cord disease.<sup>60</sup> However, the specific mechanisms by which these genetic factors affect the natural history remain incompletely defined because none of the candidates have been studied sufficiently to provide a high level of evidence, and

most studies have been conducted in isolated populations (almost all of the studies have been conducted in China, Japan, and South Korea).<sup>60</sup> While these genetic studies have predominantly focuses on polymorphisms of specific genes, recent research has shown that expression of specific microRNA's can be applied clinically as a biomarker in the clinical setting.<sup>61</sup> Laliberte et al<sup>61</sup> has recently shown that greater mir-21-5p expression was associated with worse surgical prognosis based on the mJOA at 1 year follow-up. The authors attribute this effect of mir-21-5p on its presumed pro-inflammatory mechanism.

While the genetic basis for certain syndromic conditions associated with structural aberrations of the cervical spine is better described, understanding surrounding relative susceptibility to





**Figure 4.** Dynamic cervical spinal cord compression on MRI. A neutral (A) and flexion (B) and extension (C) T2 MRI showing the effect of movement on spinal cord compression. Here flexion of the spine unmasks spinal cord compression not clear in neutral imaging. Taken from—Lao et al.<sup>71</sup>

myelopathy development with most of these conditions remains incomplete. As examples, patients with Klippel-Feil Syndrome, Down's Syndrome (atlanto-axial abnormalities),<sup>62</sup> Ehlers Danlos Syndrome (Hypermobility)<sup>63,64</sup> and Achondroplasia (congenital cervical stenosis)<sup>65</sup> have an inherited predisposition for cervical spine anomalies, many of which can lead to cervical canal narrowing. However, the relative risk of symptomatic myelopathy development among patients with these conditions, as compared to nonaffected individuals, remains largely unknown.

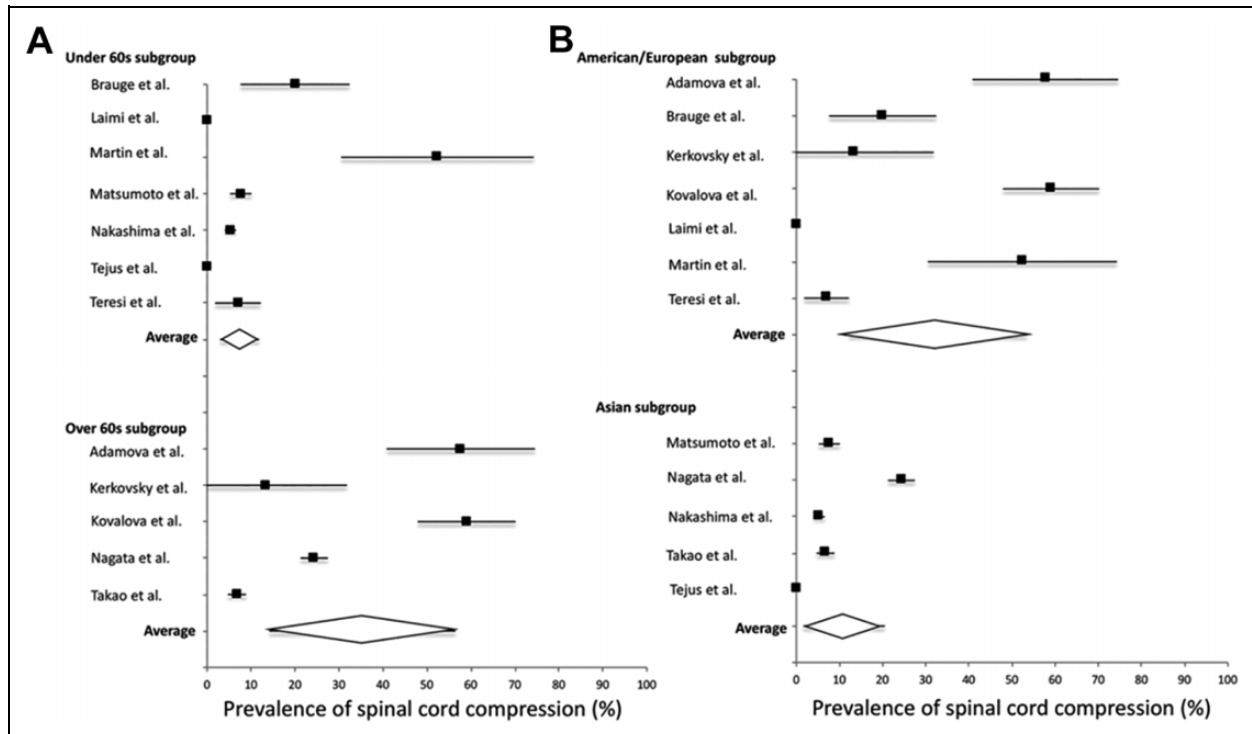
Given the current evidence, genetic factors likely influence DCM development, severity, and recovery potential, however, validation studies with genetically distinct populations will need to be undertaken before these research findings can be applied to clinical practice.

**Role of minor trauma, cervical instability and motion on the development of DCM and spinal cord injury.** Although clinical deterioration may occur spontaneously, DCM patients are at risk of developing acute spinal cord injury (SCI) in case of physical trauma (i.e. fall or motor vehicle accident). This increased risk is thought to be secondary to several factors, including the presence of spasticity and gait unsteadiness that increase the propensity for falls, and the presence of pre-existing canal narrowing and spinal cord compression. A recent systematic review showed that the incidence of hospitalization for SCI in Taiwan was 13.9 and 4.8 per 1000 person-years in patients with DCM and myelopathy secondary to OPLL, respectively.<sup>22,5,23</sup> The rate of hospitalization of SCI in patients with myelopathy from OPLL was significantly higher than the rate observed in a healthy population (hazard ratio of 32.2).<sup>5</sup> Contrary to these findings, a prospective study by Bednarik, Sladkova<sup>66</sup> did not show a relationship between traumatic

events and myelopathy onset in 199 patients with initial asymptomatic spinal cord compression. During the study, 14 patients experienced traumatic events at an average of 44-months follow-up, but none were associated with immediate neurological deterioration.

Aside from more dramatic or catastrophic instances of traumatic SCI, it has been suggested that minor traumatic events, leading to significant head and neck movements, may cause episodes of decline or may be the precipitating event causing neurological deterioration in patients with known DCM.<sup>1,66-68</sup> Movement-based spinal cord trauma can be explained by changes in the cross-sectional diameter of the spinal canal during flexion and extension,<sup>69</sup> Figure 4. In a cohort of patients with neck pain, with or without neurological symptoms, studied with dynamic MRI, Hayashi, Wang<sup>70</sup> reported a high level of missed stenosis in the neutral position, and that dynamic stenosis was discovered in 8.3% of vertebral segments only when in extension, and 1.6% only when in flexion. They noted that missed stenosis occurred most commonly at the C5-6 segment. Cervical range of motion in those with stenosis has also been implicated as a factor. Matsunaga, Kukita<sup>68</sup> showed that myelopathy was present in all patients with OPLL with stenosis <6mm and that no myelopathy was present in those with canal diameters of  $\geq 14$ mm; however, when the canal diameter was >6mm but <14mm, myelopathy preferentially developed in those with increased range of cervical motion.

Repetitive spinal cord compression events resulting from cervical instability in the setting of cervical spondylolisthesis has also been suggested to be a potential marker of worse disease severity and as a potential cause of neurological deterioration in DCM patients. This was recently highlighted by a sub-analysis of the AO Spine International studies on DCM,



**Figure 5.** Prevalence of asymptomatic spinal cord compression among different demographic groups. Taken from Smith et al.<sup>76</sup>

showing that patients with spondylolisthesis present with worse neurological function at baseline, and when propensity matched on other key variables, presented with worse neurological outcomes than patients without spondylolisthesis.<sup>72</sup> A recent systematic review on this topic corroborated these results.<sup>73</sup> It is possible that this subset of patients undergoes an alternative natural disease course highlighted by an accumulation of minor traumatic events; this, however, remains speculative.

### Natural History of Non-Myelopathic Spinal Cord Compression (NMSCC)

As discussed above, age-related cervical degenerative changes occur commonly, often leading to some degree of spinal canal narrowing or spinal cord compression. However, most patients with spinal canal narrowing or spinal cord compression do not have clinical signs and symptoms of myelopathy [non-myelopathy spinal cord compression (NMSCC)].

In a Japanese MRI study of 1,211 asymptomatic volunteers ranging between the 2nd and 7th decade, NMSCC was observed in 5.3% of the study participants, with a second Japanese study finding cord compression in 7.6% of 497 asymptomatic persons undergoing MRI.<sup>26,45</sup> However, more recent studies have shown a much higher incidence of asymptomatic spinal cord compression, particularly in older patients. Kovalova, Kerkovsky<sup>74</sup> noted NMSCC in 57.9% of 183 volunteers older than 40 years undergoing cervical MRI. Similarly, a sub-analysis of 40 non-myelopathic control subjects in a prospective DCM imaging study discovered that 20 of these

asymptomatic patients had MRI evidence of spinal cord compression (defined as indentation, flattening, or torsion).<sup>75</sup> Furthermore, the latter study showed that these NMSCC patients had macrostructural and microstructural changes (based on advanced imaging techniques) similar to those observed in symptomatic DCM. The large discrepancy in prevalence rates between these studies is challenging to interpret. However, it is likely that variations in diagnostic criteria for NMSCC between studies, as well as differences between the ethnic populations studied, may explain the heterogeneity. Specific prevalence rates of asymptomatic spinal cord compression among different study population demographics have recently been presented in a meta-analysis,<sup>76</sup> Figure 5. Based on this analysis, the prevalence of NMSCC in a healthy population is 24.2%, and 35.3% in individuals >60 years.<sup>76</sup>

The key question when considering patients with NMSCC relates to their likelihood of developing myelopathy over time. Of the 20 NMSCC patients discussed in the imaging study above, 2 (10%) eventually developed symptoms of myelopathy at a median follow-up of 21-months. In the largest prospective study performed to date on this topic, Bednarik et al found that among 199 patients enrolled with NMSCC, 8% at 1-year follow-up and 22.6% at a median of 44 months follow-up (Range 2-12 years) developed symptoms of myelopathy.<sup>77</sup> In this study, factors shown to be predictive of myelopathy development in multivariate survival analysis at 1-year follow-up included: the presence of clinical cervical radiculopathy, prolonged somatosensory and motor evoked potentials, and the absence of spinal cord T2 hyperintensity on MRI. Interestingly, at longer-term follow-up (44-months), the presence of T2

hyperintensity on MRI portended a higher risk of myelopathy development. Hence, the importance of T2 signal change in predicting the risk of clinical progression remains unknown. In another study by the same group in 2017, wherein 13.4% of patients (15/112) developed DCM at a median follow-up of 36-months, multivariate analysis showed that radiculopathy, axial cross-sectional area  $\leq 70.1\text{mm}^2$ , and compression ratio (CR, anteroposterior size/transverse size of the cord on axial imaging)  $\leq 0.4 \leq 0.4$  was predictive of DCM development.<sup>78</sup> The difference in the rate of progression and significant predictors could be influenced by a different recruitment strategy of NMDCC patients in these studies. The former study included patients referred to a center for radiculopathy or cervical pain (i.e. without myelopathic symptoms or signs, but not clearly asymptomatic) and has more severe radiological compression in contrast to the latter one recruited randomly as a part of the epidemiological study. While it is notable that many of the predictors reported have differed with follow-up time, the presence of radiculopathy has remained a consistent predictor across studies. In addition to clinical radiculopathy, electrophysiological measures, including prolonged SSEPs and MEPs, are associated with an increased rate of myelopathy development, and their presence has been suggested as a potential indication to consider surgery for patients with NMSCC.<sup>79</sup>

Further work is needed to understand the prevalence of NMSCC more precisely, as well as rates of deterioration, and to identify key biomarkers (i.e., clinical, imaging, genetic, and electrophysiological factors) that predict clinical course for purposes of aiding clinical communication, facilitating treatment decisions, and gauging the optimal follow-up interval for those who are observed over time. Ultimately, this information would be critical to direct updates to the guidelines on the management of these patients, which are currently based on limited evidence.<sup>80</sup>

### **Progression of Asymptomatic OPLL and Myelopathy Development**

While the prevalence of OPLL varies significantly depending on the region of the world and ethnicity considered (approximately 1.3% among Caucasians and 6.3% among Japanese), clinical experience dictates that only a fraction of patients with this ligamentous aberration are symptomatic and require treatment.<sup>81</sup> From a radiographic progression perspective, a recent retrospective cohort study from Japan reported on 109 individuals with incidentally discovered OPLL. At a mean follow-up of 80.8-months, the incidence of OPLL progression was 18.3%, defined as an increase of  $>2\text{mm}$  in the sagittal thickness and/or the length of the ossification.<sup>82</sup> Risk factors for progression included younger age at diagnosis, higher serum uric acid levels, OPLL involvement of  $\geq 3$  vertebral levels, and continuous type of OPLL, whereas progression was less common in individuals with a segmental type of OPLL.<sup>82</sup> Another study of conservatively treated OPLL patients with no or “slight” myelopathy also found that

younger age was a significant predictor of OPLL progression, in addition to higher body weight and BMI.<sup>83</sup>

In another recent study, Park et al<sup>84</sup> reported a progression rate of 26.8% in vertical dimensions and 22.7% in antero-posterior dimensions after a mean follow-up of 39.3 months. In this study, younger age at diagnosis and presence of OPLL at C2-3 were found to be among the variables predicting higher risk of radiographic progression. They also noted that segmental progression of an ossified mass occurred with increased segmental range of motion ( $\geq 5^\circ$ ).

Although radiographic progression of OPLL is of importance, the greater clinical concern relates to the risk of myelopathy development among patients with asymptomatic OPLL. Unfortunately, estimates surrounding this question are extremely imprecise and based on low-quality evidence. A previous systematic review<sup>79</sup> and recent studies have reported a large range of myelopathy development, ranging from 0% in subjects (0/27) followed for a mean of 59 months<sup>85</sup> to 61.5% in subjects (96/156) with a mean 123.6-month follow-up.<sup>86</sup> In addition, the recent study by Park et al<sup>84</sup> demonstrated that 9.3% of patients had mild myelopathy at a mean follow-up of 39.3 months and that an additional 2.1% of patients were operated on myelopathy during the study period. Risk factors for myelopathy development included canal stenosis of  $\geq 60\%$ , lateral deviated OPLL, and increased cervical range of motion.<sup>86</sup>

### **Progression of DCM in Non-Operatively Treated Patients**

When considering the topic of DCM, perhaps the greatest clinical knowledge gap relates to the management of patients with mild DCM. Recent guidelines suggest either surgery or clinical observation to be reasonable initial treatment options.<sup>80</sup> The central question underlying our treatment decision for mild DCM patients is: what will happen if we do not intervene with surgical decompression? Apart from mild patients, more severely affected patients, for a variety of reasons, may also not undergo surgery; for purposes of quantifying expectations for the future, attaining a sound understanding of natural history for this group is important.

The sparse and largely low-quality evidence currently available provides imprecise estimates surrounding the expected clinical course for patients with symptomatic myelopathy treated non-operatively. Systematic reviews of the literature have shown that conversion to surgery for non-operatively followed patients ranged between 4% to 40% over 3-7 year follow-up periods.<sup>5</sup> From the perspective of clinical progression, the available literature suggests that 20-62% of DCM patients treated non-operatively will experience neurological deterioration as assessed by the mJOA over 3-6 years of follow-up.<sup>87</sup> However, most of these studies used JOA or mJOA to define neurological progression without considering the minimal detectable difference (MDD), which appears to be greater than 1 point based on reliability studies.<sup>88,89</sup> A recent study using an array of measures of spinal cord function found that 57% of DCM patients deteriorate over a mean follow-up of

2.5 years, with quantitative measurement of hand grip strength, hand dexterity, electronic gait analysis, and balance showing the greatest sensitivity to deterioration.<sup>25</sup> Factors influencing the imprecision of current estimates include significant between study variations in duration and rates of follow-up, definition of clinical change or deterioration, and the specifics of cohort composition as it relates to the severity of symptoms and underlying pathology. The inexact nature of these estimates leaves clinicians in a difficult situation when attempting to counsel patients about the relative merits of operative vs. non-operative treatment.

In addition to understanding rates of clinical progression, it is also important for clinicians to understand predictors of deterioration with non-operative care so that those at the highest risk may be selectively targeted with early surgery. While several studies have investigated potential predictors of neurological deterioration, few variables have reliably demonstrated importance in this regard.<sup>16,19,90</sup> Circumferential compression of the spinal cord has been shown to be predictive of myelopathy progression.<sup>90,19</sup> Likewise, an increased range of motion, which interestingly has also been related with OPLL progression, as previously noted, has also been suggested to predict neurological decline.<sup>16</sup> From an electrophysiological perspective, normal central motor conduction time has been shown to predict lack of neurological decline in mild myelopathy patients treated without surgery.<sup>90</sup> Other factors, such as age and the presence of T2 hyperintensity on MRI have not reliably predicted the clinical course of patients treated non-operatively.<sup>87,90,19</sup>

In a recent study, quantitative MRI (qMRI) techniques, including white to gray matter ratio, fractional anisotropy and cross-sectional assessment were shown to detect myelopathy progression (Progression was defined as patients' subjective impression, 2-point mJOA decrease,  $\geq 3$  clinical measures worsening  $\geq 5\%$ , increased compression on MRI, or  $\geq 1$  of 10 qMRI measures or composite score worsening) with a higher sensitivity than mJOA.<sup>91</sup> This study highlighted that while patients may seem stable neurologically by conventional measures, disease progression not appreciated by less sensitive clinical measures may be occurring.

Although a significant proportion of patients with DCM treated non-operatively will deteriorate over time, it is also clear within the literature that a sizable proportion will remain stable over time. A new line of evidence is emerging that may help to explain this clinical stability, showing that "supraspinal" and cortical changes may facilitate adaptation of neurological function.<sup>92,93</sup> It has been recently suggested that a "functional reserve capacity," which is facilitated by new cortical motor connection in the supplementary motor region, may provide a compensatory mechanism in patients with spinal cord compression and may mask spinal cord sufferance.<sup>92</sup> While further work to support these findings is necessary, such a mechanism may help to explain the clinical stability, or even occasional clinical improvement, in neurological status seen in DCM patients, despite ongoing spinal cord compression.

## Conclusion and Future Directions

Degeneration of the cervical spine progressing to spinal cord compression, and subsequently development of myelopathy, represents a continuum of disease progression that remains incompletely understood. Furthermore, despite the ubiquity of spinal cord compression due to degenerative cervical spine disease, our understanding surrounding the frequency of clinical deterioration with non-operative care—the natural history of this condition—remains limited. This knowledge gap hinders clinicians' ability to adequately counsel patients. A number of ongoing studies are underway to address this knowledge gap including a Canadian multicenter prospective longitudinal study that assesses the natural history of patients with mild myelopathy treated with initial non-operative care (DCM-NH study). Started in 2019, and now at about 30% of the 220 subject target sample size, this study will follow mild DCM patients for up to 5 years to understand the true rate of clinical change for this patient group. This study, in addition to others, also investigates the utility of microstructural MRI variables, in addition to blood biomarkers, to predict the clinical trajectory of DCM patients treated non-operatively. In addition to clinical, imaging and blood biomarker related variables, electrophysiological parameters such as sensory and motor evoked potentials are becoming increasingly used and reported as a means to assess spinal cord sufferance and predict clinical course.<sup>2,3</sup> It is anticipated that incorporation of these and other tools may permit a more individualized estimate for disease progression facilitating personalized treatment recommendations for DCM patients based on their specific risk for clinical deterioration.

## Acknowledgments

Further details on this priority, including how it was prioritized, why it was prioritized, and on-going research activity can be found at [aospine.org/recode/natural-history](http://aospine.org/recode/natural-history).

## Declaration of Conflicting Interests


The author(s) declared no potential conflicts of interest with respect to the research, authorship, and/or publication of this article.

## Funding

The author(s) disclosed receipt of the following financial support for the research, authorship, and/or publication of this article: The research priorities were organized and funded by AO Spine through the AO Spine Knowledge Forum Spinal Cord Injury, a focused group of international Spinal Cord Injury experts. AO Spine is a clinical division of the AO Foundation, which is an independent medically-guided not-for-profit organization. Study support was provided directly through the AO Spine Research Department. MRNK is supported by the National Institute for Health Research (NIHR) Brain Injury MedTech Co-operative based at Cambridge University Hospitals NHS Foundation Trust and University of Cambridge, and BMD a NIHR Clinical Doctoral Research Fellowship. The views expressed in this publication are those of the authors and not necessarily those of the NHS, the National Institute for Health Research or the Department of Health and Social Care. JRW acknowledges support from the


Labatt Endowed Chair in Neurosurgery. JB was supported by the Czech Health Research Council grants NV18-04-00159 and by Ministry of Health of the Czech Republic project for conceptual development in research organization, ref. 65269705.


### ORCID iDs

Aria Nouri, MD, MSc  <https://orcid.org/0000-0002-4965-3059>

Hiroaki Nakashima, MD, PhD  <https://orcid.org/0000-0002-0039-9678>

Michael G. Fehlings, MD, PhD  <https://orcid.org/0000-0002-5722-6364>

Benjamin M. Davies, MRCS, BSc, MPhil  <https://orcid.org/0000-0003-0591-5069>

Jefferson R. Wilson, MD, PhD  <https://orcid.org/0000-0001-5965-0305>

### References

- Nouri A, Tetreault L, Singh A, Karadimas S, Fehlings M. Degenerative cervical myelopathy: epidemiology, genetics and pathogenesis. *Spine (Phila Pa 1976)*. 2015;40(12):E675-E693.
- Nouri A, Cheng JS, Davies B, Kotter M, Schaller K, Tessitore E. Degenerative cervical myelopathy: a brief review of past perspectives, present developments, and future directions. *J Clin Med*. 2020;9(2):535.
- Badhiwala JH, Ahuja CS, Akbar MA, et al. Degenerative cervical myelopathy—update and future directions. *Nat Rev Neurol*. 2020;16(2):1-17.
- Fehlings MG, Kwon BK, Tetreault LA. *Guidelines for the Management of Degenerative Cervical Myelopathy and Spinal Cord Injury: An Introduction to a Focus Issue*. Sage Publications; 2017.
- Tetreault LA, Karadimas S, Wilson JR, et al. The natural history of degenerative cervical myelopathy and the rate of hospitalization following spinal cord injury: an updated systematic review. *Global Spine J*. 2017;7(3\_suppl):28S-34S.
- Barnes MP, Saunders M. The effect of cervical mobility on the natural history of cervical spondylotic myelopathy. *J Neurol Neurosurg Psychiatry*. 1984;47(1):17-20.
- Bednarik J, Kadanka Z, Vohánka S, Stejskal L, Vlach O, Schröder R. The value of somatosensory-and motor-evoked potentials in predicting and monitoring the effect of therapy in spondylotic cervical myelopathy: prospective randomized study. *Spine*. 1999;24(15):1593.
- Kadanka Z, Bednarik J, Novotny O, Urbanek I, Dusek L. Cervical spondylotic myelopathy: conservative versus surgical treatment after 10 years. *Eur Spine J*. 2011;20(9):1533-1538.
- Kadanka Z, Mares M, Bednanik J, et al. Approaches to spondylotic cervical myelopathy: conservative versus surgical results in a 3-year follow-up study. *Spine (Phila Pa 1976)*. 2002;27(20):2205-2210. Discussion 10-1.
- Kadaňka Z, Mareš M, Bednařík J, et al. Predictive factors for spondylotic cervical myelopathy treated conservatively or surgically. *Eur J Neurol*. 2005;12(1):55-63.
- Kadaňka Z, Bednařík J, Vohánka S, et al. Conservative treatment versus surgery in spondylotic cervical myelopathy: a prospective randomised study. *Eur Spine J*. 2000;9(6):538-544.
- Lees F, Turner JA. Natural history and prognosis of cervical spondylosis. *Br Med J*. 1963;2(5373):1607.
- Matsumoto M, Chiba K, Ishikawa M, Maruiwa H, Fujimura Y, Toyama Y. Relationships between outcomes of conservative treatment and magnetic resonance imaging findings in patients with mild cervical myelopathy caused by soft disc herniations. *Spine (Phila Pa 1976)*. 2001;26(14):1592-1598.
- Matsumoto M, Toyama Y, Ishikawa M, Chiba K, Suzuki N, Fujimura Y. Increased signal intensity of the spinal cord on magnetic resonance images in cervical compressive myelopathy: does it predict the outcome of conservative treatment? *Spine*. 2000;25(6):677-682.
- Nakamura K, Kurokawa T, Hoshino Y, Saita K, Takeshita K, Kawaguchi H. Conservative treatment for cervical spondylotic myelopathy: achievement and sustainability of a level of “no disability.” *J Spinal Disord*. 1998;11(2):175-179.
- Oshima Y, Seichi A, Takeshita K, et al. Natural course and prognostic factors in patients with mild cervical spondylotic myelopathy with increased signal intensity on T2-weighted magnetic resonance imaging. *Spine (Phila Pa 1976)*. 2012;37(22):1909-1913.
- Roberts A. Myelopathy due to cervical spondylosis treated by collar immobilization. *Neurology*. 1966;16(9):951.
- Sampath P, Bendebba M, Davis JD, Ducker TB. Outcome of patients treated for cervical myelopathy. A prospective, multicenter study with independent clinical review. *Spine (Phila Pa 1976)*. 2000;25(6):670-676.
- Shimomura T, Sumi M, Nishida K, et al. Prognostic factors for deterioration of patients with cervical spondylotic myelopathy after nonsurgical treatment. *Spine (Phila Pa 1976)*. 2007;32(22):2474-2479.
- Sumi M, Miyamoto H, Suzuki T, Kaneyama S, Kanatani T, Uno K. Prospective cohort study of mild cervical spondylotic myelopathy without surgical treatment. *J Neurosurgery*. 2012;16(1):8-14.
- Yoshimatsu H, Nagata K, Goto H, et al. Conservative treatment for cervical spondylotic myelopathy. Prediction of treatment effects by multivariate analysis. *Spine J*. 2001;1(4):269-273.
- Wu JC, Ko CC, Yen YS, et al. Epidemiology of cervical spondylotic myelopathy and its risk of causing spinal cord injury: a national cohort study. *Neurosurg Focus*. 2013;35(1):E10.
- Wu JC, Chen YC, Liu L, et al. Conservatively treated ossification of the posterior longitudinal ligament increases the risk of spinal cord injury: a nationwide cohort study. *J Neurotrauma*. 2012;29(3):462-468.
- Matsunaga S, Sakou T, Taketomi E, Komiya S. Clinical course of patients with ossification of the posterior longitudinal ligament: a minimum 10-year cohort study. *J Neurosurg*. 2004;100(3 suppl):245-248.
- Martin A, Kalsi-Ryan S, Akbar M, et al. Clinical outcomes of nonoperatively managed degenerative cervical myelopathy: an ambispective longitudinal cohort study in 117 patients. *J Neurosurg Spine*. 2021;34(6):821-829.
- Matsumoto M, Fujimura Y, Suzuki N, et al. MRI of cervical intervertebral discs in asymptomatic subjects. *J Bone Joint Surg Br*. 1998;80(1):19-24.
- Nouri A, Martin AR, Mikulis D, Fehlings MG. Magnetic resonance imaging assessment of degenerative cervical myelopathy: a

- review of structural changes and measurement techniques. *Neurosurg Focus*. 2016;40(6):E5.
28. Nakashima H, Yukawa Y, Suda K, Yamagata M, Ueta T, Kato F. Cervical disc protrusion correlates with the severity of cervical disc degeneration: a cross-sectional study of 1,211 relatively healthy volunteers. *Spine (Phila Pa 1976)*. 2015;40(13):E774-E779.
  29. Boden SD, McCowin P, Davis D, Dina T, Mark A, Wiesel S. Abnormal magnetic-resonance scans of the cervical spine in asymptomatic subjects. A prospective investigation. *J Bone Joint Surg Am*. 1990;72(8):1178-1184.
  30. Teresi LM, Lufkin RB, Reicher MA, et al. Asymptomatic degenerative disk disease and spondylosis of the cervical spine: MR imaging. *Radiology*. 1987;164(1):83-88.
  31. Galbusera F, van Rijsbergen M, Ito K, Huyghe JM, Brayda-Bruno M, Wilke HJ. Ageing and degenerative changes of the intervertebral disc and their impact on spinal flexibility. *Eur Spine J*. 2014;23(Suppl 3):S324-S332.
  32. Inamasu J, Guiot BH, Sachs DC. Ossification of the posterior longitudinal ligament: an update on its biology, epidemiology, and natural history. *Neurosurgery*. 2006;58(6):1027-1039. Discussion-39.
  33. Fortin M, Dobrescu O, Courtemanche M, et al. Association between paraspinal muscle morphology, clinical symptoms and functional status in patients with degenerative cervical myelopathy. *Spine J*. 2016;16(10):S200.
  34. Nouri A, Martin AR, Tetreault L, et al. MRI analysis of the combined prospectively collected AOSpine North America and international data: the prevalence and spectrum of pathologies in a global cohort of patients with degenerative cervical myelopathy. *Spine (Phila Pa 1976)*. 2016;42(14):1058-1067.
  35. McClelland III S, Marascalchi BJ, Passias PG, Protosaltis TS, Frempong-Boadu AK, Errico TJ. Impact of race and insurance status on surgical approach for cervical spondylotic myelopathy in the United States: a population-based analysis. *Spine*. 2017;42(3):186-194.
  36. Fehlings MG, Ibrahim A, Tetreault L, et al. A global perspective on the outcomes of surgical decompression in patients with cervical spondylotic myelopathy: results from the prospective multicenter AOSpine international study on 479 patients. *Spine (Phila Pa 1976)*. 2015;40(17):1322-1328.
  37. Nakashima H, Yukawa Y, Suda K, Yamagata M, Ueta T, Kato F. Abnormal findings on magnetic resonance images of the cervical spines in 1211 asymptomatic subjects. *Spine*. 2015;40(6):392-398.
  38. Hukuda S, Kojima Y. Sex discrepancy in the canal/body ratio of the cervical spine implicating the prevalence of cervical myelopathy in men. *Spine (Phila Pa 1976)*. 2002;27(3):250-253.
  39. Singh A, Tetreault L, Fehlings MG, Fischer DJ, Skelly AC. Risk factors for development of cervical spondylotic myelopathy: results of a systematic review. *Evid-Based Spine-Care J*. 2012;3(3):35-42.
  40. Torg JS, Naranja RJ Jr., Pavlov H, Galinat BJ, Warren R, Stine RA. The relationship of developmental narrowing of the cervical spinal canal to reversible and irreversible injury of the cervical spinal cord in football players. *J Bone Joint Surg Am*. 1996;78(9):1308-1314.
  41. Lee MJ, Cassinelli EH, Riew KD. Prevalence of cervical spine stenosis. Anatomic study in cadavers. *J Bone Joint Surg Am*. 2007;89(2):376-380.
  42. Bajwa NS, Toy JO, Young EY, Ahn NU. Establishment of parameters for congenital stenosis of the cervical spine: an anatomic descriptive analysis of 1,066 cadaveric specimens. *Eur Spine J*. 2012;21(12):2467-2474.
  43. Pavlov H, Torg JS, Robie B, Jahre C. Cervical spinal stenosis: determination with vertebral body ratio method. *Radiology*. 1987;164(3):771-775.
  44. Nouri A, Montejo J, Sun X, et al. Cervical cord-canal mismatch: a new method for identifying predisposition to spinal cord injury. *World Neurosurg*. 2017;108:112-117.
  45. Kato F, Yukawa Y, Suda K, Yamagata M, Ueta T. Normal morphology, age-related changes and abnormal findings of the cervical spine. Part II: magnetic resonance imaging of over 1,200 asymptomatic subjects. *Eur Spine J*. 2012;21(8):1499-1507.
  46. Nakashima H, Yukawa Y, Suda K, Yamagata M, Ueta T, Kato F. Relatively large cervical spinal cord for spinal canal is a risk factor for development of cervical spinal cord compression: a cross-sectional study of 1211 subjects. *Spine (Phila Pa 1976)*. 2016;41(6):E342-E348.
  47. Nouri A, Tetreault L, Nori S, Martin AR, Nater A, Fehlings MG. Congenital cervical spine stenosis in a multicenter global cohort of patients with degenerative cervical myelopathy: an ambispective report based on a magnetic resonance imaging diagnostic criterion. *Neurosurg*. 2018;83(3):521-528.
  48. Ruegg TB, Wicki AG, Aebli N, Wisianowsky C, Krebs J. The diagnostic value of magnetic resonance imaging measurements for assessing cervical spinal canal stenosis. *J Neurosurg Spine*. 2015;22(3):230-236.
  49. Presciutti SM, DeLuca P, Marchetto P, Wilsey JT, Shaffrey C, Vaccaro AR. Mean subaxial space available for the cord index as a novel method of measuring cervical spine geometry to predict the chronic stinger syndrome in American football players. *J Neurosurg Spine*. 2009;11(3):264-2671.
  50. Brown MW, Templeton AW, Hodges FJ III. The incidence of acquired and congenital fusions in the cervical spine. *Am J Roentgenol Radium Ther Nucl Med*. 1964;92:1255-1259.
  51. Gruber J, Saleh A, Bakhsh W, Rubery PT, Mesfin A. The prevalence of Klippel-Feil syndrome: a computed tomography-based analysis of 2,917 patients. *Spine Deform*. 2018;6(4):448-453.
  52. Nouri A, Patel K, Evans H, et al. Demographics, presentation and symptoms of patients with Klippel-Feil syndrome: analysis of a global patient-reported registry. *Eur Spine J*. 2019;28(10):2257-2265.
  53. Nouri A, Martin AR, Lange SF, Kotter MRN, Mikulis DJ, Fehlings MG. Congenital cervical fusion as a risk factor for development of degenerative cervical myelopathy. *World Neurosurg*. 2017;100:531-539.
  54. Nouri A, Tetreault L, Zamorano JJ, Mohanty CB, Fehlings MG. Prevalence of Klippel-Feil syndrome in a surgical series of patients with cervical spondylotic myelopathy: analysis of the

- prospective, multicenter AOSpine North America study. *Global Spine J.* 2015;5(4):294-299.
55. Pizzutillo PD, Woods M, Nicholson L, MacEwen GD. Risk factors in Klippel-Feil syndrome. *Spine (Phila Pa 1976)*. 1994; 19(18):2110-2116.
  56. Hilibrand AS, Carlson GD, Palumbo MA, Jones PK, Bohlman HH. Radiculopathy and myelopathy at segments adjacent to the site of a previous anterior cervical arthrodesis. *J Bone Joint Surg Am.* 1999;81(4):519-528.
  57. Matsumoto M, Okada E, Ichihara D, et al. Anterior cervical decompression and fusion accelerates adjacent segment degeneration: comparison with asymptomatic volunteers in a ten-year magnetic resonance imaging follow-up study. *Spine.* 2010;35(1): 36-43.
  58. Patel A, Spiker W, Daubs M, Brodke D, Cannon-Albright L. Evidence of an inherited predisposition for cervical spondylotic myelopathy. *Spine.* 2012;37(1):26-29.
  59. Wilson JR, Patel AA, Brodt ED, Dettori JR, Brodke DS, Fehlings MG. Genetics and heritability of cervical spondylotic myelopathy and ossification of the posterior longitudinal ligament: results of a systematic review. *Spine (Phila Pa 1976)*. 2013;38(22 suppl 1): S123-S146.
  60. Pope DH, Davies BM, Mowforth OD, Bowden AR, Kotter M. Genetics of degenerative cervical myelopathy: a systematic review and meta-analysis of candidate gene studies. *J Clin Med.* 2020;9(1):282.
  61. Laliberte AM, Karadimas SK, Vidal PM, Satkunendrarajah K, Fehlings MG. miR-21 modulates inflammation and sensorimotor deficits in 2 cervical myelopathy: data from humans and animal models. *Brain Commun.* 2021;3(1):fcaa234.
  62. El-Khoury M, Mourao MA, Tobo A, Battistella LR, Herrero CFP, Riberto M. Prevalence of atlanto-occipital and atlantoaxial instability in adults with down syndrome. *World Neurosurg.* 2014;82(1-2):215-218.
  63. Castori M, Morlino S, Ghibellini G, Celletti C, Camerota F, Grammatico P. Connective tissue, Ehlers-Danlos syndrome (s), and head and cervical pain. *Am J Med Genet C Semin Med Genet.* 2015;169C(1):84-96.
  64. Matur AV, Nouri A, Huang S, et al. Complications in children with Ehlers-Danlos syndrome following spine surgery: analysis of the pediatric national surgery quality improvement program database. *World Neurosurg.* 2020;133:e473-e478.
  65. King JA, Vachhrajani S, Drake JM, Rutka JT. Neurosurgical implications of achondroplasia. *J Neurosurg Pediatr.* 2009;4(4): 297-306.
  66. Bednarik J, Sladkova D, Kadanka Z, et al. Are subjects with spondylotic cervical cord encroachment at increased risk of cervical spinal cord injury after minor trauma? *J Neurol Neurosurg Psychiatry.* 2011;82(7):779-781.
  67. Fengbin Y, Deyu C, Xinwei W, et al. Trauma-induced spinal cord injury in cervical spondylotic myelopathy with or without lower cervical instability. *J Clin Neurosci.* 2013;20(3):419-422.
  68. Matsunaga S, Kukita M, Hayashi K, et al. Pathogenesis of myelopathy in patients with ossification of the posterior longitudinal ligament. *J Neurosurg.* 2002;96(2 suppl):168-172.
  69. Kolcun JP, Chieng LO, Madhavan K, Wang MY. The role of dynamic magnetic resonance imaging in cervical spondylotic myelopathy. *Asian Spine J.* 2017;11(6):1008.
  70. Hayashi T, Wang JC, Suzuki A, et al. Risk factors for missed dynamic canal stenosis in the cervical spine. *Spine (Phila Pa 1976)*. 2014;39(10):812-819.
  71. Lao L, Daubs MD, Scott TP, Phan KH, Wang JC. Missed cervical disc bulges diagnosed with kinematic magnetic resonance imaging. *Eur Spine J.* 2014;23(8):1725-1729.
  72. Nouri A, Kato S, Badhiwala JH, et al. The influence of cervical spondylolisthesis on clinical presentation and surgical outcome in patients with DCM: analysis of a multicenter global cohort of 458 patients. *Global Spine J.* 2020;10(4):448-455.
  73. Gondar R, Nouri A, Janneli G, Schaller K, Tessitore E. Does spondylolisthesis affect severity and outcome of degenerative cervical myelopathy? A systematic review and meta-analysis. *Global Spine J.* 2020;2192568220960452.
  74. Kovalova I, Kerkovsky M, Kadanka Z, et al. Prevalence and imaging characteristics of nonmyelopathic and myelopathic spondylotic cervical cord compression. *Spine.* 2016;41(24): 1908-1916.
  75. Martin AR, De Leener B, Cohen-Adad J, et al. Can microstructural MRI detect subclinical tissue injury in subjects with asymptomatic cervical spinal cord compression? A prospective cohort study. *BMJ Open.* 2018;8(4):e019809.
  76. Smith SS, Stewart ME, Davies BM, Kotter MRN. The prevalence of asymptomatic and symptomatic spinal cord compression on magnetic resonance imaging: a systematic review and meta-analysis. *Global Spine J.* 2020;11(4):2192568220934496.
  77. Bednarik J, Kadanka Z, Dusek L, et al. Presymptomatic spondylotic cervical myelopathy: an updated predictive model. *Eur Spine J.* 2008;17(3):421-431.
  78. Kadanka Z Jr, Adamova B, Kerkovsky M, et al. Predictors of symptomatic myelopathy in degenerative cervical spinal cord compression. *Brain Behav.* 2017;7(9):e00797.
  79. Wilson JR, Barry S, Fischer DJ, et al. Frequency, timing, and predictors of neurological dysfunction in the nonmyelopathic patient with cervical spinal cord compression, canal stenosis, and/or ossification of the posterior longitudinal ligament. *Spine (Phila Pa 1976)*. 2013;38(22 suppl 1):S37-S54.
  80. Fehlings MG, Tetreault LA, Riew KD, et al. A clinical practice guideline for the management of patients with degenerative cervical myelopathy: recommendations for patients with mild, moderate, and severe disease and nonmyelopathic patients with evidence of cord compression. *Global Spine J.* 2017;7(3\_suppl): 70S-83S.
  81. Fujimori T. OPLL: disease entity, prevalence, literature research, and growth. In: Okawa A, Matsumoto M, Iwasaki M, Kawaguchi Y, eds. *OPLL: Ossification of the Posterior Longitudinal Ligament*. Springer Singapore; 2020:13-21.
  82. Doi T, Sakamoto R, Horii C, et al. Risk factors for progression of ossification of the posterior longitudinal ligament in asymptomatic subjects. *J Neurosurg.* 2020;1(aop):1-7.
  83. Katsumi K, Watanabe K, Izumi T, et al. Natural history of the ossification of cervical posterior longitudinal ligament: a three dimensional analysis. *Int Orthop.* 2018;42(4):835-842.

84. Park S, Lee DH, Ahn J, et al. How does ossification of posterior longitudinal ligament progress in conservatively managed patients? *Spine*. 2020;45(4):234-243.
85. Fujiyoshi T, Yamazaki M, Okawa A, et al. Static versus dynamic factors for the development of myelopathy in patients with cervical ossification of the posterior longitudinal ligament. *J Clin Neurosci*. 2010;17(3):320-324.
86. Matsunaga S, Nakamura K, Seichi A, et al. Radiographic predictors for the development of myelopathy in patients with ossification of the posterior longitudinal ligament: a multicenter cohort study. *Spine (Phila Pa 1976)*. 2008;33(24):2648-2850.
87. Karadimas SK, Erwin WM, Ely CG, Dettori JR, Fehlings MG. Pathophysiology and natural history of cervical spondylotic myelopathy. *Spine (Phila Pa 1976)*. 2013;38(22 suppl 1):S21-S36.
88. Yonenobu K, Abumi K, Nagata K, Taketomi E, Ueyama K. Inter-observer and intraobserver reliability of the Japanese orthopaedic association scoring system for evaluation of cervical compression myelopathy. *Spine*. 2001;26(17):1890-1894.
89. Martin A, Jentzsch T, Wilson J, et al. Inter-rater reliability of the modified Japanese orthopaedic association score in degenerative cervical myelopathy: a cross-sectional study. *Spine*. 2021.
90. Kadaňka Z, Mareš M, Bednařík J, et al. Predictive factors for mild forms of spondylotic cervical myelopathy treated conservatively or surgically. *Eur J Neurol*. 2005;12(1):16-24.
91. Martin AR, De Leener B, Cohen-Adad J, et al. Monitoring for myelopathic progression with multiparametric quantitative MRI. *PLoS One*. 2018;13(4):e0195733.
92. Zdunczyk A, Schwarzer V, Mikhailov M, et al. The corticospinal reserve capacity: reorganization of motor area and excitability as a novel pathophysiological concept in cervical myelopathy. *Neurosurgery*. 2017;83(4):810-818.
93. Wang C, Laiwalla A, Salamon N, Ellingson BM, Holly LT. Compensatory brainstem functional and structural connectivity in patients with degenerative cervical myelopathy by probabilistic tractography and functional MRI. *Brain Res*. 2020;1749:147129.