



Avoiding Complications on the Upper Face Treatment With Botulinum Toxin: A Practical Guide

André Borba¹ · Suzana Matayoshi¹ · Matheus Rodrigues²



Received: 5 May 2021 / Accepted: 8 July 2021 / Published online: 2 August 2021

© Springer Science+Business Media, LLC, part of Springer Nature and International Society of Aesthetic Plastic Surgery 2021

Abstract

Background Currently, botulinum toxin (BoNT) injections are the most commonly performed non-invasive procedure for rejuvenation on the upper face. The therapeutic use of botulinum toxin has generally been safe and well tolerated. Adverse effects are considered mild, transient, and self-limited. However, as with all other injectable procedures, this one is also susceptible to adverse events and complications. When the safety zones are respected, the chance of any of these complications is practically null.

Thus, this review aims to describe the main complications of treatment with BoNT on the upper face and to present a practical guide based on current evidence on how to avoid them.

Methods The literature research considered published journal articles (clinical trials or scientific reviews). Studies were identified by searching electronic databases (MEDLINE and PubMed) and reference lists of respective articles.

Results The main complications secondary to BoNT injections on the upper face are: ptosis of eyelid or eyebrow, eyebrow asymmetry, diplopia, Lakeopthalmos, Palpebral ectropion, and prominence of the palpebral bags. To avoid such complications, it is necessary to have knowledge of the anatomy of this region and adequate and individualized planning based on the existing patterns of the frontalis muscle, glabella, and crow's feet. This review presents the specificities of each of these regions and practical suggestions to obtain satisfactory results, avoiding complications.

Conclusion Particularly on the upper face treatment with BoNT offers predictable results, has few adverse effects, and is associated with high patient satisfaction. However, it is suggested that the commented parameters and safety areas be incorporated into daily practice so that the possibilities of complications are minimized as much as possible.

Level of Evidence III This journal requires that authors assign a level of evidence to each article. For a full description of these Evidence-Based Medicine ratings, please refer to the Table of Contents or the online Instructions to Authors www.springer.com/00266.

✉ André Borba
prof.dr.andreborba@gmail.com

Suzana Matayoshi
Suzana.Matayoshi@gmail.com

Matheus Rodrigues
matheus.rodrigues@unemat.br

¹ Department of Ophthalmology, Division of Oculoplastic, University of São Paulo Medical School, 255 Eneas Aguiar Street Office 4079, São Paulo, Zipcode 05403000, Brazil

² Department of Medicine, Division of Dermatology, Mato Grosso State University, Tancredo Neves Avenue 1095, Cáceres, Mato Grosso 78200000, Brazil

Keywords Botulinum toxin · Cosmetic surgery · Upper face

Introduction

Currently, botulinum toxin injections are the most commonly performed non-invasive procedure for rejuvenation on the upper face [1]. Hyperdynamic rhytids, particularly on the upper face, not only can be visually undesirable but, over time, also can result in dermal atrophy and

corresponding static facial rhytids. These changes, in concert with dermal photoaging, contribute to the stigmata of the aging face [2]. Since the introduction of botulinum toxin (BoNT) for alleviating glabellar rhytids in the 1990s to the present day, there has been an exponential growth in the use of neurotoxins for cosmetic purposes [3]. During the SARS-CoV2 pandemic, the importance of the upper face was observed. This region can demonstrate expressions without the need for words, expressions such as surprise, anger, joy, and concern. In the current context, with the constant need to wear facial masks, one of the few recognizable facial features was those expressed by the upper face region. In this context, an important increase of patients seeking rejuvenation techniques for this region has been observed, denoting the importance of discussing good practices in the application of Botulinum Toxin.

BoNT is an endotoxin produced by the anaerobic bacterium *Clostridium botulinum*. This endotoxin is a dimeric protein that acts at the neuromuscular junction by blocking the release of acetylcholine, thus decreasing the contraction of the motor unit [4]. Although the intracellular targets of the toxins are variable, they all ultimately prevent the release of membrane-bound acetylcholine at the neuromuscular junction of striated muscles and thus produce chemical denervation and paralysis of the muscles. The toxin is rapidly (within hours) and irreversibly bound to the presynaptic neuron at the neuromuscular junction. The botulinum toxin is internalized and then this action may not be complete for 2 weeks and effectively destroys the affected neuromuscular junction, causing muscular paralysis [5, 6]. There is an ongoing turnover of neuromuscular junctions; however, that is enhanced by toxin exposure such that muscular function begins to return at approximately 3 months and is usually complete by 6 months [2, 5].

The therapeutic use of botulinum toxin has generally been safe and well tolerated. Adverse effects are considered mild, transient, and self-limited [7]. However, as with all other injectable procedures, this one is also susceptible to adverse events and complications. There are no reports of serious or fatal complications from the cosmetic use of botulinum toxin. The complications depend on the technique used, and for this reason, it is important to have adequate knowledge and training on the application technique [8].

When the safety zones are respected, the chance of any of these complications is practically null. However, these effects can also occur by diffusion of the drug to non-target muscles, depending on the product used and the area treated. This can alter the location of the clinical effect and increase the adverse effects [9, 10]. Botulinum toxin can migrate inadvertently due to multifactorial causes, involving adjacent muscles and having a series of unpleasant side

effects. Some factors impact the migration profile of botulinum toxins, such as the application area, the dilution volume, specific characteristics of the product used, doses, and application technique [11–13].

Full knowledge of the anatomy of the facial muscles, proper marking, injection techniques, and knowledge of the mechanism of action of the product being used are the best ways to avoid such problems. Thus, the purpose of this review is to present the main complications and most common unwanted effects from the use of botulinum toxin and to demonstrate the safe areas for application of BoNT on the upper face.

Methods

This is a narrative literature review, exploring qualitative and quantitative data from studies using a systematic search on complications associated with BoNT in the upper face, aiming to present the main complications and a practical guide on how to avoid them.

The research question was formulated using the PICOS strategy [14], which represents an acronym for Population, Intervention, Comparison, Outcomes, and Study design; from the application of the strategy, the guiding question was defined as: “What are the main complications of BoNT application in the upper face and how to avoid them?”

The search strategy included the following descriptors: (botulinum toxin; onabotulinumtoxinA; incobotulinumtoxinA; aesthetic) AND (complication; side effects; safety). A literature search was conducted using two electronic databases (MEDLINE and PubMed). Manual study searches were also performed and considered using the reference list of articles included during the search process.

Inclusion criteria were: studies published between January 2000 and December 2020 in English, which described complications associated with the cosmetic use of botulinum toxin, as well as studies that presented ways to avoid them. All types of studies were defined as eligible, as follows: case reports or case series, retrospective studies, prospective studies, randomized clinical trials, literature reviews, protocols, and guidelines. Studies describing complications secondary to other than cosmetic BoNT applications were excluded.

The selection of studies was performed independently by the two authors. In the first step, the titles and abstracts of the studies found from the search described in the previous item were read, and the eligibility criteria previously defined in this review were applied. The studies selected in the first step were read in their entirety, and again the

eligibility criteria were applied, determining, then, the inclusion or not in the research.

After the critical evaluation of the selected articles, the authors organized the presentation of the results descriptively in two main topics, the first describing the main complications described in the literature, and the second presenting a practical guide on how to avoid them.

Complications and unwanted effects

Ptosis of eyelid or eyebrow is defined as the downward displacement of these anatomical entities due to disturbance in the agonist and antagonist muscle functions [12]. Ptosis in the upper eyelid, which can range from millimeters to total occlusion of the eye, occurs due to the involvement of the upper eyelid levator muscle. Ptosis of the upper eyelid is also seen when injecting the toxin in and around the glabella due to migration of injected toxin through the orbital septum leading to weakening the levator palpebrae superioris muscle [8]. It is commonly seen when botulinum toxin is injected close to the bony supraorbital margin at the mid-pupillary line and when large volumes of diluted toxin are injected in the area [12]. Ferreira et al. (2004) suggest the use of alpha-adrenergic agonist eye drops such as apraclonidine as a treatment option for widening the eyelid gap [15]. Other eye drops of the same class can also be used, such as naphazoline or phenylephrine [16].

Eyebrow ptosis is a common complication arising in the treatment of the frontalis muscle for addressing horizontal forehead lines with botulinum toxin. This complication can be avoided by staying at least 2–3 cm above the supraorbital margin or 1.5–2 cm above the eyebrow while injecting into the frontalis [9, 17]. In contrast, the elevated appearance of the tail of the eyebrow may occur by non-blocking of the frontalis muscle laterally combined with treatment of the muscle medially; to avoid this complication, it is advisable to treat the elevator and the depressors at the same time, to avoid unopposed action of one group of muscle. Sethi et al (2020) in a cohort of patients reported the overall incidence of eyelid ptosis equals 0.71% and eyebrow ptosis 0.98% [12].

Another complication that has been reported is eyebrow asymmetry, which can result from the site and amount of application difference or anatomical variations in the patient. The “Spock” or “Memphisto” brow is a common asymmetry that presents as a curvature of the lateral brow due to the imbalance arising from the deactivation of the central region of the frontalis and the activity of the lateral region of this muscle, which raises the tail of the brow. This complication can be corrected by adding a little more BoNT in the active area of the muscle, i.e., the lateral region [17, 18].

Other more rare complications can occur, such as diplopia, which can be caused by the diffusion of the toxin or the application into the orbit, affecting the extrinsic muscles of the eye, usually the lateral rectus muscle. Lakeophthalmos can occur by paralysis of the orbicular orbital muscle, leading to weakening and difficulty in maintaining muscle function properly, causing lack of complete occlusion of the eyes and ocular dryness. It should be treated with eye drops and lubricating gels. Palpebral ectropion can also occur in patients with palpebral laxity and with injection in the pre-tarsal region near the margin of the lower eyelids. The prominence of the palpebral bags may occur due to greater laxity of the orbicular muscle and consequent projection of the fat bags. Moreover, the lymphatic drainage in this region may be impaired and cause eyelid edema, especially in cases of patients with great orbicular muscle laxity and long wrinkles that extend to the malar region [3, 5, 19].

As noted, complications secondary to botulinum toxin injection can be avoided with appropriate planning and proper demarcation of safety areas. Figure 1 shows risk areas for BoNT injection along with the possible consequences of inadvertent application in these regions.

Safety and marking areas for Botulinum Toxin application on the upper face

Facial muscles have a unique mechanism that allows expressive changes and is absolutely different from all other types of muscles in the human body. The muscles of facial mimicry create a variety of facial expressions, allowing human beings to communicate effectively through emotions, without the need to use words. Before we start talking about each muscle, we would like to remind you of the main feelings that we can express with our face: joy, suspicion, anger, disgust, surprise, fear, and in between there are countless attitudes in between [3].

Fundamentally, we can understand the patient’s expectations, whether expressive or not, and how a certain facial muscle group would react with treatment in an individualized way, considering these feelings.

The muscles of facial expression are inserted directly on the skin surface, so repetitive contraction causes characteristic rhytids to form perpendicular to the direction of the vector of contraction [2, 16]; Fig. 2 shows the force vectors of the facial muscles.

Most cosmetic applications of BoNT involve the upper face, and it is usually the motivation for facial aesthetic treatment. In this area, the most common manifestations of aging of the upper face occur: horizontal forehead lines, glabella expression lines, and periocular (“crow’s feet”) wrinkles.

Figure 1. Risk areas for botulinum toxin injection and possible complications of inadvertent application in these regions.

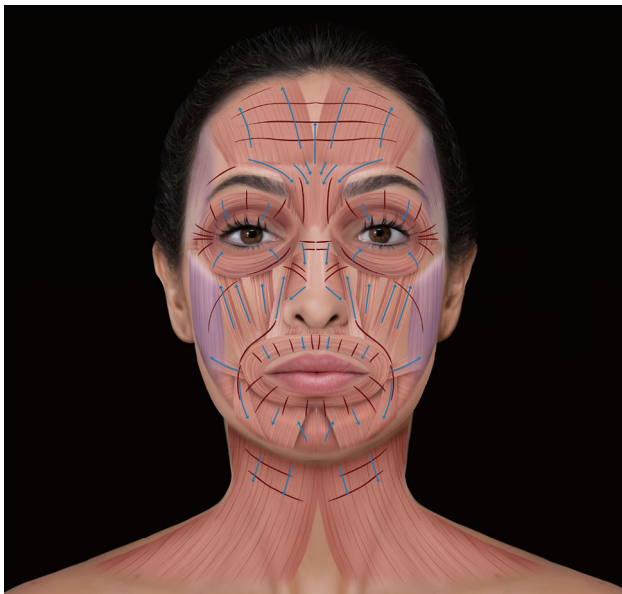
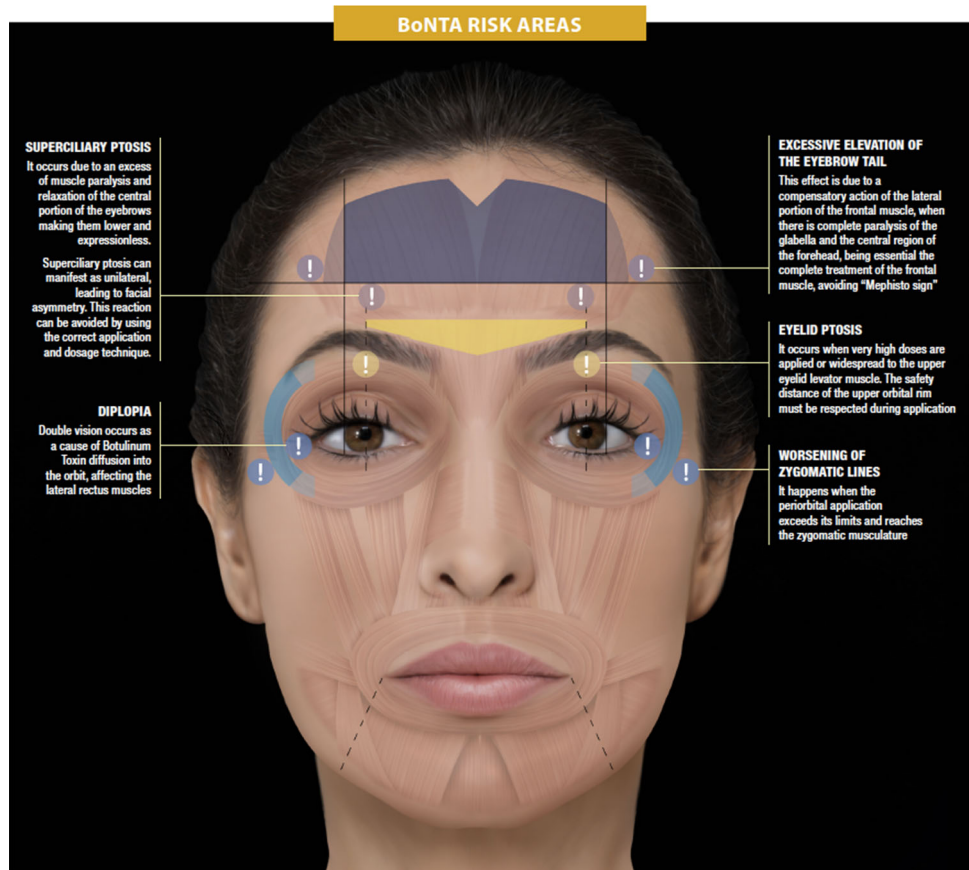


Figure 2. Muscle strength vectors of the facial muscles. *Legend:* The arrows correspond to the direction of the muscle force. The expression lines created by muscle contraction are perpendicular to the vectors shown.

The facial muscles of the upper face that are targets for botulinum toxin therapy and the safety areas for the

aesthetic treatment of each of them are presented in Fig. 3, and the identification and marking of each of these points will be detailed below. Knowledge about the treatment areas and the muscle corresponding to that area is extremely important for successful treatment. Table 1 shows the main areas of the upper face, which muscle is the target, and what should be considered when blocking each one.

BoNT is administered in “units.” One unit of BoNT-A represents the lethal dose in 50% of a group of Swiss Webster mice within 3 days of intraperitoneal injection [2, 20]. Extrapolated to a 70-kg person, the median lethal dose is estimated to be between 2500 and 3000 units. Although the exact dose of toxin known to cause toxicity is unknown, it is generally agreed that single doses of BoNT-A should not exceed 500 units [21].

Although the amounts of points and units are variable according to the needs of each patient, it is suggested that for longer duration and high patient satisfaction regarding the results for the upper face treatment, the standard and ideal botulinum toxin application plan would be using the total of 64 units of Botox®, combining: standard “U” glabella treatment (ranging from 12 U to 40 U), frontal muscle treatment—total pattern (ranging from 8 U to 25 U), and the periorbital lines (ranging from 6 U to 15 U per side). Figure 4 presents a practical suggestion for the

Figure 3. Muscles of the upper face and safety areas for BoNT application

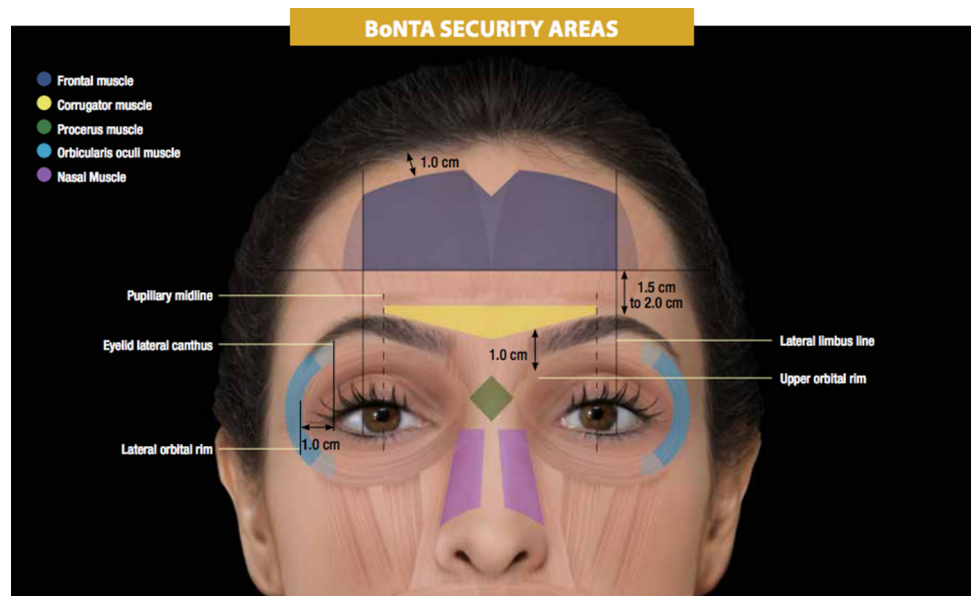


Table 1 Treatment areas with a focus on the upper face

Treatment areas	Treated muscle	What to consider in this treatment?
Frontal lines	Frontalis	Softening of horizontal forehead lines and weakening of the single eyebrow lift
Repositioning of the eyebrows	Frontalis and orbicularis muscles, mainly corrugators and procerus secondarily	Frontalis: its movement must be maintained according to the need to raise the eyebrows Orbicularis oculi: its treatment allows elevation of the eyebrow tails Procerus and corrugators: its treatment allows elevation of the medial portion of the eyebrows
Glabella	Corrugators and Procerus	Corrugators: smoothing of vertical lines and eyebrow distancing Procerus: smoothing of horizontal lines
Crow’s Feet Lines	Orbicularis oculi	Smoothing of periorbital lines and lifting of eyebrow tails

distribution of this 64 U. Although this standard dosage is still commonly used and may serve as a guide to the novice injector, many clinicians have moved to tailoring injection points and dosage to the individual. Considerations should be made to muscle strength, anatomy (rhytide pattern), baseline asymmetries as well as patient desires when deciding on dose and injection pattern [3].

In the following topics, we will present how to perform the appropriate demarcation of the safety areas shown in Fig. 3, as well as the specifics of each of the regions and how to individualize the approach to them.

Frontalis Muscle

Located in the upper third of the face, the frontal muscle originates in the aponeurotic galea below the coronal suture and attaches to the skin in the region of the eyebrow,

intertwining with fibers of the procerus, corrugator, and orbicularis oculi muscles [22]. Directed vertically, it raises the eyebrow and is responsible for the mimicry of surprise, interest, or concern. Over time, however, repeated contractions cause horizontal wrinkles to form in the overlying skin. When they persist even at rest or occur markedly during facial expression, they are called hyperfunctioning facial lines and are generally interpreted as a sign of aging [10].

The frontalis muscle exerts an important influence on the shape and position of the eyebrows, since it pulls them cranially, as opposed to the depressor muscles (procerus, corrugator, brow depressor, and orbicularis oculi). The purpose of treatment with BoNT in this region is to soften expression lines without causing brow ptosis or eliminating the entire upper face expression. To avoid complications, the most recent guidelines and consensus suggest that the

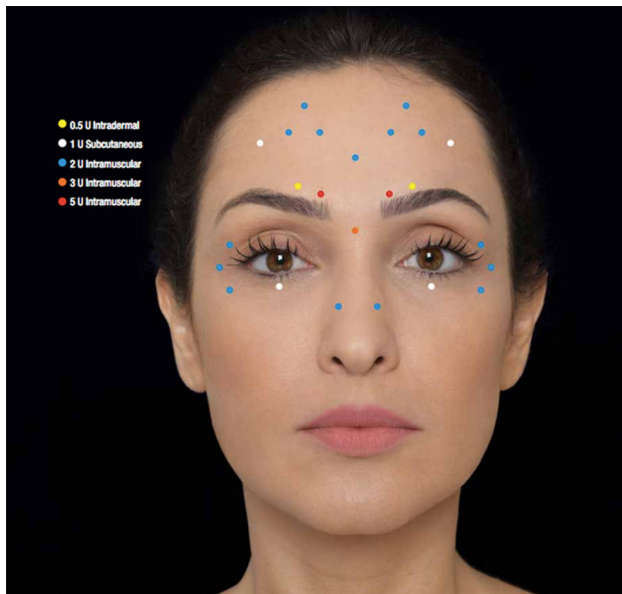


Figure 4. Aesthetic treatment of the upper face with BoNT—suggested standard dot distribution, dose, and application plan

application should be performed 2.5–3 cm above the orbital rim, respecting the limit of 1–2 cm from the upper eyebrow line [2, 7, 10]; as shown in Fig. 5a. As for the upper limit, 1 cm from the region of the implantation line of the beginning of the hairline is respected (Fig. 5b).

Because it is a flat and wide muscle, which covers almost the entire length of the upper face, for good coverage of the area of hyperkinesis, it is important to take into account that 2 units of Botox®, when injected intramuscularly in dilution 100 U/2 mL of saline 0.9%, produce a halo of action of about 1.5 cm [23]. Thus, when planning the treatment, the points of application should be distanced, respecting this halo, thus producing effective and lasting muscle relaxation.

The reshaping and repositioning of the eyebrow can be performed from the reduction of the capacity of contraction

of the depressor muscles of the upper face, as well as through changes in the vectors of traction of the frontalis muscle. The treatment of the central portion of the frontalis muscle, with preservation of the contraction capacity of its lateral portion, favors the ascension of the eyebrow tail, a condition sought by many women. In men, the performance of a lateral stitch, blocking the lateral portion of the frontal muscle is usually necessary to prevent the rise of the eyebrow tail and the feminization of the look. This stitch can be intradermal, subcutaneous, or intramuscular, and the more superficial it is, the smaller the block produced. For women who practice a lot of physical activity and for men, since the frontalis is usually more potent, a higher number of units per spot should be considered, as well as a shorter interval between reapplications.

Different anatomical characteristics and varied cinematic spectrums determine contraction patterns of the frontal muscle peculiar to each person. This knowledge is essential for the choice of the most appropriate application points, providing each patient with an individualized approach [24]. Braz and Sakuna (2010) developed a classification of frontal lines, subdividing them into total, medial, lateral and asymmetric patterns, and the injector must take into account these patterns to standardize the applications. Figure 6 shows an example of each of these patterns with the injection points.

The total pattern (Fig. 6a) is the most frequently observed type, where the horizontal rhytids are present in the center of the forehead advancing laterally beyond the mediopupillary line to the end of the tail of the eyebrows. For these patients, we suggest the application points along with the entire musculature, with larger doses in the central region and smaller ones at the lateral extremities. We also suggest always treating the frontalis muscle with the glabella, whose muscles are depressors and antagonists of the frontalis, since the frontalis is the only elevator of the upper third of the face and fundamental to the positioning of the eyebrows. We reaffirm the recommendation to respect the

Figure 5. Demonstration of the safety marking (**B**) at the lowest allowed point of the right belly of the frontalis muscle and (**B**) the uppermost point of the right belly of the frontalis muscle. *Legend:* The lower limit of the injection should be at least 1–2 cm above the upper eyebrow line, and the upper limit should be 1 cm below the implantation line region of the scalp.

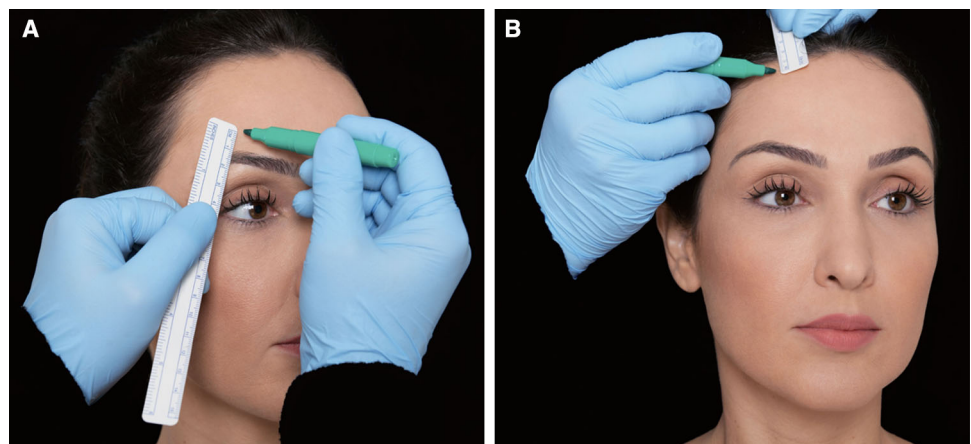
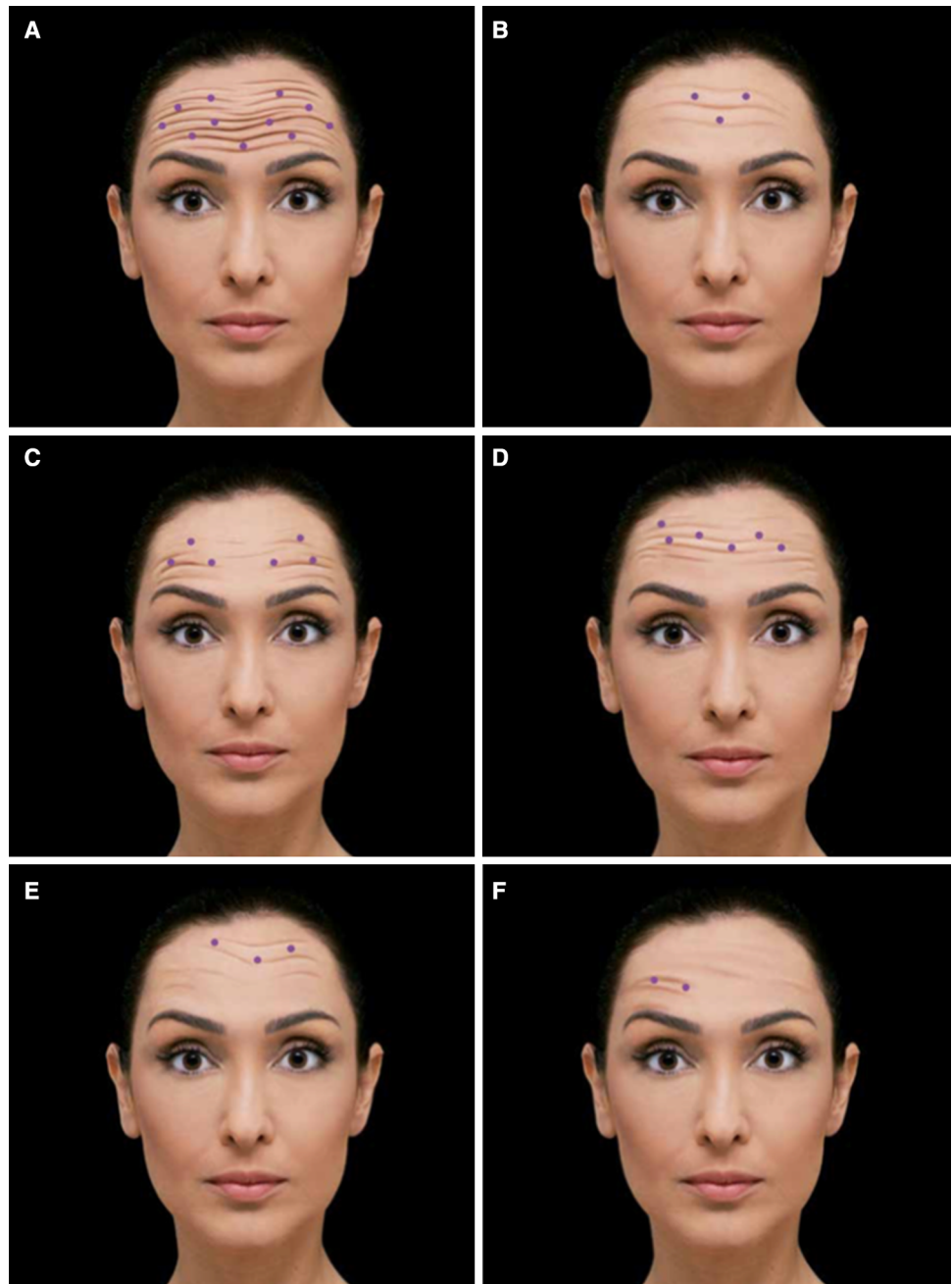


Figure 6. Patterns of frontal lines according to Braz and Sakuna's (2010) classification and BoNT injection points. *Legend:* **a** Total pattern, **b** Medial pattern; **c** Lateral pattern; **d** Lateral pattern with a predominance of the rhytids on the upper part and the extremities of the frontalis muscle on the right; **e** Medial pattern with a predominance of rhytids on the extremities of the frontalis muscle on the left; **f** Lateral pattern, with a predominance of the rhytids on the right



space of 1.5 cm above the eyebrow (Fig. 3), in the mid-pupillary line, to avoid upper eyelid ptosis if the eyelid levator muscle is affected.

The medial pattern (Fig. 6b) was described as the second most frequent. In this pattern, the rhytids are concentrated in the central region of the forehead, limited to the mediopupillary lines. Braz and Sakuna (2010), who suggested these patterns, reported that patients presenting this pattern most often also have rectified eyebrows, with ptosis of the tail in some cases. It is then suggested, in this group, to apply one to three points, as presented in Fig. 6b, in the shape of an inverted triangle. To avoid brow ptosis or

accents of these, we suggest avoiding applications outside the mediopupillary lines.

The lateral pattern (Fig. 6c) is less frequent. In this one, horizontal rhytids predominate on the sides of the forehead, mostly after the mediopupillary line, with less intensity (and sometimes absent) in the medial frontal region. A predominance of arched brow positioning was observed in patients with a lateral pattern. As for the application points, it is suggested to use low doses in the points described in Fig. 5c, so as not to compromise the movement of the eyebrow tail.

A small percentage of patients present asymmetries within the described patterns, and these variations should be taken into consideration when marking the points. Figure 6d, e, and f shows some of these asymmetries and the application points [24].

Glabella

Usually, in daily practice, the glabella is the region most treated by botulinum toxin. The main muscles that form the glabellar complex include corrugators and orbicular of the eyelid (approximate and depress the eyebrows), procerus and depressors of the eyebrow (depress), and the inferior fibers of the frontalis (elevate the eyebrows). Muscle activity causes hyperkinetic lines perpendicular to the direction of muscle contraction (see Fig. 2), forming unwanted horizontal, vertical, and oblique wrinkles.

The treatment of glabellar region focuses on the attenuation of mainly the procerus and corrugator supercillii muscles. The corrugator may present as a narrow, short, oblique muscle located at the medial end of the supra-orbital rim or as a long, “fan-shaped” muscle spreading laterally over the upper orbital rim. Contraction of the procerus muscle lowers the medial aspect of the eyebrow and is the main contributor to the horizontal lines, whereas contraction of the corrugator muscle draws down the medial aspect of the eyebrow and is primarily responsible for vertical lines [10]. The brow depressor muscle is, for many, part of the corrugator muscle, extending from the nasal portion of the frontal bone to the skin of the medial portion of the brow, its belly being positioned about 1 centimeter above the medial canthal ligament [23]. It thus is important that the injection points are projected above 1 cm from the medial canthal ligament, as shown in Fig. 3.

Many practitioners consider glabellar wrinkles to be identical in most individuals and therefore use classical models of application on the glabella, with three, five, or seven points distributed on the corrugator, procerus and/or orbicular eyelid muscles. The descriptions of universal models do not take into account the individual characteristics that are present in the different muscle contraction patterns. To individualize the management and obtain more satisfactory results, it is important to identify the patterns of the glabellar lines and then plan the injection points. Almeida et al. (2011) identified 5 patterns of the glabellar lines, pattern V, U, omega, converging arrows, and inverted omega [23]. Figure 7 demonstrates each one and the suggested points for an individualized injection.

The “V” pattern (Fig. 7a) is the most common, where approximation and depression of the medial part of the eyebrows are observed, ranging from moderate to severe, in greater intensity than the “U” pattern group. At repose, the eyebrows of the patients are usually more horizontal or

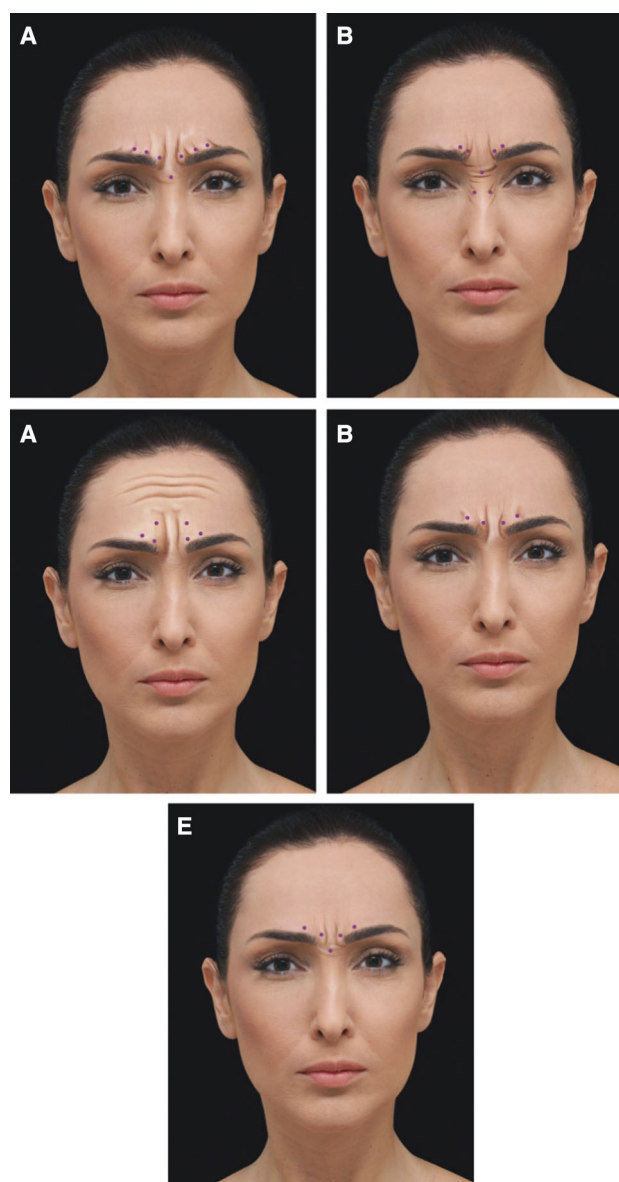


Figure 7. Patterns of glabellar lines proposed by the classification of Almeida et al. (2011) and injection points of BoNT. *Legend:* **a** V-pattern; **b** U-pattern; **c** “omega” pattern; **d** Pattern in “converging arrows”; **e** Pattern in “inverted omega”

rectified and of lower location. Besides the force exerted by the corrugators and the procerus, there is important participation of the medial part of the orbicular. Therefore, these patients usually need more doses of botulinum toxin and more injection points. We recommend injecting at 7 points, as shown in Fig. 7a, with higher doses concentrated in the procerus and corrugators.

The “U” pattern is usually the second most common. Patients in this group predominantly have a discrete approximation and depression of the glabella, with the resulting movement forming a U-shape. At rest, the

eyebrows are usually arched. We recommend treatment with the classic five-point injection points, as shown in Fig. 7b.

In the “Omega” pattern, the prominent movements are of approximation and medial elevation of the glabella, forming the Greek letter omega. Lateral depression of the eyebrows occurs simultaneously. The dominant muscles are the corrugators, the medial part of the orbicularis, and the frontalis, with little contraction of the procerus. The authors who proposed the classification suggest that the best approach for these cases is to inject BoNT into the corrugators and orbicularis of the eyelids in the medial part of the frontalis muscle (Fig. 7c), with larger doses in the corrugators and smaller doses in the frontal and orbicular points. We recommend that treatment in the procerus be minimal, often not requiring an application.

In the “converging arrows” pattern, there is mainly approximation of the eyebrows, with little or no medial or lateral depression or elevation. A resulting final movement is a horizontal approach. The muscles involved are the corrugators and the medial part of the orbicular. We recommend that the application scheme should be more horizontal, focusing on the muscles involved, as shown in Fig. 7d, not requiring application points on the procerus or frontalis.

The “inverted omega” pattern is the least frequent, with a predominantly depressing movement over an approximating one. The muscles involved are mainly the procerus, the brow depressor, the inner part of the eyelid orbicular, and eventually the nasal (although not traditionally characterized as a glabellar muscle). The most appropriate treatment is done with larger doses in the procerus and the depressors of the eyebrow, and smaller doses in the internal part of the eyelid orbicular, and injection points may be associated with the nasal muscle (Fig. 7e).

Global Aesthetics Consensus Group recommended lower minimum doses and numbers of injection points (e.g., three to seven injection points for the glabella with total dosage of 12–40 units in most cases, and doses less than 12 units when indicated) [7]. The Global Aesthetics Consensus cites two randomized, double-blind, placebo-controlled studies of mild resting glabellar lines that demonstrated efficacy in elimination with a 20-unit dose of onabotulinumtoxinA [25]. In addition, the authors highlighted a meta-analysis of four trials with 621 patients found that treatment of 20 units of glabellar lines resulted in sustained clinical benefit for 4 months in more than half of the responders [26].

Crow’s Feet Lines

Lateral canthal wrinkling (crow’s feet) may represent one of the earliest signs of aging. Repeated contraction of

numerous facial muscles involved in smiling and squinting, notably the orbicularis oculi muscles, leads to formation of lateral canthal lines, also known as crow’s feet lines. These lines radiate from the lateral canthus and initially appear on smiling but may become static because of aging, photo-damage, and skin remodeling [10, 27]. The orbicularis oculi muscle of the eye is a flat, broad, sphincter muscle. Its main bundles are: palpebral, orbital and lacrimal portions. Botulinum toxin-A, when applied to the lateral peripalpebral region, produces the relaxation of the lateral portion of the orbicular muscle of the eye and, consequently, the control of hyperkinetic wrinkles in the region [3].

The injection in this area should be adapted to the wrinkle pattern; however, the injections should be superficial, respecting the limit of 1 cm from the orbital border and 1.5 cm from the lateral canthus to prevent the product from spreading to undesired areas, reaching, for example, the lateral rectus muscle, innervated by the abducens nerve, which can lead to paresis of this muscle and diplopia (Figs. 1, 3). A total dose of 10 to 30 units can typically be given divided between 2 and 3 injection sites per side. The pattern of wrinkling sometimes requires modification of this pattern. Again, treatment must be individualized. The dosage depends on the depth and extent of the hyperdynamic rhymes, and to determine the distribution of the points, the patient is asked to make a forced smile. Care should be taken not to inject too inferiorly. Injection of the zygomatic may affect the tone of the upper lip, resulting in an asymmetry of the upper lip [28].

Conclusion

Botulinum toxin injection for the treatment of facial wrinkles is one of the most frequently performed cosmetic procedures in Cosmiatry. Particularly on the upper face treatment with BoNT offers predictable results, has few adverse effects, and is associated with high patient satisfaction. Complications with cosmetic botulinum toxin injections are uncommon, and those that occur are usually mild and transient. However, it is suggested that the commented parameters and safety areas be incorporated into daily practice so that the possibilities of complications are minimized as much as possible. The primary aim of our study was to present a practical guide to avoiding complications in botulinum toxin injection; for this, we conducted a narrative review on the topic from a systematic search of the literature. Thus, different protocols or strategies were not compared for different clinical outcomes. We suggest to the next authors who will study the theme to conduct systematic reviews of the literature to contemplate this objective.

Financial support This research has no financial support.

Declarations

Conflict of interest Dr. André Borba reports grants from Allergan, Inc. as a speaker. There are no conflicts of interest to declare regarding this article. Dr. Suzana Matayoshi has nothing to disclose. Matheus Rodrigues has nothing to disclose.

Ethical approval This article does not contain any studies with human participants or animals performed by any of the authors.

Informed consent Patients provided written consent for the use of their images.

References

- de Maio M, Wu WTL, Goodman GJ, Monheit G (2017) Facial assessment and injection guide for Botulinum Toxin and injectable hyaluronic acid fillers: Focus on the Lower Face. *Plast Reconstr Surg* 140:393e–404e. <https://doi.org/10.1097/PRS.0000000000003646>
- Qaqish C (2016) Botulinum toxin use in the upper face. *Atlas Oral Maxillofac Surg Clin* 24:95–103. <https://doi.org/10.1016/j.cxom.2016.05.006>
- Borba A, Matayoshi S (2018) Facial rejuvenation techniques: botulinum toxin and MD Codes TM, 1st edn. Buzz Editor Ltda, São Paulo (Brazil)
- Erickson BP, Lee WW, Cohen J, Grunebaum LD (2015) The role of neurotoxins in the periorbital and midfacial areas. *Facial Plast Surg Clin North Am* 23:243–255. <https://doi.org/10.1016/j.fsc.2015.01.010>
- Klein AW (2004) Contraindications and complications with the use of botulinum toxin. *Clin Dermatol* 22:66–75. <https://doi.org/10.1016/j.clindermatol.2003.12.026>
- Feily A, Fallahi H, Zandian D, Kalantar H (2011) A succinct review of botulinum toxin in dermatology; update of cosmetic and noncosmetic use. *J Cosmet Dermatol* 10:58–67. <https://doi.org/10.1111/j.1473-2165.2010.00545.x>
- Sundaram H, Signorini M, Liew S et al (2016) Global aesthetics consensus. *Plast Reconstr Surg* 137:518e–529e. <https://doi.org/10.1097/01.prs.0000475758.63709.23>
- Kassir M, Gupta M, Galadari H et al (2020) Complications of botulinum toxin and fillers: A narrative review. *J Cosmet Dermatol* 19:570–573. <https://doi.org/10.1111/jocd.13266>
- Klein AW (2002) Complications and adverse reactions with the use of botulinum toxin. *Dis Mon* 48:336–356. <https://doi.org/10.1053/mda.2001.25964>
- de Maio M, Swift A, Signorini M, Fagien S (2017) Facial assessment and injection guide for Botulinum Toxin and injectable hyaluronic acid fillers. *Plast Reconstr Surg* 140:265e–276e. <https://doi.org/10.1097/PRS.0000000000003544>
- Klein AW (1998) Dilution and storage of Botulinum Toxin. *Dermatologic Surg* 24:1179–1180. <https://doi.org/10.1111/j.1524-4725.1998.tb04094.x>
- Sethi N, Singh S, DeBouille K, Rahman E (2020) A review of complications due to the use of Botulinum Toxin A for cosmetic indications. *Aesthetic Plast Surg*. <https://doi.org/10.1007/s00266-020-01983-w>
- Jia Z, Lu H, Yang X et al (2016) Adverse events of Botulinum Toxin type A in facial rejuvenation: a systematic review and meta-analysis. *Aesthetic Plast Surg* 40:769–777. <https://doi.org/10.1007/s00266-016-0682-1>
- Higgins JPT, Thomas J, Chandler J, Cumpston M, Li T, Page MJ, Welch VA (eds) (2019) *Cochrane handbook for systematic reviews of interventions*, 2nd edn. John Wiley & Sons, Chichester (UK)
- Ferreira MC, Salles AG, Gimenez R, Soares MFD (2004) Complications with the use of Botulinum Toxin Type A in facial rejuvenation: report of 8 Cases. *Aesthetic Plast Surg* 28:441–444. <https://doi.org/10.1007/s00266-004-0031-7>
- Omoigui S, Irene S (2005) Treatment of ptosis as a complication of Botulinum Toxin Injection. *Pain Med* 6:149–151. <https://doi.org/10.1111/j.1526-4637.2005.05029.x>
- Carruthers A, CARRUTHERS J, (1998) Clinical indications and injection technique for the cosmetic use of Botulinum A Exotoxin. *Dermatologic Surg* 24:1189–1194. <https://doi.org/10.1111/j.1524-4725.1998.tb04097.x>
- Vartanian AJ, Dayan SH (2005) Complications of botulinum toxin A use in facial rejuvenation. *Facial Plast Surg Clin North Am* 13:1–10. <https://doi.org/10.1016/j.fsc.2004.04.008>
- Klein AW (2001) Complications and adverse reactions with the use of botulinum toxin. *Semin Cutan Med Surg* 20:109–120. <https://doi.org/10.1053/sder.2001.25964>
- Lowe NJ, Shah A, Lowe PL, Patnaik R (2010) Dosing, efficacy and safety plus the use of computerized photography for botulinum toxins type A for upper facial lines. *J Cosmet Laser Ther* 12:106–111. <https://doi.org/10.3109/14764170903480013>
- Sorensen EP, Urman C (2015) Cosmetic complications: rare and serious events following botulinum toxin and soft tissue filler administration. *J Drugs Dermatol* 14:486–491
- Abramo AC, Do Amaral TPA, Lessio BP, De Lima GA (2016) Anatomy of forehead, glabellar, nasal and orbital muscles, and their correlation with distinctive patterns of skin lines on the upper third of the face: reviewing concepts. *Aesthetic Plast Surg* 40:962–971. <https://doi.org/10.1007/s00266-016-0712-z>
- Trindade De Almeida A, Secco L, Carruthers A (2011) Handling Botulinum toxins. *Dermatologic Surg* 37:1553–1565. <https://doi.org/10.1111/j.1524-4725.2011.02087.x>
- Braz AV, Sakuma TH (2010) Patterns of contraction of the frontalis muscle: a pilot study. *Surg Cosmet Dermatol* 2(3):191–194
- Carruthers A, Carruthers J, Lei X et al (2010) Onabotulinum-toxinA treatment of mild Glabellar lines in repose. *Dermatologic Surg* 36:2168–2171. <https://doi.org/10.1111/j.1524-4725.2010.01708.x>
- Glogau R, Kane M, Beddingfield F et al (2012) Onabotulinum-toxinA: a meta-analysis of duration of effect in the treatment of Glabellar Lines. *Dermatologic Surg* 38:1794–1803. <https://doi.org/10.1111/j.1524-4725.2012.02582.x>
- Charles Finn J, Cox SE, Earl ML (2003) Social implications of hyperfunctional facial lines. *Dermatologic Surg* 29:450–455. <https://doi.org/10.1046/j.1524-4725.2003.29112.x>
- Matarasso SL, Matarasso A (2001) Treatment guidelines for Botulinum Toxin Type A for the periorcular region and a report on partial upper lip ptosis following injections to the lateral Canthal Rhytids. *Plast Reconstr Surg* 108:208–214. <https://doi.org/10.1097/00006534-200107000-00033>

Publisher's Note Springer Nature remains neutral with regard to jurisdictional claims in published maps and institutional affiliations.