

# Hybrid Technique for Removal of Eroded Adjustable Gastric Band

Mario Rodarte-Shade, MD,<sup>1</sup> Gustavo Torres Barrera, MD,<sup>2</sup> Jose H. Flores Arredondo, MD,<sup>3</sup>  
Roberto Rumbaut Diaz, MD<sup>1,4</sup>

## ABSTRACT

**Background:** Intra-gastric migration is a late and rare postsurgical complication in patients with gastric band placement. Gastric band erosion rate has previously been described to be 1.46%. In this report, we present the case of a 43-y-old male with gastric band erosion undergoing a laparoendoscopic retrieval of the gastric band, due to intra-gastric migration.

**Method:** A hybrid procedure was performed to retrieve the gastric band. A laparoscopic approach was initially used to extract the connecting tube. Endoscopy was then performed to cut the gastric band with a specific cutter system and was subsequently extracted transorally.

**Results:** The postoperative course was uneventful. Clear liquids were started on day 1, and the patient was discharged on day 2.

**Discussion:** The purpose of this study was to describe a hybrid technique for the removal of an eroded gastric band, as a safe and feasible option in patients with band erosions.

**Conclusion:** The laparoscopic approach enables safe extraction of the connecting tube, while endoscopy allows extraction of the band without creating a large incision in the stomach.

**Key Words:** Gastric band, Gastric band erosion, Intra-gastric migration, complications, Gastric band cutter.

<sup>1</sup>Department of Surgery, Escuela de Medicina y Ciencias de la Salud, Instituto Tecnológico y de Estudios Superiores de Monterrey (ITESM), Mexico.

<sup>2</sup>Department of Gastroenterology, Escuela de Medicina y Ciencias de la Salud, Instituto Tecnológico y de Estudios Superiores de Monterrey (ITESM), Mexico.

<sup>3</sup>The Methodist Hospital Research Institute, The Methodist Hospital at Houston, Houston, Texas, USA.

<sup>4</sup>Centro de Especialidades Bariatricas, Monterrey, Mexico.

Address correspondence to: Mario Rodarte-Shade MD, Posgrado en Cirugía, Escuela de Medicina y Ciencias de la Salud, Instituto Tecnológico y de Estudios Superiores de Monterrey (ITESM), Avenida Morones Prieto No. 3000 Poniente, Colonia Doctores, Monterrey, Nuevo Leon, Mexico. CP 64710. Telephone: +52 81 12771127, Fax: +52 81 83331061, E-mail: marioshade@hotmail.com

DOI: 10.4293/108680813X13654754534279

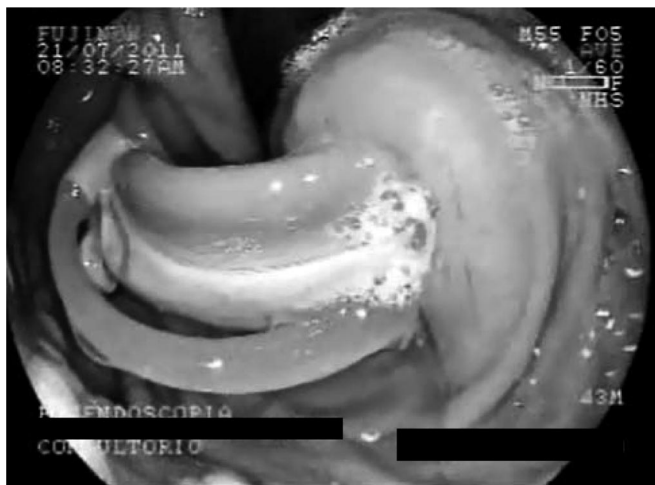© 2013 by JLS, *Journal of the Society of Laparoendoscopic Surgeons*. Published by the Society of Laparoendoscopic Surgeons, Inc.

## INTRODUCTION

Laparoscopic placement of an adjustable gastric band (AGB) is a common bariatric procedure.<sup>1</sup> It has proven to be a simple restrictive surgery with established efficacy, but can still cause serious complications.<sup>2</sup> A wide range of AGB-related complications have been described, including port problems, band slippage, pouch dilatation, and band erosion.<sup>1</sup> Gastric band erosion, also known as intra-gastric migration of the gastric band, is a late and rare complication of adjustable gastric bands. Erosions are failed bariatric procedures that cause failure to lose weight and in most cases weight regain. Gastric band erosions have a reported incidence that varies from 0.23% to 32.65% in several studies. A recent systematic review found an erosion rate of 1.46%.<sup>3</sup> One explanation for the inconsistency in incidence may be because gastric band erosions are misdiagnosed and/or underreported. The difficulty in diagnosing gastric band erosions may be due to the diverse clinical scenarios. This may indicate that a high index of suspicion with a low threshold to perform a gastroscopy is key in adequately diagnosing a patient with an eroded band. Epigastric pain, dysphagia, weight regain, and port-site abnormalities are some of the most common side effects.<sup>4-6</sup> Gastric band erosion has putatively been associated with several factors, such as band material, gastric plication over band, overfilled bands, slippage, use of perigastric technique, surgeon experience, gastric perforation or serosal tears during band placement, infection, and nonsteroidal anti-inflammatory drugs use.<sup>6-14</sup> A direct correlation between these factors and gastric band erosions has not been, hence the etiology remains unclear. While various approaches (i.e., laparoscopic vs. endoscopic) have been described in treating an eroded gastric band, our group presents a novel laparoendoscopic technique.

## CASE REPORT

A 43-y-old male was admitted with a surgical history of laparoscopic adjustable gastric band placement 2 y prior to his onset of symptoms. In the months before his second surgical intervention, the patient developed severe dysphagia, epigastric pain, and recurrent port-site

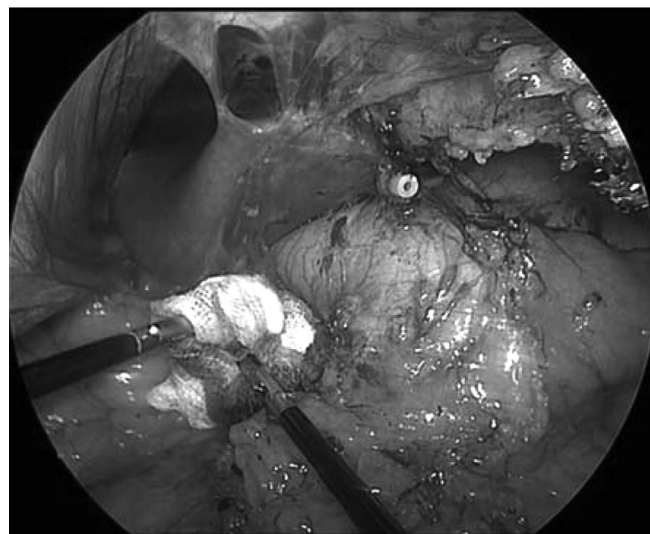


**Figure 1.** Gastric band erosion shown via gastroscopy.

infections. An upper endoscopy revealed intragastric migration of approximately 60% of the gastric band through the stomach wall (**Figure 1**). Retrieval of the band was offered to the patient through a hybrid procedure involving an endoscopic and laparoscopic approach.

## METHODS

After consenting to treatment, the patient was taken to the operating room and placed under general anesthesia. A pneumoperitoneum was created using the veress needle technique, and 3 nonbladed laparoscopic ports were placed (i.e., 5-mm, 10-mm, and 10-mm). A 30-degree scope was used for visualization. Extensive adhesions were visualized mainly around the adjustable gastric band (which was not visible) and the connecting tube. Dissection with electrocautery was performed following the connecting tube all the way to the gastric band. The connecting tube was then cut and extracted through the 10-mm trocar (**Figure 2**). Gastroscopy was performed revealing intragastric migration of approximately 60% of the band. The gastric band buckle was found to be inside the stomach. A special endoscopic instrument was used to perform an endoscopic removal of the gastric band (A.M.I., Aigner Gastric Band Cutter System), consisting of a cutting wire, a flexible guidewire, a handle, and a toggle. **Figure 3** shows the handle and toggle mechanism of the gastric band cutter. The cutting wire was passed around the gastric band. Initially, the endoscope was inserted into the stomach and the cutting wire was introduced by passing it on one side of the gastric band. The endoscope was then retrieved and reintroduced on the other side of the gastric

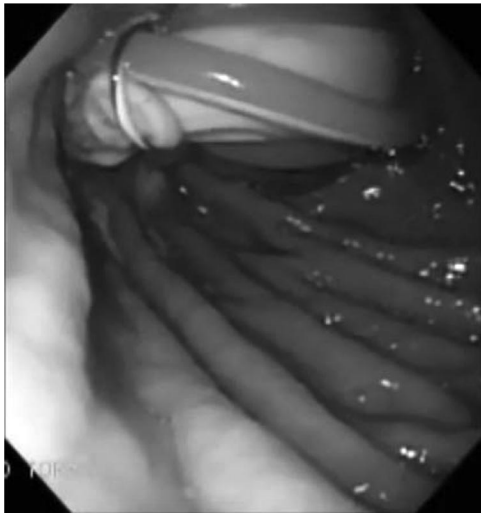


**Figure 2.** Laparoscopic view of the stomach and connecting tube.

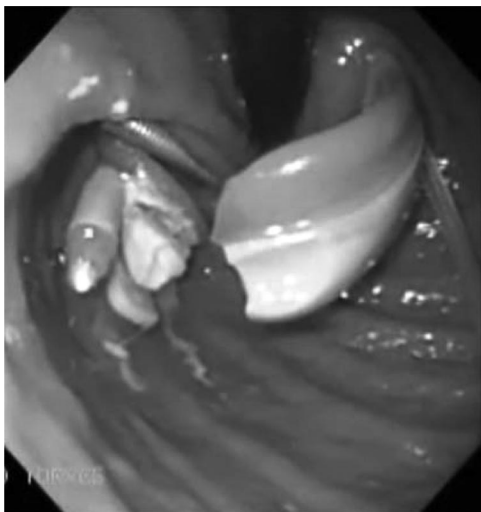


**Figure 3.** Handle and toggle mechanism.

band and with the aid of a grasper, the cutting wire was taken and extracted creating a loop around the gastric band (**Figure 4**). The 2 exposed ends of the cutting wire were used to pass the flexible guidewire all the way to the band. Subsequently, the cutting wire ends were coiled around the toggle, which was then connected to the handle (**Figure 3**). The toggle was subsequently turned to compress the cutting wire and the flexible guide wire until the band was cut. This system acted like a tourniquet that strangled the cutting wire around the band (**Figure 5**). Finally, the band was extracted transorally with the aid of basic endoscopic instruments, followed by endoscopic inspection of the esophagus and the stomach was performed to rule out any injury. The fistulous tract, originated by the connecting tube of the band, was closed with



**Figure 4.** View of cutting wire around the gastric band.

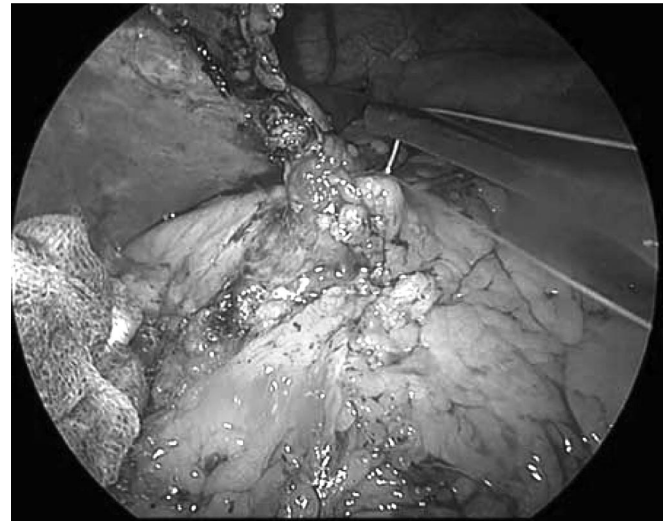

**Figure 5.** System acts like a tourniquet and cuts the band.

nonabsorbable suture stitches (**Figure 6**). A laparoscopic revision and pneumatic test were performed to visualize leaks. Finally, the band port was extracted, and debridement of the fistulous tract was performed up to the abdominal fascia.

## RESULTS

There was a total operative time of 75 min, and an estimated blood loss of 50cc. The patient had no operative complications and recovered successfully. Clear liquids were initiated 24 h after surgery, and the patient was discharged on the second day.



**Figure 6.** Stomach closure.

## DISCUSSION

A hybrid technique was described for the removal of an eroded gastric band, which included a combination of endoscopic and laparoscopic approaches. Endoscopic extraction is a viable option in select patients with eroded bands. To achieve this successfully, the gastric band buckle needs to be located inside the stomach. When endoscopic extraction is feasible, there is a minimal risk of leaks because gastrotomy is unnecessary. Laparoscopic assistance facilitates the endoscopic extraction by cutting the connecting tube and performing adhesiolysis, which helps release the gastric band. Another advantage of laparoscopic assistance is a pneumatic test at the end of the procedure to test for leaks.

Neto et al.<sup>4</sup> reported a series of 78 eroded gastric bands removed via endoscopy in a safe and effective manner. Kohn et al.<sup>15</sup> reported 49 cases of eroded gastric bands that were removed successfully via laparoscopy. Unfortunately, there are no comparative studies involving laparoscopic and endoscopic techniques in the removal of an eroded band. Experts advocating for laparoscopic removal argue that endoscopy requires general anesthesia. They also believe that several procedures must be performed for successful removal and that patients must have more than 50% of intragastric migration of the band.<sup>4,16</sup> The laparoendoscopic approach, as presented in this report, represents a safe and feasible option to successfully resolve this rare complication. Finally, we firmly believe that the management strategy of gastric band erosions should be handled on a case-by-case basis.

**References:**

1. Favretti F, Ashton D, Busetto L, Segato G, De Luca M. The gastric band: first-choice procedure for obesity surgery. *World J Surg.* 2009;33:2039–2048.
2. Watkins BM, Ahroni JH, Michaelson R, et al. Laparoscopic adjustable gastric banding in an ambulatory surgery center. *Sur Obes Rel Dis.* 2008;4:S56–S62.
3. Egberts K, Brown WA, O'Brien PE. Systematic review of erosion after laparoscopic adjustable gastric banding. *Obes Surg.* 2011;21:1272–1279.
4. Neto MP, Ramos AC, Campos JM, et al. Endoscopic removal of eroded adjustable gastric band (AGB): lessons learned after 5 years and 78 cases. *Surg Obes Rel Dis.* 2010;6:423–428.
5. Mozzi E, Lattuada E, Zappa MA, et al. Treatment of band erosion: feasibility and safety of endoscopic band removal. *Surg Endosc.* 2011;25:3918–3922.
6. Chisholm J, Kitan N, Toouli J, Kow L. Gastric band erosion in 63 cases: endoscopic removal and rebanding evaluated. *Obes Surg* 2011;21:1676–1681.
7. Bozbora A, Coskun H, Barbaros U, Sari S, Asoglu O. The effects of gastric bands of different synthetic materials on the gastric and esophageal mucosa: an experimental study. *Obes Surg.* 2004;14:246–252.
8. Lattuada E, Zappa MA, Mozzi E, et al. Histologic study of tissue reaction to the gastric band: does it contribute to the problem of band erosion? *Obes Surg.* 2006;16:1155–1159.
9. Kurian M, Sultan S, Garg K, et al. Evaluating gastric erosion in band management: an algorithm for stratification of risk. *Surg Obes Relat Dis.* 2010;6:386–389.
10. Singhal R, Bryant C, Kitchen M, et al. Band slippage and erosion after laparoscopic gastric banding: a meta-analysis. *Surg Endosc.* 2010;24:2980–2986.
11. Cherian PT, Goussous G, Ashori F, Sigurdsson A. Band erosion after laparoscopic gastric banding: a retrospective analysis of 865 patients over 5 years. *Surg Endosc.* 2010;24:2031–2038.
12. Angrisani L, Furbetta F, Doldi SB, et al. Lap Band adjustable gastric banding system: the Italian experience with 1863 patients operated on 6 years. *Surg Endosc.* 2003;17:409–412.
13. Abu-Abeid S, Zohar DB. Treatment of intra-gastric band migration following laparoscopic banding: safety and feasibility of simultaneous laparoscopic band removal and replacement. *Obes Surg.* 2005;15:849–852.
14. Meir E, Van Baden M. Adjustable silicone banding and band erosion: personal experience and hypotheses. *Obes Surg.* 1999; 9:191–193.
15. Kohn GP, Hansen CA, Gilhorne RW, et al. Laparoscopic management of gastric band erosions: a 10-year series of 49 cases. *Surg Endosc.* 2012;26:541–545.
16. O'Brien P. Comment on: Endoscopic removal of eroded adjustable gastric band (AGB): lessons learned after 5 years and 78 cases. *Surg Obes Rel Dis.* 2010;6:427–428.