

## Single Case

---

# Successful Novel Treatment of Nonuremic Calciphylaxis with Sodium Thiosulfate and Iloprost: A Case Report

Lisa Wiltfang Nina Booken Stefan W. Schneider

Clinic of Dermatology and Venerology, University Medical Center Hamburg-Eppendorf, Hamburg, Germany

## Keywords

Nonuremic calciphylaxis · Sodium thiosulfate · Iloprost

## Abstract

Calciphylaxis is a rare and potentially life-threatening disease which occurs most frequently in end-stage renal disease. Here, we describe a 69-year-old male patient who presented to the clinic with extremely painful necrotic ulcers of the right lower extremity. His risk factors included hypertension, diabetes mellitus type II, steatosis hepatis, and chronic hepatitis B. Laboratory studies revealed no signs for uremia, hyperparathyroidism, and normal phosphorus as well as calcium levels. A diagnosis of nonuremic calciphylaxis was made in correlation with clinical and histological features. A novel therapeutic approach combining sodium thiosulfate and iloprost showed remarkable improvement of the wound-associated pain and healing of the ulcers within 3 months. Due to its high mortality rate, an early diagnosis and initiation of treatment are crucial to be beneficial for patient outcomes.

© 2022 The Author(s).

Published by S. Karger AG, Basel

## Introduction

Calciphylaxis can be divided into uremic calciphylaxis in patients with end-stage renal disease (ESRD) and nonuremic calciphylaxis, including about 20% of the calciphylaxis population [1]. Cardinal features include painful necrotic ulcers caused by calcification and occlusion of microvessels in the dermis and subcutaneous adipose tissue. An incidence rate of 4 cases per 10,000 in dialysis patients in Germany has been reported [1]. Sepsis caused by

---

Correspondence to:  
Lisa Wiltfang, l.wiltfang@uke.de

infection of the skin ulcers is the main cause of mortality. The 1-year mortality rate in ESRD patients is higher compared to non-ESRD patients [2]. The mean age varies between 50 and 70 years [1, 3]. Risk factors for patients with nonuremic calciphylaxis are summarized in Table 1. Clinical features include induration, plaques, nodules, livedo or purpura, and necrotic ulcerations with a bizarre shape [4]. The pathogenesis of calciphylaxis remains to be uncertain. Vitamin K seems to play a role in activating the matrix G1a protein which acts as a strong inhibitor of calcification in the vessels [5]. Histopathologically, calcification, fibrointimal hyperplasia, and thrombosis in microvessels in the subcutaneous adipose tissue and dermis, often accompanied by necrosis of epidermal and adipose tissue, dermal-epidermal separation, panniculitis, proliferation of dermal endothelial cells, and extravascular calcifications can be found [6]. Differential diagnosis that should be considered includes warfarin-induced necrosis, atherosclerotic vascular disease, venous stasis ulcer, livedoid vasculopathy, pyoderma gangrenosum, and Martorell's ulcer [6].

Currently, there is no standardized and approved therapy available. Effective approaches reported in case reports and uncontrolled trials consist of adequate pain and wound management, elimination of risk factors, and systemic therapeutic agents including sodium thiosulfate. Here, we aim to provide a novel treatment combining sodium thiosulfate and iloprost in order to promote wound healing and adequate pain management.

### Case Report

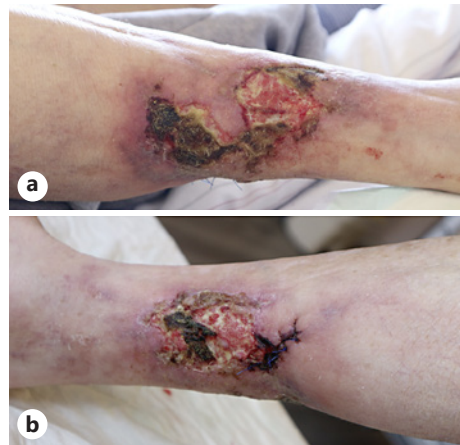
A 69-year-old male patient presented to the clinic with intensely painful necrotic ulcers of the right lower extremity. Symptoms started 4 months prior after a minimal trauma pretibial. Subsequently, new ulcers on the right dorsal calf developed. He did not report fever, claudication, or history of previous leg ulcers or thrombosis. The pain intensity was 10/10 on the numeric rating scale (NRS). One episode of severe bleeding was reported.

The patient had a medical history notable for hypertension, diabetes mellitus type II, hepatic steatosis, chronic alcohol consumption, and chronic hepatitis B. His medications included metformin, hydrochlorothiazide, amlodipine, ramipril, pravastatin, and pregabalin.

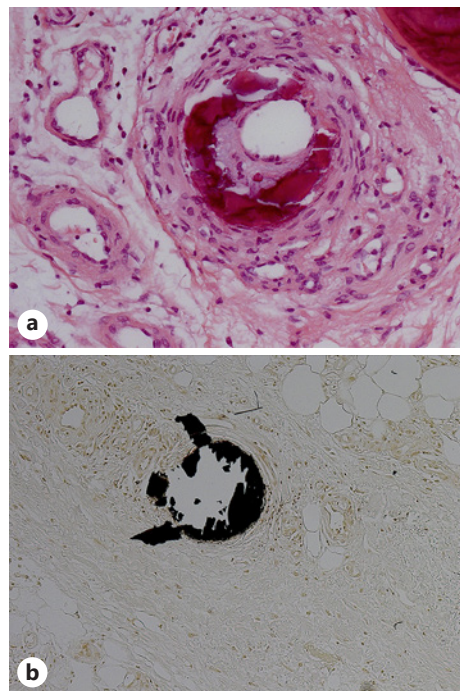
Physical examination revealed three necrotic ulcers of the right calf with black plaques and surrounding erythema (Fig. 1a, b). Furthermore, reticulated erythema of the left and right calf was observed. Laboratory studies showed normal creatinine, glomerular filtration rate, calcium, and phosphorus. Serum parathyroid hormone was 12.6 ng/L and total 25-hydroxyvitamin D 8.7 µg/L. Carbohydrate-deficient transferrin was 2.6%. The hemoglobin A1c was 6.6%, GGT 287 U/L. In addition, a hyperchromic macrocytic anemia with a hemoglobin level of 8.8 g/dL was found. Because of a folate deficiency, 5 mg of folic acid was administered daily.

**Table 1.** Important risk factors for nonuremic calciphylaxis

Obesity
Diabetes mellitus
Hypertension
Female sex
Malfunction of calcium and phosphate homeostasis (hypercalcemia, hyperphosphatemia)
Vitamin K deficiency
Hepatobiliary disease
Medications (e.g., warfarin, vitamin D)



**Fig. 1.** Clinical presentation: necrotic ulcers of the right calf with surrounding erythema. **a** Lateral right calf. **b** Medial right calf.

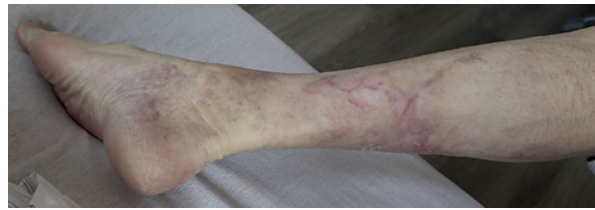


**Fig. 2.** **a** Histologically, a deep ulcer with areas of fat necrosis, vessels with fibrosclerosis, and intraluminal calcific deposits in small subcutaneous vessels were found. Neutrophil infiltration was observed in the medium-sized vessels. **b** Von Kossa stain showed intravascular calcification.

In the esophagogastroduodenoscopy, no bleeding source was found. In the external colonoscopy, no abnormality had been detected, and the Haemoccult test was negative. X-ray results were without pathological findings.

Tissue biopsy of the right calf was performed for histologic evaluation. The tissue showed a deep ulcer with areas of fat necrosis, vessels with fibrosclerosis, and intraluminal calcific deposits in small subcutaneous vessels. Neutrophil infiltration was observed in the medium-sized vessels (Fig. 2a). The von Kossa stain which illustrates mineralization also revealed intravascular calcification, respectively (Fig. 2b).

A diagnosis of nonuremic calciphylaxis was made in correlation with clinical and histological features, and the patient was started on intravenous sodium thiosulfate 20 g 3 times per week in combination with iloprost 20 µg over 5 h in 50 mL sodium chloride 0.9% 4 times per week. Cycles were repeated every 6–8 weeks for 5 months.



**Fig. 3.** Complete healing of the ulcers within 3 months after treatment initiation.

The skin ulcers were managed with daily wound care in the form of regular dressing and surgical wound debridement. Because of clinical presentation of wound infection and an elevation of C-reactive protein (68 mg/L), an antibiotic treatment with intravenous ampicillin/sulbactam was administered for 9 days. The pain treatment consisted of metamizole 4 g/day and tramadol hydrochloride 50 mg twice daily. Because of the anemia, two red cell concentrates were administered. After the first treatment cycle, the pain intensity was 3/10 NRS. Notable after the third treatment cycle, the ulcers had healed completely and the wound-associated pain was completely resolved (Fig. 3). During the course of the treatment, an improvement of the anemia (12.1 g/dL) was observed. At the last follow-up after discontinuation of treatment, the ulcers were still completely healed and no wound-associated pain was reported.

## Discussion

Here, we show a novel successful treatment option using a combination of sodium thiosulfate and prostaglandin (iloprost). Calciphylaxis is caused by occlusion of blood vessels in the dermis and subcutaneous adipose tissue. Iloprost is a prostacyclin analogue which is used, e.g., to treat scleroderma and Raynaud's phenomenon in which the blood vessels are constricted, whereas sodium thiosulfate is thought to have cation-chelating, antioxidant, and vasodilatory effects [7].

We used both agents combined in order to promote vasodilation, prevent further calcification, and provide an adequate oxygenation of the ischemic tissue. In our case, the treatment combination was well tolerated and our patient's wound-associated pain could be completely relieved.

Significant risk factors that may have promoted calciphylaxis in our patient include hypertension, diabetes mellitus type II, hepatic steatosis, history of chronic alcohol consumption, and chronic hepatitis B. No medications were identified as subsequent risk factors. Especially in patients with nonuremic calciphylaxis, the early diagnosis of the disease may be challenging and other differential diagnosis may be considered first. Therefore, skin biopsy is crucial for the confirmation of the suspected diagnosis especially in nonuremic patients.

Not only in calciphylaxis but also in Martorell's ulcer, subsequent calcification of microvessels has been reported. According to Hafner [8], calciphylaxis and Martorell's ulcer may be closely related to one another concerning risk factors, clinical patterns, and histopathology. Therefore, similar treatment concepts for the acute phase of the diseases could be feasible in both diseases [8]. Therefore, our treatment combination with sodium thiosulfate and iloprost may be effective also in patients with Martorell's ulcer. In addition to optimized control of cardiovascular risk factors including diabetes and hypertension, a proactive wound approach including early surgical measures, e.g., debridement with necrosectomy and early skin grafts, may be effective to promote healing of the wound [8].

Concerning systemic treatment options, there are recent studies investigating potential treatment agents. These treatment options include sodium thiosulfate, vitamin K supplementation, and SNF472.

SNF472 is currently investigated in phase 2 and 3 trials for patients with calciphylaxis as it has been shown to be related to slow progression of cardiovascular calcification in patients on hemodialysis [9, 10]. As vitamin K deficiency prevents matrix G1a protein activation and therefore may promote calcification, it has been discussed as a treatment agent and used successfully in a single dialysis patient [11, 12]. According to our knowledge, a treatment combination using sodium thiosulfate and iloprost in nonuremic calciphylaxis has not been published in the literature before.

### Conclusion

Recent advances in better understanding of the underlying mechanisms of the pathogenesis of calciphylaxis have identified potential therapeutic agents that are currently tested in clinical trials. The efficacy of a novel treatment combination with sodium thiosulfate and iloprost could be demonstrated in our patient. Further treatment evaluation is needed for general treatment recommendations. Early diagnosis and initiation of treatment are important in helping to prevent serious infections and complications.

### Statement of Ethics

The authors have no ethical conflicts to declare. Written informed consent was obtained from the patient for publication of the medical case and accompanying images. The case complied with the Declaration of Helsinki. Ethical approval beyond written informed consent was not required for this study in accordance with local guidelines.

### Conflict of Interest Statement

The authors have no conflicts of interest to declare.

### Funding Sources

No funding sources were used in preparation of the manuscript.

### Author Contributions

Lisa Wiltfang, Nina Booken, and Stefan W. Schneider were involved in diagnosis and treatment of the patient; contributed to literature review, and writing and reviewing the manuscript; and approved the version to be published.

### Data Availability Statement

All data are available in this manuscript.

## References

- 1 Brandenburg VM, Kramann R, Rothe H, Kaesler N, Korbiel J, Specht P, et al. Calcific uremic arteriopathy (calciphylaxis): data from a large nationwide registry. *Nephrol Dial Transplant*. 2017;32(1):126–32.
- 2 Nigwekar SU, Thadhani R, Brandenburg VM. Calciphylaxis. *N Engl J Med*. 2018;379(4):399–400.
- 3 McCarthy JT, El-Azhary RA, Patzelt MT, Weaver AL, Albright RC, Bridges AD, et al. Survival, risk factors, and effect of treatment in 101 patients with calciphylaxis. *Mayo Clin Proc*. 2016;91(10):1384–94.
- 4 Wollina U. Update on cutaneous calciphylaxis. *Indian J Dermatol*. 2013;58(2):87–92.
- 5 Nigwekar SU, Zhao S, Wenger J, Hymes JL, Maddux FW, Thadhani RI, et al. A nationally representative study of calcific uremic arteriopathy risk factors. *J Am Soc Nephrol*. 2016;27(11):3421–9.
- 6 Nigwekar SU, Thadhani R, Brandenburg VM. Calciphylaxis. *N Engl J Med*. 2018;378(18):1704–14.
- 7 Udomkarnjananon S, Kongnatthasate K, Praditpornsilpa K, Eiam-Ong S, Jaber BL, Susantitaphong P. Treatment of calciphylaxis in CKD: a systematic review and meta-analysis. *Kidney Int Rep*. 2019;4(2):231–44.
- 8 Hafner J. Calciphylaxis and martorell hypertensive ischemic leg ulcer: same pattern: one pathophysiology. *Dermatology*. 2016;232(5):523–33.
- 9 Raggi P, Bellasi A, Bushinsky D, Bover J, Rodriguez M, Ketteler M, et al. Slowing progression of cardiovascular calcification with snf472 in patients on hemodialysis: results of a randomized phase 2b study. *Circulation*. 2020;141(9):728–39.
- 10 Raggi P, Bellasi A, Sinha S, Bover J, Rodriguez M, Ketteler M, et al. Effects of SNF472, a novel inhibitor of hydroxyapatite crystallization in patients receiving hemodialysis: subgroup analyses of the CALIPSO trial. *Kidney Int Rep*. 2020;5(12):2178–82.
- 11 Chang JJ. Calciphylaxis: diagnosis, pathogenesis, and treatment. *Adv Skin Wound Care*. 2019;32(5):205–15.
- 12 Christiadi D, Singer RF. Calciphylaxis in a dialysis patient successfully treated with high-dose vitamin K supplementation. *Clin Kidney J*. 2018;11(4):528–9.