

## Case Report

# Massive Osteolysis in a Modern Total Knee Prosthesis

Emmanuel Gibon <sup>1</sup>, Jacquelyn A. Knapik,<sup>2</sup> and Hari K. Parvataneni <sup>1</sup>

<sup>1</sup>Division of Adult Reconstruction, Department of Orthopedics and Rehabilitation, University of Florida College of Medicine, University of Florida, Gainesville, FL, USA

<sup>2</sup>Department of Pathology, Immunology and Laboratory Medicine, University of Florida College of Medicine, University of Florida, Gainesville, FL, USA

Correspondence should be addressed to Emmanuel Gibon; [emmanuel.gibon@gmail.com](mailto:emmanuel.gibon@gmail.com)

Received 8 June 2021; Accepted 27 September 2021; Published 20 October 2021

Academic Editor: Robert U. Ashford

Copyright © 2021 Emmanuel Gibon et al. This is an open access article distributed under the Creative Commons Attribution License, which permits unrestricted use, distribution, and reproduction in any medium, provided the original work is properly cited.

*Case.* An 82-year-old woman underwent right total knee replacement with a sequentially irradiated and annealed highly cross-linked polyethylene insert. At 9 years, she was found to have a massive femoral osteolysis with an impending fracture. *Conclusion.* This case demonstrates a rare occurrence of massive femoral osteolysis, requiring revision surgery, with a sequentially irradiated and annealed highly cross-linked polyethylene.

## 1. Introduction

Total knee arthroplasty is a highly reliable and reproducible procedure to treat end-stage knee osteoarthritis. The Australian registry shows a survivorship of 91.4% at 18 years [1].

First-generation highly cross-linked polyethylene (HXLPE) was first introduced clinically in 2001 for total knee arthroplasty (TKA) [2]. However, due to concern for the potential risk of early fracture, its implementation has been more gradual than for total hip arthroplasty (THA). There remain concerns about transitioning from UHMWPE to HXLPE due to the reduction in ductility and fracture resistance associated with cross-linking. Nevertheless, *in vitro* studies have shown significant reduction of wear with first-generation HXLPE tibial inserts [3–5]. HXLPE tibial inserts are now predominantly used in Australia and represents 64.2% of all the PE inserts [1].

The X3® (Stryker, Mahwah, NJ) is a second-generation HXLPE, which was widely introduced in 2005. It is produced by gamma irradiating compression-molded GUR 1020 with 30 kGy of gamma irradiation followed by annealing to 130°C. These steps are repeated three times, and then, gas plasma sterilization occurs. The rationale behind this

manufacturing technique for X3® was to remove enough free radicals to provide oxidation resistance while retaining the advantage of the UHMWPE mechanical properties. Wang et al. showed this process to be effective at dramatically eliminating free radicals equivalent to the level of virgin UHMWPE [6]. Accelerated aging studies showed similar results [7]. Knee simulator investigations reported wear reduction ranging from 64% to 86% compared to conventional UHMWPE [8–10]. Registry data shows a survivorship of the Triathlon® with X3® of 96.2% at 10 years [1]. Meneghini et al. [11] reported no radiographic osteolysis or mechanical failure of the tibial polyethylene at 5-year follow-up. Minoda et al. [12] showed a 58% reduction of the number of *in vivo* X3® wear particles compared to conventional PE in TKA.

Here, we present a case of catastrophic femoral osteolysis following a TKA with sequentially annealed highly cross-linked polyethylene, which is, to the best of our knowledge, the first report of this mode of failure in this modern design. The patient was informed that data concerning the case would be submitted for publication, and she provided consent.

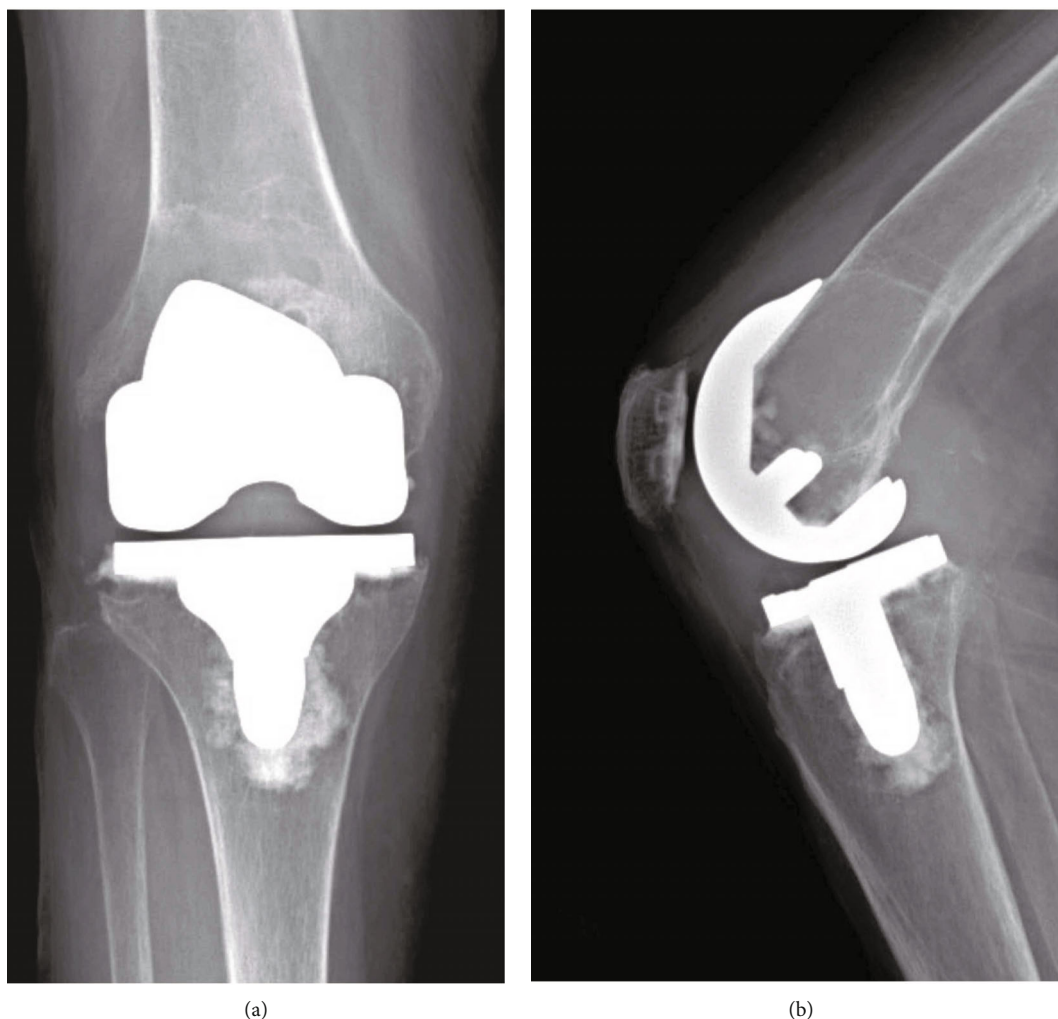


FIGURE 1: Right knee: (a) AP and (b) lateral radiographs at the time of presentation (February 2019).

## 2. Case Report

An 82-year-old woman presented to our institution for evaluation of her right TKA, which was performed in 2009 at an outside hospital. Her past medical history was significant only for rheumatoid arthritis (RA) for which she usually took adalimumab biweekly, methotrexate and celecoxib but reported this was well controlled.

Per her outside operative records, implants used at the initial surgery were a cemented Triathlon® CR femoral component, a 9 mm size 3 X3® CS insert, a size 3 Triathlon® universal tibial baseplate, and a 10 mm asymmetric Triathlon® X3® patella.

The patient was initially referred by the primary surgeon to our oncology clinic in February 2019 due to findings of a distal femur lesion in her right knee discovered on follow-up X-rays (Figure 1) and better seen in a noncontrast MRI. At that time, the patient was pain-free but reported feelings of instability. The physical exam showed a well-healed midline surgical incision for TKA without complication. No obvious

instability with varus/varus testing or drawer testing was found.

MRI with IV contrast was performed to further characterize this mass in the right distal femur and rule out a malignant lesion (Figure 2). The MRI report showed “post-surgical changes of right TKA with findings typical for osteolysis secondary to particle disease and knee joint effusion with synovitis.” The orthopedic oncologist then referred the patient to our adult reconstruction clinic with very low suspicion for a neoplastic process.

The patient was assessed again in April 2019 and mentions occasional knee buckling but without pain. Her X-rays showed a focal well-circumscribed lucent lesion with thin geographic mineralized margin along the distal diaphysis and deep to the cemented femoral component. There was thinning and weakening of the cortices in several areas. At that time, we recommended surgery due to the fracture risk. The patient declined but was agreeable to close surveillance. She was assessed two months later and did not want to consider surgery, again and refused X-rays due to

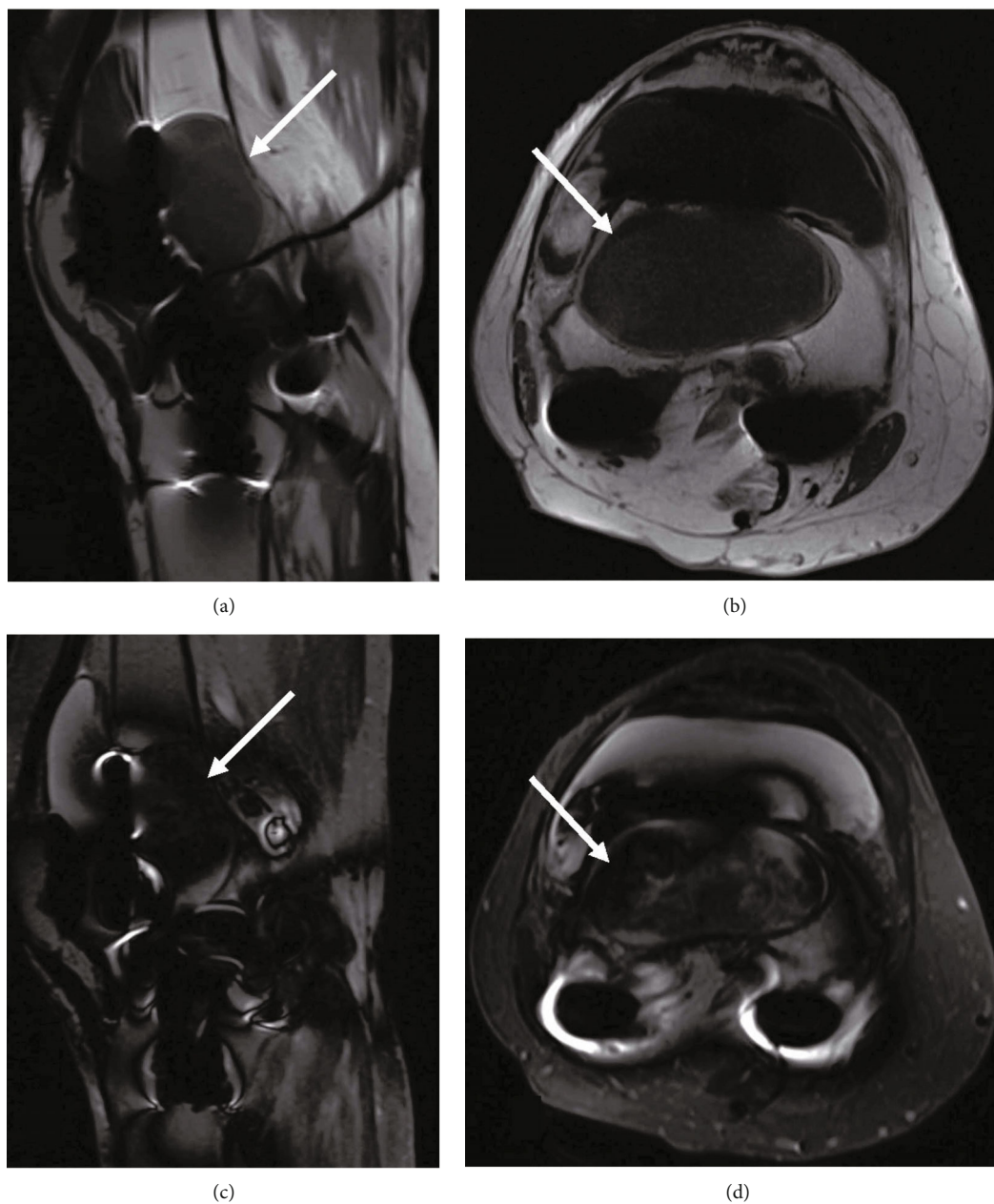


FIGURE 2: MRI of the right knee with IV gadolinium. In the distal femur, there is low T1 signal in the sagittal (a) and axial (b) views and heterogeneously predominantly low T2 signal in the sagittal (c) and axial (d) views with a sharp rim and thin peripheral enhancement (white arrows) that is in continuity with the prosthesis and typical for osteolysis secondary to particle disease (MRI machine: Titan 3T (Toshiba)).

absence of pain. She returned back a month later with mild knee pain and opted to proceed with a revision TKA for the diagnosis of massive femoral osteolysis and impending femoral fracture. The patient was later seen preoperatively, and the pain and X-rays remained stable (Figure 3).

We utilized the prior incision and entered the joint through a medial parapatellar arthrotomy. Clear synovial fluid was seen and sent for culture. The patella and tibia were mobilized and found to be well fixed, although the tibia had some osteolysis. The polyethylene was found to have minor

oxidation, but no significant wear was found. We found no third bodies or other debris. We removed the insert and found no backside wear or any other explanation for this massive osteolysis. There was visual appearance of diffuse in vivo oxidation. Based on the extent of the osteolysis, we decided to revise the femur with a stem to bypass the defect. The femoral component was then removed with minimal bone loss. There were massive cystic changes with some debris that we sent for pathology (Figure 4). After refreshing the cuts, we proceeded with reconstruction. The femoral

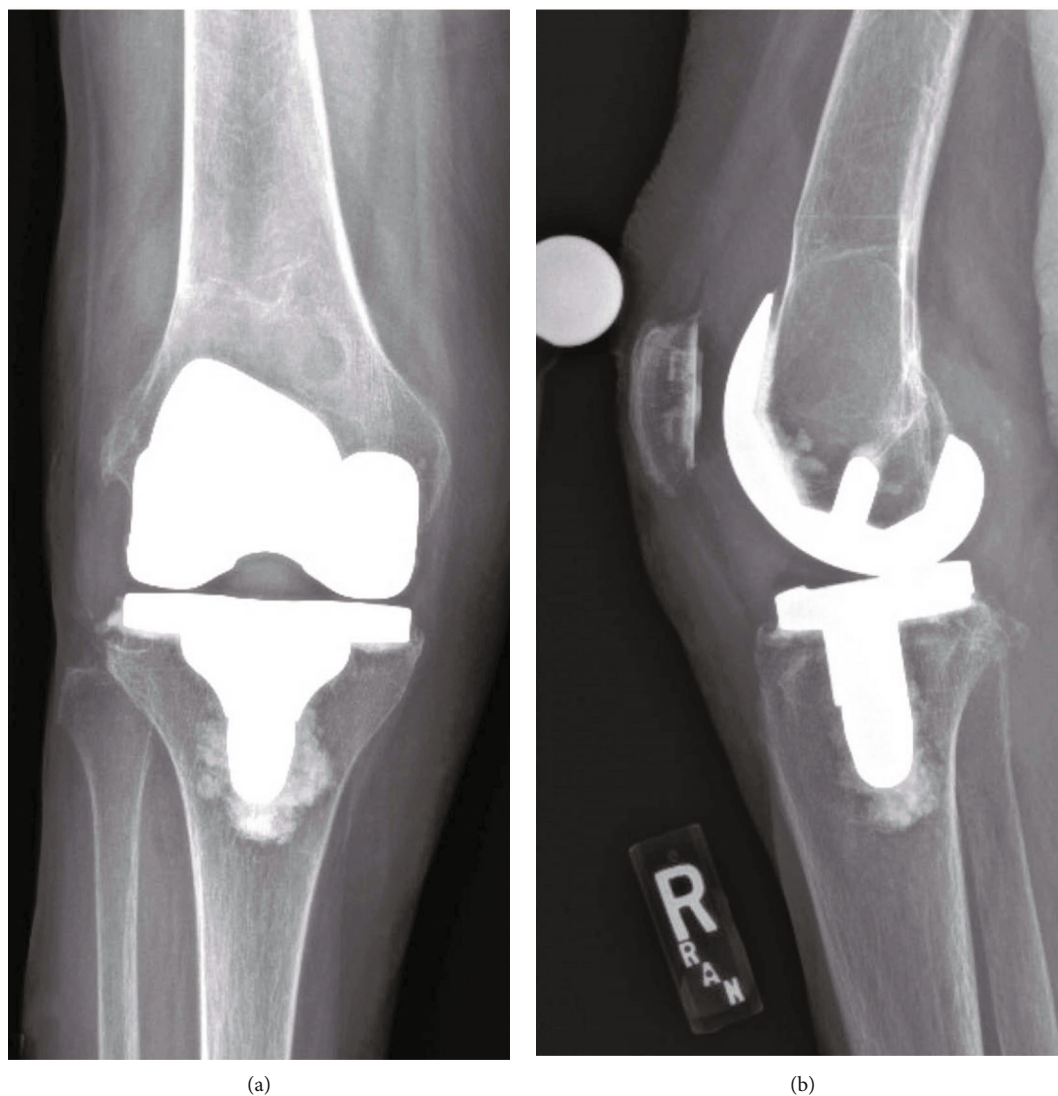


FIGURE 3: Right knee: (a) AP and (b) lateral radiographs six months later (October 2019).

reconstruction was performed using a size A Tritanium® metaphyseal cone and Triathlon® femoral component with a 15 mm × 100 mm cemented stem extension and a 16 mm posterior stabilized X3® insert.

All the cultures resulted negative. Microscopic evaluation (Figure 5) of the periprosthetic tissue revealed features typically observed when implant failure has taken place. Numerous multinucleated foreign body giant cells can be seen filled with debris from breakdown products. Some of the giant cells had empty spaces where engulfed methyl methacrylate cement was present but dissolved during tissue processing. Other foreign body giant cells contained shards of refractile debris and fragmented refractile particles. Macrophages also infiltrated the tissue and are filled with phagocytosed microparticles. Chronic inflammatory cells were present but there was no acute inflammation supporting that this was an aseptic process.

At one-year clinical follow-up, the patient was noted to be doing well with no changes in her radiographic examination (Figure 6). Her incision healed uneventfully. The patient was pain free and ambulating without walking aids. At the last follow-up, her right knee range of motion was 0-130°.

### 3. Discussion

Osteolysis is now an uncommon reason for late failure of modern TKA and has been shown to represent 9% [13]. Our case is unique because it is the first report of a catastrophic femoral osteolysis at just under 10 years in an otherwise well-functioning TKA using a modern HXLPE insert which has an excellent track record. There are only a very limited number of case reports of previous failure of the X3® in TKA, and the failure modes were different than this report. Sonn and

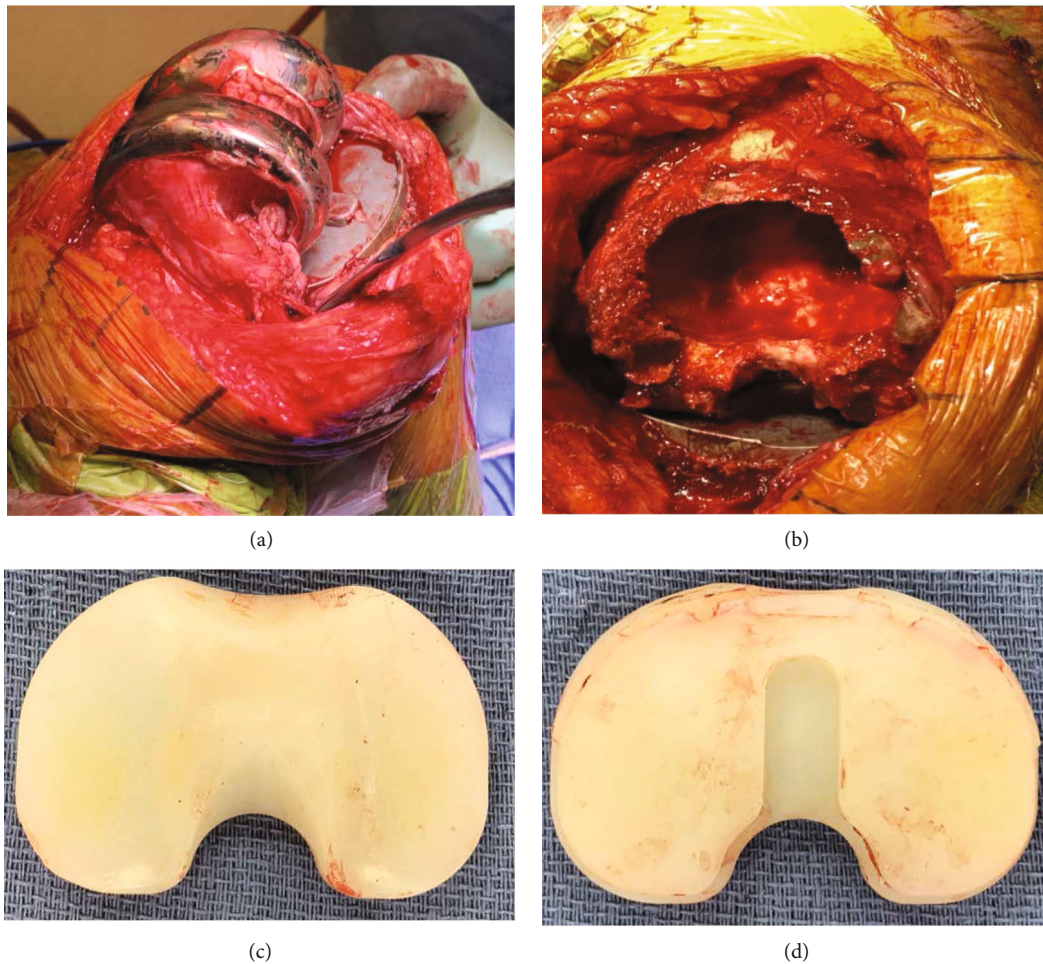


FIGURE 4: Intraoperative findings. (a) Lateral view of the distal femur showing massive osteolysis of the lateral condyle. (b) Top-down view of the distal femur after implant removal showing extension of the osteolysis into the canal. (c) Top view and (d) backside view of the X3® insert with no evidence of wear or surface damage. The entire polyethylene surface demonstrated yellow discoloration consistent with oxidation.

Meneghini [14] discussed an early failure of X3® at 5 years. The mechanism of failure was a completely worn through polyethylene. Kop et al. [15] investigated 15 implants from revision surgeries at a mean of 3 years. Of note, none of the revision was performed for isolated osteolysis. Furthermore, 4 of the 15 bearings exhibited signs of oxidation. MacDonald et al. [16] assessed the in vivo performance of X3® retrieved tibial inserts ( $n = 345$ ) and compared them to gamma inert sterilized PE tibial inserts. The authors found that the X3® inserts had similar oxidation levels when compared to gamma inert controls. Moreover, they had 6 cases of posterior fracture in the X3® cohort and none in the control group.

In our case, one could propose that RA could have resulted in the bony changes. However, the patient's disease was well controlled and the pathology analysis did not notice any microscopic tissue modification pointing toward RA. Pathology also ruled out a neoplasm. Polyethylene-induced osteolysis was further confirmed by histological analysis. Examination of our retrieval PE insert

showed signs of burnishing, which is not an uncommon finding for tibial bearings. We did not observe any fracture or delamination of the implant but significant oxidation was seen.

Typical risk factors for osteolysis associated with TKA are malalignment of the mechanical axis and improper ligament balancing, early-generation PE sterilization techniques, back-side wear, third-body abrasion, young age, increased activity level, and elevated body mass index. In our case, the patient was a low-demand 82-year-old woman with a BMI of  $23.8 \text{ kg/m}^2$ . In this present case, one potential explanation could be an isolated issue with a batch from manufacturing since this is such an unusual case.

The Manufacturer and User Facility Device Experience (MAUDE) database captures failure patterns with certain FDA cleared medical devices in a timely manner. We reviewed this database between 2005 and 2020 and found 15 reported cases related to the X3® insert, and 10 of them were about the tibial inserts. None of them were related to osteolysis.

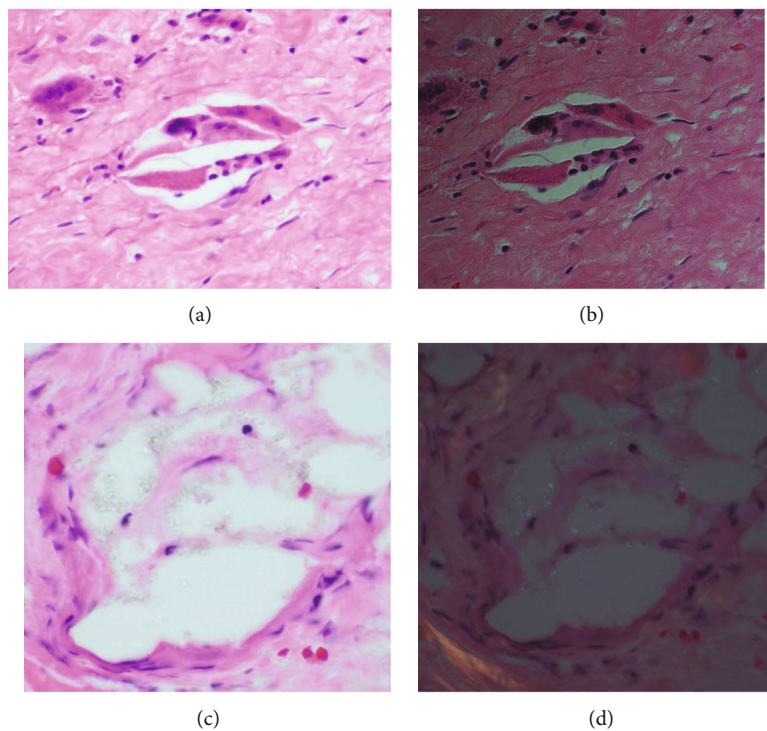


FIGURE 5: Histological analysis. (a, c) Multinucleated foreign body giant cells with engulfed shards of PE debris (H&E 40x). (b, d) H&E under refractile light.

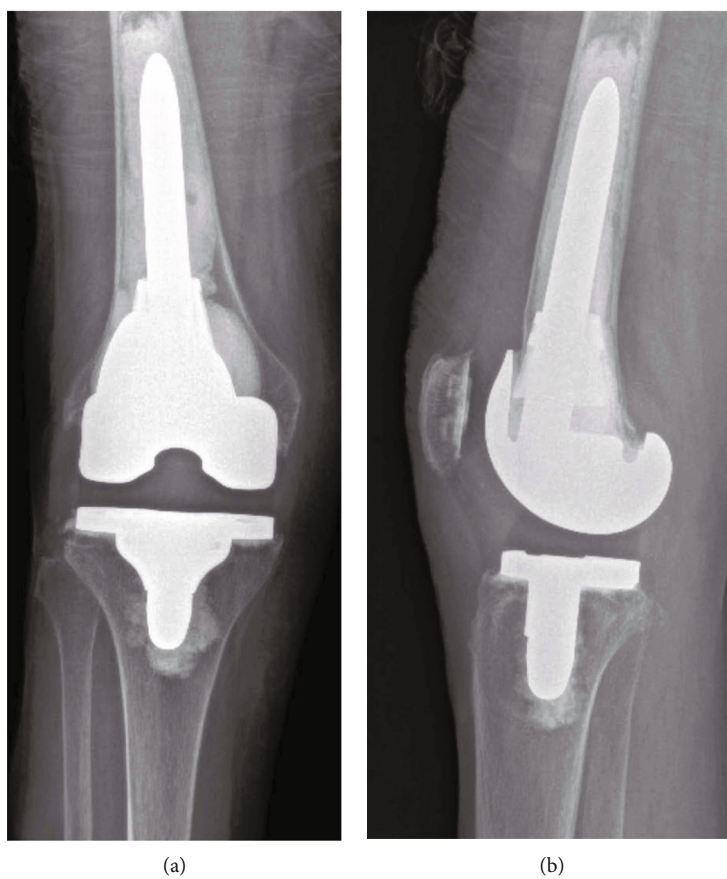


FIGURE 6: Right knee: (a) AP and (b) lateral radiographs at one-year follow-up.

The use of HXLPE in TKA is still controversial. A recent study by Partridge et al. [17] that combined registries from England, Wales, and Northern Ireland showed that conventional polyethylene had significantly lower aseptic revision rates than HXLPE, except for a very specific subset of patients.

#### 4. Conclusion

In summary, this case demonstrates that primary TKA performed with sequentially irradiated and annealed highly cross-linked polyethylene are not immune to polyethylene-induced osteolysis. Although X3® shows excellent survivorship at 10 years for TKA, routine surveillance of patients might be warranted especially around the first decade after implantation.

#### Data Availability

The data used to support the findings of this study are included within the article.

#### Conflicts of Interest

The authors declare that they have no conflicts of interest.

#### References

- [1] "Australian National Joint Replacement Registry, Annual Report 2019," 2020, Available at: <https://aoanjrr.sahmri.com/annual-reports-2019>.
- [2] J. T. Hodrick, E. P. Severson, D. S. McAlister, B. Dahl, and A. A. Hofmann, "Highly crosslinked polyethylene is safe for use in total knee arthroplasty," *Clinical Orthopaedics & Related Research*, vol. 466, no. 11, pp. 2806–2812, 2008.
- [3] O. K. Muratoglu, C. R. Bragdon, D. O. O'Connor, R. S. Perinchief, M. Jasty, and W. H. Harris, "Aggressive wear testing of a cross-linked polyethylene in total knee arthroplasty," *Clinical Orthopaedics and Related Research*, vol. 404, pp. 89–95, 2002.
- [4] O. K. Muratoglu, A. Mark, D. A. Vittetoe, W. H. Harris, and H. E. Rubash, "Polyethylene damage in total knees and use of highly crosslinked polyethylene," *The Journal of Bone and Joint Surgery. American Volume*, vol. 85, Suppl 1, pp. 7–S13, 2003.
- [5] S. Utzschneider, N. Harrasser, C. Schroeder, F. Mazoochian, and V. Jansson, "Wear of contemporary total knee replacements - A knee simulator study of six current designs," *Clinical Biomechanics*, vol. 24, no. 7, pp. 583–588, 2009.
- [6] A. Wang, H. Zeng, S. S. Yau, A. Essner, M. Manley, and J. Dumbleton, "Wear, oxidation and mechanical properties of a sequentially irradiated and annealed UHMWPE in total joint replacement," *Journal of Physics D: Applied Physics*, vol. 39, no. 15, pp. 3213–3219, 2006.
- [7] J. H. Dumbleton, J. A. D'Antonio, M. T. Manley, W. N. Capello, and A. Wang, "The basis for a second-generation highly cross-linked UHMWPE," *Clinical Orthopaedics and Related Research*, vol. 453, pp. 265–271, 2006.
- [8] M. A. Kester, L. Herrera, A. Wang, and A. Essner, "Knee bearing technology: where is technology taking us?," *The Journal of Arthroplasty*, vol. 22, no. 7, pp. 16–20, 2007.
- [9] R. Tsukamoto, P. A. Williams, H. Shoji et al., "Wear of sequentially enhanced 9-Mrad polyethylene in 10 million cycle knee simulation study," *Journal of Biomedical Materials Research Part B: Applied Biomaterials*, vol. 86B, no. 1, pp. 119–124, 2008.
- [10] A. Wang, S.-S. Yau, A. Essner, L. Herrera, M. Manley, and J. Dumbleton, "A highly crosslinked UHMWPE for CR and PS total knee arthroplasties," *The Journal of Arthroplasty*, vol. 23, no. 4, pp. 559–566, 2008.
- [11] R. M. Meneghini, L. R. Lovro, S. A. Smits, and P. H. Ireland, "Highly cross-linked versus conventional polyethylene in posterior-stabilized total knee arthroplasty at a mean 5-year follow-up," *The Journal of Arthroplasty*, vol. 30, no. 10, pp. 1736–1739, 2015.
- [12] Y. Minoda, K. Hata, K. Goto, T. Itohara, and H. Nakamura, "Sequentially annealed highly cross-linked polyethylene reduced in vivo wear particle generation in total knee arthroplasty," *Journal of Orthopaedic Surgery*, vol. 25, no. 2, 2017.
- [13] D. H. Le, S. B. Goodman, W. J. Maloney, and J. I. Huddleston, "Current modes of failure in TKA: infection, instability, and stiffness predominate," *Clinical Orthopaedics and Related Research*, vol. 472, no. 7, pp. 2197–2200, 2014.
- [14] K. A. Sonn and R. M. Meneghini, "Early failure of sequentially annealed polyethylene in total knee arthroplasty," *Arthroplasty Today*, vol. 6, no. 1, pp. 18–22, 2020.
- [15] A. M. Kop, M. B. Pabbruwe, C. Keogh, and E. Swarts, "Oxidation of second generation sequentially irradiated and annealed highly cross-linked X3™ polyethylene tibial bearings," *The Journal of Arthroplasty*, vol. 30, no. 10, pp. 1842–1846, 2015.
- [16] D. W. MacDonald, G. B. Higgs, A. F. Chen, A. L. Malkani, M. A. Mont, and S. M. Kurtz, "Oxidation, damage mechanisms, and reasons for revision of sequentially annealed highly crosslinked polyethylene in total knee arthroplasty," *The Journal of Arthroplasty*, vol. 33, no. 4, pp. 1235–1241, 2018.
- [17] T. C. J. Partridge, P. N. Baker, S. S. Jameson, J. Mason, M. R. Reed, and D. J. Deehan, "Conventional versus highly cross-linked polyethylene in primary total knee replacement," *The Journal of Bone and Joint Surgery. American Volume*, vol. 102, no. 2, pp. 119–127, 2020.