

Received: 2021.03.23

Accepted: 2021.07.13

Available online: 2021.08.05

Published: 2021.09.15


Spontaneous Knot Formation in a Central Venous Catheter

Authors' Contribution:

Study Design A
Data Collection B
Statistical Analysis C
Data Interpretation D
Manuscript Preparation E
Literature Search F
Funds Collection GEFG 1 **Carolina Bortolozzo Graciolli Facanali**
BG 2 **Vanessa Simões Paixão**
DG 1 **Carlos Walter Sobrado**
AG 1 **Marcio Roberto Facanali**

1 Department of Gastroenterology, University of São Paulo, School of Medicine, São Paulo, SP, Brazil

2 Metropolitan University of Santos (UNIMES), Santos, SP, Brazil

Corresponding Author: Carolina Bortolozzo Graciolli Facanali, e-mail: cbgraciolli@hotmail.com**Conflict of interest:** None declared**Patient:** Male, 63-year-old
Final Diagnosis: Spontaneous knot formation in central venous catheter
Symptoms: Central venous catheter whit any flow • associated with pain at the insertion site of the access
Medication: —
Clinical Procedure: Central venous catheterization
Specialty: General and Internal Medicine • Surgery**Objective:** Challenging differential diagnosis**Background:** Central venous catheterization (CVC) is indispensable in the management of critically ill patients in the emergency room and intensive care units, either to avoid the various peripheral punctures and vasoactive drugs administration in decompensated patients, or even to administer parenteral nutrition. CVC is an invasive procedure with possible mechanical, infectious, and thrombotic complications. The complete knotting of a catheter is a rare complication. The aim of this study is to report a case of a simple tight knot 2 cm from the catheter tip. We provide insights for early identification of catheter knotting, as well as its management.**Case Report:** A 63-year-old man with a previous history of angioplasty and non-pharmacological coronary stent in a marginal branch of the circumflex coronary artery evolved to junctional bradycardia and cardiogenic shock and was transferred to the reference hospital. He had a CVC inserted in the right jugular vein; however, it did not have any blood flow. The hypothesis of catheter knotting was suggested and confirmed through a chest X-ray. Venotomy was performed and it was successfully removed.**Conclusions:** Knotting in CVC obstruction is a rare complication. Recognition of this complication is essential to avoid major complications, such as catheter fragmentation and venous injury. Radiological follow-up after the procedure in patients with difficult anatomy is essential, and echo-guided catheterization should be encouraged when available. Despite the rarity of a knotted intravascular catheter, it is important to note this possible late complication that must be considered in the absence of catheter blood flow.**Keywords:** Catheterization, Central Venous • Diagnostic Techniques, Cardiovascular • Vascular Surgical ProceduresFull-text PDF: <https://www.amjcaserep.com/abstract/index/idArt/932354>


1733



—



2



44



Background

Access using intravascular devices is used in the management of patients under different indications to avoid the various peripheral punctures, or even in cardiopulmonary resuscitation and life-saving measures [1,2].

The devices most commonly used in intensive care units (ICU) are venous. The use of central venous catheterization (CVC) was first introduced by Dr. Werner Forssmann in 1929, who self-inserted a ureteral catheter into the cubital vein up to the right atrium [3]. In 1953, the catheterization technique was protocolized by the radiologist Sven Ivar Seldinger, using a metallic guidewire in the subclavian vein [4] and since then the access technique has become safe and is recommended by some authors [5].

Currently, the catheter is inserted mainly through a needle into the jugular, subclavian, or femoral veins using the Seldinger technique. The CVC can have 1, 2, or more routes, and the choice will depend on the therapeutic complexity [6]. Proper catheter maintenance is essential to minimize damage and achieve the longest useful catheter life [2].

Most treatments require prolonged time; therefore, it is important that CVCs have a long duration, either for general medications administration to decompensated patients [7] and hemodynamic monitoring when administering vasoactive drugs [8], or for parenteral diets [9,10].

CVC is an invasive procedure and, as such, it is not exempt from complications [7]. The location choice for the CVC passage depends on factors such as the physician's expertise with the technique, in identifying anatomical landmarks, and the risk of minor complications related to catheter insertion and manipulation [11].

Numerous mechanical, infectious, and thrombotic complications have been reported with use of CVCs [12,13]. Mechanical and thrombotic complications during catheter insertion include hematoma formation, pneumothorax, hemothorax, thrombosis, phlebitis, gas embolism, hemorrhage, and inadvertent arterial puncture [12]. Complications associated with catheter manipulation tend to be infections, such as sepsis [14].

A multicenter observational study with more than 10 000 patients found mechanical complications in 1.1% of patients undergoing CVC [15], and a retrospective ICU cohort study of 311 patients at a teaching hospital in Brazil reported a rate of 6% [16].

The knotting of an intravascular catheter is a very rare complication, first described in 1954 by Johansson et al [17].

The aim of this study is to report a case of a knot in the distal end of a mono-lumen CVC, formed after guidewire removal, inserted through the right internal jugular vein, and removed under local anesthesia. This study was approved by the Teaching and Research Committee – CAAE: 20940619.2.0000.5509.

Case Report

A 63-year-old male patient, a former smoker, with a previous angioplasty history and a non-pharmacological placement coronary stent in a marginal branch of the circumflex coronary artery 30 days before the current presentation, progressed to junctional bradycardia and cardiogenic shock.

He was transferred to the reference hospital ICU in the city of São Paulo/SP, Brazil. On admission, he was asymptomatic, with clinical and hemodynamic stability without the use of vasoactive drugs. He presented sinus rhythm and 99% oxygen saturation on room air.

He had a CVC inserted in the right jugular vein but without flow. As reported in medical records, the CVC was inserted through the right jugular without the aid of ultrasound, with blood flow and blood reflux present. There were no reports of difficulties or the number of catheterization intentions. However, when the patient was asked about the number of attempts to pass the catheter, he reported that more than one doctor tried the procedure. Efforts were made in an attempt to unblock the CVC, such as washing with saline solution and gentle catheter twisting, but without success. Thus, we opted for CVC removal and creating a new central access puncture. There was no difficulty in removal, up to about 2 cm for the catheter exteriorization, when some resistance was noted, with excessive catheter traction associated with pain at the CVC insertion site.

At that time, we considered the hypothesis of a knot close to the end of the catheter, and an anteroposterior chest X-ray was performed (**Figure 1**). After the diagnostic suspicion was confirmed, venotomy was performed under local anesthesia with 2% lidocaine without a vasoconstrictor. The catheter was successfully recovered without fragmentation, as analyzed after its removal (**Figure 2**).

Discussion

The use of CVC has become an essential procedure in ICU routine in the care of critically ill patients [18]. Although the procedure is generally safe, it is estimated that around 15% of patients admitted to the ICU have complications related to CVC [18,19].

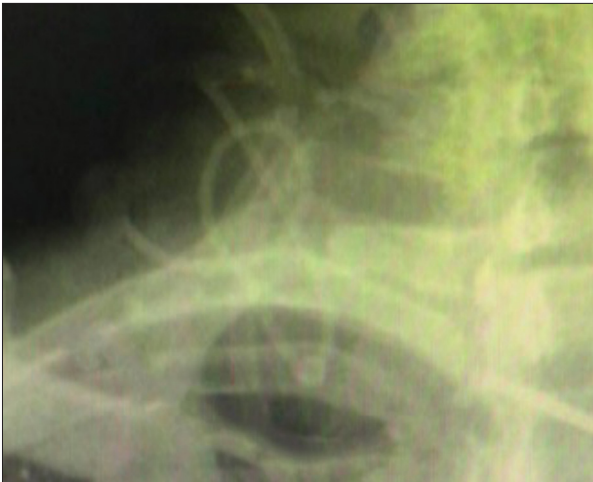

Figure 1. Enlarged chest X-ray, after an immediate attempt to remove catheter, suggesting a knot in the catheter, in addition to loop formation.

Catheter occlusion can occur due to a variety of conditions and even for no apparent reason. It is reported that this complication occurs in 36% of CVC cases [20]. Distal CVC obstruction is a rare complication [5,15], with most of the reported cases related to pulmonary artery catheters, probably because they are more flexible, longer, and do not have a guidewire [21].

In the 50 years from 1950 to 2000, only 113 cases of CVC knot were reported [21]. It is a serious complication that, in addition to the difficulties in its removal, can interrupt blood flow, require surgery and, depending on the location, lead to death [22].

CVC depends exclusively on human action, so some basic points must not be overlooked so that the benefits always outweigh the risks inherent in this invasive procedure. With this in mind, the team must be familiar with anatomical landmarks such as vascular anatomy and underlying structures; choose the exactly correct catheter type; should know the puncture site and the vascular insertion techniques; must strictly follow the described technique; be careful in asepsis and antisepsis in performing the puncture; and identify and recognize early complications and treat them [12].

Our patient was admitted at the unit with CVC installed, with no flow, and we only had basic information about the initial catheter passage procedure. We did not know the procedure details, the difficulties encountered, the number of attempts made, or even if there was a previous catheterization in the same vein. The fact attracted the doctors' attention because the inability to infuse solutions in the catheter lumen can lead to immediate therapy suspension and the need for a new procedure [23].

It is known that advancing a CVC without proper care can lead to knot formation [25], and making more attempts at catheterization



Figure 2. Single-lumen central venous catheter with a knot about 2.0 cm from the tip, after removal by venotomy under local anesthesia.

is associated with higher risk of complications [6,24]. As with the vein cannulation previously used for CVC, thrombus formation is common, and thrombosis is also a potential cause of the formation of a loop, entanglement, and knotting [26].

CVC knot cases have been reported in neonates for more than 30 years. Being careful not to advance the catheter too far in the vein of choice helps prevent this complication [25].

Some practices are recommended by the American agency responsible for research and quality in health care with the aim of increasing safety in the management of CVCs, with the use of ultrasound to guide central venous punctures being one of them. This recommendation was based on a meta-analysis that reviewed 8 randomized clinical trials [27]. A prospective multicenter study showed that the echo-guided technique is a diagnostic modality with moderate sensitivity and high specificity to detect poor catheter positioning [28]. Ultrasound makes it possible to assess the vein that will be punctured under direct vision, reducing accidents and other complications [18], and when available, its use should be encouraged [27,29], even in children [30]. In this present study, such a procedure was not available.

A simple chest X-ray to confirm the final catheter position should always be requested immediately after catheter insertion, identifying possible complications that may have gone unnoticed [31]. Radiological follow-up after the procedure in patients with difficult anatomy is essential [32]. Some authors recommend performing a late chest X-ray in the presence of any possible complication [33], just as was done in our patient.

The internal jugular vein, chosen for venous access in present case, allows a high success rate in puncture, together with low rates of serious complications [34]. A higher rate of infection and thrombosis is described when CVC is performed through the femoral vein, in comparison with the subclavian vein [11,35,36].

In the present case, the professional's experience in immediately suspecting a late CVC complication was essential to avoid major complications, such as catheter fragmentation and venous injury. However, it was not possible to exactly determine the cause of its formation. We believe that the various previous attempts of catheterization of the central vein reported by the patient, as well as a probable blood whirling caused by the cardiac arrhythmia, or else a possible improper catheter traction during the patient transfer, may have contributed to the knot formation.

Catheter wire entanglement usually results in a knot, as seen in this case, in which there was a loop in the catheter. There are several options reported in these cases regarding the possibility of removing the catheter: traction application, in which the knot (of entanglement or loop) is tightened with the catheter removal done smoothly through an enlarged insertion site [37], venotomy under local anesthesia [38,39], and knot manipulation under fluoroscopy by radiology [40]. In some cases, surgical procedures may also be necessary [41]. In a 2002

literature review, 36% of cases required a surgical procedure to remove the catheter knot, and it was associated with the knot location [21].

To reduce the risk of this occurrence, when catheters are introduced, some precautions are needed, such as incision in the skin at an adequate depth, elimination of excessive force when inserting the vessel dilator and catheter on it, keeping its introduction absolutely immobilized without abrupt maneuvers [42], observing the fluid flow as the catheter is inserted, and not advancing the catheter when there is resistance [26,43].

Such efforts to prevent complications should be routinely adopted, improving the safety and quality of care in ICUs. All these precautions improve the doctor's ability to effectively neutralize problems in the clinical environment, and they need to be combined and integrated [44].

Conclusions

Despite the rarity of intravascular catheter knots, it is important to note that this is a possible late complication that must be considered when there is absence of flow and difficulty of withdrawal associated with referred local pain.

Conflicts of Interest

None declared.

Declaration of Figures Authenticity

All figures submitted have been created by the authors who confirm that the images are original with no duplication and have not been previously published in whole or in part.

References:

1. Marcondes CRR, Biojone CR, Cherri J, et al. [Early and late complications in central venous access. Analysis of 66 implants.]. *Acta Cir Bras*. 2000;15(Suppl. 2):73-75 [in Portuguese]
2. Lee KA, Ramaswamy RS. Intravascular access devices from an interventional radiology perspective: indications, implantation techniques, and optimizing patency. *Transfusion*. 2018;58(February):549-57
3. Forssmann W. [Probing the right heart.]. *Klin Wochenschr* [Internet]. 1929;8(45):2085-87 [in German]
4. Seldinger SI. Catheter replacement of the needle in percutaneous arteriography: A new technique. *Acta Radiol* [Internet]. 1953;39(5):368-76
5. Patel AR, Patel AR, Singh S, et al. Central line catheters and associated complications: A review. *Cureus*. 2019;11(5):e4717
6. Joana A, Miguel F, Oliveira D, et al. [Infection associated with the central venous catheter – literature review.]. *Rev Enferm Ref*. 2009;11(1):125-33 [in Portuguese]
7. Lockwood J, Desai N. Central venous access. *Br J Hosp Med*. 2019;80(8):C114-19
8. Takashima M, Ray-Barruel G, Ullman A, et al. Randomized controlled trials in central vascular access devices: A scoping review. *PLoS One*. 2017;12(3):1-23
9. Diener JR, Coutinho MS, Zoccoli CM. [Central venous catheter-related infections in critically ill patients.]. *Rev Assoc Med Bras*. 42(4):205-14 [in Portuguese]
10. Jamshidi R. Central venous catheters: Indications, techniques, and complications. *Semin Pediatr Surg*. 2019;28(1):26-32
11. Bannon MP, Heller SF, Rivera M. Anatomic considerations for central venous cannulation. *Risk Manag Healthc Policy*. 2011;4:27-39
12. Araújo S. [Central venous and peripheral arterial accesses – technical and practical aspects.]. *Rev Bras Ter Intensiva*. 2003;15(2):70-82 [in Portuguese]
13. Mitchell S, Clark R. Complications of central venous catheterization. *Am J Roentgenol*. 1979;133(3):467-76
14. Hanauer LPT, Comerlato PH, Papke A, et al. Reducing central vein catheterization complications with a focused educational program: A retrospective cohort study. *Sci Rep*. 2020;10(1):17530
15. Björkander M, Bentzer P, Schött U, et al. Mechanical complications of central venous catheter insertions: A retrospective multicenter study of incidence and risks. *Acta Anaesthesiol Scand*. 2019;63(1):61-68

16. Comerlato PH, Rebelatto TF, De Almeida FAS, et al. Complications of central venous catheter insertion in a teaching hospital. *Rev Assoc Med Bras.* 2017;63(7):613-20
17. Johansson L, Malmstrom G, Uggliä LG. Intracardiac knotting of the catheter in heart catheterization. *J Thorac Surg.* 1954;27(6):605-7
18. Zerati AE, Wolosker N, Luccia N de, Puech-Leão P. [Fully implantable venous catheters: History, implant technique, and complications]. *J Vasc Bras.* 2017;16(2):128-39 [in Portuguese]
19. Taylor RW, Palagiri AV. Central venous catheterization. *Crit Care Med.* 2007;35(5):1390-96
20. Baskin JL, Pui C-H, Reiss U, et al. Management of occlusion and thrombosis associated with long-term indwelling central venous catheters. *Lancet.* 2009;374(9684):159-69
21. Karanikas ID, Polychronidis A, Vrachatis A, et al. Removal of knotted intravascular devices. Case report and review of the literature. *Eur J Vasc Endovasc Surg.* 2002;23(3):189-94
22. Kumar SP. Removal of a knotted flow-directed catheter by a nonsurgical method. *Ann Intern Med.* 1980;92(5):639
23. Danski MTR, Da Silva SR, Pontes L, Pedrolo E. [Educational action for standardization in hickman catheter management.] *Cogitare Enferm.* 2018;23(3):54488 [in Portuguese]
24. Lefrant J-Y, Muller L, De La Coussaye J-E, et al. Risk factors of failure and immediate complication of subclavian vein catheterization in critically ill patients. *Intensive Care Med.* 2002;28(8):1036-41
25. Arad I, Haskel Y, Vinograd I. A knot of the subclavian venous catheter in a premature neonate. *Am J Perinatol.* 1985;2(1):15-16
26. Ikeda S, Shirley LD, Schweiss JF. Triple knotting of a central venous catheter. *J Clin Anesth.* 1989;1(3):218-21
27. Dexheimer Neto FL, Teixeira C, Oliveira RP de. [Ultrasound-guided central venous access: What is the evidence?] *Rev Bras Ter Intensiva.* 2011;23(2):217-21 [in Portuguese]
28. Smit JM, Haaksma ME, Lim EHT, et al. Ultrasound to detect central venous catheter placement associated complications: A multicenter diagnostic accuracy study. *Anesthesiology.* 2020;(4):781-94
29. Millington SJ, Lalu MM, Boivin M, Koenig S. better with ultrasound: Subclavian central venous catheter insertion. *Chest.* 2019;155(5):1041-48
30. Lau CSM, Chamberlain RS. Ultrasound-guided central venous catheter placement increases success rates in pediatric patients: A meta-analysis. *Pediatr Res.* 2016;80(2):178-84
31. Wang HE, Sweeney TA. Subclavian central venous catheterization complicated by guidewire looping and entrapment. *J Emerg Med.* 1999;17(4):721-24
32. Erkiñç E, Aksoy M, Gümüş T, et al. Jugular venous catheterization: A case of knotting. *Case Rep Med.* 2015;2015:810346
33. Roy G, Cheriyan A, Rymbai M. How is that? Knotting of a peripherally inserted central venous catheter. *Indian J Anaesth.* 2010;54(3):272-74
34. Asari AIA, Barros RAV, Borges MAP. Anatomical variation of the internal jugular vein and its importance in vascular access for hemodialysis. *J Vasc Bras.* 2019;18:e20190014
35. Timsit JF, Baleine J, Bernard L, et al. Expert consensus-based clinical practice guidelines management of intravascular catheters in the Intensive Care Unit. *Ann Intensive Care.* 2020;10(1):118
36. Merrer J. Complications of femoral and subclavian venous catheterization in critically ill patients a randomized controlled trial. *JAMA.* 2001;286(6):700
37. Shirvani A, Zadeh M. The role of routine chest radiography for detecting complications after central venous catheter insertion. *Saudi J Kidney Dis Transplant.* 2014;25(5):1011
38. Karahan N, Yetkin U, Takut N, et al. Approach to swan ganz thermodilution catheter complications: 6 years experience with 2310 cases. *Internet J Thorac Cardiovasc Surg.* 2007;11:5957
39. Hida S, Ohashi S, Kinoshita H, et al. Knotting of two central venous catheters: A rare complication of pulmonary artery catheterization. *J Anesth.* 2010;24(3):486-87
40. Vetrugno L, Piccoli G, Costa MG, et al. The dos and do knots of central venous catheterization. *J Clin Anesth.* 2012;24(2):148-50
41. Graff J, Gong R, Byron R, Hassett JM. Knotting and entanglement of multiple central venous catheters. *J Parenter Enter Nutr.* 1986;10(3):319-21
42. Olsfänger D, Jedeiken R, Fredman B, Ben-Or A. Intertwining and knotting of a guidewire with a central venous catheter. *Chest.* 1993;104(2):623-24
43. Safety Committee of Japanese Society of Anesthesiologists. Practical guide for safe central venous catheterization and management 2017. *J Anesth.* 2020;34(2):167-86
44. Saugel B, Scheeren TWL, Teboul JL. Ultrasound-guided central venous catheter placement: A structured review and recommendations for clinical practice. *Crit Care.* 2017;21(1):225