



EUS-guided ileocolonic anastomosis for relief of complete small-bowel obstruction

Theodore W. James, MD, MSc, Rahman Nakshabendi, MD, Todd H. Baron, MD

Small-bowel obstruction (SBO) is typically managed with gastric decompression and intravenous hydration; however, when conservative management fails, operative management is necessary.¹ In cases of extrinsic compression from adhesive disease, laparotomy with lysis of adhesions is often required.² Patients with high-grade obstruction who do not proceed to operative management are at risk for bowel perforation and septic shock from peritonitis.³ However, many patients either fail operative management or are not candidates for surgery because of comorbidities.⁴ Endoscopic management of distal SBO is most effective in short strictures without high-grade obstruction.⁵ A nonsurgical method for treating SBO in patients unfit for surgery has the potential to improve clinical outcomes for a challenging patient population. The aim of this video (Video 1, available online at www.VideoGIE.org) was to describe the EUS-directed ileocolonic anastomosis technique in the nonoperative management of distal SBO.

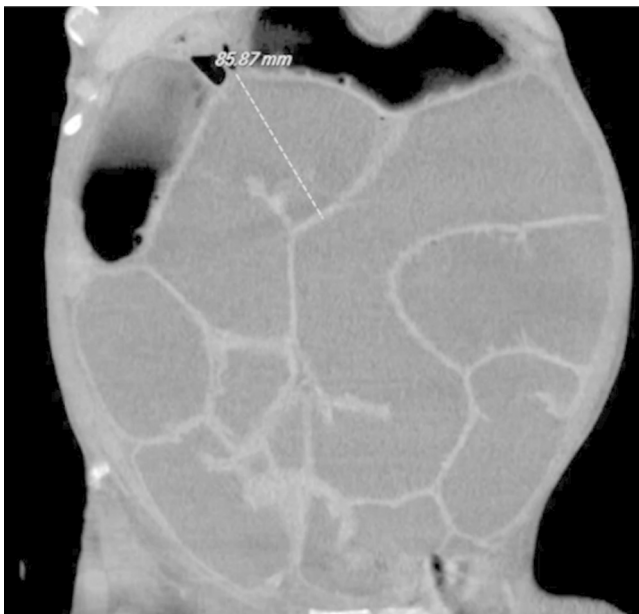


Figure 1. CT of the abdomen and pelvis demonstrating massively dilated small-bowel loops proximal to the obstruction at the ileocolonic anastomosis.

TECHNIQUE DESCRIPTION

EUS-directed ileocolonic anastomosis is performed with the patient under general anesthesia. A forward-viewing curvilinear array echoendoscope (TGF-UC180J; Olympus, Central Valley, Pa, USA) is inserted and advanced into the right colon segment, as close to the SBO transition point as possible. Under fluoroscopic guidance, we pass the echoendoscope to the proximal right colon segment, and echo is used to visualize the dilated small bowel. A lumen-apposing metal stent (LAMS) with electrocautery-enhanced tip (AXIOS-EC; Boston Scientific, Natick, Mass, USA) is advanced across the colonic wall into the target ileum. The distal flange of the LAMS is deployed under EUS guidance and the proximal end of the stent under direct endoscopic visualization. Optionally, the LAMS is then dilated with a through-the-scope balloon dilator to allow passage of the endoscope into the small bowel. Under fluoroscopy, contrast is injected to confirm placement of the LAMS across the lumina and absence of leakage.

CASE

A 65-year-old man with a history of HIV infection (CD4: 347), chronic obstructive pulmonary disease, hypertension, and anal squamous cell carcinoma who had

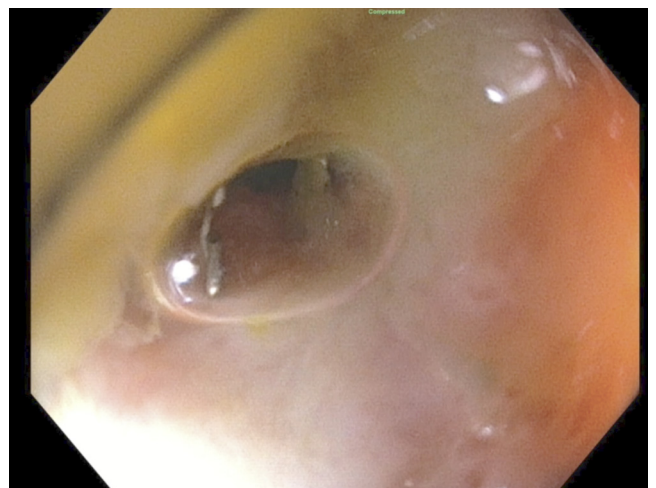


Figure 2. Endoscopic view of the stenosis at the ileocolonic anastomosis.

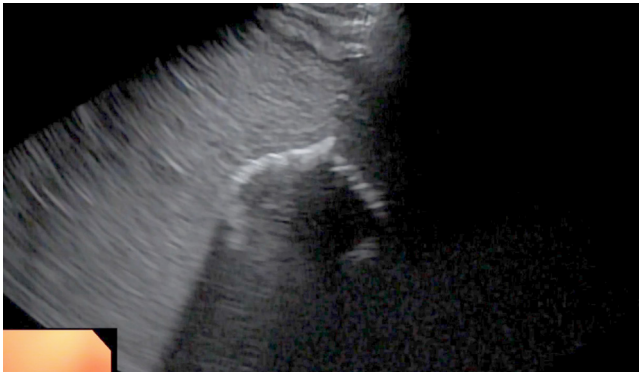


Figure 3. EUS view of the distal flange of the lumen-apposing metal stent deployed within the small bowel.

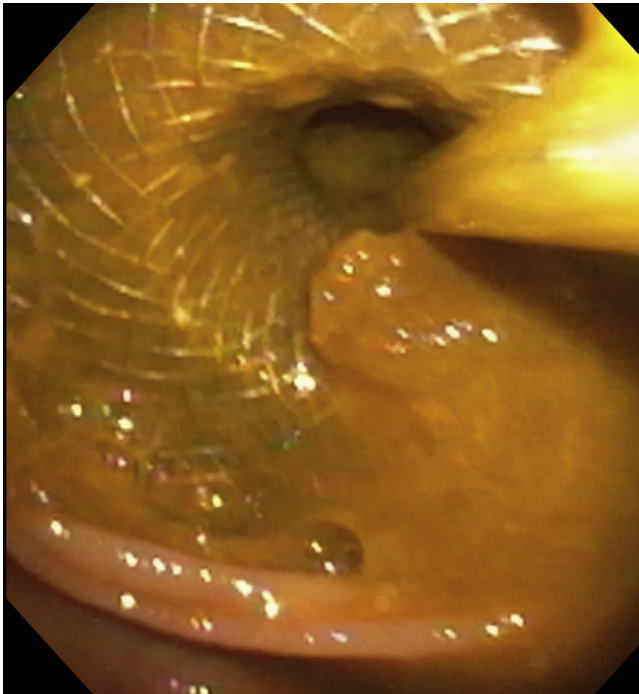


Figure 4. Endoscopic view from the colon of the lumen-apposing metal stent forming an ileocolonic anastomosis.

undergone diverting colostomy, ileocectomy with ileocolonic anastomosis, and adjuvant chemoradiation developed recurrent SBO. After an extended admission at our institution for SBO with failure of conservative treatment, the patient underwent surgical management with laparotomy and lysis of adhesions; a gastrostomy tube was placed at that time for gastric decompression. He was readmitted 3 additional times for recurrent SBO, which was managed conservatively.

He presented again with a complete SBO with no ostomy output for 1 week and increased gastrostomy tube drainage. A CT scan of the abdomen and pelvis demonstrated massively dilated small-bowel loops with a

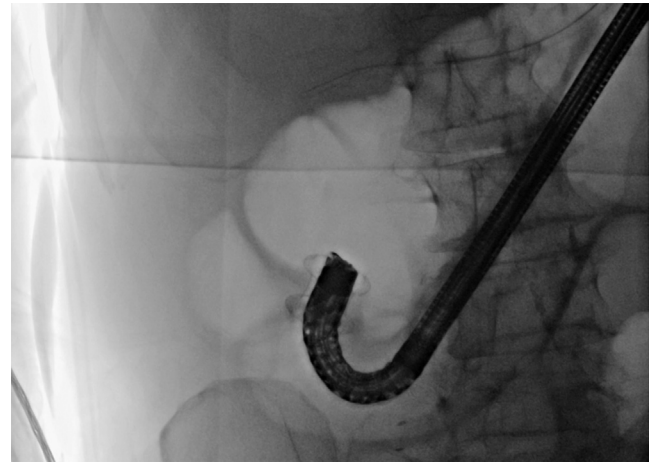


Figure 5. Fluoroscopic image of the lumen-apposing metal stent forming an ileocolonic anastomosis through which the forward-viewing echoendoscope is passed into the ileum.

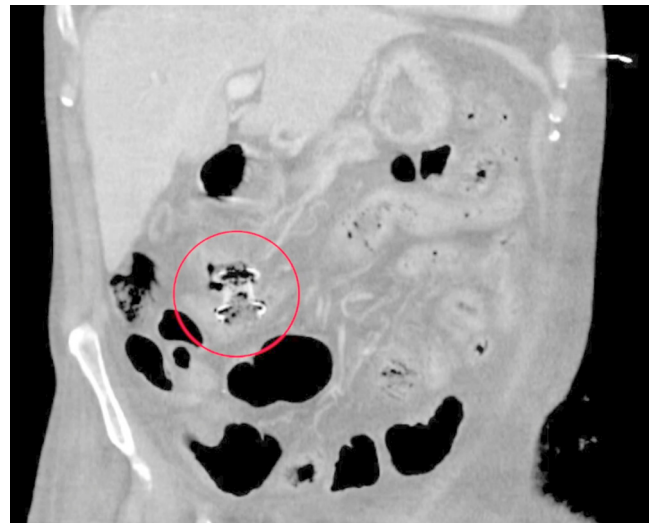


Figure 6. CT of the abdomen and pelvis 9 months postprocedure demonstrating the lumen-apposing metal stent in good position with interval resolution of the dilated bowel.

high-grade obstruction at the level of the ileocolonic anastomosis without associated mass (Fig. 1). He was started on intravenous fluids, and a nasogastric tube was placed. Blood cultures were collected and found to be positive for coagulase-negative *Staphylococcus*; he was started on vancomycin and cefepime. Colonoscopy was performed and demonstrated complete obliteration of the lumen at the ileocolonic anastomosis (Fig. 2). He was deemed to be a poor surgical candidate because of his prior surgeries and was referred for further management.

A forward-viewing echoendoscope was inserted into the colostomy and advanced into the right colon segment. Under fluoroscopy, the echoendoscope was positioned in the proximal transverse colon. The endosonographic view

demonstrated a markedly dilated small bowel. Using a LAMS with electrocautery, we advanced a 20- × 20-mm stent across the colonic wall into the ileum (Fig. 3). Using a 20-mm through-the-scope balloon dilator, we dilated the stent to its fully expanded diameter (Fig. 4). The endoscope was advanced into the small bowel, and contrast injection confirmed excellent placement without leakage (Fig. 5).

The patient tolerated the procedure well without adverse events. Within 12 hours, his nasogastric tube was removed and he was tolerating a liquid diet; by 48 hours after the procedure he was tolerating a regular diet. There were no adverse events (Fig. 6).

In conclusion, EUS-directed ileocolonic anastomosis is a novel approach to the management of SBO. The advent of LAMSs has made bypass of a bowel obstruction possible. Further study is needed to determine optimal patient selection.

DISCLOSURE

Dr Baron is a consultant and speaker for Boston Scientific, W.L. Gore, Cook Endoscopy, and Olympus America. Dr James receives research and training support by a grant from the NIH (T32DK007634). All other authors

declare no relevant funding for this work. All other authors disclosed no financial relationships.

Abbreviations: LAMS, lumen-apposing metal stent; SBO, small-bowel obstruction.

REFERENCES

1. Tanaka S, Yamamoto T, Kubota D, et al. Predictive factors for surgical indication in adhesive small bowel obstruction. *Am J Surg* 2008;196:23-7.
2. Hayanga AJ, Bass-Wilkins K, Bulkley GB. Current management of small-bowel obstruction. *Adv Surg* 2005;39:1-33.
3. Foster NM, McGory ML, Zingmond DS, et al. Small bowel obstruction: a population-based appraisal. *J Am Coll Surg* 2006;203:170-6.
4. Barkan H, Webster S, Ozeran S. Factors predicting the recurrence of adhesive small-bowel obstruction. *Am J Surg* 1995;170:361-5.
5. Hirai F, Beppu T, Takatsu N, et al. Long-term outcome of endoscopic balloon dilation for small bowel strictures in patients with Crohn's disease. *Dig Endosc* 2014;26:545-51.

Division of Gastroenterology and Hepatology, University of North Carolina, Chapel Hill, North Carolina.

Copyright © 2020 American Society for Gastrointestinal Endoscopy. Published by Elsevier Inc. This is an open access article under the CC BY-NC-ND license (<http://creativecommons.org/licenses/by-nc-nd/4.0/>).

<https://doi.org/10.1016/j.vgie.2020.05.004>

Twitter

Become a follower of *VideoGIE* on Twitter. Learn when new articles are posted and receive up-to-the-minute news as well as links to our latest videos. Search @VideoGIE on Twitter.