

Dual thyroid ectopia-role of thyroid scintigraphy and neck ultrasonography

Tarun Kumar Jain, Ram Singh Meena, Anmol Bhatia¹, Ashwani Sood, Anish Bhattacharya, Bhagwant Rai Mittal

Departments of Nuclear Medicine and PET and ¹Radiodiagnosis, Postgraduate Institute of Medical Education and Research, Chandigarh, India

ABSTRACT

Ectopic thyroid tissue (ETT) is a rare developmental anomaly of the thyroid tissue where the thyroid gland is not located in its usual position. Dual thyroid ectopia is far rarer. This case of a 5-year-old euthyroid girl with thyroglossal cyst was planned for surgery. Presurgical ultrasonography (USG) of the neck followed by thyroid scintigraphy was performed. There was absent normal thyroid gland with single ETT in neck swelling on USG. However, thyroid scintigraphy revealed two ectopic foci of thyroid tissue; one was corresponding to neck swelling, and other was superior to it at the base of the tongue along with absent eutopic thyroid gland. The repeat neck USG could demonstrate the same. The present case emphasizes that, if the thyroid gland is not visible by USG; ETT should be evaluated with thyroid scintigraphy in case of thyroid dysgenesis.

Keywords: Dual ectopic thyroid, thyroglossal cyst, thyroid scintigraphy, ultrasonography

INTRODUCTION

Thyroid tissue develops with the appearance of anlage of the thyroid within the embryo as a midline structure. It descends as part of the thyroglossal duct to the thyroid bed. The thyroid anlage develops into thyroid lobes bilaterally and thyroglossal duct gets obliterated in the normal course. However a persistent duct may lead to cyst. Thyroglossal duct cyst usually present as painless midline or paramedian structure. The abnormal migration or developmental defects of the thyroid gland may result into ectopic thyroid tissue (ETT), which may be found along the tract of the thyroglossal duct.^[1] ETT is a rare congenital anomaly and finding the dual thyroid ectopia is very rare. It presents as midline neck swelling at the base of tongue in the majority of patients with less common sites include sublingual, cervical, mediastinal or abdominal region.^[2,3] The patients may have the only functioning ETT in the body found on imaging. The clinical examination, ultrasonography (USG) of neck, thyroid scintigraphy and occasional computed tomography (CT) scan are usually undertaken for the detailed

evaluation before planning any surgical intervention for a thyroglossal cyst.

CASE REPORT

The authors present a case of 5-year-old girl presented with gradually increasing midline swelling in the upper part of the neck since birth [Figure 1a]. It was moving on deglutination and tongue protrusion with a provisional diagnosis of the thyroglossal cyst. The thyroid function tests were normal (T3 – 5.6 pmol/L [3.5–6.5], T4 – 13 pmol/L [9–25] and thyroid-stimulating hormone – 2.0 mIU/L [0.35–5.50]). The USG neck showed homogenous thyroid tissue in the right para-midline location with increased blood flow corresponding to clinically palpable neck swelling and absence of eutopic thyroid gland. The thyroid scan was performed with 3 mCi of Tc-99m pertechnetate I/V injection. The scan showed no tracer uptake in the thyroid bed with two distinct foci of increased tracer uptake in the upper cervical region [Figure 1b and c]. Repeat images with a radioactive marker on neck swelling revealed the lower focus of tracer uptake corresponding to the cervical swelling and another focus of tracer uptake at the base of the tongue. The scan was reported as dual ectopic functioning thyroid tissue with no eutopic thyroid gland. The repeat USG neck also revealed additional ectopic hyperechoic tissue in the tongue base region similar to the scan findings [Figure 2a-d]. In view of the thyroid scintigraphy and USG neck findings, the excision of the swelling was deferred.

Access this article online

Quick Response Code:



Website:
www.ijnm.in

DOI:
10.4103/0972-3919.164023

Address for correspondence:

Dr. Ashwani Sood, Department of Nuclear Medicine and PET, Postgraduate Institute of Medical Education and Research, Chandigarh - 160 012, India. E-mail: sood99@yahoo.com

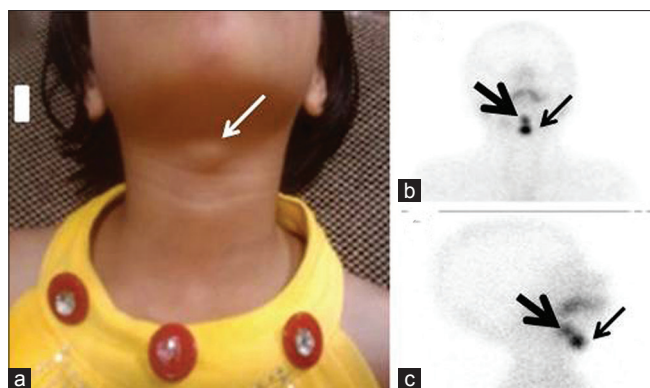


Figure 1: (a) Clinical photograph of the girl with a midline neck swelling; (b and c) Thyroid scan (anterior and lateral view) showed no tracer uptake in thyroid bed with two distinct foci of increased tracer uptake in upper cervical region (thin arrow corresponded to neck swelling and thick arrow for another focal tracer uptake superiorly)

DISCUSSION

Thyroid dysgenesis is usually manifested as ETT, athyreosis, thyroid gland hypoplasia or hemiagenesis.^[4] Thyroid USG and scintigraphy are used to image the patients with thyroid dysgenesis. USG is helpful to demonstrate ectopic thyroid tissue, however if not seen by USG; then thyroid scintigraphy is required to differentiate whether patient has athyreosis or ectopia. Thyroid USG is not very accurate in differentiating ectopia or athyreosis in the absence of thyroid gland at normal position.^[5] The USG has a variable range from 0% to 21% in detecting the ETT,^[6-9] though color Doppler US has higher detection rate.^[10] In the present case, initial USG neck showed single ETT in the neck with the absence of thyroid tissue in thyroid bed. The thyroid scintigraphy demonstrated dual ETT along with absent ectopic thyroid tissue and follow-up USG also revealed them. It showed that scintigraphy was better than USG neck in detecting the additional thyroid ectopia. So far approximately 50 odd cases have been reported in the literature and most of them are case reports. The majority of patients with dual ectopic thyroid were under 30 years and presented almost equally either with euthyroid, subclinical or overt hypothyroid status.^[11] It had been observed that patient reporting in early age group had euthyroid status, which could be explained that there was less thyroid hormone requirement in prepubertal age group and could be easily met initially. The age of our patient was 5 years, which could explain the presence of normal thyroid function tests. A search of the PubMed literature showed few case reports of dual thyroid ectopia, where both USG neck and thyroid scan were helpful in right management of patients.

A study done by Karakoc-Aydiner *et al.*, in 82 patients with different causes for thyroid dysgenesis, USG precisely detected thyroid agenesis in the patients by showing absence of detectable thyroid tissue; however it fared poorly in detecting thyroid ectopia and majority of them were missed when USG was the only imaging modality. Thyroid scintigraphy demonstrated high sensitivity and specificity in detecting the ETT.^[12] Similarly in a

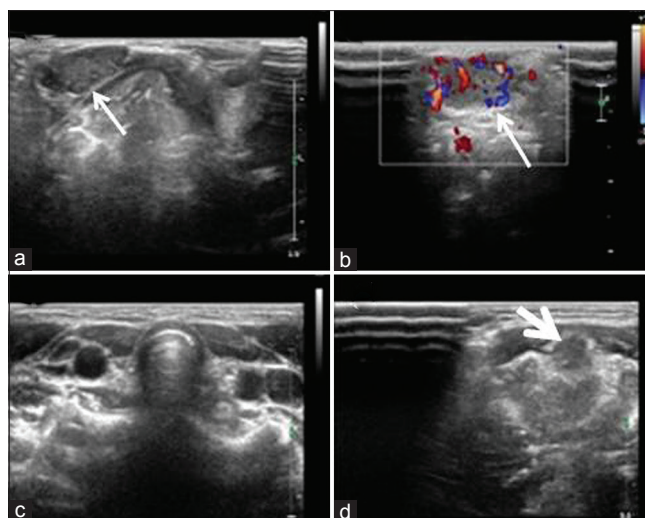


Figure 2: (a-c) Gray scale transverse ultrasound neck images done before thyroid scan showed homogenous thyroid tissue in the right para-midline location in the cervical region with absent thyroid tissue in thyroid bed, color Doppler showed increased vascularity in thyroid tissue (thin arrow); (d) Repeat ultrasound of upper neck region showed additional small homogenous soft tissue nodule, similar in echogenicity to thyroid tissue (thick arrow)

case report of dual ETT by Markovic *et al.*, the initial thyroid USG revealed empty thyroid bed and no ETT in neck, however dual ectopic lingual and sublingual thyroid tissues were established by thyroid scintigraphy and contrast-enhanced CT (CT) neck, which was also shown by USG through the mouth on the repeat study.^[13]

The majority of dual thyroid ectopia is diagnosed with the help of thyroid scintigraphy but in some of the cases, USG and CT neck had also been used as an additional imaging modality. In the present case, we have presented the findings of thyroid scintigraphy as well as of USG neck. The ectopic lingual thyroid tissue missed initially on USG neck, was seen on repeat USG while thyroid scan done between two USG studies clearly demonstrated dual ETT. So in case of thyroid dysgenesis, both the imaging modalities should be used as complimentary rather than competing with each other for better patient's management.

CONCLUSION

This case clearly illustrates that thyroid scintigraphic imaging is a valuable imaging modality in revealing ETT, which may be missed on USG neck images. Though USG is a better modality in absent thyroid tissue in the thyroid bed, but combining the both modalities may give the better answer that would be helpful in correct patient management decision.

REFERENCES

- De Felice M, Di Lauro R. Thyroid development and its disorders: Genetics and molecular mechanisms. *Endocr Rev* 2004;25:722-46.
- Pintar JE, Allerand CD. Normal development of the hypothalamic-pituitary-thyroid axis. In: Braverman LE, Utiger RD, editors. *Werner and Ingbar's the Thyroid*. 6th ed. Philadelphia: Lippincott; 1991. p. 11-4.

3. Sood A, Sood V, Sharma DR, Seam RK, Kumar R. Thyroid scintigraphy in detecting dual ectopic thyroid: A review. *Eur J Nucl Med Mol Imaging* 2008;35:843-6.
4. Kaplan EL, Shukla M, Hara H, Ito K. Developmental abnormalities of the thyroid. In: De Groot LJ, editor. *Endocrinology*. Philadelphia: Saunders; 1994. p. 893-9.
5. Panoutsopoulos G, Mengreli C, Ilias I, Batsakis C, Christakopoulou I. Scintigraphic evaluation of primary congenital hypothyroidism: Results of the Greek screening program. *Eur J Nucl Med* 2001;28:529-33.
6. Takashima S, Nomura N, Tanaka H, Itoh Y, Miki K, Harada T. Congenital hypothyroidism: Assessment with ultrasound. *AJNR Am J Neuroradiol* 1995;16:1117-23.
7. Niu DM, Chao T, Tiu CM, Chou YH, Chu YK, Hwang B. Comparison of radioisotopic and ultrasonic scanning in the evaluation of neonatal hypothyroidism. *Zhonghua Yi Xue Za Zhi (Taipei)* 1995;56:345-50.
8. Bubuteishvili L, Garel C, Czernichow P, Léger J. Thyroid abnormalities by ultrasonography in neonates with congenital hypothyroidism. *J Pediatr* 2003;143:759-64.
9. De Bruyn R, Ng WK, Taylor J, Campbell F, Mitton SG, Dicks-Mireaux C, *et al.* Neonatal hypothyroidism: Comparison of radioisotope and ultrasound imaging in 54 cases. *Acta Paediatr Scand* 1990;79:1194-8.
10. Tamam M, Adalet I, Bakir B, Türkmen C, Darendeliler F, Bas F, *et al.* Diagnostic spectrum of congenital hypothyroidism in Turkish children. *Pediatr Int* 2009;51:464-8.
11. Meng Z, Lou S, Tan J, Jia Q, Zheng R, Liu G, *et al.* Scintigraphic detection of dual ectopic thyroid tissue: Experience of a Chinese tertiary hospital. *PLoS One* 2014;9:e95686.
12. Karakoc-Aydiner E, Turan S, Akpınar I, Dede F, Isgüven P, Adal E, *et al.* Pitfalls in the diagnosis of thyroid dysgenesis by thyroid ultrasonography and scintigraphy. *Eur J Endocrinol* 2012;166:43-8.
13. Markovic V, Glavina G, Eterovic D, Punda A, Brdar D. Dual ectopic thyroid gland: Sonography and scintigraphy of lingual and sublingual thyroid. *Clin Nucl Med* 2014;39:556-8.

How to cite this article: Jain TK, Meena RS, Bhatia A, Sood A, Bhattacharya A, Mittal BR. Dual thyroid ectopia-role of thyroid scintigraphy and neck ultrasonography. *Indian J Nucl Med* 2015;30:338-40.

Source of Support: Nil. **Conflict of Interest:** None declared.