

Secondary Corneal Myxoma After DMEK (Descemet Membrane Endothelial Keratoplasty)

Authors' Contribution:
Study Design A
Data Collection B
Statistical Analysis C
Data Interpretation D
Manuscript Preparation E
Literature Search F
Funds Collection G

ABCDEF 1 **Dimitri Chaussard**
CDE 2 **Eric Frouin**
AE 1 **Julie Francois**
D 1 **Maxime Sot**
D 3 **Elena-Adinisia Paraschiv**
ABCDEF 1 **Jean-Marc Perone**

1 Department of Ophthalmology, Regional Hospital Center of Metz-Thionville Mercy Hospital, Metz, France
2 Department of Pathological Anatomy and Cytology, University Hospital Center of Poitiers, Poitiers, France
3 Department of Pathological Anatomy and Cytology, Regional Hospital Center of Metz-Thionville, Mercy Hospital, Metz, France

Corresponding Author: Jean-Marc Perone, e-mail: jm.perone@chr-metz-thionville.fr
Conflict of interest: None declared

Patient: Male, 52
Final Diagnosis: Secondary corneal myxoma
Symptoms: Red eye
Medication: —
Clinical Procedure: Surgical treatment
Specialty: Ophthalmology





Objective: Unusual clinical course
Background: This is a clinical case of secondary corneal myxoma, which developed 18 months after Descemet membrane endothelial keratoplasty (DMEK). The DMEK was performed to treat viral endotheliitis and, postoperatively, a diagnosis of Crohn's disease was made.

Case Report: A 52-year-old male, with no prior clinical history, presented with an endotheliitis in the left eye. The hypothesis of an undetected herpes infection was favored, and an antiviral treatment was prescribed using valacyclovir (1 g orally, 3 times daily). After 3 months of antiviral treatment, the endotheliitis was successfully controlled and a combined intervention of DMEK endothelial graft and phacoemulsification was performed. A corneal tumor was found 18 months after a successful DMEK procedure and was surgically removed. A pathological examination revealed a secondary corneal myxoma.

Conclusions: Corneal myxomas are rare lesions, often secondary to trauma in the Bowman's membrane, which is why it is often called a myxomatous corneal degeneration. In this instance, there is no link with Carney complex. However, myxomas under the eyelid or within the orbit are often associated with cardiac myxomas. Treatment is strictly surgical, either by simple excision or by surgical excision followed by graft. To the best of our knowledge, this is the first time that such an association between DMEK and secondary corneal myxoma has been described in the literature.

MeSH Keywords: Cornea • Eye Abnormalities • Myxoma

Full-text PDF: <https://www.amjcaserep.com/abstract/index/idArt/917641>

 1412  1  6  22



Background

Myxomas are rare benign tumors that appear in mesenchymal tissue, mainly in peripheral muscles and the heart, particularly the left atrium [1,2]. Myxomas can also develop in periarticular areas and in the skin. They can be isolated or in association with Carney complex [3–6]. In ophthalmology, myxomas can be found under the eyelid [7], in the conjunctiva, and in the cornea, and only 20 cases of corneal myxoma have been reported [8–13].

In the cornea, myxomas are divided into categories of primary tumoral lesions and secondary lesions, following a pre-existent corneal or conjunctival lesion, also known as secondary myxomas, or myxomatous corneal degeneration.

Here, we report a case of secondary corneal myxoma, which developed following a viral endotheliitis, treated with a Descemet membrane endothelial keratoplasty (DMEK) lamellar graft.

Case Report

A 52-year-old male, with no prior clinical history, presented in March 2016, with an endotheliitis in the left eye. The endotheliitis seemed to have evolved over several months, and the patient mainly complained of visual acuity loss.

The initial slit-lamp examination showed an important conjunctival hyperemia, an altered ocular surface with superficial keratitis and corneal hypesthesia, an inflammatory reaction in the anterior chamber with a grade 3+ Tyndall effect according to the SUN (Standardization of Uveitis Nomenclature), and an endothelial decompensation, with corneal edema and Descemet folds.

Paraclinical explorations did not allow the etiology to be determined. The genome of herpes simplex virus was searched by polymerase chain reaction (PCR) after a puncture of the anterior chamber, which yielded negative results. The hypothesis of an undetected herpes infection was favored, and an antiviral treatment was prescribed, using valacyclovir (1 g orally, 3 times daily).

After 3 months of antiviral treatment, the endotheliitis was successfully controlled and a combined intervention of DMEK endothelial graft and phacoemulsification was performed. The best corrected visual acuity (BCVA) of the left eye prior to the intervention was 1.3 logmar.

The inflammatory reaction in the anterior chamber was controlled, but there was still a pathologic ocular surface with conjunctival hyperemia, despite treatment with lubricants.

Postoperative treatment consisted of Cosopt® (eye drop, dorzolamide 2%+timolol 0.5%; Santen France), Tobradex® (eye drop, tobramycin and dexamethasone, Alcon, Novartis Pharmaceuticals, France), and antiviral treatment, valacyclovir (1 g orally, 3 times daily).

A rapid improvement of BCVA was observed 15 days after the intervention (0.05 logmar), and after 6 weeks (0 logmar). Tonus was normalized after reinforced hypotonic treatment with Ganfort® (eye drop, bimatoprost 0.3 mg/mL+timolol 5 mg/mL; Allergan France) and Simbrinza® (eye drop, brinzolamide 10 mg/mL+brimonidine 2 mg/mL; Alcon, Novartis Pharmaceuticals, France). Nevertheless, the patient's left eye still presented an altered ocular surface.

Satisfactory postoperative results allowed for a diminution of the corticosteroid therapy after 3 months, which then was replaced by Flucon® (eye drop, Fluorométholone Alcon, Novartis Pharmaceuticals, France). Antiviral treatment was also lowered to a residual dose, valacyclovir (500 mg orally, once daily).

Fifteen months after the intervention, the patient complained of a decline in visual acuity in the left eye. His BCVA was then 0.3 logmar for the left eye, with persistent conjunctival hyperemia. This eye presented with corneal edema as well as supranasal neovascularization and stromal haze, but there was no visible inflammation in the anterior chamber.

An injection of betamethasone was performed under the conjunctiva, associated with local corticosteroid therapy, with no clinical improvement. A new puncture of the anterior chamber was undertaken in order to search for the herpes simplex virus in the aqueous humour, with negative results. A complete check-up revealed the development of Crohn's disease, which was treated with azathioprine, orally (2 mg/kg short term, 50 mg daily long term).

Three months later, the ocular lesion became white and opaque, with round and well-defined edges (Figures 1, 2). It measured 9×5 mm and covered almost the entire upper half of the cornea.

Some vascularization was visible in the interior of the lesion. An anterior segment optical coherence tomography (AS-OCT) (OCT NIDEK RS 3000, NIDEK SA, 94042 Créteil, France) was performed, revealing a round and homogenous form that developed in the corneal epithelium and Bowman's membrane, without affecting the stroma (Figure 3). Visual acuity was 1.3 logmar. A surgical dissection with a Crescent knife (Beaver™Xstar™Safety Crescent Knife, Becton Dickinson France S.A., F-38801 Le Pont-de-Claix Cedex) was performed, revealing a cleavage plane and a seemingly healthy cornea.

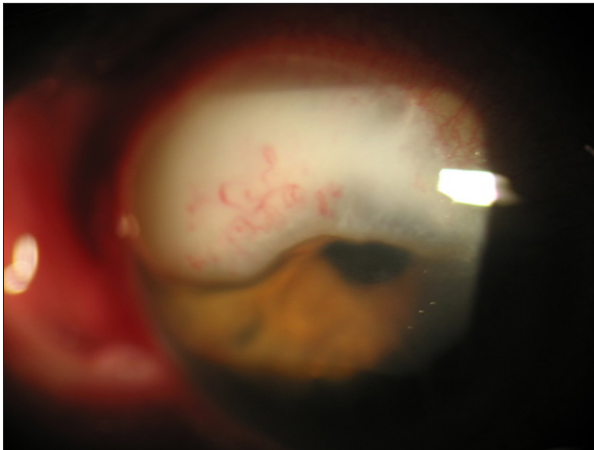


Figure 1. Slit-lamp examination revealing a purely corneal white lesion, measuring about 9×5 mm, with visible vascularization, and covering almost all the upper-half of the cornea.

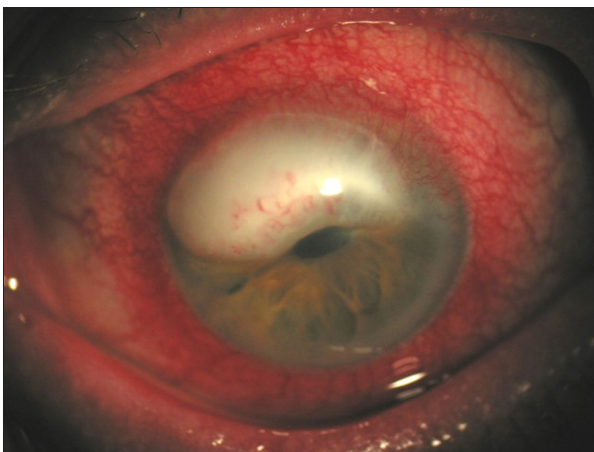


Figure 2. Corneal involvement only, without associated limbus lesion, with chronic conjunctival hyperemia.

Histological analysis showed a myxoid lesion projecting from the stroma, between the epithelium and Bowman's membrane (HES ×2.5; Figure 4A). The lesion was made of spindle or star-shaped fibroblastic elements, without cytonuclear atypia or mitosis (HES ×40; Figure 4B). The lesion was colored with Alcian blue (×2.5; Figure 4C). Immunohistochemistry analysis showed that tumoral cells were not targeted by anti-CD34 (×4; Figure 4D), anti-PS100, or anti-Actin smooth muscle antibodies. Proliferation index was estimated to under 1%, using Ki67 antibody.

The conclusion of the diagnostic was a secondary myxoma or a myxomatous corneal degeneration.

Postoperatively, the aspect became satisfactory one month after the intervention, both with biomicroscopy (Figure 5) and AS-OCT (Figure 6).

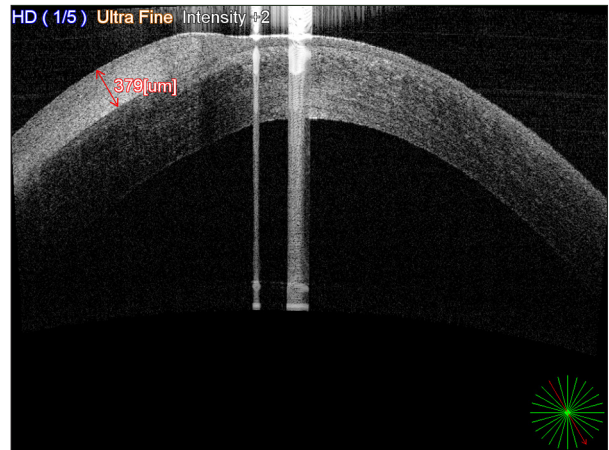


Figure 3. Anterior segment optical coherence tomography showing corneal myxoma: a round homogenous formation, mildly hyper-reflective, which developed at the expense of the corneal epithelium and the Bowman's membrane.

Discussion

Corneal myxomas are rare ophthalmologic lesions. Primary corneal myxomas are extremely rare and affect young people under the age of 15 years old, with no particular clinical background. On the other hand, most of corneal myxoid lesions occur in patients who have previously developed a corneal lesion such as traumatic or infectious corneal ulcers or keratoconus, or after a surgical treatment such as cataract surgery, keratoplasty, or photorefractive keratectomy [1–5,8–14] (See Table 1 [8–22]).

Secondary myxoma can affect patients of all ages, from 4 months to 80 years, with the average age of 52 years, and there seems to be a male predominance (15 males: 6 females). The delay between the presumed original lesion, or treatment, and the appearance of the myxoma can be very long, up to 10 years. Clinically, this lesion is characterized by a white, gelatinous tumor in the cornea. Differential diagnosis can be made with Salzmann nodular degeneration, keloid scar, pannus, amyloid deposition, or squamous cell carcinomas [10].

The evoked physiopathological hypothesis consists of a degenerative process, following the rupture of Bowman's membrane, because of the transformation of corneal stromal keratocytes into myofibroblasts with significant secretory activity. Indeed, cells from the lesion usually express smooth muscle actin, suggesting cell differentiation towards myofibroblasts, as they cease to express CD34, a characteristic of normal keratocytes. Chronic corneal edema also seems to be a common physiopathological marker of these type of lesions [10].

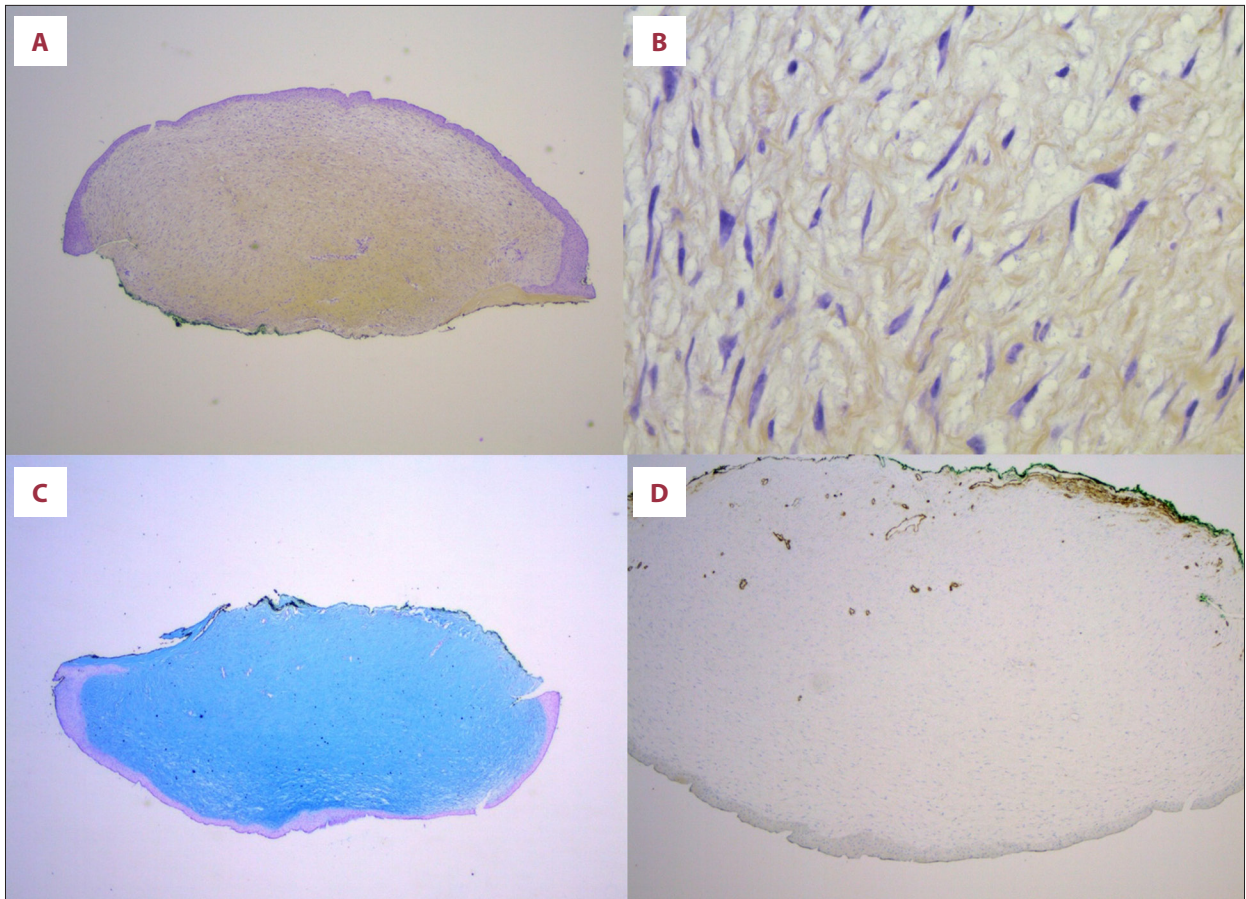


Figure 4. Histological analysis showed a myxoid lesion projecting from the stroma, between the epithelium and Bowman's membrane (HES $\times 2.5$; **A**). The lesion was made of spindle or star-shaped fibroblastic elements, without cytonuclear atypia or mitosis cells (HES $\times 40$; **B**). The lesion was colored with Alcian blue ($\times 2.5$; **C**). Immunohistochemistry analysis showed that tumoral cells were not targeted by anti-CD34 ($\times 4$; **D**), anti-PS100, or anti-actin smooth muscle antibodies. Proliferation index was estimated to under 1%, using Ki67 antibody.

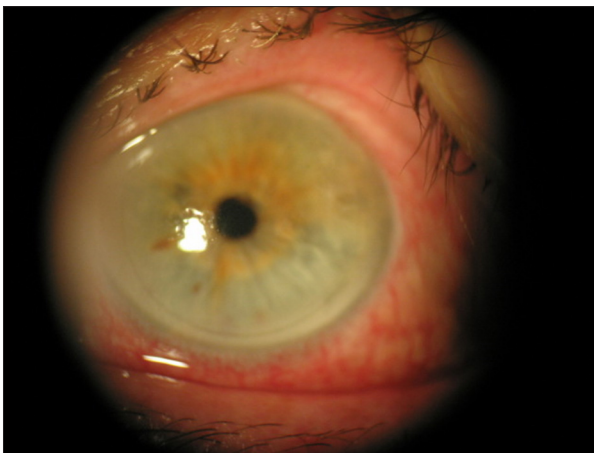


Figure 5. One month postoperatively bio-microscopical aspect.

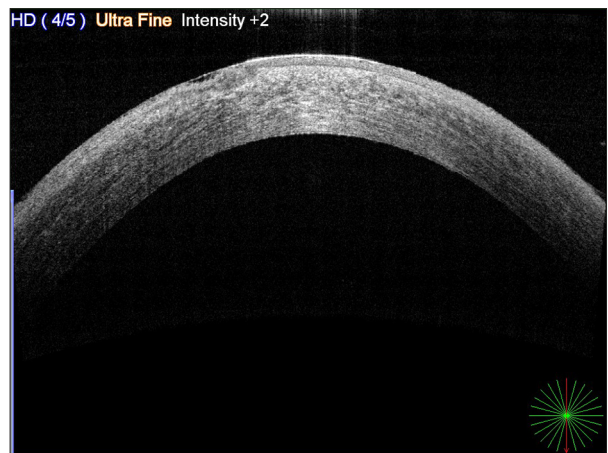

Figure 6. One month postoperatively anterior segment optical coherence tomography aspect.

Table 1. Corneal myxomas previously reported in the literature.

Case report	Age (years)	Sex	Presumed etiology	Treatment
Mitvalsky (1894) [15]	26	F	Tuberculous keratitis with corneal staphyloma	Excision
Bussy (1925) [16]	66	M	Chronic corneal ulcer	Enucleation
Lo et al. (1990) [13]	44	F	Primary	Excision
Pérez-Grossmann et al. (1997) [12]	53	M	Chronic corneal ulcer	Evisceration
Léger et al. (2000) [11]	26	F	Keratoconus	Penetrating keratoplasty
Wollensak et al. (2002) [10]	48	M	Bullous keratopathy	Excision
Hansen et al. (2004) [9]	36	F	Primary	Excision
Robinson et al. (2006) [8]	51	M	Bullous keratopathy, photorefractive keratectomy	Penetrating keratoplasty
Khan et al. (2008) [17]	4 months	F	Peters-plus syndrome	Penetrating keratoplasty
Alkatan et al. (2008) [18]	58	M	Post-cataract surgery, post-ptyerygium excision	Excision, amniotic membrane transplant
Soong T (2008) [19]	65	M	Primary	Excision
Lang et al. (2010) [20]	56	F	Primary	Excision
Peralta et al. (2010) [21]	70	M	Primary	Excision
Belliveau et al. (2012) [22]	45	M	Trauma, penetrating keratoplasty	Evisceration
	76	M	Trauma, cataract surgery	Penetrating keratoplasty
	69	M	Trauma, cataract surgery	Evisceration
	63	M	Trauma	Evisceration
	73	M	Trauma, penetrating keratoplasty, cataract surgery	Excision
	80	M	Penetrating keratoplasty	Excision
Kyung Sup Lim (2014) [14]	32	M	Primary	Deep anterior lamellar keratoplasty

F – Female; M – Male.

The link between Crohn's disease and the development of the corneal myxoid lesion is unknown, and to the best of our knowledge, such a link has never been reported. Crohn's disease is known for provoking peripheral ulcerative keratitis (PUK), but the ocular surface of our patient did not show any ulcer that could evoke a PUK. This is also the first report of a secondary myxoma following a DMEK. Two stitches (nylon 10/0) secondary to the DMEK, present under the tumor, might have been the starting point for the irritation causing the tumor, but this hypothesis remains uncertain.

The treatment of secondary myxomas consists of a surgical excision of the lesion, normally without recurrence. Surgery can be limited to the tumor, or it can include a reconstruction by penetrating keratoplasty or anterior lamellar graft keratoplasty,

which seems to lead to satisfactory results [14]. To our knowledge, pharmacological treatments, including topical treatments, are not effective for this kind of lesion.

In ophthalmology, myxomas have also been reported in the conjunctiva, in the orbit, and under the eyelid. In the conjunctiva, lesions are always isolated, while up to 15% of myxomas under the eyelid are associated with Carney complex. This is an autosomal dominant genetic disorder, which associates cardiac myxomas, lentiginos, naevi, Cushing's syndrome, acromegaly, and mucous pigmentation, which can affect the conjunctiva [3,4,6,7]. The major risk is a cardiac myxoma, which can be worsened by emboli, heart failure, or arrhythmia. Therefore, any diagnostic of ocular myxoma should lead to cardiac examination.

Conclusions

Corneal myxomas are rare lesions, often secondary to trauma in the Bowman's membrane, which is why it is often called a myxomatous corneal degeneration. In this instance, there is no link with Carney complex. However, myxomas under the eyelid or within the orbit are often associated with cardiac myxomas. Treatment is strictly surgical, either by simple excision

or by surgical excision followed by graft DMEK. To the best of our knowledge, this is the first time that such an association between DMEK and secondary corneal myxoma has been described in the literature.

Conflicts of interest

None.

References:

1. Bulkley BH, Hutchins GM: Atrial myxomas: A fifty-year review. *Am Heart J*, 1979; 97: 639–43
2. Horie Y, Ikawa S, Okamoto I et al: Myxoma of the conjunctiva: A case report and a review of the literature. *Jpn J Ophthalmol*, 1995; 39: 77–82
3. Correa R, Salpea P, Stratakis CA: Carney complex: An update. *Eur J Endocrinol*, 2015; 173: M85–97
4. Chinchurreta-Capote A, Trueba A, Hernández FJ et al: [Ocular findings in Carney complex]. *Arch Soc Esp Oftalmol*, 2006; 81: 709–11 [in Spanish]
5. Kennedy RH, Flanagan JC, Eagle RC et al: The Carney complex with ocular signs suggestive of cardiac myxoma. *Am J Ophthalmol*, 1991; 111: 699–702
6. Carney JA, Gordon H, Carpenter PC et al: The complex of myxomas, spotty pigmentation, and endocrine overactivity. *Medicine (Baltimore)*, 1985; 64: 270–83
7. Kennedy RH, Waller RR, Carney JA: Ocular pigmented spots and eyelid myxomas. *Am. J. Ophthalmol*, 1987; 104: 533–38
8. Robinson JW, Brownstein S, Mintsoulis G: Corneal myxoma arising in a patient with repeated phototherapeutic keratectomies. *Cornea*, 2006; 25: 1111–14
9. Hansen LH, Prause JU, Ehlers N et al: Primary corneal myxoma. *Acta Ophthalmol Scand*, 2004; 82: 224–27
10. Wollensak G, Green WR, Seiler T: Corneal myxoma. *Jpn J Ophthalmol*, 2002; 46: 193–97
11. Léger F, Sawan B, Mortemousque B et al: Corneal myxoma associated with keratoconus and Down's syndrome. *Cornea*, 2000; 19: 561–63
12. Pérez-Grossmann RA, Mesias LA, Contreras F et al: Solitary corneal myxoma. *Cornea*, 1997; 16: 498–500
13. Lo GG, Biswas J, Rao NA et al: Corneal myxoma. Case report and review of the literature. *Cornea*, 1990; 9: 174–78
14. Lim KS, Wee SW, Kim JC: Treatment of an 8-mm myxoma using acellular corneal tissue. *Korean J Ophthalmol*, 2014; 28: 86–90
15. Mitvalsky J: Sur les myxomes de la cornée. *Arch Ophtalmol (Paris)*, 1894; 14: 480–87 [in French]
16. Bussy L: Le myxome de la cornée. *Arch Ophtalmol (Paris)*, 1925; 42: 33–38 [in French]
17. Khan AO, Al-Katan H, Al-Ghedan S: Infantile corneal myxoma. *J AAPOS*, 2008; 12: 207–9
18. Alkatan H, Al-Arfaj K: Myxoma of the cornea. *Ann Saudi Med*, 2008; 28: 297–99
19. Soong T, Soong V, Salvi SM et al: Primary corneal myxoma. *Cornea*, 2008; 27: 1186–88
20. Lang TU, Williams JM, Laver NV: Corneal myxoma. *Ophthalmic Surg Lasers Imaging*, 2010; 42: E1–2
21. Peralta RJ: Primary corneal myxoma. *Arch Ophthalmol*, 2010; 128: 933
22. Belliveau MJ, Liao WN, Brownstein S et al: Myxomatous corneal degeneration: A clinicopathological study of six cases and a review of the literature. *Surv Ophthalmol*, 2012; 57: 264–71