



Subcutaneous ICD implantation under ultrasound-guided serratus anterior plane block: Single-center experience in the Netherlands

Jan Elders^{a,*}, Hisham AlHashimi^a, Marc Gomes^a, Ivo Panhuizen^b, Sander van Kuijk^c, Kevin Vernooij^{d,e}

^a Department of Cardiology, Canisius Wilhelminahospital, Nijmegen, The Netherlands¹

^b Department of Anesthesiology, Canisius Wilhelminahospital, Nijmegen, The Netherlands¹

^c Department of Clinical Epidemiology and Medical Technology Assessment (KEMTA), Maastricht University Medical Center (MUMC+), Maastricht, The Netherlands¹

^d Department of Cardiology, Radboud University Medical Center, Nijmegen, The Netherlands¹

^e Department of Cardiology, Cardiovascular Research Institute Maastricht (CARIM), Maastricht University Medical Center (MUMC+), Maastricht, The Netherlands¹

ARTICLE INFO

Keywords:

Serratus anterior plane block
Subcutaneous implantable cardioverter-defibrillator
Primary prevention
Implantation technique

ABSTRACT

Introduction: To avoid general anesthesia (GA) and improve postoperative pain management for subcutaneous implantable cardioverter-defibrillator (S-ICD) implantation there is a growing interest for alternative methods. We describe the first experience in the Netherlands of S-ICD implantation under Ultrasound-guided Serratus Anterior Plane Block (US-SAPB).

Methods: US-SAPB was performed 1 hour before S-ICD implantation. The two-incision technique was used and a pocket beneath the latissimus dorsi muscle was surgically created. Lidocaine was used to provide anesthesia of the skin. Sedation during defibrillation testing (DFT) was induced by intravenous Propofol. Perioperative pain experience was monitored using the Numerical Rating Scale for Pain (NRS-Pain). The results were compared with a control group of patients undergoing S-ICD implantation under GA.

Results: Forty consecutive patients (29 Male/11 Female, median age 59 years (range 34–84 years), median body mass index 26 (range 17–41) underwent S-ICD implantation; Twenty patients under US-SAPB and twenty under GA. Median procedure time was 42 min. (range 28–60 min.) with no differences between both groups. In both groups implantations went successful and defibrillation was accomplished using 65 J. US-SAPB was successful in 19 of the 20 patients and GA was successful in all cases. Median NRS-Pain in the US-SAPB group was 2 (range 2–6) and in the GA group 4 (range 2–6). In the US-SAPB group 5 patients required additional opioids post-operatively compared to 10 patients in the GA group.

Conclusions: S-ICD implantation under US-SAPB is feasible, safe and reduces the need for postoperative opioids significantly. S-ICD implantation under US-SAPB seems a good alternative for GA.

1. Introduction

Transvenous ICDs (TV-ICD) are associated with serious risks including lead dislodgement, pneumothorax, cardiac tamponade, endocarditis, occluded veins in the long run and lead fracture which may lead to an increased morbidity and mortality [1]. To avoid many of these potential complications a subcutaneous ICD (S-ICD) has been developed that has shown to be a good alternative to conventional TV-ICD to prevent sudden cardiac death in indicated patients [2,3].

To ensure a good shockvector of the S-ICD, a submuscular pocket

between the latissimus dorsi and the serratus anterior muscle is often surgically created rather than a subcutaneous pocket. The shock electrode is tunneled subcutaneously from the pocket to the xiphoid and into a parasternal position from the xiphoid in a cranial direction [4]. For this implantation method general anesthesia (GA) is administered most of the time. However, GA is associated with risks as hemodynamic compromises, trauma related to endotracheal intubation, vomiting and nausea [5].

Moreover, the majority of the ICD patients are heart failure patients with a reduced left ventricular ejection fraction (LVEF). According to a

* Corresponding author at: Department of Cardiology, Canisius Wilhelminahospital, Weg door Jonkerbos 100, 6532SZ Nijmegen, The Netherlands.

E-mail address: j.elders@cwz.nl (J. Elders).

¹ This author takes responsibility for all aspects of the reliability and freedom from bias of the data presented and their discussed interpretation.

large retrospective cohort study patients with heart failure are in general more obese, older, have a higher rate of medical comorbidities and a higher American College of Anesthesiologists (ASA) score than patients without heart failure [6]. In addition, as GA can cause a cardiodepressive reaction resulting in hypotension, the risk of acute cardiac distress is at hand in heart failure patients. Consequently, there may be an increased mortality risk in patients with reduced LVEF undergoing implantation under GA.

Also, patients often experience significant postoperative discomfort associated with the incision, dissection in the highly innervated mid-axillary chest wall, and tunneling of the subcutaneous lead [7]. The use of opioids postoperatively is associated with short- and long-term morbidity [8].

In order to avoid the use of general anesthesia (GA) for S-ICD implantation, S-ICD implantation with ultrasound-guided serratus anterior plane block (US-SAPB) is a potential alternative technique [9]. We report our single-center experience on US-SAPB S-ICD implantation regarding feasibility, safety and post-operative opioid use and compare it to S-ICD implantation under GA.

2. Methods

Consecutive patients with a class I indication for either primary or secondary sudden cardiac death prevention and considered suitable for S-ICD implantation were included in this retrospective study.

S-ICD implantation was performed with the two-incision technique in combination with a intermuscular positioning of the generator between the latissimus dorsi and the serratus muscle [10]. With the two-incision technique the electrode is tunneled subcutaneously using a tunneling tool in combination with a peel-away sheath. With the two-incision technique the superior parasternal incision is eliminated reducing the risk of dehiscence, infection, discomfort, decubitus and anti-aesthetic scarring.

S-ICD implantation under US-SAPB were performed in the year 2019 and compared with twenty patients in whom the S-ICD was implanted under GA in the year 2018.

There are two kinds of SAPB: deep SAPB (between the serratus muscle and the fifth rib) and superficial SAPB (between the latissimus dorsi muscle and the serratus anterior muscle). The spread of analgesia is the same in both techniques and covers T2-T9. Sensory block duration is prolonged in patients with superficial SAPB compared with deep SAPB. On the other hand it is suggested that with deep SAPB there is improved analgesia and duration compared with superficial SAPB [11–13].

We used a combined block in combination with local skin infiltration with 0.375% Ropivacaine and 1% Lidocaine.

US-SAPB was performed according to the technique described by Droghetti et al. [14] One hour before implantation the patient was referred to the anesthesiologist to place the serratus block. US-SAPB provides analgesia of the anterolateral hemithorax by targeting the lateral cutaneous branches of the intercostal nerves [9]. For US-SAPB the patient is placed in a supine position with the left arm in abduction in 90°. After disinfection of the skin a high-frequency linear ultrasound probe (Philips Sparq 40,761 Diagnostic Ultrasound System, Best, the Netherlands) was used to identify the latissimus dorsi and serratus anterior muscles in the area between the fifth and sixth rib in a mid-axillary line (Fig. 1A). Under local skin infiltration with 1% Lidocaine a 22-gauge needle with a length of 100 mm (Braun Stimuplex Ultra 360) was inserted under ultrasound guidance in an anterior-posterior direction. After identifying the superficial interfascial plane between the serratus anterior and the latissimus dorsi a hydrodissection was performed by injecting 4 ml of saline. After verification that we are in the correct interfascial plane 10–15 ml of 0.375% Ropivacaine (20 ml of 0,75% Ropivacaine diluted with 20 ml of 0,9% NaCl = 0,375% Ropivacaine). was injected (Fig. 1B). Subsequently, the 22-gauge needle is positioned between the serratus anterior and the intercostal muscles to

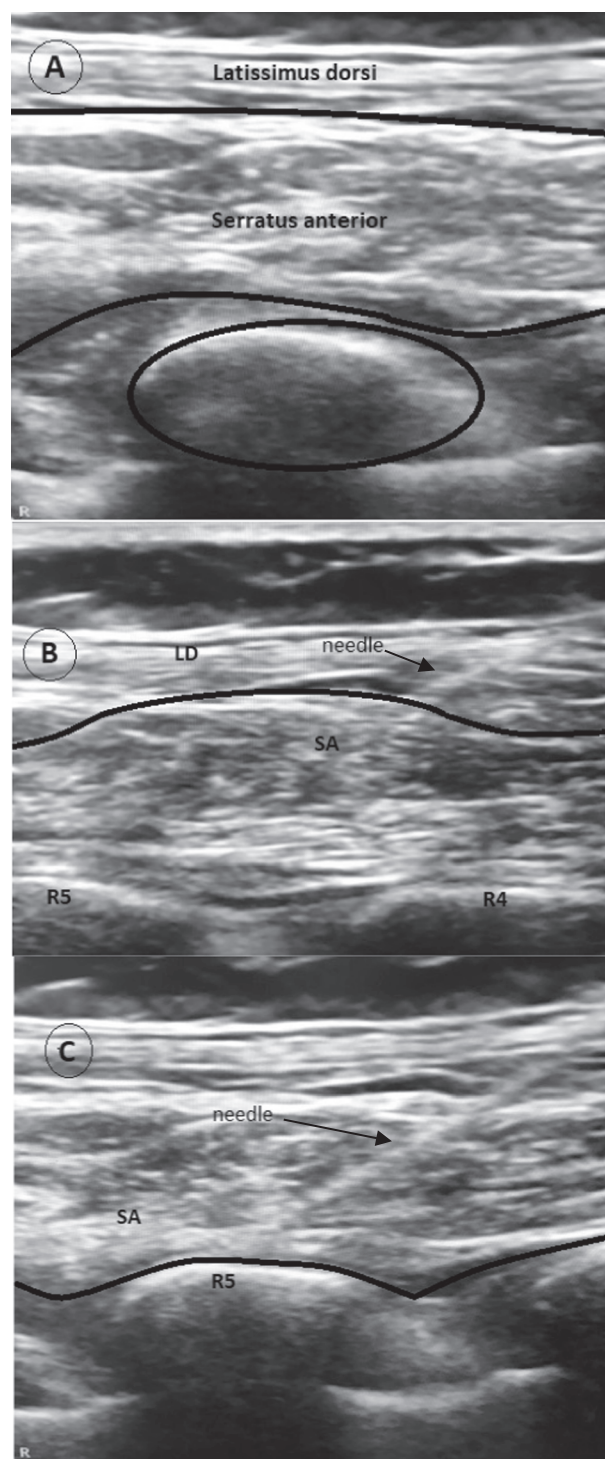


Fig. 1. Ultrasound image in a midaxillary line of the latissimus dorsi and the serratus anterior **panel A:** ultrasound image of the fifth rib, serratus anterior muscle and latissimus dorsi muscle in a midaxillary line. **panel B:** superficial serratus anterior block. **panel C:** deep serratus anterior block. SA: Serratus Anterior. LD: Latissimus Dorsi. R4: fourth Rib. R5: fifth rib.

create a deep serratus anterior block injecting 10–15 ml of 0,375% Ropivacaine (Fig. 1C). The amount of Ropivacaine 0.375 was maximized to 25 ml during the US-SAPB to keep 15 ml of this solution for escape-infiltration during the surgical intervention.

Injecting the Ropivacaine into the Serratus plane takes about 10 min. After that it takes about 30 min for the Ropivacaine to infiltrate properly.

Before incision, 15 ml of 1% Lidocaine was used for local anesthetic of the skin. Perioperative intravenous Propofol as well as S-Ketamine and/or fentanyl was administered by an anesthesiologist guided by pain experience to achieve mild sedation to relief discomfort.

In the GA group the patients went under general anesthesia and were intubated. GA and intubation takes about 15 min. Patients were monitored during GA by an anesthesiologist. Local skin infiltration is not necessary.

The generator was placed intermuscular between the serratus anterior and the latissimus dorsi and the lead was positioned subcutaneous in a parasternal position (Fig. 2). When the S-ICD was implanted and, the patient was sedated with intravenous Propofol for defibrillation threshold testing. Ventricular fibrillation (VF) was induced with a 50 Hz burst and defibrillation was performed with a 65 J shock.

Pain intensity was measured using the 11-point Numeric Rating Scale (NRS). It is labeled from zero to ten, with zero indicating no pain and ten being the worst pain. The NRS-pain is a valid and reliable tool for rating pain intensity and quick to administer and score. Disadvantages are that it only evaluates one aspect of pain (intensity), it does not factor in past pain experiences or fluctuations in pain [15].

Baseline characteristics of the two groups were described as mean and standard deviation or median and first and third quartile for continuous variables, and as count and percentage for categorical variables. Differences between groups were tested using the independent-samples *t*-test and Pearson's chi-square test. All analyses were performed using IBM SPSS version 27.0.0.

3. Results

From January 2018 to January 2020 forty consecutive patients were scheduled for an elective S-ICD implantation. Twenty patients underwent S-ICD implantation under GA (year 2018) and twenty patients under US-SAPB (year 2019).

Table 1 shows the baseline characteristics of the two patient groups. The baseline characteristics of the GA group and the US-SAPB group were rather similar. However, the US-SAPB group consisted of less males (13 vs 16), and in the US-SAPB group both median BMI (26 range 17–36 vs 28 range 22–41, n.s.) and LVEF (25% range 15–63% vs 30%, range 15–75%) were slightly lower compared to the GA group. Distribution of

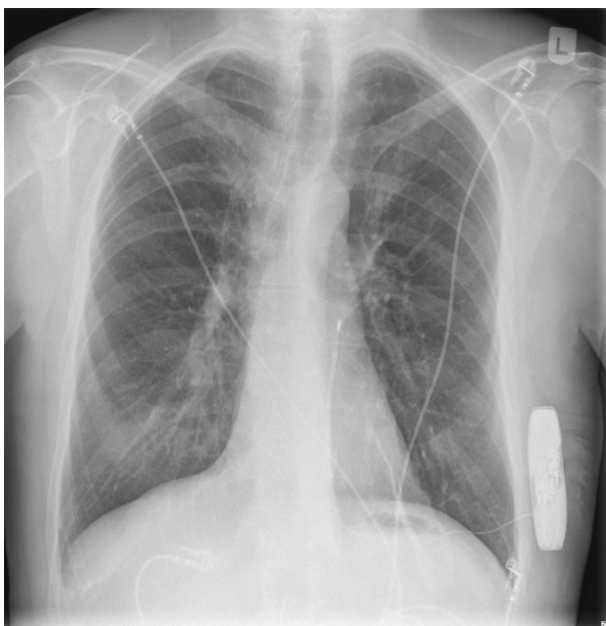


Fig. 2. Chest X-ray with the S-ICD in an intermuscular position and the electrode in a parasternal position.

Table 1

Baseline characteristics, demographic parameters and results.

	US-SAPB (n = 20)	GA (n = 20)	P- value (paired)
Male gender, n (%)	13 (65)	16 (80)	n.s.
Age, years (median)	57 (30–84)	61 (34–79)	n.s.
Body mass index (median)	26 (17–36)	28 (22–41)	n.s.
LV ejection fraction, % (median)	25 (15–63)	30 (15–75)	n.s.
New York Heart Association Class I, n (%)	2 (10)	2 (10)	n.s.
Class II, n (%)	18 (90)	18 (90)	n.s.
Primary prevention, n (%)	18 (90)	18 (90)	n.s.
Ischemic Cardiomyopathy, n (%)	10 (50)	10 (50)	n.s.
Dilated Cardiomyopathy, n (%)	10 (50)	10 (50)	n.s.
Diabetes, n (%)	3 (15)	2 (10)	n.s.
Renal insufficiency, n (%)	3 (15)	2 (20)	n.s.
Total Cathlab time, minutes (median)	60 (45–82)	100 (55–137)	p < 0.001
Procedure time, minutes (median)	42 (30–68)	42 (28–63)	n.s.
Primo implantation, n (%)	18 (90)	20 (100)	n.s.
Numeric Rating Scale-Pain (median)	2 (2–6)	4 (2–6)	p < 0.001
Start Postoperative pain (hours)	5(±1)	2(±1)	P < 0.001
Postoperative Paracetamol use, n (%)	5 (25)	15 (75)	p < 0.001
Postoperative Opioid use, n (%)	5 (25)	10 (50)	p < 0.001
Prolonged use Paracetamol, n (%)	5 (25)	5 (25)	n.s.

NYHA functional class, primary prevention and percentage of ischemic cardiomyopathy was similar in both groups.

US-SAPB was effective in all patients, established by loss of pinprick. In all patients the skin was infiltrated with local anesthesia (1% Lidocaine combined with 0.375% Ropivacaine).

In one patient a switch to general anesthesia was necessary because of intolerable pain experience.

Nineteen S-ICD implantation procedures (95%) in the US-SAPB group went without any complications. One patient experiences a comminuted left-sided subcapital humerus fracture probably as a result of the positioning of the arm (abducted and externally rotated) during the defibrillation test at which the current pathway is through the pectoral muscle causing a forceful contraction [16].

No complications were seen in the GA group.

In 36 patients (16 US-SAPB and 20 GA) DFT was performed and was successful in all cases with 65 J.

The median skin-to-skin procedure time of the S-ICD implantation was similar in both groups (42, range 30–68 min vs 42, range 28–63 min). The total time spent in the Cathlab was lower in the US-SAPB group compared to the GA group (60, range 45–82 min vs 100, range 55–137 min, P < 0.001).

4. Postoperative pain management

After the S-ICD implantation both GA and US-SAPB patients experienced mild pain direct postoperative. In the GA group the mean discomfort started 2 ± 1 h postoperative. In the US-SAPB group the mean discomfort started 5 ± 1 h (p < 0.001) after the intervention. The median NRS-pain score in the US-SAPB group was 2 (range 2–6). The median NRS-pain score in the GA group 4 (range 2–6; p < 0.001). In the US-SAPB group five patients (25%) needed additional paracetamol (1000 mg) and in the GA group ten patients (50%) needed oral Paracetamol (1000 mg, p < 0.001).

For five patients (25%) in the US-SAPB group, oral Oxycodone (5 mg) was prescribed for 24 h with good results. In the GA group ten patients needed oral opioids (50%, p < 0.001) postoperatively. Whereas five patients (25%) in the US-SAPB group did not experience any

discomfort, this was not the case in the GA group where every patient needed analgetics ($p < 0.001$).

Two weeks after the procedure all patients were seen in the outpatient-clinic. Ten patients (5 US-SAPB patients (25%) and 5 GA-patients (25%, n.s.) reported prolonged use of Paracetamol (500 mg, 4 times a day) for at least 7–10 days to relieve discomfort. Thirty-nine patients recovered without any complications.

5. Discussion

Our first experience with US-SAPB in combination with pain-guided intravenous Propofol by an anesthesiologist and local skin infiltration with Lidocaine/ Ropivacaine showed that US-SAPB is a feasible and effective method for S-ICD implantation. Secondly US-SAPB guarantees longer lasting postoperative pain relief with lesser use of postoperative Paracetamol and opioids. Also the mean Numerical Rating Scale Pain was lower in the US-SAPB group as compared to the GA group, resulting in a reduced need for analgetics after the procedure.

Since the introduction of the S-ICD's, most centers perform these implantation procedures under GA. The reason for this is that tunneling of the subcutaneous electrode and dissection of the submuscular pocket of the S-ICD is very painful under local anesthesia. GA is however known for its related risks including hemodynamic compromise, risks related to endotracheal intubation, nausea and vomiting. Postoperative the patients experience more pain compared to the conventional ICD implantation. The use of postoperative opioids can be associated with short- and long-term morbidity [8].

To bypass the potential adverse effects of GA an alternative was found in US-SAPB in combination with local skin infiltration with Lidocaine/Ropivacaine. Insertion of an US-SAPB is relatively easy to perform. Application of this block was described earlier for surgery of the lateral chest wall [9].

The anesthesiologists performed US-SAPB in patients scheduled for surgery affecting the chest wall. For our work-up we scheduled our S-ICD implantations in the afternoon in order to facilitate the anesthesiologist to place the US-SAPB in advance. The time to perform an US-SAPB is approximately 10 min and works for at least 8 h. Compared to GA we could optimize our logistic structure related to our implantations. Length of stay in the cathlab for S-ICD implantation reduced significantly after the introduction of UA-SAPB from ± 100 min to ± 60 min as we only needed 45 min on average for the surgical intervention itself. Subsequently the number of interventions on a whole day could be increased when this US-SAPB is implemented in clinical practice.. In addition, as a result of the long-lasting anesthesia US-SAPB patients experienced less pain and discomfort compared to implantations under GA which could result in faster discharge after implantation.

Our first experience with US-SAPB in combination with pain-guided intravenous Propofol are consistent with the data of other studies. Ueshima et al reported two S-ICD implantations under US-SAPB where both patients did not need postoperative analgetics. However, data on this topic is scarce [17]. In a letter to the editor Droghetti et al. reported 10 patients with an S-ICD under US-SAPB with cooperative sedation. These ten implantations went without complications and the NRS-pain score was very low. Postoperative analgesia for the patients was 3 g of paracetamol [18].

Another article from the same group reported 12 patients for S-ICD implantation under US-SAPB. In one patient there was a switch to GA for unknown reasons. Postoperative only mild pain was reported and no analgetics were administered [14]. Also, Miller et al reported a comparison between S-ICD patients under US-SAPB with GA and US-SAPB with deep sedation. All implantations went without complications but the GA group significantly needed more postoperative morphine than the US-SAPB group (milligram morphine equivalent (MME) 60 vs 0) [7].

In one patient however, we had to switch from US-SAPB to GA. This patient had a history of a severe ICD pocket infection. It is our assumption that the US-SAPB could not infiltrate enough due to scar-

tissue and connective tissue growth besides the fact that pharmacokinetics of local anesthetics change in an environment with a low pH.

With respect to the patient with the subcapital humerus fracture as a result of the positioning of the arm (abducted and externally rotated) during the defibrillation threshold test we reviewed the case and concluded that it is advisable to adduct the arm before defibrillation testing in S-ICD implantation [16].

6. Limitations

The main limitation of the present study is that is a retrospective, single center study with a relatively small sample size. Also, patients were not randomized but compared with a cohort of patients from a previous year.

7. Conclusion

The current study shows that US-SAPB S-ICD implantation is a feasible and safe alternative for GA. Moreover, ultrasound-guided serratus anterior plane block reduces the need for postoperative opioids significantly. Therefore US-SAPB seems an excellent alternative for general anesthesia. Larger studies are however necessary to confirm the results that US-SAPB is a safe and equivalent method to S-ICD implantations under GA.

Declaration of Competing Interest

The authors declare that they have no known competing financial interests or personal relationships that could have appeared to influence the work reported in this paper.

References

- [1] R.E. Kirkfeldt, J.B. Johansen, E.A. Nohr, O.D. Jorgensen, J.C. Nielsen, Complications after cardiac implantable electronic device implantations: an analysis of a complete, nationwide cohort in Denmark, *Eur. Heart J.* 35 (18) (2014) 1186–1194, <https://doi.org/10.1093/eurheartj/ehf511>.
- [2] S. Priori, C. Blomström-Lundqvist, A. Mazzanti, et al., ESC guidelines for the management of patients with ventricular arrhythmias and the prevention of sudden cardiac death: The Taskforce for the Management of Patients with Ventricular Arrhythmias and the Prevention of Sudden Cardiac Death of the European Society of Cardiology (ESC). Endorsed by: Association for European Paediatric and Congenital Cardiology (EAPC), *Eur. Heart J.* 36 (2015) 2793–2867.
- [3] R.E. Knops, L.R.A. Olde Nordkamp, P.-P. Delnoy, L.V.A. Boersma, J. Kuschyk, M. F. El-Chami, H. Bonnemeier, E.R. Behr, T.F. Brouwer, S. Kääh, S. Mittal, A.-F. Quast, L. Smeding, W. van der Stuijt, A. de Weger, K.C. de Wilde, N. R. Bijsterveld, S. Richter, M.A. Brouwer, J.R. de Groot, K.M. Kooiman, P. D. Lambiasi, P. Neuzil, K. Vernooij, M. Alings, T.R. Betts, F.A.L.E. Bracke, M. C. Burke, J.S.S.G. de Jong, D.J. Wright, J.G.P. Tijssen, A.A.M. Wilde, Subcutaneous or Transvenous Defibrillator Therapy, *N. Engl. J. Med.* 383 (6) (2020) 526–536.
- [4] J. Winter, M. Siekera, D.I. Shin, et al., Intermuscular technique for implantation of the subcutaneous implantable cardioverter defibrillator implantation: Long-term performance and complications, *Europace.* 19 (2017) 2036–2041.
- [5] Hyman MC, Vemulapali S, Szeto WY, et al. Conscious sedation versus general anesthesia for transcatheter aortic valve replacement: insights from the National Cardiovascular Data Registry Society of Thoracic Surgeons/American College of Cardiology Transcatheter Valve Registry. *Circulation.* 2017;136:3132-2140.
- [6] B.J. Lerman, R.A. Papat, T.L. Assimes, P.A. Heidenreich, S.M. Wren, Association of left ventricular ejection fraction and symptoms with mortality after elective noncardiac surgery among patients with heart failure, *JAMA* 321 (6) (2019) 572, <https://doi.org/10.1001/jama.2019.0156>.
- [7] M.A. Miller, J. Garg, B. Salter, T.F. Brouwer, A.J. Mittnacht, M.L. Montgomery, R. Honikman, D.E. Arkonac, S. Choudry, S.R. Dukkipati, V.Y. Reddy, M.M. Weiner, Feasibility of subcutaneous implantable cardioverter-defibrillator implantation with opioid sparing truncal plane blocks and deep sedation, *J. Cardiovasc. Electrophysiol.* 30 (1) (2019) 141–148.
- [8] E. Sun, B. Darnall, L. Baker, et al., Incidence of and risk factors of chronic opioid use among opioid-naive patients in the postoperative period, *JAMA Intern Med.* 176 (9) (2016) 1286–1293, <https://doi.org/10.1001/jamainternmed.2016.3298>.
- [9] R. Blanco, T. Parras, J.G. McDonnell, A. Prats-Galino, Serratus plane block: A novel ultrasound guided thoracic wall nerve block, *Anesthesia.* 68 (11) (2013) 1107–1113.
- [10] R.E. Knops, L.R.A. Olde Nordkamp, J.R. de Groot, A.A.M. Wilde, Two-incision technique for implantation of the subcutaneous implantable cardioverter-defibrillator, *Heart Rhythm.* 10 (8) (2013) 1240–1243.

- [11] A. Biswas, V. Castanov, Z. Li, A. Perlas, R. Kruisselbrink, A. Agur, V. Chan, Serratus Plane Block: A Cadaveric Study to Evaluate Optimal Injectate Spread, *Reg. Anesth. Pain Med.* (2018) 1, <https://doi.org/10.1097/AAP.0000000000000848>.
- [12] R.M. George, M. Yared, S.H. Wilson, Deep Serratus Plane Catheter for Management of Acute Postthoracotomy Pain After Descending Aortic Aneurysm Repair in a Morbidly Obese Patient: A Case Report, *A A Pract.* 10 (3) (2018) 49–52, <https://doi.org/10.1213/XAA.0000000000000628>.
- [13] M.M. Piracha, S.L. Thorp, V. Puttanniah, A. Gulati, “A Tale of Two Planes”: Deep Versus Superficial Serratus Plane Block for Postmastectomy Pain Syndrome, *Reg. Anesth. Pain Med.* 42 (2) (2017) 259–262, <https://doi.org/10.1097/AAP.0000000000000555>.
- [14] A. Droghetti, E. Basso Ricci, P. Scimia, F. Harizai, M. Marini, Ultrasound-guided serratus anterior plane block combined with the two incision technique for subcutaneous ICD implantation, *Pacing Clin. Electrophysiol.* 41 (5) (2018) 517–523.
- [15] J.D. Childs, S.R. Piva, J.M. Fritz, Responsiveness of the numeric pain rating scale in patients with low back pain, *Spine* 30 (11) (2005) 1331–1334.
- [16] J. Elders, H. AlHashimi, Left-Sided Humerus Fracture as an Unusual Complication of Defibrillation Threshold Testing Following S-ICD Implantation, *J Am Coll Cardiol Case Report* 2 (2) (2020) 255–257.
- [17] H. Ueshima, E. Hara, H. Otake, Successful cases of S-ICD implantation performed under the serratus plane block, *J. Clin. Anesth.* 33 (2016) 147–148.
- [18] A. Droghetti, Ultrasound-guided serratus anterior plane block and parasternal block in cooperative sedation for S-ICD implantation, *Pacing Clin. Electrophysiol.* 42 (2019) 1076–1078.