

Genital donovanosis with malignant transformation: An interesting case report

K. Navya Sri, A. Swetha Chowdary, B. S. N. Reddy

Department of Dermatology, Mamata Medical College and Hospital, Khammam, Telangana, India

Address for correspondence:

Dr. A. Swetha Chowdary, Department of Dermatology, Mamata General Hospital, Khammam, Telangana, India.

E-mail: dr.swethachowdary@gmail.com

Abstract

Donovanosis is a chronic indolent sexually transmitted granulomatous ulceration of genito-inguinal region, caused by *Calymmatobacterium granulomatis*. It became uncommon due to indiscriminate use of broad spectrum antibiotics. In recent years, much interest is being focused on this condition because genital ulcers facilitate HIV infection. We report an interesting episode of genital donovanosis complicated with squamous cell carcinoma in a middle aged female for its rarity and clinical interest.

Key words: Donovan bodies, donovanosis, malignant transformation

INTRODUCTION

Donovanosis is a sexually transmitted infection presenting with fleshy exuberant granulomatous ulceration. Though donovanosis is considered a sexually transmitted infection, there is possibility that the lesions are not always sexually transmitted, but through fecal contamination and autoinoculation.^[1] Malignancy, though a rare complication, should be suspected in patients not responding to antibiotic treatment. We are reporting an interesting case of genital donovanosis with malignant transformation for its rarity and clinical interest.

CASE REPORT

A 50-year-old female presented to our outpatient clinic, with a painless ulcerative growth that bleeds on touch over the left vulva of 5 years duration. Initially, her problem started as a painless small skin

lesion over the left labia and gradually progressed to ulceration to involve the entire vulva. She is married since 30 years and denied history of extramarital sexual exposure. Her husband is healthy with no history of genital ulcers.

Clinical examination of the patient revealed a granulomatous ulcer measuring 7 cm × 5 cm extending from the clitoris to fourchette involving the entire left labia [Figure 1]. Ulcer was nontender, bleeding on touch with everted edges. Bilateral, nontender, firm, discrete inguinal lymphadenopathy was present. Rest of the skin and systemic examination revealed no other abnormality.

Tissue smear from the edge of the ulcer showed pink ovoid bodies containing dark blue nuclei with bipolar condensation lying within and also outside of large monocytes [Figure 2]. A clinical diagnosis of donovanosis was made based on the smear report. Serology for HIV, hepatitis and Venereal Disease Research Laboratory were nonreactive.

Patient was prescribed capsule doxycycline 100 mg bid for 2 weeks. This did not show any clinical improvement in her condition. Hence, a fine-needle aspiration cytology (FNAC) of the inguinal lymphnode was carried out along

Access this article online**Quick Response Code:****Website:**

www.ijstd.org

DOI:

10.4103/0253-7184.142409

How to cite this article:

Sri KN, Chowdary AS, Reddy B. Genital donovanosis with malignant transformation: An interesting case report. Indian J Sex Transm Dis 2014;35:135-7.

with a biopsy from the edge of the ulcer. Both these reports demonstrated features suggestive of squamous cell carcinoma with oval cells containing large hyperchromatic nuclei, abundant cytoplasm, high N/C ratio and keratin pearl formation [Figures 3 and 4]. She was explained about the disease and was referred to MNJ Institute of Oncology Regional Cancer Centre, Hyderabad for further management, where the diagnosis of squamous cell carcinoma was confirmed, and subsequently she has undergone radical vulvectomy with bilateral inguinal lymphnode block dissection [Figure 5].

DISCUSSION

Donovanosis was first described in 1882 by McLeod^[2] and the etiologic agent (Donovan bodies) was demonstrated in 1905 by Major Charles Donovan in the tissue smears of an oral granuloma

patient from Madras General Hospital.^[3] It is a mildly contagious, gradually progressive, often sexually transmitted, granulomatous ulceration of the genito-inguinal area caused by Gram-negative bacillus *Calymmatobacterium granulomatis*.

The disease usually manifests initially with a small papule or nodule which gets eroded to form characteristic clinical lesions namely (a) ulcerogranulomatous or fleshy exuberant, (b) necrotic, (c) hypertrophic or verrucous, and (d) sclerotic or cicatricial type.^[1,4] Although it is generally considered as a sexually transmitted infection (STI), lesions may occur through fecal contamination and autoinoculation.^[5]

Largest epidemic occurred in Papua New Guinea between 1922 and 1952. However, according to recent studies by WHO it has become rare now.^[1] A sentinel surveillance conducted in 2004 combining all the

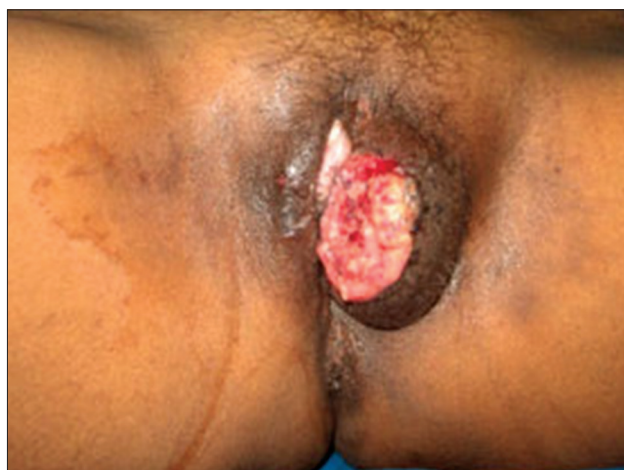

Figure 1: Clinical photograph of donovanosis patient showing ulcerogranulomatous lesion over left labia

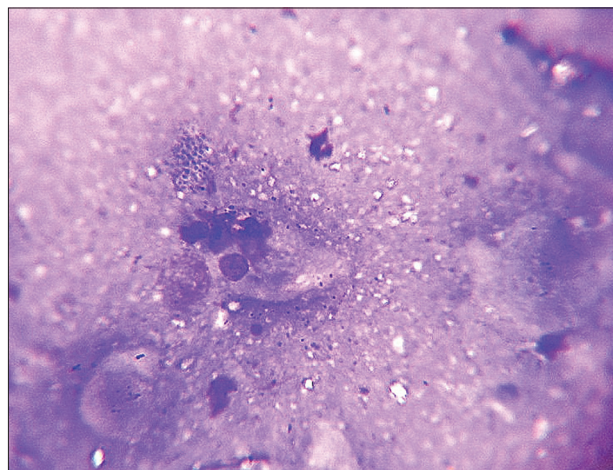


Figure 2: Tissue smear showing Donovan bodies

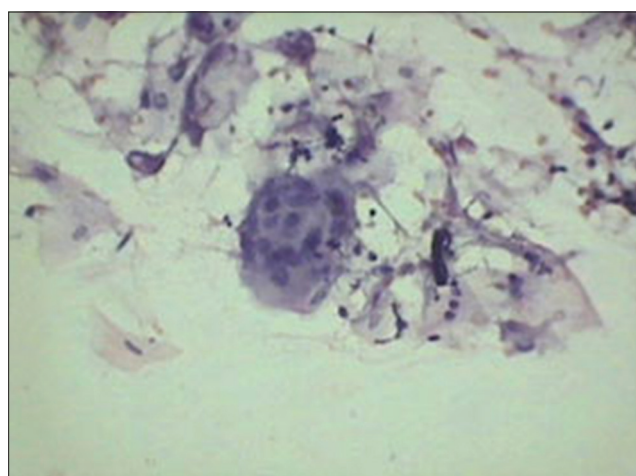


Figure 3: Fine-needle aspiration cytology of inguinal lymphnode showing oval cells containing large hyperchromatic nuclei, abundant cytoplasm and high N/C ratio suggestive of squamous cell carcinoma

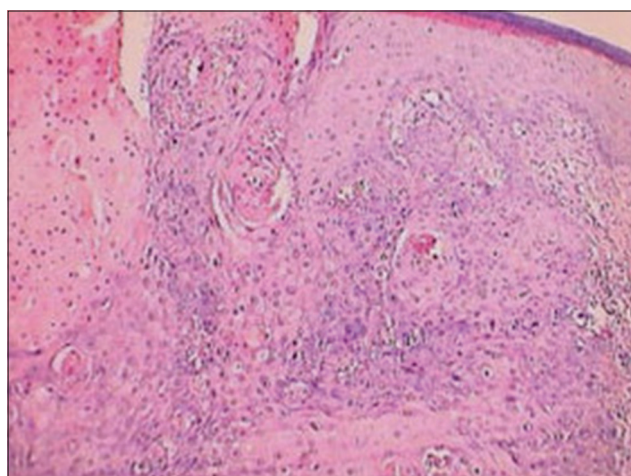


Figure 4: Photomicrograph of biopsy from the ulcer of donovanosis patient showing histopathologic features of squamous cell carcinoma with oval cells with large hyperchromatic nuclei, abundant cytoplasm with high N/C ratio and keratin pearl formation (H and E, ×40)

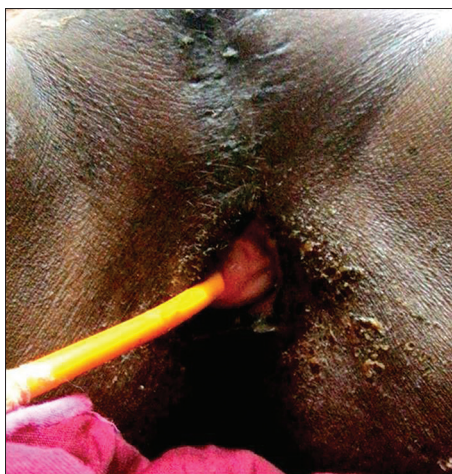


Figure 5: Postoperative picture following vulvectomy

studies in South Africa from 1980 to 2000 revealed the proportion of genital ulcer disease attributable to granuloma inguinale to be close to 1%.^[6]

In various STI clinics, the prevalence ranged from 0.013% in Tezpur to 8.2% in Pondicherry and 10% in Mumbai. In Chandigarh, the prevalence declined from 6.3% in 1977-1985 to 0.5% in 1995-1996. In Delhi, it increased from 0.25% in 1955-61 to 1.4% in 1989-95 and then declined to 0.48% in 1995-99.^[7] Two epidemics of donovanosis occurred in Delhi, in 1983 and 1985, when the reported incidences were 6.38% and 8.33%, respectively.^[7]

In recent years, the incidence of donovanosis has decreased to the extent that the cases are almost sporadic even in the areas where it was once prevalent in significant numbers due to the efforts to curtail genital ulcers as a public health issue with syndromic management of sexually transmitted diseases by broad spectrum antibiotics coupled with usage of condoms as a precautionary measure to prevent HIV epidemic transmission.^[8]

Our patient manifested with ulcerogranulomatous lesions. Based on the characteristic morphology of her genital ulcers and presence of typical Donovan bodies in the tissue smears, she was diagnosed as a case of donovanosis, and administered antibiotic treatment. Lack of therapeutic benefit to this coupled

with chronicity of her ulcer made us suspect malignant transformation, which was confirmed with subsequent FNAC of inguinal lymph node and histopathologic examination of the ulcer.

Most frequent complications of donovanosis include pseudoelephantiasis as a consequence of lymphatic obstruction, mutilations and obstruction of the vaginal orifice due to destruction of tissues and consequent fibrosis. However, the most important complication in long standing cases is the malignant transformation of the ulcers as evidenced in our patient. This feature has been observed in about 0.25% of the patients in Rajam and Rangaiah series^[9] and also in a few isolated case reports.^[10-12] It is important to note that lack of response to conventional treatment, especially in long standing lesions of donovanosis should alert the suspicion of malignant transformation.

REFERENCES

1. O'Farrell N. Donovanosis. *Sex Transm Infect* 2002;78:452-7.
2. McLeod K. Precis of operations performed in the wards of the first surgeon, Medical College Hospital, during the year 1881. *Indian Med Gaz* 1882;111:113-23.
3. Donovan C. Medical cases from Madras General Hospital: Ulcerating granuloma of the pudenda. *Indian Med Gaz* 1905;40:414.
4. Hart G. Donovanosis. *Clin Infect Dis* 1997;25:24-30.
5. Goldberg J. Studies on granuloma inguinale. V. Isolation of a bacterium resembling *Donovania granulomatis* from the faeces of a patient with granuloma inguinale. *Br J Vener Dis* 1962;38:99-102.
6. Johnson LE, Coetzee DJ, Dorrington RE. Sentinel surveillance of sexually transmitted infections in South Africa: A review. *Sex Transm Infect* 2005;81:287-93.
7. Sharma VK, Khandpur S. Changing patterns of sexually transmitted infections in India. *Natl Med J India* 2004;17:310-9.
8. O'Farrell N. Donovanosis. In: Gupta S, Kumar B, editors. *Sexually Transmitted Infections*. 2nd ed. India Elsevier; 2012. p. 533.
9. Rajam RV, Rangaiah PN. Donovanosis. *Monogr Ser World Health Organ* 1954;24:1-72.
10. Thappa DM, Senthikumar M, Laxmisha C. Malignant transformation of donovanosis. *Indian J Sex Transm Dis* 2004;125:77.
11. Sardana K, Garg VK, Arora P, Khurana N. Malignant transformation of donovanosis (granuloma inguinale) in a HIV-positive patient. *Dermatol Online J* 2008 15;14:8.
12. Agrawal M, Arora SK, Agarwal A. A forgotten disease reminds itself with a rare complication. *Indian J Dermatol* 2011;56:430-1.

Source of Support: Nil. Conflict of Interest: None declared.