

The timing of open surgical release of post-traumatic elbow stiffness

A systematic review

Chao Sun, MD^a, Xijie Zhou, MD^a, Chenglun Yao, MD^a, Keshav Poonit, MD^a, Cunyi Fan, MD, PhD^b, Hede Yan, MD, PhD^{a,*}

Abstract

Background: Open release of post-traumatic elbow stiffness is effective in restoring elbow function, but there is no guideline on the optimal time point of surgical release so far. The purpose of this article was to summarize the current available literature reporting on the timing of open release of post-traumatic elbow stiffness.

Methods: The PubMed, Cochrane Library, and EMBASE were searched with a set of predefined inclusion and exclusion criteria. Manual searches for references were performed to find potential relevant studies. Two authors separately extracted data from all the articles selected.

Results: 27 articles published between 1989 and 2017 were included with an overall enrollment of 836 patients. We divided all included studies into 3 groups according to the timing of surgical release: group 1 (6–10 months after injury), group 2 (11–20 months after injury), and group 3 (>20 months after injury). The mean postoperative Mayo Elbow Performance Score (MEPS) and recurrence rate were similar among the 3 groups; however, the mean gain in arc of motion in group 1 was the highest with the lowest complication rate among the 3 groups.

Conclusion: There was a trend toward a shorter waiting time from injury to open arthrolysis from 12 months to 6 months. The shorter waiting period of 6 to 10 months yielded better results. Therefore, early surgical release of stiff elbows is recommended for a shorter rehabilitation time and earlier return to work.

Level of evidence: Level IV, Systematic Review.

Abbreviations: HO = heterotopic ossification, MEPS = Mayo Elbow Performance Score, ROM = range of motion.

Keywords: complications, open surgical release, post-traumatic elbow stiffness, range of motion, systematic review, timing

1. Introduction

Elbow stiffness is generally defined as elbow range of motion (ROM) < 30° to 130°. Morrey et al^[1] reported that most of our

daily activities can be accomplished with 100° of elbow flexion (from 30° to 130°) and 100° of forearm rotation (50° of pronation and 50° of supination). Although a variety of causes may lead to elbow stiffness, elbow stiffness is mainly caused by traumatic causes. Post-traumatic elbow stiffness may result from contracture of the joint capsule and ligaments, muscle contracture, adherence, osteophytes, ectopic ossification, articular surface incongruity, and loose bodies.^[2]

There are 2 major methods to treat elbow stiffness: nonoperative and operative methods. Nonoperative methods include myofascial soft tissue mobilization, joint mobilization, splinting, and so on.^[2–4] Operative methods mainly include arthroscopy and open arthrolysis. Due to the complex pathology, arthroscopy often fails to result in complete release and thus open arthrolysis should be the optimal method.^[4–6] Generally, if functional ROM is not obtained by nonoperative treatment, surgical release may be taken into consideration.

Operation is usually performed 6 months or more after injury, during which time bone gradually grows to be mature and secondary contracture of soft tissue occurs leading to dissatisfactory outcomes.^[7,8] Several studies have reported that early surgical release is both safe and effective.^[9,10] There is no guideline on the optimal time point of surgical release so far. Therefore, we initiated a systematic review of studies on the time point of surgical release to compare recurrence rates and obtained ROM between early and late release; thus providing a reference for the optimal time point of surgical release.

Editor: Johannes Mayr.

CS and HDY conceived and designed the study; CS and CLY searched potential citations, selected studies, collected information and drafted the article; CS, XJZ, KP, CYF, and HDY edited the article. All authors have reviewed the manuscript.

This study was supported by the new technology and Project of the Second Affiliated Hospital and Yuying Children's Hospital of Wenzhou Medical University.

The authors have no funding and conflicts of interest to disclose.

^aDepartment of Orthopaedics (Division of Plastic and Hand Surgery), The Second Affiliated Hospital and Yuying Children's Hospital of Wenzhou Medical University, Wenzhou, ^bDepartment of Orthopedics, Shanghai Jiao Tong University Affiliated Sixth People's Hospital, Shanghai, China.

*Correspondence: Hede Yan, Department of Orthopedic Surgery (Division of Plastic and Hand Surgery), The Second Affiliated Hospital and Yuying Children's Hospital of Wenzhou Medical University, 109 West Xueyuan Road, Lucheng District, Wenzhou, China, 325027 (e-mail: yanhede@hotmail.com)

Copyright © 2017 the Author(s). Published by Wolters Kluwer Health, Inc. This is an open access article distributed under the terms of the Creative Commons Attribution-Non Commercial-No Derivatives License 4.0 (CCBY-NC-ND), where it is permissible to download and share the work provided it is properly cited. The work cannot be changed in any way or used commercially without permission from the journal.

Medicine (2017) 96:49(e9121)

Received: 16 July 2017 / Received in final form: 14 November 2017 / Accepted: 15 November 2017

<http://dx.doi.org/10.1097/MD.00000000000009121>

2. Methods

This systematic review is reported on the basis of the Preferred Reporting Items for Systematic Reviews and Meta-Analysis (PRISMA) guidelines.^[11] Since it was a systematic review, it did not need ethical approval or patient consent.

2.1. Inclusion and exclusion criteria

An article was found eligible when it: (1) met diagnosis standards for post-traumatic elbow stiffness (such as elbow arc of motion $<30^{\circ}$ – 130° after trauma);(2) provided data regarding the time point of surgical release;(3) reported treatment of open surgery and results of post-traumatic elbow stiffness in human adults with a minimal follow-up of 1 year. We excluded articles if they: (1) reported on stiff elbow after burns or brain injury, outcomes of arthroscopic arthrolysis or arthroplasty, or revision operations;(2) were reviews, expert opinions, case reports on 5 or less patients, cadaveric or biomechanical studies, or full texts not available; (3) did not provide related data on outcomes.

2.2. Search strategy

We searched the PubMed, Cochrane Library, and EMBASE in September 2016 and updated our search in March 2017 using the following keywords ([elbow] AND (stiff* or contracture or ankylos*)) AND (releas* or arthrolysis) to include relevant studies as many as possible. In addition, we performed manual searches for references regarding stiff elbow or elbow stiffness to find potential relevant studies. The search was limited to articles written in English.

2.3. Data extraction

Two authors (CS and CLY) separately extracted data from articles which had been selected according to the inclusion and exclusion criteria and the final data were selected by their common decisions. The data include: surgical timing, number of patients, gender, mean age, outcome measures, mean follow-up, and general complications.

2.4. Statistical analysis

This review has extracted and summarized data from 27 studies involving 836 patients (Table 1). The average time from initial injury to surgery in all patients ranged from 6 to 120 months (Table 2). Early release was defined as release performed at less than 10 months.^[7,12] Considering the sum of articles, the sum of patients and surgical timing, we divided all included studies into 3 groups: 6 to 10 months after injury (the first group), 11 to 20 months after injury (the second group), >20 months after injury (the third group), as listed in Table 3. It was clear that most studies had different inclusion criteria, outcome measures, and postoperative protocols, thus prohibiting statistical analysis among the different studies. Nonetheless, a general comparison in terms of improvements in arc of motion, complications rate, and recurrence rate were carried out, all of which were crucial parameters in evaluation of surgical treatment.

3. Results

3.1. Process outcomes

We included 27 articles with an overall enrollment of 836 patients (Table 1). The number of patients in the articles ranged

Table 1

Characteristics of articles included.

Author (Year)	Study design	Level of evidence	No. of patients	Mean age, years	Female, %	Mean FU, months
Chen (2015) ^[17]	R	3	52	38.3	32.7	15
Yu (2015) ^[41]	R	4	15	31.2	86.7	22
Wang (2014) ^[30]	R	4	46	37	45.7	24.3
Hong (2013) ^[4]	R	4	15	37.9	40	31.1
Koh (2013) ^[18]	R	4	77	37.8	42.9	42.3
Koh (2013) ^[42]	R	4	24	38.8	54.1	60.0
Liu (2013) ^[21]	R	4	8	31.7	12.5	26
Ouyang (2013) ^[43]	R	4	11	41.9	36.4	29.1
Ehsan (2012) ^[9]	R	4	77	45	32.5	12
Kevin (2012) ^[31]	R	4	6	41.5	33	20
Liu (2011) ^[32]	R	4	12	34	33.3	15
Park (2010) ^[19]	R	4	42	37	52.4	38.5
Kulkarni (2010) ^[36]	R	4	26	30	42.3	62
Rex (2008) ^[20]	R	4	47	30.8	23.4	33.9
Nobuta (2008) ^[22]	R	4	27	42	33.3	18
Sharma (2007) ^[38]	R	4	25	34	24	94
Tosun (2007) ^[33]	R	4	20	30	45	12
Virak (2006) ^[6]	R	4	52	35.1	38.5	18.7
Marti (2002) ^[44]	R	4	46	31	50	120
Yang (2002) ^[40]	R	4	7	31	28.6	17
Olivier (2000) ^[39]	R	4	91	34	50.5	44
Viola (1999) ^[37]	P	4	15	28	6.7	29
Kraushaar (1999) ^[45]	R	4	12	28.5	25	36.5
Cohen (1998) ^[46]	R	4	22	35	45.5	29
Boerboom (1993) ^[47]	R	4	14	36	41.7	62
Amillo (1992) ^[48]	R	4	34	31	38.2	48
Weizenbluth (1989) ^[49]	R	4	13	29	38.5	60

FU (m) = months of follow-up, P = prospective, R = retrospective.

Table 2
Functional outcomes of articles included.

Author (Year)	TFI, months	Prearc, degree	Post-arc, degree	Gain in arc, degree	Complication, %	Recurrence%	Pre-MEPS	Post-MEPS
Yang (2002) ^[40]	6	54	127	73	14.3	0	–	–
Viola (1999) ^[37]	6	43	120	77	13.3	0	–	–
Chen (2015) ^[17]	6.1	38	112	84	30.8	21.2%	55	92
Tosun (2007) ^[33]	6.8	35	86.2	51.2	35	20%	–	–
Liu (2013) ^[21]	8.3	29.4	113.1	83.7	50	25%	57.5	92.5
Liu (2011) ^[32]	9	35	115	80	16.7	0	–	–
Kulkarni (2010) ^[36]	9.1	15.6	102.4	86.8	11.5	0	45	89
Kevin (2012) ^[31]	10	28	100	72	16.7	0	–	–
Park (2010) ^[19]	10	55	115	60	16.7	4.8%	73	94
Wang (2014) ^[30]	11	25	126	101	21.7	6.5%	63	91
Rex (2008) ^[20]	12.6	33.9	105	71.1	14.9	0	66.6	93.8
Sharma (2007) ^[38]	13	55	105	50	32	4%	65	90
Olivier (2000) ^[39]	13	49	94	45	13.2	7.7%	–	–
Yu (2015) ^[41]	14	37	116	79	33.3	13.3%	–	–
Nobuta (2008) ^[22]	14	53	95	42	29.6	14.8%	–	–
Virak (2006) ^[6]	14	57	116	59	48.1	26.9%	–	–
Koh (2013) ^[18]	16.4	45	112	67	35.1	20.8%	71	95
Amillo (1992) ^[48]	19	45	92	47	29.4	8.8%	–	–
Marti (2002) ^[44]	21	45	99	55	41.3	8.7%	–	–
Hong (2013) ^[4]	21.2	0	116	116	40	20%	67.7	86.7
Boerboom (1993) ^[47]	22	73	112	39	7.1	7.1%	–	–
Ouyang (2013) ^[43]	22.1	41.3	114.1	72.8	54.5	0	59	87.2
Koh (2013) ^[42]	26.1	60	105	45	20.8	4.2%	69	87
Ehsan (2012) ^[9]	32	51	109	58	18.2	7.8%	–	–
Weizenbluth (1989) ^[49]	60	34	85	51	38.5	15.4%	–	–
Cohen (1998) ^[46]	70	74	129	55	31.8	0	50	89
Kraushaar (1999) ^[45]	120	70	117	47	33.3	33.3%	–	–

MEPS=Mayo Elbow Performance Score, TFI=Time from injury.

from 6 to 91. These articles were published between 1989 and 2017. Figure 1 presents the number of articles screened, assessed, and included in the review. Table 1 summarizes the main characteristics of articles included in the systematic review. There was one retrospective cohort study (level 3) and the rest were case series (level 4), as assessed by the Oxford Centre for Evidence-Based Medicine 2011 Levels of Evidence.^[13]

3.2. Results of analysis

3.2.1. Range of motion (ROM). We took the data regarding ROM as main functional outcome (Table 3). The mean preoperative arc of motion was 38.5°, 44.7°, and 50.5° for groups 1 to 3, respectively. The mean postoperative arc of motion was 109.7°, 106.3°, and 108.4° for groups 1 to 3, respectively. The mean gain in arc of motion was 71.2°, 61.6°, and 57.9° for groups 1 to 3, respectively. By comparison, the first group (surgical timing:6–10 months after injury) whose mean

preoperative arc of motion was the smallest in 3 groups achieved the highest mean gain in arc of motion, which was 8.6° more than the total mean gain in arc of motion.

3.2.2. Complications. Complications included infection, heterotopic ossification, elbow instability, nerve complications, pain and others and the mean complications rate was 22.9%, 25.8%, and 28.6% for groups 1 to 3, respectively. We classified the complications into major ones (including infection, elbow instability, nerve complications, recurrence, and refracture) and minor ones (including pain and others). The mean rate of major complications was 17.0%, 22.7%, and 21.4% for groups 1 to 3, respectively (Table 4). Group 1 had the lowest major complications rate and the lowest mean complications rate. The mean rate of recurrence was 10.1%, 12.1%, and 9.0% for groups 1 to 3, respectively (Table 4). The mean rate of pain was 0, 1.2%, and 5.1% for groups 1 to 3, respectively (Table 4). Apparently Group 1 had the lowest mean rate of pain.

Table 3
Summary of different surgical timing.

Surgical timing, months	Sum of articles	Sum of patients	Mean age, years	Mean FU, months	Mean arc, degree Pre/Post/ gain	Mean% of complications	Recurrence%	MEPS Pre/Post
6–10	9	188	34.4	28.3	38.5/109.7/71.2	43 (22.9%)	19 (10.1%)	59.0/92.1
11–20	9	414	35.0	38.0	44.7/106.3/61.6	107 (25.8%)	50 (12.1%)	67.3/93.1
>20	9	234	37.8	48.7	50.5/108.4/57.9	67 (28.6%)	21 (9.0%)	61.4/87.6
Total	27	836	35.6	38.8	45.0/107.6/62.6	217 (26.0%)	90 (10.8%)	63.5/91.8

FU (m)=months of follow-up, MEPS=Mayo Elbow Performance Score.

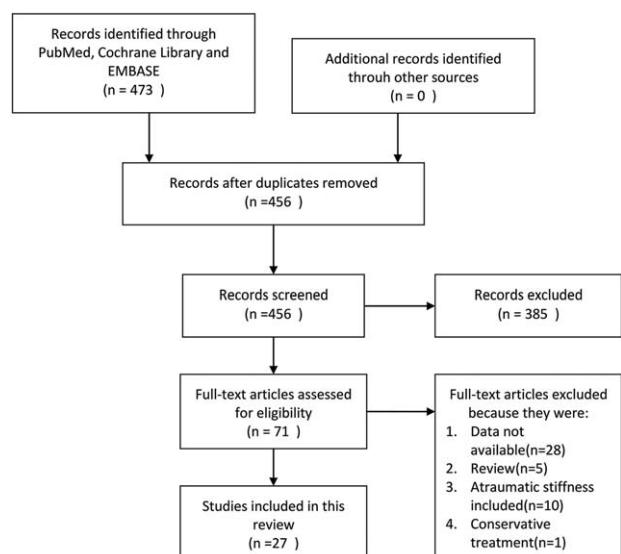


Figure 1. Flowchart for article selection.

arthrolysis from 12 months to 6 months. Due to a high incidence of recurrence, surgical excision of HO is usually delayed for 12 to 24 months (from injury to operation) until the maturation of bone occurs.^[12,14–16,24–29] Most of these articles were published before 2000. As time went by, many authors whose articles had been published after 2000 advised that nonoperative treatment such as physiotherapy, dynamic splinting, and static progressive splinting should be continued for at least 6 months before operative treatment.^[6,9,10,17–22,30–40] Apparently, the waiting period from injury to operation was shorter than before.

From Table 3, it was clear that the first group (surgical timing: 6–10 months) achieved the highest mean gain in arc of motion, which was 8.6° more than the total mean gain in arc of motion. From Tables 3 and 4, group 1 had the lowest major complications rate, the lowest mean complications rate, and the lowest mean rate of pain. But the mean rate of recurrence in group 1 was not the lowest. We thought that there were 2 major factors contributing to this result. Firstly, the slight recurrent HO seen on plainfilms made a contribution. At the least 12 months follow-up, the small degrees of HO did not affect the function of elbow and the final ROM was considerably improved.^[17,19,21] Secondly, the number of patients in the first group were small, which could improve the ratio. So we concluded that the shorter waiting period of 6 to 10 months yielded better results. Therefore, early surgical release of stiff elbows is recommended for a shorter rehabilitation time and earlier return to work.

There is no definite evidence indicating that the surgical delay means less recurrence and better function. Rex et al^[20] have reported that they believe that it is most beneficial to excise HO in the first 6 months following injury and it is unnecessary to wait for the maturity of HO before excision. Viola and Hanel^[37] performed early excision, at a mean waiting period of 23 weeks, in 15 elbows with post-traumatic elbow stiffness, and they found no recurrence. Yang et al^[40] analyzed the results of early surgical management (mean, 6 months) in 7 patients. Their results were satisfactory. Almost full range of motion and complete functional ability following surgery were recovered in 6 of the 7 patients. Koh et al^[18] reported that delayed surgery is associated with less favorable results. Early improvement in ROM is significant for early rehabilitation and the recovery of elbow function.^[6,14] Early release will bring significant convenience and less pain to patients' daily life. Early release will accelerate the treatment time and recovery period, which will enable patients to return to daily life and work as soon as possible.

Many factors affect postoperative outcomes. Physical therapy and constant passive exercise are useful to minimize the loss of ROM acquired intraoperatively. The rigorous rehabilitation exercises are beneficial to prevent the recurrence of joint adhesion, thus leading to good results. Patients' compliance with postoperative rehabilitation program is important for favorable postoperative outcomes.

3.2.3. Mayo elbow performance score (MEPS). The mean post-operative MEPS was 92.1, 93.1, and 87.6 for groups 1 to 3, respectively. The mean postoperative MEPS in group 1 was 92.1, which was slightly higher than total mean postoperative MEPS.

4. Discussion

The surgical timing is vital to the treatment and rehabilitation of elbow stiffness, but the surgical timing is controversial. There is no guideline on the optimal surgical time point for release so far, which is usually dependent on surgeons' experience. Surgical release is commonly indicated when nonoperative treatment fails to improve ROM after a period. It is emphasized that a delay of at least 12 or 6 months is necessary to ensure that the maturation of bone occurs,^[9,12,14–22] which leads to a low risk of recurrence. However, during the waiting period the stiff elbow gives rise to significant inconvenience to a patient's daily life. During this period the ligaments and capsules undergo fibrosis, and articular cartilage degrades and muscles atrophies, contributing to secondary joint arthrosis. Secondary joint arthrosis, in turn, will aggravate elbow stiffness.^[17] The ulnar nerve will be damaged by ischemia and compression due to constant flexion of the elbow or pressure caused by HO.^[23]

Generally, when nonoperative treatment fails to obtain functional ROM, surgical release may be taken into consideration. But the optimal time point of surgical release is difficult to determine. By studying many articles, we found that there was a trend toward a shorter waiting time from injury to open

Table 4

Summary of complications in each group.

Group	Major complications					Minor complications		
	Infection, %	Elbow instability, %	Nerve complications, %	Recurrence, %	Refracture	Pain	Others, %	Sum, %
1	3.2	2.1	1.6	10.1	0	0	4.8	5.9
2	1.2	2.2	7.2	12.1	0	1.2%	3.1	3.1
3	3.0	0.4	6.4	9.0	2.6%	5.1%	6.0	7.3

There are some limitations in this review. Firstly, the number of patients among 3 groups differs a lot; thus probably leading to the high rate of recurrence in the first group, which affected our analysis. Secondly, the level of evidence in articles included is low and the general strength of evidence is level IV. Thirdly, although all articles included were selected strictly according to inclusion and exclusion criteria, it was unhomogeneous in surgical techniques, the degree of stiffness in elbows, postoperative rehabilitation protocols, and the follow-up time among studies, thus limiting other specific statistical analysis.

5. Conclusions

In summary, there was a trend toward a shorter waiting time from injury to open arthrolysis from 12 months to 6 months. The shorter waiting period of 6 to 10 months yielded better results. Therefore, early surgical release of stiff elbows is recommended for a shorter rehabilitation time and earlier return to work. More and larger prospective studies are needed to determine the most beneficial surgical timing.

References

- Morrey BF, Askew LJ, Chao EY. A biomechanical study of normal functional elbow motion. *J Bone Joint Surg Am* 1981;63:872–7.
- Davila SA, Johnston-Jones K. Managing the stiff elbow: operative, nonoperative, and postoperative techniques. *J Hand Ther* 2006;19:268–81.
- Wilk KE, Arrigo C, Andrews JR. Rehabilitation of the elbow in the throwing athlete. *J Orthop Sports Phys Ther* 1993;17:305–17.
- Ruan HJ, Liu S, Fan CY, et al. Open arthrolysis and hinged external fixation for posttraumatic ankylosed elbows. *Arch Orthop Trauma Surg* 2013;133:179–85.
- Kodde IF, van Rijn J, van den Bekerom MP, et al. Surgical treatment of post-traumatic elbow stiffness: a systematic review. *J Shoulder Elbow Surg* 2013;22:574–80.
- Tan V, Daluiski A, Simic P, et al. Outcome of open release for post-traumatic elbow stiffness. *J Trauma* 2006;61:673–8.
- Moritomo H, Tada K, Yoshida T. Early, wide excision of heterotopic ossification in the medial elbow. *J Shoulder Elbow Surg* 2001;10:164–8.
- Tsionos I, Leclercq C, Rochet JM. Heterotopic ossification of the elbow in patients with burns. Results after early excision. *J Bone Joint Surg Br* 2004;86:396–403.
- Ehsan A, Huang JI, Lyons M, et al. Surgical management of posttraumatic elbow arthrofibrosis. *J Trauma Acute Care Surg* 2012;72:1399–403.
- Lindenhovius AL, Linzel DS, Doornberg JN, et al. Comparison of elbow contracture release in elbows with and without heterotopic ossification restricting motion. *J Shoulder Elbow Surg* 2007;16:621–5.
- Moher D, Liberati A, Tetzlaff J, et al. Preferred reporting items for systematic reviews and meta-analyses: the PRISMA statement. *PLoS Med* 2009;6:e1000097.
- McAuliffe JA, Wolfson AH. Early excision of heterotopic ossification about the elbow followed by radiation therapy. *J Bone Joint Surg Am* 1997;79:749–55.
- Howick F CI, Glasziou P, Greenhalgh T, et al. Explanation of the 2011 Oxford Centre for Evidence-Based Medicine (OCEBM) Levels of Evidence (Background Document). OCEBM 2011.
- Beingessner DM, Patterson SD, King GJ. Early excision of heterotopic bone in the forearm. *J Hand Surg Am* 2000;25:483–8.
- Naraghi FF, DeCoster TA, Moneim MS, et al. Heterotopic ossification. *Orthopedics* 1996;19:145–51.
- Hastings H2nd, Graham TJ. The classification and treatment of heterotopic ossification about the elbow and forearm. *Hand Clin* 1994;10:417–37.
- Chen S, Yu SY, Yan H, et al. The time point in surgical excision of heterotopic ossification of post-traumatic stiff elbow: recommendation for early excision followed by early exercise. *J Shoulder Elbow Surg* 2015;24:1165–71.
- Koh KH, Lim TK, Lee HI, et al. Surgical treatment of elbow stiffness caused by post-traumatic heterotopic ossification. *J Shoulder Elbow Surg* 2013;22:1128–34.
- Park MJ, Chang MJ, Lee YB, et al. Surgical release for posttraumatic loss of elbow flexion. *J Bone Joint Surg Am* 2010;92:2692–9.
- Rex C, Suresh Kumar PM, Srimannarayana A, et al. Analysis of results of surgical treatment of posttraumatic stiff elbow. *Indian J Orthop* 2008;42:192–200.
- Liu S, Liu JJ, Li XJ, et al. Open arthrolysis and prosthetic replacement of the radial head for elbow stiffness associated with rotation limitation. *J Shoulder Elbow Surg* 2013;22:275–9.
- Nobuta S, Sato K, Kasama F, et al. Open elbow arthrolysis for post-traumatic elbow contracture. *Ups J Med Sci* 2008;113:95–102.
- Cipriano CA, Pill SG, Keenan MA. Heterotopic ossification following traumatic brain injury and spinal cord injury. *J Am Acad Orthop Surg* 2009;17:689–97.
- Abrams RA, Simmons BP, Brown RA, et al. Treatment of posttraumatic radioulnar synostosis with excision and low-dose radiation. *J Hand Surg Am* 1993;18:703–7.
- Garland DE. A clinical perspective on common forms of acquired heterotopic ossification. *Clin Orthop Relat Res* 1991;263:13–29.
- Morrey BF. Post-traumatic contracture of the elbow. Operative treatment, including distraction arthroplasty. *J Bone Joint Surg Am* 1990;72:601–18.
- Failla JM, Amadio PC, Morrey BF. Post-traumatic proximal radio-ulnar synostosis. Results of surgical treatment. *J Bone Joint Surg Am* 1989;71:1208–13.
- Vince KG, Miller JE. Cross-union complicating fracture of the forearm. Part I: Adults. *J Bone Joint Surg Am* 1987;69:640–53.
- Thompson HC 3rd, Garcia A. Myositis ossificans: aftermath of elbow injuries. *Clin Orthop Relat Res* 1967;50:129–34.
- Wang W, Jiang SC, Liu S, et al. Stability of severely stiff elbows after complete open release: treatment by ligament repair with suture anchors and hinged external fixator. *J Shoulder Elbow Surg* 2014;23:1537–44.
- Malone KJ, Martineau PA, Hanel DP. Ulnar collateral ligament reconstruction in posttraumatic elbow release. *Orthopedics* 2012;35:e202–7.
- Liu S, Fan CY, Ruan HJ, et al. Combination of arthrolysis by lateral and medial approaches and hinged external fixation in the treatment of stiff elbow. *J Trauma* 2011;70:373–6.
- Tosun B, Gundes H, Buluc L, et al. The use of combined lateral and medial releases in the treatment of post-traumatic contracture of the elbow. *Int Orthop* 2007;31:635–8.
- Heirweg S, De Smet L. Operative treatment of elbow stiffness: evaluation and outcome. *Acta Orthop Belg* 2003;69:18–22.
- King GJ, Faber KJ. Posttraumatic elbow stiffness. *Orthop Clin North Am* 2000;31:129–43.
- Kulkarni GS, Kulkarni VS, Shyam AK, et al. Management of severe extra-articular contracture of the elbow by open arthrolysis and a monolateral hinged external fixator. *J Bone Joint Surg Br* 2010;92:92–7.
- Viola RW, Hanel DP. Early “simple” release of posttraumatic elbow contracture associated with heterotopic ossification. *J Hand Surg Am* 1999;24:370–80.
- Sharma S, Rymaszewski LA. Open arthrolysis for post-traumatic stiffness of the elbow: results are durable over the medium term. *J Bone Joint Surg Br* 2007;89:778–81.
- Olivier LC, Assenmacher S, Setareh E, et al. Grading of functional results of elbow joint arthrolysis after fracture treatment. *Arch Orthop Trauma Surg* 2000;120:562–9.
- Yang SC, Chen AC, Chao EK, et al. Early surgical management for heterotopic ossification about the elbow presenting as limited range of motion associated with ulnar neuropathy. *Chang Gung Med J* 2002;25:245–52.
- Yu SY, Yan HD, Ruan HJ, et al. Comparative study of radial head resection and prosthetic replacement in surgical release of stiff elbows. *Int Orthop* 2015;39:73–9.
- Koh KH, Lim TK, Lee HI, et al. Surgical release of elbow stiffness after internal fixation of intercondylar fracture of the distal humerus. *J Shoulder Elbow Surg* 2013;22:268–74.
- Ouyang Y, Liao Y, Liu Z, et al. Hinged external fixator and open surgery for severe elbow stiffness with distal humeral nonunion. *Orthopedics* 2013;36:e186–92.
- Marti RK, Kerkhoffs GM, Maas M, et al. Progressive surgical release of a posttraumatic stiff elbow. Technique and outcome after 2–18 years in 46 patients. *Acta Orthop Scand* 2002;73:144–50.
- Kraushaar BS, Nirschl RP, Cox W. A modified lateral approach for release of posttraumatic elbow flexion contracture. *J Shoulder Elbow Surg* 1999;8:476–80.

- [46] Cohen MS, Hastings H2nd. Post-traumatic contracture of the elbow. Operative release using a lateral collateral ligament sparing approach. *J Bone Joint Surg Br* 1998;80:805–12.
- [47] Boerboom AL, de Meyier HE, Verburg AD, et al. Arthrolysis for post-traumatic stiffness of the elbow. *Int Orthop* 1993;17:346–9.
- [48] Amillo S. Arthrolysis in the relief of post-traumatic stiffness of the elbow. *Int Orthop* 1992;16:188–90.
- [49] Weizenbluth M, Eichenblat M, Lipskeir E, et al. Arthrolysis of the elbow. 13 cases of posttraumatic stiffness. *Acta Orthop Scand* 1989; 60:642–5.