

Prenatal diagnosis of cryptorchid testicular teratoma

Rahul Rajendra Arkar, Rajesh A Umap¹, Sudhakar Jadhav²

Department of Radiology, B. J. Medical College and Sassoon General Hospital, ¹Department of Radiology, B. J. Medical College, Pune, ²SJKC Trust's Paed-Surgery Centre and P. G. Institute, Sangli, Maharashtra, India

Correspondence: Dr. Rahul Rajendra Arkar, Department of Radiology, B. J. Medical College and Sassoon General Hospital, Pune - 411 001, Maharashtra, India. E-mail: rrrakar@gmail.com

Abstract

Testis follows a predictable course during its stepwise descent from its site of origin in the lumbar region to its final destination in ipsilateral hemi-scrotum. Undescended (cryptorchid) testis is more prone for neoplastic transformation. Testicular teratoma is rare relative to ovarian teratoma and occurs rarely prenatally than postnatally. Teratoma is composed of derivatives of three germ layers. Ultrasound with color Doppler is the most commonly used modality for assessment of prenatal status. Prenatal diagnosis of cryptorchid testicular teratoma involves identification of well-defined, complex solid-cystic lesion with calcifications along the path of testicular descent and absent testis in ipsilateral hemi-scrotum at 36 weeks of gestation. Complications associated with cryptorchid testicular teratoma include torsion, hemorrhage, or malignant transformation. Early diagnosis is important to avoid complications, and hence, ultrasound imaging features play an important role in diagnosis.

Key words: Cryptorchid; malignant transformation; teratoma

Introduction

Ovarian teratoma is far more common than testicular teratoma.^[1,2] Testicular teratoma usually appears during infancy as a palpable scrotal mass. We report a case of mature teratoma of the undescended left testis diagnosed on the basis of prenatal ultrasonography. Worldwide, totally five similar cases were reported in literature previously. Not a single case was reported from India. The ultrasound features and clinical implications of the condition will be discussed.

Case Report

A 26-year-old gravida 1 woman with no medical or surgical illness was referred for third trimester growth profile ultrasonography to our center at 36 weeks of gestation

as a routine procedure showed 2.0 × 1.8 cm sized, well-circumscribed lesion in pelvis. The lesion was round in shape, cystic with a solid component, located on the left lateral side of urinary bladder [Figure 1]. The lesion showed few discrete subcentimeter-sized foci of calcifications. The overall ultrasonographic image was similar to that of an ovarian dermoid cyst. Left scrotal sac was empty, while the right scrotal sac showed normal echogenicity gonad of size 1.4 × 0.9 cm, and there were no other structural abnormalities identified. The provisional diagnosis of cryptorchid testicular teratoma was made and follow-up ultrasonography was suggested on day 1 of postnatal life. The neonate was born via the vaginal route. After delivery, the neonate was found to have left undescended testis with normal positioned right

This is an open access article distributed under the terms of the Creative Commons Attribution-NonCommercial-ShareAlike 3.0 License, which allows others to remix, tweak, and build upon the work non-commercially, as long as the author is credited and the new creations are licensed under the identical terms.

For reprints contact: reprints@medknow.com

Cite this article as: Arkar RR, Umap RA, Jadhav S. Prenatal diagnosis of cryptorchid testicular teratoma. Indian J Radiol Imaging 2016;26:67-9.

Access this article online

Quick Response Code:



Website:
www.ijri.org

DOI:
10.4103/0971-3026.178334

testis. The left testis was not palpable in the left inguinal canal. Postnatal ultrasonographic examination revealed a well-defined round to oval mass (2.0 × 1.9 cm) with foci of subcentimeter-sized calcifications located on the left lateral side of urinary bladder [Figure 2 postnatal]. The right testis was normal in echogenicity with normal position. Tumor marker levels were within reference ranges. The tumor was excised by laparotomy at day 3 of neonatal period. Intraoperatively, a 2.0 × 1.5 cm sized left testicular mass was found on the left lateral side of urinary bladder [Figure 3 of surgical photos]. Histology examination showed testis with a tumor composed of elements of all germ cell layers, viz. skin with adnexal structures, wall of small intestine with mucosal and muscular layers, fibrovascular tissue, brown fat, cartilage, bone with bone marrow, lymphoid tissue, glial tissue, and few areas of immature mesenchyme. On histopathology, surrounding testicular parenchyma showed primitive seminiferous tubules. Also, the tumor was confined to testis.

The diagnosis of mature (pure) testicular teratoma was thus confirmed. The infant recovered well from the surgery and was discharged from the hospital.

Discussion

The well-known consequence of undescended testis is neoplastic change. There is 3–8 times higher risk of neoplasia in cryptorchid testis relative to general population.^[3] The incidence of testicular neoplasm in prepubertal age group is 0.5 per 100,000, while that in postpubertal age group is 10 times higher, i.e. 5.4 per 100,000.^[1] Teratomas contribute to 23–48% of prepubertal testicular tumors.^[1,4] Prepubertal testicular teratoma presents at a median age of 13 months.^[5] In adults, intratubular germ cell neoplasia is considered a precursor to testicular germ cell tumors and is found in

2%-8% of adults with a history of cryptorchidism, but it has historically not been found in association with prepubertal germ cell tumors.^[6] Intratubular germ cell neoplasia has been reported adjacent to mature teratoma in a prepubertal patient as an exceptionally rare finding.^[7] The differential diagnosis for a prenatally detected cystic abdominal mass includes lymphangioma, neuroblastoma, gonadal teratoma, multicystic dysplastic kidney, meconium cyst, and intestinal duplication cyst.^[8,9] The organ of origin for most cystic abdominal masses in the neonate is kidney;^[9] however, the pelvic location of the mass in our case suggested a gonadal origin. The appearance of the mass as mixed cystic with calcifications helps to further narrow the differential diagnosis in favor of a testicular teratoma. Till date, five cases of prenatally detected testicular teratoma have been reported in literature. No case has been reported from the Asian continent. Mboyo *et al.*^[10] detected a 2.5 × 2.3 cm cystic and solid mass on the left side of the bladder on prenatal ultrasonography at 31 weeks gestation. It was excised on day 13 of life. Shih *et al.*^[11] reported a 5 × 4 × 3 cm semi-solid mass with central echogenicity in front of the right fetal kidney and anterior to the bladder at 36 weeks gestation. It was excised at 6 days of life. Siu *et al.*^[12] reported a 3 cm, well-circumscribed, round, mixed cystic and solid intra-abdominal lesion located below the liver, anterior to the right kidney, and superior to the bladder at 30 weeks gestation. The lesion was excised at 1 month of age. Pramanik *et al.*^[3] evaluated an infant at 6 months of age who was previously found to have a 2.1 × 1.9 cm mass in the right iliac fossa at 27 weeks gestation. The mass was stable on ultrasound at 30 and 35 weeks gestation and postnatally at 3 months of age. The mass was diagnosed as mature testicular teratoma on histopathology. Janda *et al.*^[13] detected 1.2 × 1.0 cm sized cystic mass on the left side of urinary bladder at 22 weeks of gestation, which on postnatal post-surgery histopathology showed features of teratoma. Cryptorchidism has been associated with

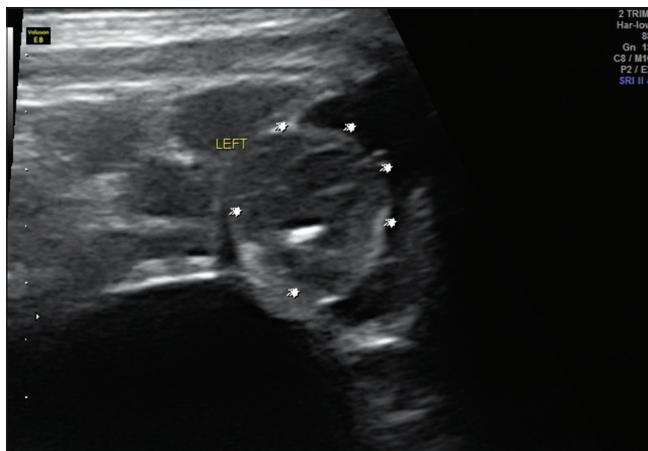


Figure 1: Prenatal USG shows well-defined round lesion on left side of urinary bladder with foci of calcifications (multiple white markers along margin of lesion). Prenatal diagnosis of cryptorchid testicular teratoma was made (images of normal testis were not included due to limitations pertaining to PCPNDT)

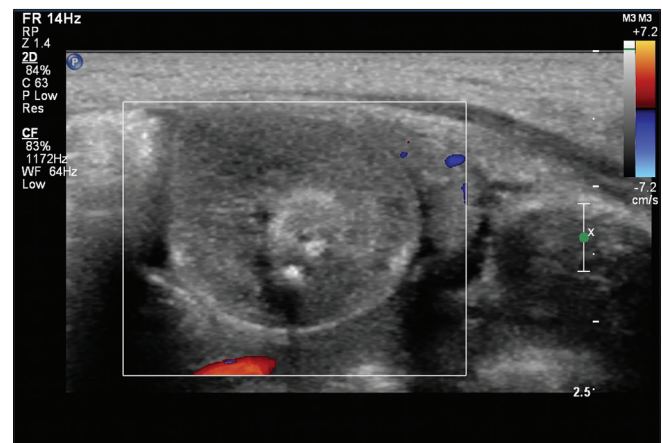


Figure 2: Postnatal USG shows cystic lesion with calcifications on left side of urinary bladder with no internal vascularity on Doppler study. These findings were similar on prenatal USG and diagnosis of cryptorchid testicular teratoma was assured

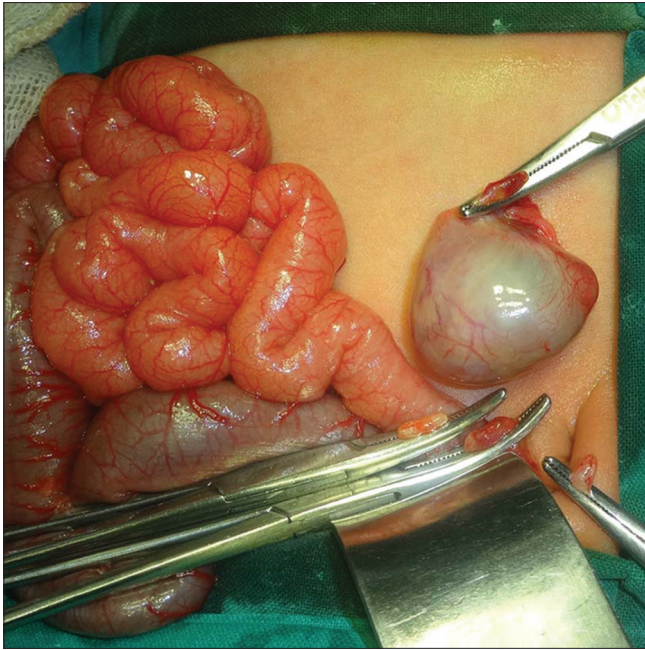


Figure 3: Intra-operative image shows lesion excised during surgery (excised lesion held with forceps)

testicular torsion. In historical series, the incidence of torsion of the testis or its appendages by 25 years was 1 in 160 men; however, cryptorchidism was associated with a 10-fold higher risk of torsion.^[14] Torsion of the intra-abdominal testicle is a rare event, and a tumor within the testicle appears to predispose the gonad to torsion. Duncan *et al.*^[15] reported that 59.5% of torsed intra-abdominal testicles were associated with testicular malignancy. Most of the intra-abdominal testicular tumors present in adulthood. In the prepubertal population, Brown *et al.*^[16] reported that six of seven patients (86%) ranging in age from 2 months to 11 years with intra-abdominal testicular torsion had testicular tumors.

Financial support and sponsorship

Nil.

Conflicts of interest

There are no conflicts of interest.

References

1. Pohl HG, Shukla AR, Metcalf PD, Cilento BG, Retik AB, Bagli DJ, *et al.* Prepubertal testis tumors: Actual prevalence rate of histological types. *J Urol* 2004;172 (6 Pt 1):2370-2.
2. Mukai M, Takamatsu H, Noguchi H, Tahara H. Intra-abdominal testis with mature teratoma. *Pediatr Surg Int* 1998;13:204-5.
3. Wood HM, Elder JS. Cryptorchidism and testicular cancer: Separating fact from fiction. *J Urol* 2009;181:452-61.
4. Ross JH, Rybicki L, Kay R. Clinical behavior and a contemporary management algorithm for prepubertal testis tumors: A summary of the prepubertal testis tumor registry. *J Urol* 2002;168 (4 Pt 2):1675-8.
5. Grady RW, Ross JH, Kay R. Epidemiological features of testicular teratoma in a prepubertal population. *J Urol* 1997;158 (3 Pt 2):1191-2.
6. Reinberg Y, Manivel JC, Fraley EE. Carcinoma *in situ* of the testis. *J Urol* 1989;142 (2 Pt 1):243-7.
7. Renedo DE, Trainer TD. Intratubular germ cell neoplasia (ITGCN) with p53 and PCNA expression and adjacent mature teratoma in an infant testis. An immunohistochemical and morphologic study with a review of the literature. *Am J Surg Pathol* 1994;18:947-52.
8. Pramanik DD, Bhatnagar V, Subbarao KC, Sharma MC, Agarwala S, Gupta AK. Antenatally detected mature teratoma in an undescended testis. *Eur J Pediatr Surg* 2011;21:209-10.
9. Schwartz MZ, Shaul DB. Abdominal masses in the newborn. *Pediatr Rev* 1989;11:172-9.
10. Mboyo A, Foulet A, Hocine S, Cheve MT, Plat M, Weil D. Teratoma in an undescended testis detected prenatally. *J Urol* 1997;158:200-1.
11. Shih HH, Teng RJ, Yau KI, Lin HH, Hsieh FJ, Chen CC. Mature teratoma arising from an intra-abdominal undescended testis presenting as a fetal abdominal mass. *Ultrasound Obstet Gynecol* 1997;10:209-11.
12. Siu SS, Leung TN, Leung TY, Ng SW, Yeung CK, Lau TK. Prenatal diagnosis of intra-abdominal mature testicular teratoma. *J Ultrasound Med* 2001;20:1257-60.
13. Janda GM, Najdzionek JS, Kozielski R, Greenfield SP, Williot PE. Early prenatal detection of an intra-abdominal cryptorchid testicular teratoma. *Urology* 2014;83:214-6.
14. Zilberman D, Inbar Y, Heyman Z, Shinhar D, Bilik R, Avigad I, *et al.* Torsion of the cryptorchid testis – can it be salvaged? *J Urol* 2006;175:2287-9.
15. Duncan ND, Gabay L, Coard KC, Antoine M, McDonald A. Torsion of an intra-abdominal testicle in a neonate. Case report and review of the literature. *West Indian Med J* 1997;46:126-7.
16. Brown IR, Dunlap HJ, Nizalik E, Schillinger JF. A child with an intra-abdominal testicular teratoma: A case report and review of prepubertal cryptorchid germ cell tumors. *Urology* 1995;46:863-6.