

CASE REPORT

Under-deployed TAVI with occluded left-main and severe aortic regurgitation; bailout chimney-in-chimney stenting and aggressive postdilatation saves the day

Pandula Athauda-arachchi^{1,2}  

¹Durdans Heart Centre, Colombo, Sri Lanka

²General Sir John Kotelawala Defence University, Colombo, Sri Lanka

Correspondence

Pandula Athauda-arachchi, Faculty of Medicine, General Sir John Kothelawala Defence University, Colombo, Sri Lanka.

Email: pma29@cantab.net

Abstract

Narrow calcific aortic roots with low coronary heights present challenges for a successful trans-catheter aortic valve replacement. We describe a case where pre-emptive coronary protection and chimney stent-in-stent procedure was successfully performed during a cardiac arrest secondary to coronary occlusion and restricted TAVI valve deployment in such an anatomy.

KEYWORDS

complication management, low-lying left-main coronary artery occlusion, paravalvular AR, TAVI under-deployment

1 | CLINICAL PRESENTATION AND INVESTIGATIONS

A 78-year-old woman had presented with a 4-month history of worsening shortness of breath and presyncope with an ejection systolic murmur and was found to have critical aortic stenosis (Peak Gradient >120 mmHg, AVA <0.5 cm²), with a small annulus and LVOT (<18 mm) and mild-moderate aortic regurgitation with preserved LV systolic function (EF > 50%). ECG showed pre-existing right bundle branch block but no evidence of second or third degree heart block on monitoring despite history of presyncope. Coronary angiogram demonstrated a left dominant coronary system with no significant obstructive disease. Patient was referred for cardiothoracic surgical opinion for surgical aortic valve replacement, but intermittent cognitive/ behavioral issues, diabetes, reduced mobility, and refusal by patient and family resulted in consideration for TAVI. Her calculated Euroscore II (mortality) for root enlargement and a SAVR was 10.99%.

The CT of aorta confirmed the difficult anatomy for TAVI, with a small annulus of 16 × 19.6 mm and a low

coronary height to dominant left main of 7 mm and small left coronary sinus (21.8 mm), with a potential for left-main occlusion. Area (251.4 sqmm) derived annular diameter was 17.9 mm (see [Figure 1](#)). Common femoral arteries were small (6.8 mm). TAVR in hospital mortality risk was calculated at 2.17%. A further multidisciplinary discussion was offered and following this patient and family decision for TAVR was finally honored.

2 | INTERVENTIONS

Transfemoral TAVI with a Balloon expandable MyVal 20 mm device (smallest available device) with transradial coronary protection was performed under local anesthesia. Valve crossing was difficult as well as retaining of a Amplatz Extra stiff wire due to small LVOT and “whipping effect” with AR. A Lundequist wire gave better support and a 16 mm balloon was used for predilatation, which surprisingly did not demonstrate any tendency for coronary occlusion by native valve leaflets. Despite this, a coronary guidewire and a 4 × 12 mm Xience DES were

This is an open access article under the terms of the [Creative Commons Attribution-NonCommercial-NoDerivs](#) License, which permits use and distribution in any medium, provided the original work is properly cited, the use is non-commercial and no modifications or adaptations are made.

© 2022 The Author. *Clinical Case Reports* published by John Wiley & Sons Ltd.

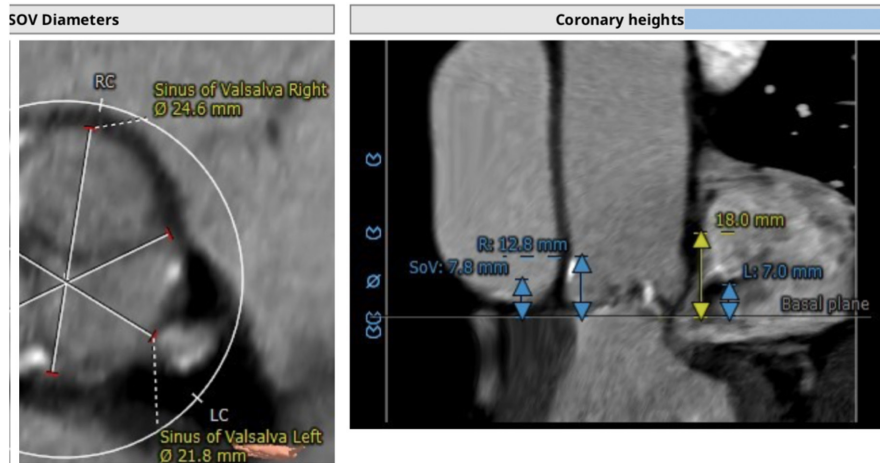


FIGURE 1 3-Mensio reconstructions of preprocedure CT aorta, illustrating shallow left coronary sinus and low left coronary height of 7 mm (left dominant system)

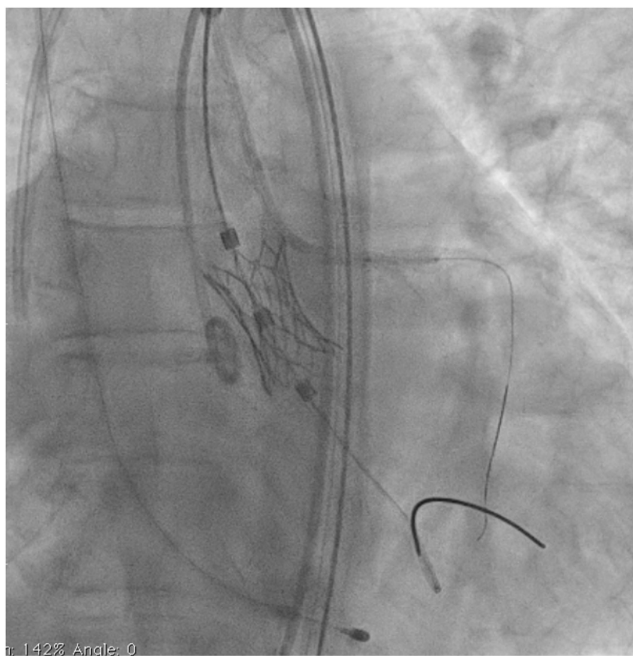


FIGURE 2 Restricted expansion of TAVI device with left-main occlusion (trace of flow restored only on engaging coronary guide whilst pulling stent forwards) and severe AR, leading to cardiac arrest

parked as a precaution in the LAD. The 20 mm valve was deployed with 2 cc less in the navigator system, under rapid pacing. However, the TAVI valve failed to expand fully (see [figure 2](#)) with severe drop in pressures, AR, and slow flow in left main culminating in cardiac arrest. CPR was promptly commenced and the waiting stent in LAD was deployed in ostium of left main as a “Chimney stent” (see [figure 3](#)). This resulted in stabilization of situation. A root angiogram showed torrential AR and a decision was made to recross and postdilate the device with the navigator system with 2 cc extra volume. The concern was that the chimney may collapse on postdilatation against the shallow sinus. The initial coronary guidewire, which had,

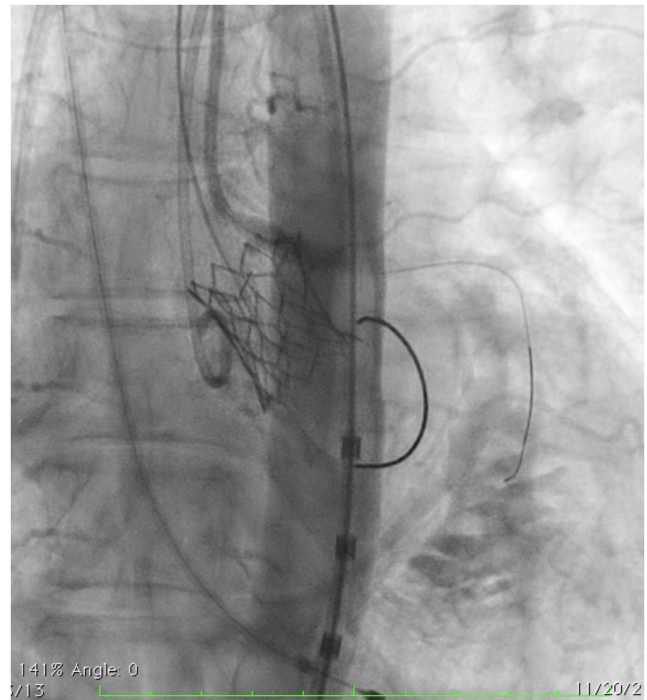


FIGURE 3 First Chimney stenting of Left main with 4×12 mm DES

unfortunately, come off to the aorta during the resuscitation attempt now had to be recrossed quickly through the ostial LM stent, avoiding any TAVI or coronary stent struts. An additional 4×8 mm DES was parked beyond the previous stent and the optimal postdilatation of TAVI device was achieved with only a trace of residual AR. Due to the concern of compromise of the previous coronary stent in this limited space, a “chimney-in-chimney” stenting was performed with another 4×8 mm DES (see [figure 4](#)), postdilated to 4.5 mm, to fully expand the struts and maintain left-main access and patency with better radial strengthening of the proximal portion of the chimney. The final result was excellent with no AR and good flow in left main coronary (See [figure 5](#)). Fluoroscopy and stent boost

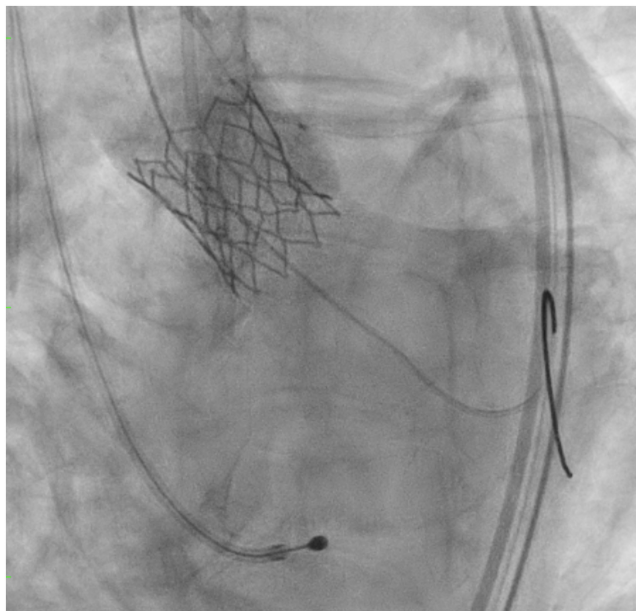


FIGURE 4 Postdilatation of TAVI and chimney-in-chimney stenting (4 × 8 mm) for additional protection of the left main

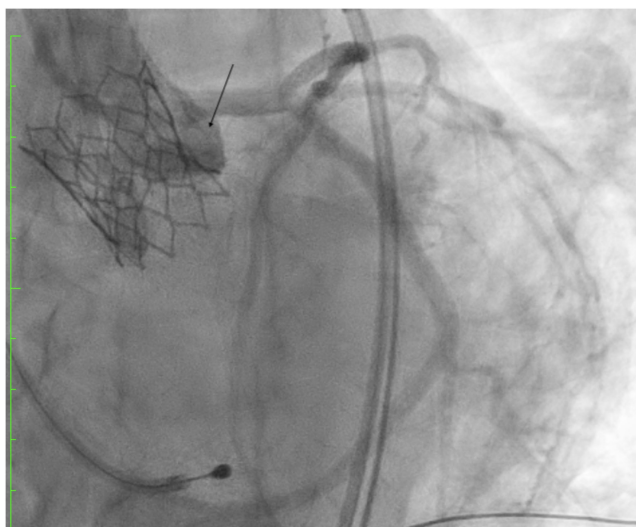


FIGURE 5 Final appearance of left mainstem and TAVI device. Bulky leaflet buttressed under the chimney-in-chimney stents (black arrow)

appearance was useful to confirm stent and valve expansion (see [Figure 6](#)). The femoral access was sealed with Proglide percutaneous sutures. Patient made an uneventful recovery [Figures 1–6](#).

3 | DISCUSSION

Potential for occlusion of low-lying left main during TAVI in native aortic stenosis could be anticipated (to an extent)

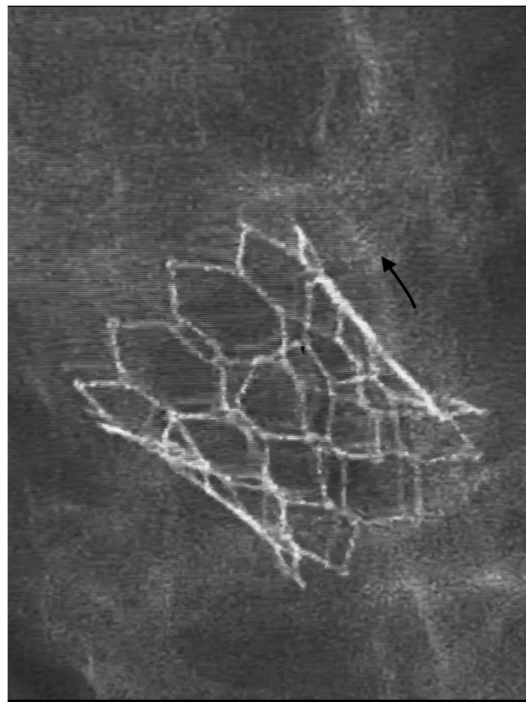


FIGURE 6 TAVI device and the overlapping distal segments of stents visible (black arrow) under fluoroscopy

based on the findings on a CT aorta.¹ Performance of a BASILICA procedure² or selection of new generation supra-annular aortic valves that grasp the native valve leaflets³ may reduce the incidence of acute coronary occlusion, but the availability of these options is varied in different countries. Whether the predilatation may or may not show the tendency for coronary occlusion, provision of coronary protection with wire/stent could be life-saving practice, but it may be difficult to implement in narrow anatomies with small annuli and small sinuses. When the TAVI devices may not fully expand and complications such as left-main occlusion and a cardiac arrest occurs, rapid restoration of left-main flow with chimney⁴ stenting is paramount and subsequent optimization of the TAVI prosthesis is mandatory. In narrow coronary sinuses, there is always a risk of the chimney stent becoming deformed or occluded, with poor outcomes perioperatively.

We described our case where “chimney-in-chimney” stenting had to be performed following postdilatation of the TAVI device to optimize the left-main blood supply. To our knowledge, this situation of chimney-in-chimney stenting has only very rarely been described in literature but could be vital to augment radial strength of the chimney in narrow anatomies in emergency situations as per our case. It is important to ensure good immediate outcomes by anticipation of potential complications, in setting up new structural heart intervention programmes to alleviate the growing heart failure epidemic in many countries with aging populations.⁵

4 | FOLLOW-UP

Patient had substantial reduction of her transaortic gradients down to 28 mmHg (Peak) and 14 mmHg (mean) with only a trace of residual paravalvular AR. The pre-existing conduction disturbance with intermittent brief episodes of heart block persisted, hence a backup permanent pacemaker was implanted. There was no chest pain/ischemia or LV dysfunction noted at 1 week. Patient remains on long-term dual antiplatelet therapy.

5 | CONCLUSIONS

Suboptimal deployment of a TAVI device in a narrow aortic annulus with proximity to left-main origin could present a challenge in balancing patient safety from complications and optimization of device parameters. Pre dilatation test of aortic valve did not appear to predict potential of complications experienced in this TAVI procedure. Chimney stenting or chimney-in-chimney stenting of left main could be life-saving in this instance but careful follow-up of patients will be required in due course.

AUTHOR CONTRIBUTION

Sole author, responsible for procedure, all data, preparation, and submission of the manuscript.

ACKNOWLEDGMENTS

The acknowledgment is to patient and family.

CONFLICT OF INTEREST

None.

DATA AVAILABILITY STATEMENT

Data sharing not applicable - no new data generated. Description of a Case

ETHICAL APPROVAL

Not applicable.

CONSENT

Written informed consent was obtained from the patient to publish this report in accordance with the journal's patient consent policy.

ORCID

Pandula Athauda-arachchi  <https://orcid.org/0000-0001-5401-5548>

TWITTER

Pandula Athauda-arachchi  @AthaudaPhD

REFERENCES

1. Corrigan FE 3rd, Gleason PT, Condado JF, et al. Imaging for predicting, detecting, and managing complications after transcatheter aortic valve replacement. *JACC Cardiovasc Imaging*. 2019;12(5):904-920. doi:10.1016/j.jcmg.2018.07.036
2. Khan JM, Greenbaum AB, Babaliaros VC, et al. The BASILICA trial: prospective multicenter investigation of intentional leaflet laceration to prevent TAVR coronary obstruction. *JACC Cardiovasc Interv*. 2019;12(13):1240-1252. doi:10.1016/j.jcin.2019.03.035
3. Möllmann H, Hengstenberg C, Hilker M, et al. Real-world experience using the ACURATE neo prosthesis: 30-day outcomes of 1,000 patients enrolled in the SAVI TF registry. *EuroIntervention*. 2018;13(15):e1764-e1770. Published 2018 Feb 2. doi:10.4244/EIJ-D-17-00628
4. Mercanti F, Rosseel L, Neylon A, et al. Chimney stenting for coronary occlusion during TAVR: insights from the chimney registry. *JACC Cardiovasc Interv*. 2020;13(6):751-761. doi:10.1016/j.jcin.2020.01.227
5. Athauda-arachchi P. Advanced interventional cardiac procedures and perioperative care required to prevent the epidemic of end-stage heart disease in Sri Lanka. *Sri Lanka Journal of Medicine*. 2019;28(1):54. doi:10.4038/sljm.v28i1.121

SUPPORTING INFORMATION

Additional supporting information can be found online in the Supporting Information section at the end of this article.

How to cite this article: Athauda-arachchi P. Under-deployed TAVI with occluded left-main and severe aortic regurgitation; bailout chimney-in-chimney stenting and aggressive postdilatation saves the day. *Clin Case Rep*. 2022;10:e06224. doi: [10.1002/ccr3.6224](https://doi.org/10.1002/ccr3.6224)