

# Fixed-flexion view X-ray of the knee superior in detection and follow-up of knee osteoarthritis

Hiroyuki Kan, MD, PhD<sup>a,b</sup>, Yuji Arai, MD, PhD<sup>c,\*</sup>, Masashi Kobayashi, MD, PhD<sup>d</sup>, Shuji Nakagawa, MD, PhD<sup>c</sup>, Hiroaki Inoue, MD, PhD<sup>a</sup>, Manabu Hino, MD<sup>a,b</sup>, Shintaro Komaki, MD<sup>a,b</sup>, Kazuya Ikoma, MD, PhD<sup>a</sup>, Keiichiro Ueshima, MD, PhD<sup>a</sup>, Hiroyoshi Fujiwara, MD, PhD<sup>a</sup>, Isao Yokota, PhD, MPH<sup>e</sup>, Toshikazu Kubo, MD, PhD<sup>a</sup>

## Abstract

A fixed flexion view (FFV) is useful for evaluating joint space when assessing the severity of osteoarthritis (OA) of the knee. We analyzed changes in joint space revealed by standing extended view (SEV) and FFV over a mean 4 years, to compare both views on their capacity to measure joint space width accurately at particular time points during follow-up.

SEV and FFV images were acquired in patients with knee OA. The 81 patients (157 knees) followed up for  $\geq 24$  months were selected as study subjects. Medial joint space widths (MJSW), Kellgren–Lawrence (KL) grades, and reductions in MJSW on SEV ( $\Delta$ SEV) and FFV ( $\Delta$ FFV) were compared in knees evaluated by SEV and FFV.

At both time-points, mean MJSW was significantly lower by FFV than by SEV. Mean MJSW was significantly lower at follow-up than at first examination by both SEV and FFV. At both time-points, the KL grade was higher by FFV than by SEV group. The  $\Delta$ FFV was significantly greater than the  $\Delta$ SEV.  $\Delta$ SEV did not differ significantly among KL grades, but  $\Delta$ FFV was significantly greater in patients with KL grade II than in patients with other KL grades.

FFV is not only useful for evaluating joint space in knees with OA, but also for accurately evaluating the progression of OA. The risk of rapid progression of knee OA may be higher in patients with KL grade II, as determined by FFV. FFV may be superior to SEV in determining appropriate treatment strategies for knee OA.

**Abbreviations:** ADL = activities of daily living, ANOVA = analysis of variance, FFV = fixed flexion view, HTO = high tibial osteotomy, ICCs = intraclass correlation coefficients, KL = Kellgren–Lawrence, MJSW = medial joint space widths, OA = osteoarthritis, SD = standard deviation, SEV = standing extended view, TKA = total knee arthroplasty, UKA = unicompartmental knee arthroplasty.

**Keywords:** fixed flexion view (FFV), knee, osteoarthritis (OA)

## 1. Introduction

The Kellgren–Lawrence (KL) classification is frequently used for staging knee osteoarthritis (OA) on plain radiography in routine medical practice, and it is useful in the selection of an appropriate treatment method and in determining the timing of treatment. In

the KL classification, the OA stage is judged mainly on the basis of osteophyte formation, narrowing of the joint space, and subchondral osteosclerosis. With the recent development of computer systems, determination of cartilage wear by numerical quantification of the joint space width has been investigated and sensitive assessment of the knee OA stage has become possible. While the frontal view of the knee joint in a standing position is used for evaluation on plain radiography, it can be difficult to accurately evaluate the joint space in the knee extension position due to influence of the cartilage wear region, meniscus, and tibial posterior tilt.<sup>[1–3]</sup> Therefore, the method by Rosenberg et al<sup>[2]</sup> has also been used, in which the image is acquired in a standing knee flexion position. The fixed flexion view (FFV)<sup>[4–6]</sup> has recently been reported as a new acquisition method, in which images can be simply acquired in a knee flexion position, which is more stable than the position employed in the Rosenberg method, thus, facilitating more accurate evaluation. We acquired images of 1102 knees with OA using the FFV method and demonstrated that this method was useful in evaluating joint space narrowing.<sup>[6]</sup> While conservative treatment is selected for early-stage knee OA, surgical treatment is selected when the cartilage is worn with progression of OA and when activities of daily living (ADL) are impaired. The treatment method differs depending on the OA stage and disease condition among conservative or surgical treatments. Thus, to select an appropriate treatment from among the many available, it is necessary to evaluate the joint space width over time with high reproducibility and to identify the degree of progression of cartilage wear compared with that on the

Editor: Heye Zhang.

We declare there is no conflict of interest.

<sup>a</sup> Department of Orthopaedics, Graduate School of Medical Science, Kyoto Prefectural University of Medicine, <sup>b</sup> Department of Orthopaedics, Kyoto Interdisciplinary Institute Hospital of Community Medicine, <sup>c</sup> Department of Sports and Para-Sports Medicine, Graduate School of Medical Science, Kyoto Prefectural University of Medicine, <sup>d</sup> Kobayashi Orthopaedic Clinic, <sup>e</sup> Department of Biostatistics, Graduate School of Medical Science, Kyoto Prefectural University of Medicine, Kyoto, Japan.

\* Correspondence: Yuji Arai, Department of Sports and Para-Sports Medicine, Graduate School of Medical Science, Kyoto Prefectural University of Medicine, 465 Kawaramachi-Hirokoji, Kamigyo-ku, Kyoto 602-8566, Japan (e-mail: yarai89046@nike.eonet.ne.jp)

Copyright © 2017 the Author(s). Published by Wolters Kluwer Health, Inc. This is an open access article distributed under the terms of the Creative Commons Attribution-Non Commercial-No Derivatives License 4.0 (CCBY-NC-ND), where it is permissible to download and share the work provided it is properly cited. The work cannot be changed in any way or used commercially without permission from the journal.

Medicine (2017) 96:49(e9126)

Received: 13 June 2017 / Received in final form: 14 October 2017 / Accepted: 15 November 2017

<http://dx.doi.org/10.1097/MD.00000000000009126>

first examination. However, to our knowledge, the time-course of changes in the joint space has not been evaluated using the FFV method. As this method is advantageous, in that the joint space can be evaluated accurately and reproducibly, we hypothesized that using the FFV method, the degree of progression can be accurately evaluated in addition to OA staging during the first examination. This study measured changes in joint space, as determined by standing extended view (SEV) and FFV, over an average of 4 years in knee OA patients.

## 2. Subjects and methods

### 2.1. Subjects

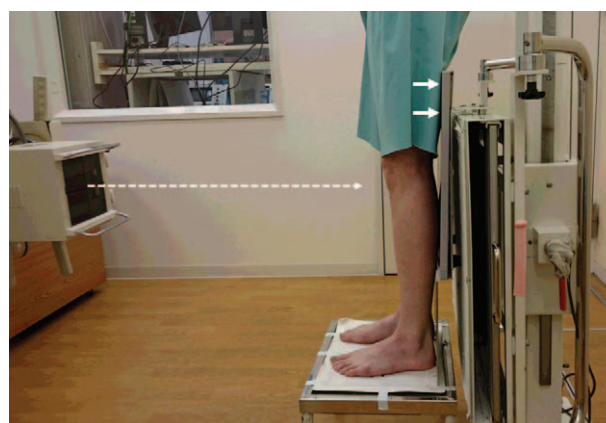
SEV and FFV images were acquired in patients who visited Kobayashi Orthopaedic Clinic in Kyoto, Japan, with a chief complaint of knee joint pain. The inclusion criterion was patients diagnosed with knee OA on plain radiography followed up for  $\geq 24$  months. Patients with rheumatoid arthritis, valgus knee, or those who underwent knee surgery during the observation period were excluded. Of 567 patients (1102 knees) diagnosed with knee OA on plain radiography, including 125 males (243 knees) and 442 females (859 knees), 81 patients (157 knees) were followed up for  $\geq 24$  months. These 81 patients (157 knees), comprising 22 males (42 knees) and 59 females (115 knees), had a mean  $\pm$  SD age of  $65.6 \pm 8.4$  (range: 40–80) years, and a mean follow-up of  $49.5 \pm 15.5$  (range: 24–89) months (Table 1). SEV and FFV images were acquired during the first examination and during follow-up in all patients, with 628 images analyzed retrospectively.

### 2.2. Radiography of the knee joint

To acquire SEV images, the patient stood in front of the film cassette, with the posterior thigh in contact with the cassette. Even if flexion contracture of the knee was present, we did not adjust for it. Irradiation was applied in the horizontal direction (Fig. 1). FFV images were acquired as described.<sup>[5,6]</sup> Briefly, the patient stood with a  $10^\circ$  external rotation of the feet, with the anterior thigh in close contact with the cassette and the tips of the toes on the same plane as that of the cassette. A posteroanterior image was acquired at an irradiation angle of  $10^\circ$  tilt in the caudal direction (Fig. 2). The acquisition conditions of SEV and FFV were the same: X-ray tube voltage, 55 kv; X-ray tube current, 100 mA; time, 0.071 seconds; SID, 100 cm; and grid (-).

### 2.3. Analysis

The medial joint space width (MJSW) was defined the distance between the apex of the medial condyle of the femur and the tibial



**Figure 1.** The patient stood in front of the film cassette, with the posterior thigh in contact with the cassette. Irradiation was applied in the horizontal direction.

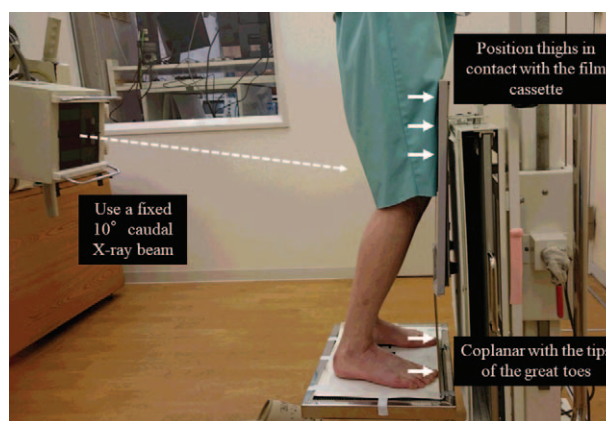
posterior end (Fig. 3).<sup>[6]</sup> The disease stage of knee OA was evaluated using K-L classification.<sup>[7]</sup> Knees were classified into KL grade I-IV, based on KL grade on each of SEV and FFV at baseline. Images were analyzed using ApolloView Lite ver. 1.3.8.2 (Medison Acoma Nishinohon Corporation, Fukuoka, Japan). Reductions in MJSW on SEV ( $\Delta$ SEV) and FFV ( $\Delta$ FFV) were measured and compared among the 4 KL groups.

All plain radiographs were acquired by a single radiographer. Each MJSW was measured independently by 2 orthopedic surgeons, specializing in knee surgery with 10 and 14 years of experience, blinded for the follow-up date. Each measurement was performed twice at an interval of 1 week, with the average value regarded as the result. KL grades were determined by X-ray image. Disagreements between the 2 observers were resolved by consensus between them.

This study was approved by the Institutional Review Board of the Kyoto Interdisciplinary Institute of Community Medicine. All subjects provided written informed consent.

### 2.4. Statistical analysis

Measurements are expressed as mean  $\pm$  SD. Outcomes in the SEV and FFV were compared using paired *t* tests. Two-way analysis of

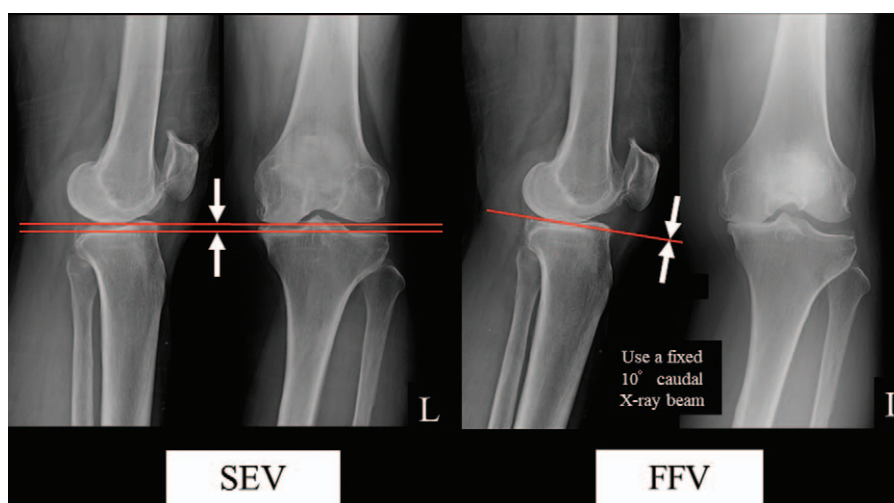


**Figure 2.** The patient stood with a  $10^\circ$  external rotation of the feet, with the anterior thigh in close contact with the cassette and the tips of the toes on the same plane as that of the cassette. A posteroanterior image was acquired at an irradiation angle of  $10^\circ$  tilt in the caudal direction.

**Table 1**

**Summary of the subjects.**

Inclusion criteria	Knee OA on plain radiography Followed up for $\geq 24$ mo
Exclusion criteria	Rheumatoid arthritis Valgus knee Past history of knee surgery
Age	$65.6 \pm 8.4$ (range: 40–80) y
Gender	22 males (42 knees), 59 females (115 knees)
Follow-up period	$49.5 \pm 15.5$ (range: 24–89) mo



**Figure 3.** The medial joint space width (MJSW) was defined the distance between the apex of the medial condyle of the femur and the tibial posterior end.

variance (ANOVA) was used to analyze the mean MJSW, with group (KL grade I~IV) and period (first and follow-up examinations) as between-subject factors; Tukey post hoc test was performed for multiple comparisons. Intraclass correlation coefficients (ICCs) were calculated with a 2-way random model. All statistical analyses were performed using SPSS (version 21.0 for Windows; IBM, Chicago, IL), with  $P < .05$  defined as statistically significant. In a pilot study of 10 patients,  $\Delta$ SEV and  $\Delta$ FFV were measured and the mean and SD were calculated. The mean  $\Delta$ SEV and  $\Delta$ FFV were  $0.82 \pm 1.60$  and  $1.53 \pm 1.33$  mm, respectively. A power analysis was performed using EZR (Saitama Medical Center, Jichi Medical University), which is a graphical user interface for R (The R Foundation for Statistical Computing, version 2.13.0). For a power of 0.8 and an alpha value of 0.05, the required sample size was 67 patients. To take into account any correlations among knee data within subjects, a mixed model was used to compare  $\Delta$ SEV and  $\Delta$ FFV among KL grades I~IV, which were determined by SEV and FFV measured at baseline, respectively. We treated subjects as a random variable and tested KL grades contrasts using Tukey test for multiple comparisons. In addition, we reanalyzed the data after adjusting for age and sex.

### 3. Results

The mean  $\pm$ SD MJSW at the first examination and follow-up were  $4.52 \pm 1.15$  and  $4.29 \pm 1.27$  mm, respectively, by SEV, and  $3.11 \pm 1.46$  and  $2.16 \pm 1.46$  mm, respectively, by FFV. At both

time-points, MJSW was lower when determined by FFV than by SEV group for all patients ( $P < .001$ ). Mean MJSW by both SEV and FFV was also significantly lower at follow-up than at first examination ( $P < .001$  each). SEV at first examination classified 68 knees as KL grade I, 61 as KL grade II, 25 as KL grade III, and 3 as KL grade IV. At follow-up, SEV classified 53 knees as KL grade I, 70 as KL grade II, 30 as KL grade III, and 4 as KL grade IV (Table 2). FFV at first examination classified 37 knees as KL grade I, 44 as KL grade II, 46 as KL grade III, and 30 as KL grade IV; at follow-up, FFV classified 10 knees as KL grade I, 40 as KL grade II, 57 as KL grade III, and 50 as KL grade IV (Table 3). At both time-points, the KL grade was higher when evaluated by FFV than by SEV, and many knees evaluated as KL grades I and II by SEV had higher grades when evaluated by FFV (Tables 4 and 5). MJSW was significantly smaller at follow-up than at first

**Table 3**

**Relationships between FFV determinations of KL grade at initial examination and at follow-up.**

FFV	KL grade at follow-up				Total
	I	II	III	IV	
KL grade during the first examination					
I	10	22	3	2	37
II	0	18	22	4	44
III	0	0	32	14	46
IV	0	0	0	30	30
Total	10	40	57	50	157

FFV = fixed flexion view, KL = Kellgren–Lawrence.

**Table 2**

**Relationships between SEV determinations of KL grade at initial examination and at follow-up.**

SEV	KL grade at follow-up				Total
	I	II	III	IV	
KL grade during the first examination					
I	53	15	0	0	68
II	0	52	9	0	61
III	0	3	21	1	25
IV	0	0	0	3	3
Total	53	70	30	4	157

KL = Kellgren–Lawrence, SEV = standing extended view.

**Table 4**

**Relationships between SEV and FFV determinations of KL grade at initial examination.**

First examination	FFV KL grade				Total
	I	II	III	IV	
SEV KL grade					
I	37	19	10	2	68
II	0	25	27	9	61
III	0	0	9	16	25
IV	0	0	0	3	3
Total	37	44	46	30	157

FFV = fixed flexion view, KL = Kellgren–Lawrence, SEV = standing extended view.

**Table 5**  
Relationships between SEV and FFV determinations of KL grade at follow-up.

Follow-up	FFV KL grade				Total
	I	II	III	IV	
SEV KL grade					
I	10	26	15	2	53
II	0	14	36	19	69
III	0	0	7	24	31
IV	0	0	0	4	4
Total	10	40	58	49	157

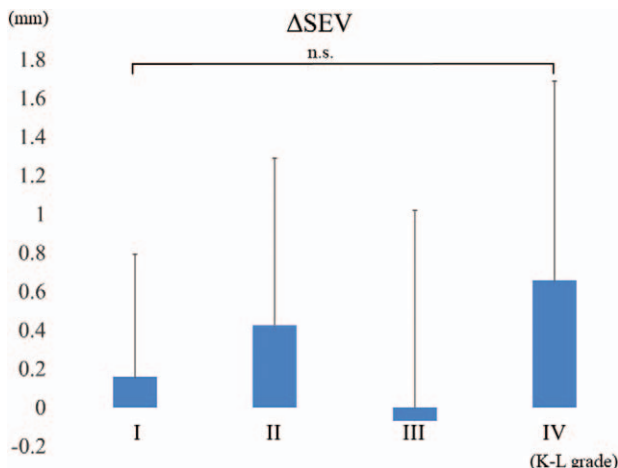
FFV = fixed flexion view, KL = Kellgren–Lawrence, SEV = standing extended view.

examination in all KL grade groups, as determined by both SEV and FFV ( $P < .001$ ).  $\Delta$ FFV was significantly greater the  $\Delta$ SEV ( $P < .001$ ).  $\Delta$ SEV did not differ significantly among the KL grade groups ( $p > 0.05$ , Fig. 4), but  $\Delta$ FFV was significantly greater in patients with KL grade II than in patients with other KL grades ( $P < .05$ , Fig. 5). Estimated values and confidence intervals remained almost unchanged, and significant differences were still found after adjustment for age and sex.

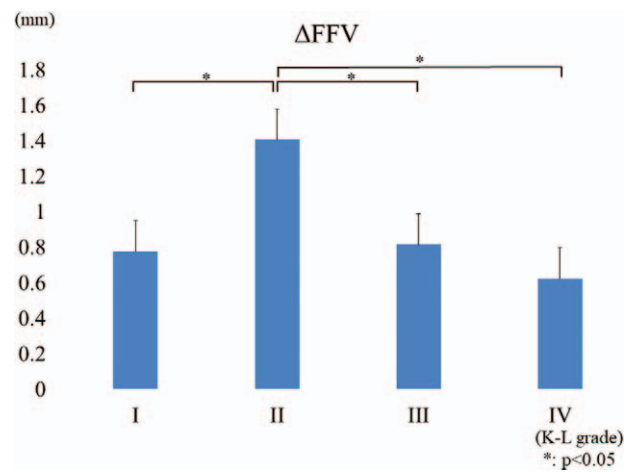
The interobserver reliability of the 2 orthopedists for measurement of MJSW was 0.887. The intraobserver reliabilities of Observers 1 and 2 were 0.873 and 0.993, respectively.

#### 4. Discussion

The most important findings of this study were that FFV is not only useful when evaluating the joint space in patients with knee OA but also for accurately evaluating OA progression. Joint cartilage wear on the femoral side has been reported to start from a 20° to 60° flexion position against the intramedullary axis of the femur.<sup>[12]</sup> A pathological study showed that cartilage destruction in knee OA begins from the posterior condyles of the femur and tibia.<sup>[8]</sup> Furthermore, a biomechanical study reported that maximum contact stress in the femorotibial joint is generated at 28° knee joint flexion.<sup>[9]</sup> Furthermore, flexion is considered more useful than extension for evaluating joint space by plain radiography because the meniscus and tibial posterior tilt can alter the evaluation.<sup>[1–6,10–12]</sup> Conventionally, images are acquired in a standing position, with the knee flexion angle set at 20° to 45° using a goniometer, but retention of posture may be

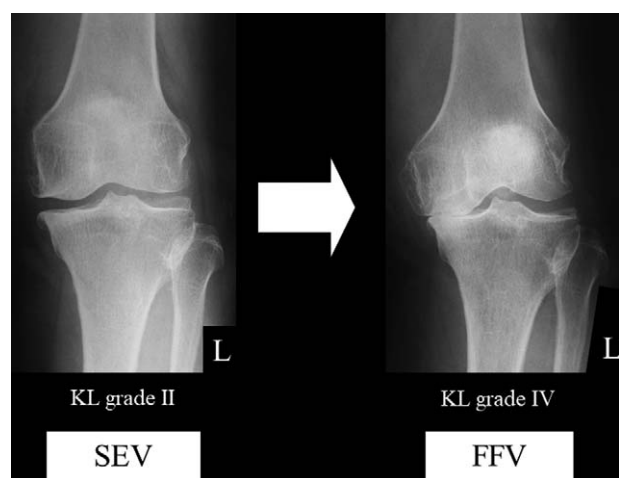


**Figure 4.**  $\Delta$ SEV did not differ significantly among the KL grade groups.



**Figure 5.**  $\Delta$ FFV was significantly greater in patients with KL grade II than in patients with other KL grades.

difficult for elderly individuals and patients with marked arthralgia.<sup>[1,2,10,11,13]</sup> Alternatively, in the FFV method, the anterior thigh is placed in close contact with the cassette and the tips of the toes are placed on the same plane as that of the cassette during acquisition.<sup>[5,6]</sup> Although variability of knee flexion angle might affect the evaluation, this makes retention of the limb position easier and enables stable acquisition, as well as reducing errors in the knee flexion angle and distance from the cassette.<sup>[14]</sup> The Lyon Schuss view (LSV), which uses the same posture as FFV to acquire images, is also considered useful for joint space evaluation, as well as being more reproducible than SEV.<sup>[3,15]</sup> In FFV, the irradiation angle is fixed at 10° in the caudal direction, based on fluoroscopic results. In contrast, LSV requires fluoroscopic adjustment of the irradiation angle to the medial plateau of the tibia. LSV is more accurate for measuring actual joint space width than FFV,<sup>[16]</sup> but it increases the exposure dose and makes the procedure more complex and time-consuming. An extensive literature search found no report of anatomical features of Japanese knees. But Yue et al<sup>[17]</sup> reported the anatomical features of Chinese knees that we presume to be of the same Asian type. They reported that there was no difference in medial/lateral posterior slope between Chinese and white subjects in either sex. Thus, we acquired radiograms by FFV and SEV in knee OA patients at the first examination and after at least a 24-month follow-up, and investigated whether FFV was useful in evaluating the severity and progression of knee OA. Both at first examination and follow-up, MJSW was smaller in all patients when measured by FFV than by SEV. Furthermore, KL grade was the same or higher on FFV than on SEV. FFV is more useful than SEV in evaluating the severity of knee OA in routine medical practice, even in Japanese patients, despite distinct differences in the physique of Japanese and western patients.<sup>[4]</sup> Using SEV alone was found insufficient for evaluating the severity of early-stage knee OA.<sup>[12]</sup> In the present study, 43 (81.1%) of the 53 knees evaluated as KL grade I on follow-up SEV were evaluated as grades II, III, and IV on FFV, and 55 (79.7%) of 69 knees evaluated as grade II on SEV were evaluated as grades III and IV on FFV. These findings indicated a lack of agreement between SEV and FFV in evaluating the severity of early-stage knee OA and suggested that SEV may underestimate the severity of knee OA, especially in its early stage (Fig. 6). Furthermore, MJSW was lower at follow-up than at baseline in all patients when evaluated



**Figure 6.** The MJSW values were smaller in the FFV than SEV group for all patients.

by FFV, whereas MJSW was higher in some patients at follow-up than at baseline when evaluated by SEV. Measurement of MJSW is inaccurate using SEV because of the influence of intra-articular structures, including the joint cartilage and meniscus and the backward slope of the tibial joint surface. Deterioration in the extension limit of the knee changes the distance between the cassette and the knee, affecting the available image from radiography.

In knee OA, joint cartilage wear progresses with time.<sup>[18]</sup> Cartilage thickness is one important measure in describing both OA development and progression.<sup>[19]</sup> Assessments by SEV showed no significant change in MJSW over 1 year, whereas LSV showed significant narrowing over time.<sup>[15]</sup> In our study, MJSW was significantly narrower at follow-up than at baseline when assessed by both SEV and FFV, with  $\Delta$ FFV being significantly greater than  $\Delta$ SEV. These findings indicated that joint cartilage wear progressed over the 4-year time period, with FFV being superior to SEV in evaluating changes over time in the joint space. Determination of an appropriate treatment strategy requires an accurate evaluation of the severity and grade of progression of knee OA, in addition to assessing clinical symptoms.<sup>[20]</sup> OA symptoms, namely physical function impairment and pain, increases significantly as mJSW decreases below about 3.5 mm. Loss of MJSW may require high tibial osteotomy (HTO),<sup>[21–23]</sup> unicompartmental knee arthroplasty (UKA), or total knee arthroplasty (TKA).<sup>[24]</sup> However, when residual MJSW is present, the knee can be treated with joint-conserving surgery including osteotomy. In choosing conservative treatment of knees with a relatively large amount remaining joint cartilage at the initial examination, it is important to acquire plain radiographs over time to determine the progression of joint cartilage wear over time, allowing the selection of a less-invasive surgical procedure at an appropriate time when the disease impairs activity of daily life. We compared the progression of joint space narrowing among the KL grades.  $\Delta$ SEV did not differ significantly among the 4 groups, whereas  $\Delta$ FFV was significantly greater in patients with KL grade II than in the other groups. The clinical relevance of these findings is that they reveal FFV is more useful in evaluating joint space narrowing than SEV, and that the risk of progression of narrowing is high in patients diagnosed as KL grade II based on FFV. The results of the present study suggest that FFV images be acquired routinely in patients who visit the hospital with a chief complaint of knee joint pain.

## 5. Limitations

There are several limitations of this study. First, knee extension and flexion views show different parts of the knee joint cartilage status. Joint cartilage wear on the femoral side has been reported to start from a 20° to 60° flexion position against the bone axis. We are able to evaluate the site where cartilage is more reduced in FFV than in SEV. But these radiographic views cannot reflect any superiority of either method in expressing the OA grade. Long-term radiographic follow-up is needed to determine any superiority of either method in expressing the OA grade. Second, strictly speaking, analyzing the joint space in mm was not possible, as the radiographs were not calibrated. In the case with flexion contracture, the magnification percentage of the radiograph may be larger than that in the case without flexion contracture. But FFV is useful for evaluating joint space in OA knees in daily medical practice.

## 6. Conclusion

Compared with the first examination, MJSW narrowed significantly at the follow-up for all groups, as determined by both SEV and FFV.  $\Delta$ FFV was significantly greater in patients with KL grade II than the other grades. FFV is not only useful when evaluating the joint space in patients with knee OA but also for accurately evaluating OA progression. The risk of rapid progression of knee OA may be high in patients evaluated as KL grade II on FFV. FFV may be superior to SEV in choosing an appropriate treatment strategy for knees with OA.

## References

- [1] Deep K, Norris M, Smart C, et al. Radiographic measurement of joint space height in non-osteoarthritic tibiofemoral joints. A comparison of weight-bearing extension and 30 degrees flexion views. *J Bone Joint Surg Br* 2003;85:980–2.
- [2] Rosenberg TD, Paulos LE, Parker RD, et al. The forty-five-degree posteroanterior flexion weight-bearing radiograph of the knee. *J Bone Joint Surg Am* 1988;70:1479–83.
- [3] Vignon E, Piperno M, Le Graverand MP, et al. Measurement of radiographic joint space width in the tibiofemoral compartment of the osteoarthritic knee: comparison of standing anteroposterior and Lyon schuss views. *Arthritis Rheum* 2003;48:378–84.
- [4] Niinimäki T, Ojala R, Niinimäki J, et al. The standing fixed flexion view detects narrowing of the joint space better than the standing extended view in patients with moderate osteoarthritis of the knee. *Acta Orthop* 2010;81:344–6.
- [5] Peterfy C, Li J, Zaim S, et al. Comparison of fixed-flexion positioning with fluoroscopic semi-flexed positioning for quantifying radiographic joint-space width in the knee: test-retest reproducibility. *Skeletal Radiol* 2003;32:128–32.
- [6] Kan H, Arai Y, Kobayashi M, et al. Radiographic measurement of joint space width using the fixed flexion view in 1,102 knees of Japanese patients with osteoarthritis in comparison with the standing extended view. *Knee Surg Relat Res* 2017;29:63–8.
- [7] Kellgren JH, Lawrence JS. Radiological assessment of osteoarthritis. *Ann Rheum Dis* 1957;16:494–502.
- [8] Messieh SS, Fowler PJ, Munro T. Anteroposterior radiographs of the osteoarthritic knee. *J Bone Joint Surg Br* 1990;72:639–40.
- [9] Macquet PJG. Biomechanics of the Knee with Application to the Pathogenesis and the Surgical Treatment of Osteoarthritis. 1977; Springer-Verlag, Berlin:1-237.
- [10] Davies AP, Calder DA, Marshall T, et al. Plain radiography in the degenerate knee. A case for change. *J Bone Joint Surg Br* 1999; 81:632–5.
- [11] Inoue S, Nagamine R, Miura H, et al. Anteroposterior weight-bearing radiography of the knee with both knee in semiflexion, using new equipment. *J Orthop Sci* 2001;6:475–80.
- [12] Merle-Vincent F, Vignon E, Brandt K, et al. Superiority of the Lyon schuss view over the standing anteroposterior view for detecting joint

- space narrowing, especially in the lateral tibiofemoral compartment, in early knee osteoarthritis. *Ann Rheum Dis* 2007;66:747–53.
- [13] Duddy J, Kirwan JR, Szébenyi B, et al. A comparison of the semiflexed (MTP) view with the standing extended view (SEV) in the radiographic assessment of knee osteoarthritis in a busy routine X-ray department. *Rheumatology* 2005;44:349–51.
- [14] Nevitt MC, Peterfy C, Guermazi A, et al. Longitudinal performance evaluation and validation of fixed-flexion radiography of the knee for detection of joint space loss. *Arthritis Rheum* 2007;56:1512–20.
- [15] Piperno M, Hellio Le Graverand MP, Conrozier T, et al. Quantitative evaluation of joint space width in femorotibial osteoarthritis: comparison of three radiographic views. *Osteoarthritis Cartilage* 1998;6:252–9.
- [16] Mazzuca SA, Hellio Le Graverand MP, Vignon E, et al. Performance of a non-fluoroscopically assisted substitute for the Lyon schuss knee radiograph: quality and reproducibility of positioning and sensitivity to joint space narrowing in osteoarthritic knees. *Osteoarthritis Cartilage* 2008;16:1555–9.
- [17] Yue B, Varadarajan KM, Ai S, et al. Differences of knee anthropometry between Chinese and white men and women. *J Arthroplasty* 2011; 26:124–30.
- [18] Nishimura A, Hasegawa M, Kato K, et al. Risk factors for the incidence and progression of radiographic osteoarthritis of the knee among Japanese. *Int Orthop* 2011;35:839–43.
- [19] Schmitz RJ, Wang HM, Polprasert DR, et al. Evaluation of knee cartilage thickness: a comparison between ultrasound and magnetic resonance imaging methods. *Knee* 2017;24:217–23.
- [20] Komatsu D, Hasegawa Y, Kojima T, et al. Absence of a relationship between joint space narrowing and osteophyte formation in early knee osteoarthritis among Japanese community-dwelling elderly individuals: a cross-sectional study. *Mod Rheumatol* 2017;27:675–82.
- [21] Lee DC, Byun SJ. High tibial osteotomy. *Knee Surg Relat Res* 2012;24:61–9.
- [22] Kim HJ, Yoon JR, Choi GW, et al. Imageless navigation versus conventional open wedge high tibial osteotomy: a meta-analysis of comparative studies. *Knee Surg Relat Res* 2016;28:16–26.
- [23] Akizuki S, Shibakawa A, Takizawa T, et al. The long-term outcome of high tibial osteotomy: a ten- to 20-year follow-up. *J Bone Joint Surg Br* 2008;90:592–6.
- [24] Pandit H, Jenkins C, Barker K, et al. The Oxford medial unicompartmental knee replacement using a minimally-invasive approach. *J Bone Joint Surg Br* 2006;88:54–60.