

# The efficacy of 5% dapsone gel plus oral isotretinoin versus oral isotretinoin alone in acne vulgaris: A randomized double-blind study

Gita Faghihi, Mehrdad Rakhshanpour, Bahareh Abtahi-Naeini, Mohammad Ali Nilforoushzadeh<sup>1</sup>

Departments of Dermatology, Skin Diseases and Leishmaniasis Research Center, School of Medicine, Isfahan University of Medical Sciences, Isfahan, <sup>1</sup>Departments of Dermatology, Skin and Stem Cell Research Center, Tehran University of Medical Sciences, Tehran, Iran

## Abstract

**Background:** Acne vulgaris, a common human skin condition, is an inflammatory disease characterized by comedones, papules, nodules and possibly scarring.

This study aimed to evaluate the efficacy of a combination of 5% dapsone gel plus oral isotretinoin in the treatment of acne vulgaris.

**Materials and Methods:** A randomized, placebo-controlled, study was carried out on patients with moderate to severe acne. The patients were randomly divided in two groups: (dapsone gel and vehicle gel). All Patients were administered oral isotretinoin 20 mg daily and topical gel twice a day for 8 weeks. The Global Acne Assessment Score (GAAS), the number lesions and side-effects were documented at base line and weeks 4, 8 and 12.

**Results:** A total of 58 patients (age range: 18-25 years) were included in our study. The number of lesions was significantly lower in the dapsone-treated group at all follow-up visits ( $P < 0.001$ ). The mean GAAS score in the dapsone-treated group and in the Placebo-treated group decreased, but there was no statistical difference in two groups ( $P < 0.001$ ). The side-effects on the dapsone-treated group were a mild burning sensation in 7 patients (24.13%), mild erythema of the skin and mild dryness in 4 (13.79%) and 3 (10.34%) cases respectively ( $P < 0.001$ ). In our study, adverse effects were common but they were minor and tolerable. No clinically significant changes in laboratory parameters were observed ( $P < 0.001$ ).

**Conclusions:** Dapsone gel was an effective medication for patients who received isotretinoin for acne vulgaris treatment resulting in a significant reduction of the number of lesions.

**Key Words:** Acne vulgaris, isotretinoin, 5% dapsone gel

### Address for correspondence:

Dr. Mehrdad Rakhshanpour, Department of Dermatology, Al-Zahra General Hospital, Sofeh Road, Isfahan University of Medical Sciences, Isfahan, Iran.

E-mail: m\_rakhshan\_md@yahoo.com

Received: 06.11.2013, Accepted: 29.12.2013

Access this article online	
Quick Response Code:	Website: www.advbiores.net
	DOI: 10.4103/2277-9175.139413

## INTRODUCTION

Acne vulgaris is a common dermatologic disease that is usually managed by application of topical preparations, systemic medications, or a combination of the two.<sup>[1,2]</sup> Acne is primarily an inflammatory disease, challenging the current nomenclature of non-inflammatory versus inflammatory acne lesions, suggesting that the

Copyright: © 2014 Faghihi. This is an open-access article distributed under the terms of the Creative Commons Attribution License, which permits unrestricted use, distribution, and reproduction in any medium, provided the original author and source are credited.

**How to cite this article:** Faghihi G, Rakhshanpour M, Abtahi-Naeini B, Nilforoushzadeh MA. The efficacy of 5% dapsone gel plus oral isotretinoin versus oral isotretinoin alone in acne vulgaris: A randomized double-blind study. Adv Biomed Res 2014;3:177.

nomenclature is outdated and incorrect.<sup>[3]</sup> The evidence in support of acne as an inflammatory disease also has clinical implications, in that anti-inflammatory drugs used to treat the disease can be expected to exert effects against all lesion stages, albeit via distinct mechanisms of anti-inflammation.<sup>[3]</sup> Today, different topical therapies are available for patients with acne vulgaris, including comedolytic agents, anti-inflammatory medications, antibiotics, systemic retinoid and even herbal preparations. Antibiotics play a pivotal role in treatment.<sup>[4]</sup> Dapsone (4, 4'-diaminodiphenylsulfone) is a drug of the sulfone class and was discovered in 1908.<sup>[5]</sup> Oral dapsone has demonstrated efficacy in acne, but was associated with severe side-effects such as anemia, which was particularly serious in patients with glucose-6-phosphate dehydrogenase (G6PD) deficiency. Topical dapsone was developed to overcome this limitation.<sup>[6]</sup> A unique property of dapsone is that it has dual therapeutic activity and demonstrates antimicrobial and anti-inflammatory properties.<sup>[7]</sup> Dapsone 5% gel (Aczone) was developed to treat acne vulgaris and today has Food and Drug Administration (FDA) approval.<sup>[8]</sup> There are a very limited number of studies on the topical use of anti-inflammatory agent in combination with other systemic medications such as isotretinoin in acne vulgaris. Due to a delay in starting of isotretinoin response, it will be helpful to add a topical anti-inflammatory agent to treatment regime to fasten the onset of clinical response and control initial exacerbation of symptoms. To the best of our knowledge, this is the first time to combine topical dapsone gel as an anti-inflammatory agent with oral isotretinoin in treatment of moderate to severe acne in order to enhance the efficacy. Hence this study aimed to evaluate the efficacy of 5% dapsone gel with systemic isotretinoin in facial acne vulgaris in Iranian patients.

## MATERIALS AND METHODS

This double-blind, placebo-controlled clinical trial was conducted at Al-Zahra General Hospital, a referral clinic of dermatology in Isfahan, Iran. 58 young adults (age range: 18-25 years) with moderate to severe facial acne vulgaris according to the Global Acne Assessment Score (GAAS) were recruited from September 2012 through July 2013. Reasons for exclusion were: Acne being secondary to other problems; pregnancy or intention of pregnancy; breastfeeding; other dermatological diseases of the face; G6PD deficiency; taking any other acne treatment; history of having taken any medication that could interact with dapsone (e.g. Trimetoprim-sulfamethoxazol) or isotretinoin (e.g. tetracyclines, methotrexate and vitamin A supplements) within the previous 3 months; and known hypersensitivity to the study

medication. The patients were divided into groups randomly: (group A: 5% dapsone gel and group B vehicle neutral gel). The study protocol was approved by the Ethics Committee of Isfahan University of Medical Sciences, Isfahan, Iran (NO: 392090). All patients provided written informed consent before participation.

All patients were administered oral isotretinoin (Roaccutane®, F. Hoffmann-La Roche Ltd.), 20 mg once a day for 8 weeks. The 5% dapsone gel was prepared in Isfahan University's Department of Pharmacy. Dapsone gel was prepared from its powder solved in a little ethanol and mixed with lubricant non-comedogenic gel up to 5% concentration. The dapsone gel and vehicle non-comedogenic neutral gel were filled in similar tubes that were marked 'A' or 'B,' indicating the side on which they should be applied. Topical 5% dapsone gel and non-comedogenic vehicle gel was applied on the face twice daily for 8 weeks in our patients (group A: 5% dapsone gel and group B vehicle gel). During the study period, only a caregiver who was not involved in the experiment was aware of the contents of the tubes; the patients and the examiner were blind to the topical compounds. The patients came for follow-up examinations on day 2 and weeks 4, 8 and 12. Photographic imaging was performed using a camera (Canon power shot G12, Cannon components Inc. Japan) in the same physical condition, by one person at base line and on each follow-up visit. The numbers of acne lesions were counted manually by the investigator for both the treatment site and control site at baseline and on each follow-up visit. The counting was assessed by marking each counted lesion with a pen to ensure that each lesion was only registered once. The global severity of acne was assessed by the investigator using the 5-point scale at base line and the end of the study<sup>[9]</sup> [Table 1]. All patients completed the study period. Presence of any possible complications/side effects was assessed and documented on each visit by a skilled dermatologist. CONSORT flow chart of the study was showed in one diagram [Figure 1].

Statistical evaluation was done using SPSS® for Windows version 18.0 (SPSS Inc., II, USA). Data were shown as frequency (percentage) or mean  $\pm$  standard deviation. The repeated-measures analysis (ANOVA) and the Chi-square test were used as the appropriate measures.  $P \leq 0.001$  was considered to be statistically significant.

## RESULTS

Fifty eight patients, 25 males (43.1%) and 33 females (56.9%), range: 18-25 years were enrolled

in this study. The mean duration of acne in the study population was  $3.19 \pm 1.8$  years (range: 2-5 years). The patients were divided into groups randomly: (group A: 5% dapsone gel and group B vehicle neutral gel); there were no significant differences between the two groups ( $P > 0.001$ ). Demographic data and number of inflammatory, non-inflammatory facial lesions and GAAS are summarized in Table 2 and compared between the two groups at baseline [Table 2]. All patients had normal of G6PD level. Finally, the two groups were compared with regard to baseline counts. Decrease in the mean inflammatory and non-inflammatory lesion counts was significantly

more in group A compared to group B on all follow-up visits ( $P < 0.001$ ) [Figures 2], Although reduction in GAAS was not significant on all follow-up visits ( $P = 0.264$ ) [Table 3]. Our result showed that clinical efficacy (i.e. number of lesion) in topical dapsone plus oral isotretinoin group in female patients are significantly superior to the male ones after treatment at the end of the study ( $P < 0.001$ ). The side-effects on the dapsone-treated group were a mild burning sensation in 7 patients (24.13%), mild erythema of the skin and mild dryness in 4 (13.79%) and 3 (10.34%) cases respectively ( $P < 0.001$ ). The side-effects are summarized and compared in the two groups on different occasions are shown in Table 4. One patient

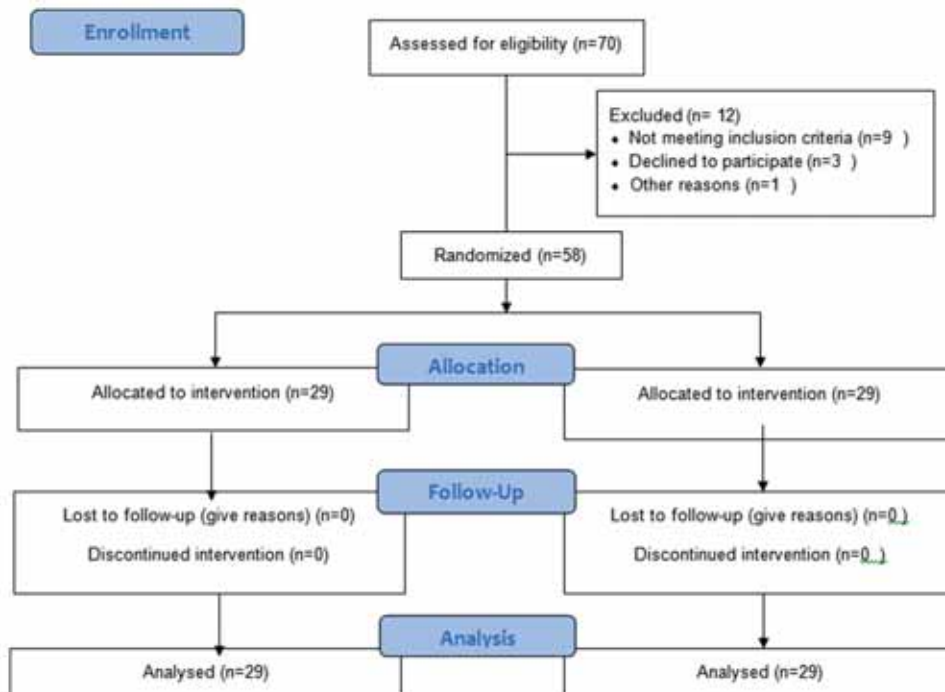
**Table 1: Global acne assessment scale**

Grade	Value	Definition
Clear	0	Normal, clear skin with no evidence of acne vulgaris
Almost clear	1	Rare non-inflammatory lesions present, with rare non-inflamed papules (papules must be resolving and may be hyperpigmented, though not pink-red)
Mild	2	Some non-inflammatory lesions are present, with few inflammatory lesions (papules/pustules only, no nodulocystic lesions)
Moderate	3	Non-inflammatory lesions predominate, with multiple inflammatory lesions evident; several to many comedones and papules/pustules; there may or may not be one small nodulocystic lesion
Severe	4	Inflammatory lesions are more apparent, many comedones and papules/pustules, there may or may not be a few nodulocystic lesions
Very severe	5	Highly inflammatory lesions predominate, variable number of comedones, many papules/pustules and many nodulocystic lesions

**Table 2: Baseline demographics and disease characteristics**

Demographics and disease characteristics data	Dapsone-treated gel (group A) (n=29)	Placebo-treated gel (group B) (n=29)
Age, years		
Mean (SD)	20.3 (3.2)	20.13 (2.9)
Sex, n (%)		
Male	13 (44.82)	12 (41.38)
Female	16 (55.18)	17 (58.62)
GAAS, n (%)		
Mean (SD)	3.6 (0.4)	3.5 (0.4)
Range	3-4	3-4
Lesion count, mean (SD)		
Inflammatory	20.8 (6.8)	21.5 (7.1)
Non-inflammatory	24.8 (8.1)	25.1 (8.7)
Hemoglobin level, mean (SD)	14.1 (1.2)	13.5 (1.1)

SD: Standard deviation, GAAS: Global acne assessment score



**Figure 1: CONSORT flow chart of the study**

developed contact conjunctivitis due to application of dapsone too close to the eye. However, none of these side-effects led to discontinuation of treatment and all the participants completed the study. No clinically significant changes were made in laboratory parameters including hemoglobin ( $P = 0.345$ ).

## DISCUSSION

In the present study, 5% dapsone gel was an effective and safe topical medication for patients that received isotretinoin for acne vulgaris treatment with a significant reduction in the number of lesions but this combination applied to therapy did not alter the final outcome and The GAAS. There are only a limited number of studies that have similarly examined the effect of the combination of isotretinoin and topical application on acne vulgaris and the results are incongruous. Dhir *et al.* found no significant benefit in the combination of topical anti-acne and isotretinoin over isotretinoin alone in improving nodulocystic acne vulgaris.<sup>[4]</sup> However, in our study, the significant efficacy observed in the use of topical 5% dapsone in a similar setting in reducing the count of lesions in weeks 4, 8 and 12, is probably due to the additional anti-inflammatory effect of dapsone. In a study by Tanghetti *et al.* compared the efficacy and tolerability of dapsone 5% gel in female versus male patients with facial acne vulgaris and reported that the response to dapsone 5% gel appears to be influenced by gender, with female patients experiencing a significantly greater reduction in acne lesion counts and a significantly higher clinical success rate following 12 weeks of treatment.<sup>[10]</sup> Our findings are in concordance with the results of Tanghetti's study. The high efficacy of 5% dapsone gel in female patients suggests that gender is an important predictor of the therapeutic outcome in acne treatment and should be considered in acne clinical trial design and analysis. Our findings show significant reduction in both "inflammatory" and "non-inflammatory" (comedonal) lesions in all weeks. Draelos *et al.* documented

efficacy of topical 5% dapsone gel for the reduction of both inflammatory and non-inflammatory acne lesions, so the anti-inflammatory dapsone is effective in treatment of both "inflammatory" and "non-inflammatory" lesions.<sup>[10-12]</sup> Mechanisms other than bactericidal action may underlie the therapeutic effect of dapsone, such as anti-inflammatory and anti-interleukin 8 actions, as well as the inhibition of neutrophil adherence. Dapsone has multiple anti-inflammatory properties.<sup>[13,14]</sup> Although a topical formulation of dapsone (Aczone, Allergan, Inc., Irvine, CA, USA) has been approved by the FDA for the treatment of acne vulgaris but the risks of serious side effects have made it an undesirable drug for use in the relatively healthy acne population.<sup>[8]</sup> In our study, there is no significant difference between before and after hemoglobin level. Draelos *et al.* showed no clinically significant changes in laboratory parameters, including hemoglobin, even among G6PD-deficient patients, as was the case in our study. Other adverse events were comparable between the treatment groups and rarely led to discontinuation of the topical drug.<sup>[11]</sup>

## CONCLUSION

The results suggest that anti-inflammatory agents such as dapsone can effectively reduce the count of lesions but do not alter the final outcome and The GAAS treat when used in combination with systemic isotretinoin.

**Table 3: Mean GAAS: Weeks 4, 8 and 12**

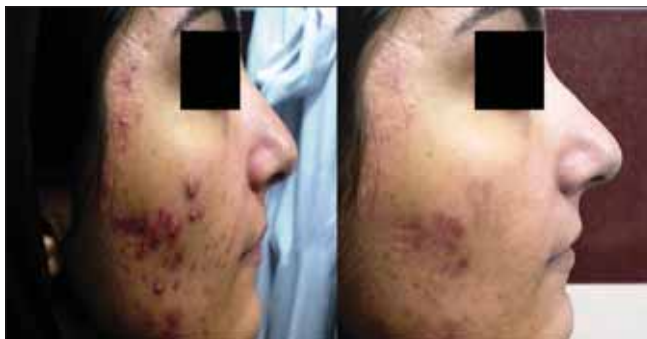Follow-up time	GAAS (SD) (N=29)		P value
	Dapsone-treated gel (group A)	Placebo-treated gel (group B)	
At baseline	3.6 (0.4)	3.5 (0.4)	0.231
At week 4	3.3 (0.3)	3.4 (0.4)	0.256
At week 8	2.9 (0.3)	2.7 (0.3)	0.301
At week 12	2.4 (0.2)	2.6 (0.3)	0.345

SD: Standard deviation, GAAS: Global acne assessment scores.  $P < 0.001$  is statistically significant

**Table 4: AEs occurring during the course of treatment**

Side effects	Subjects with AEs, n (%) (N=29)		P value
	Group A	Group B	
Any AEs	18 (62.0)	3 (10.3)	<0.001
Application site conditions			
Burning sensation	7 (24.1)	2 (6.9)	<0.001
Erythema/or/irritation	4 (13.8)	1 (3.4)	<0.001
Dryness	3 (10.3)	0 (0.0)	<0.001
Exfoliation	1 (3.4)	0 (0.0)	0.019
Pruritus	1 (3.4)	0 (0.0)	0.019
Photosensitivity	1 (3.4)	0 (0.0)	0.019
Other side-effects	1 (3.4)	0 (0.0)	0.019

AEs: Adverse events. ( $P < 0.001$ ) is statistically significant



**Figure 2:** The number of inflammatory and non-inflammatory lesions reduced significantly after 8 weeks of treatment with topical dapsone gel plus isotretinoin as shown in these pictures

The limitations of our study were short duration of treatment and lack of more objective methods for result assessment.

## ACKNOWLEDGMENTS

We are very grateful to Dr. Baghaeizadeh and Dr. Khosravani, for their help in performing this research.

## REFERENCES

1. Hsu P, Litman GI, Brodell RT. Overview of the treatment of acne vulgaris with topical retinoids. *Postgrad Med* 2011;123:153-61.
2. Kraft J, Freiman A. Management of acne. *CMAJ* 2011;183:E430-5.
3. Tanghetti EA. The role of inflammation in the pathology of acne. *J Clin Aesthet Dermatol* 2013;6:27-35.
4. Dhir R, Gehi NP, Agarwal R, More YE. Oral isotretinoin is as effective as a combination of oral isotretinoin and topical anti-acne agents in nodulocystic acne. *Indian J Dermatol Venereol Leprol* 2008;74:187.
5. Sago J, Hall RP. Dapsone. *Dermatol Ther* 2002;15:340-51.
6. Scheinfeld N. Aczone, a topical gel formulation of the antibacterial, anti-inflammatory dapsone for the treatment of acne. *Curr Opin Investig Drugs* 2009;10:474-81.
7. Paniker U, Levine N. Dapsone and sulfapyridine. *Dermatol Clin* 2001;19:79-86, viii.
8. Pickert A, Raimer S. An evaluation of dapsone gel 5% in the treatment of acne vulgaris. *Expert Opin Pharmacother* 2009;10:1515-21.
9. Schlessinger J, Menter A, Gold M, Leonardi C, Eichenfield L, Plott RT, *et al.* Clinical safety and efficacy studies of a novel formulation combining 1.2% clindamycin phosphate and 0.025% tretinoin for the treatment of acne vulgaris. *J Drugs Dermatol* 2007;6:607-15.
10. Tanghetti E, Harper JC, Oefelein MG. The efficacy and tolerability of dapsone 5% gel in female vs male patients with facial acne vulgaris: Gender as a clinically relevant outcome variable. *J Drugs Dermatol* 2012;11:1417-21.
11. Draelos ZD, Carter E, Maloney JM, Elewski B, Poulin Y, Lynde C, *et al.* Two randomized studies demonstrate the efficacy and safety of dapsone gel, 5% for the treatment of acne vulgaris. *J Am Acad Dermatol* 2007;56:439.e1-10.
12. Kircik LH. Harnessing the anti-inflammatory effects of topical dapsone for management of acne. *J Drugs Dermatol* 2010;9:667-71.
13. Booth SA, Moody CE, Dahl MV, Herron MJ, Nelson RD. Dapsone suppresses integrin-mediated neutrophil adherence function. *J Invest Dermatol* 1992;98:135-40.
14. Debol SM, Herron MJ, Nelson RD. Anti-inflammatory action of dapsone: Inhibition of neutrophil adherence is associated with inhibition of chemoattractant-induced signal transduction. *J Leukoc Biol* 1997;62:827-36.

**Source of Support:** Skin Diseases and Leishmaniasis Research Center, Isfahan University of Medical Sciences, Isfahan, Iran. **Conflict of Interest:** None declared.