

# The Use of a Hartmann's Pouch for Bowel Vaginoplasty: A Case Report

Peter William Zak, MD\*

Ian Chow, MD†

Xiao Zhu, MD†

Harry W. Sell Jr, MD\*

Paul J. Rusilko, DO‡

Guy M. Stofman, MD†

**Summary:** Bowel vaginoplasty is a well-described procedure utilizing a pedicled segment of large or small bowel. It has most commonly been used for vaginal agenesis, male-to-female gender affirmation surgery when the phallus skin is not sufficient, or a revision after failure of the primary reconstruction. Our case report describes the usage of a pedicled segment of large bowel to reconstruct the vagina after severe stricture of the original reconstruction. We were able to provide relief of the symptomatic Hartmann's pouch mucocele, urethral stricture, and provide a functional introitus and vaginal canal. This technique can provide a framework that can be used as a salvage plan in patients with previously irritated and inhospitable defects. (*Plast Reconstr Surg Glob Open* 2021;9:e3546; doi: [10.1097/GOX.0000000000003546](https://doi.org/10.1097/GOX.0000000000003546); Published online 23 April 2021.)

The literature on vaginal reconstruction using a pedicled segment of bowel is largely limited to cases of vaginal agenesis requiring creation of a neovagina, male-to-female gender affirmation surgery where inverted phallus skin is not sufficient, or as a revision procedure after failure of the primary reconstruction or complications such as vaginal stenosis in transgender surgery. Bowel vaginoplasty is a well-described procedure utilizing a pedicled segment of either the small or large intestine.<sup>1-7</sup> Acquired vulvar and vaginal defects present a more complicated challenge to the reconstructive surgeon because many of these patients have large wounds and prior radiation, requiring complex reconstructions. We present a novel case report of a patient with a history of previous irradiation, a large vulvar defect, vaginal stenosis, and a Hartmann's mucocele who was successfully managed with a unilateral gracilis flap, thigh advancement flaps, and bowel vaginoplasty using a Hartmann's pouch. Such an approach not only allowed for drainage of a large symptomatic Hartmann's mucocele and a symptomatic urethral stricture, but also provided the patient with a functional introitus and vaginal canal. This report provides the first described use of a Hartmann's pouch for the creation of a neovagina. We believe the usage of such a technique

provides a viable salvage operation in the setting of an irradiated and inhospitable perineal defect.

## CASE REPORT/DESCRIPTION OF TECHNIQUE

A 54-year-old woman with a medical history of diabetes, lupus, and lichen sclerosis of the vulva presented with recurrent vulvar squamous cell carcinoma (Fig. 1). Historically, the patient had undergone a hemivulvectomy and postoperative radiation therapy 2 years before presentation. The local squamous cell cancer recurrence necessitated the performance of a total vulvectomy by gynecologic oncology and fecal diversion with laparoscopic permanent colostomy by general surgery. Plastic surgery was consulted to reconstruct the vulvar defect. A left-sided gracilis flap was elevated and used to reconstruct the vulvectomy defect, which consisted of an exposed urethral orifice, vaginal cuff, and rectum. The left gracilis muscle was harvested and rotated into position around the exposed vaginal cuff based on its dominant proximal blood supply to recreate the muscular sling between the posterior vagina and anterior rectum. A skin graft was placed over the gracilis flap and a prosthetic was placed into the vaginal canal as a bolster for the skin graft and to prevent adhesion formation of the introital. Over the next month, there was progressive contracture of the patient's wound, causing the patient to present to the emergency department with urinary retention from perineal urethral stenosis.

Following cystoscopy, dilation of the patient's urethral opening, and Foley catheter placement, it was noted that she had significant stenosis of the vaginal orifice attributed to radiation-induced fibrosis, prompting the need for surgical revision. Before planned surgical intervention, the

From the \*Department of General Surgery, UPMC Mercy, Pittsburgh, Pa.; †Department of Plastic Surgery, University of Pittsburgh Medical Center, Pittsburgh, Pa.; and ‡Department of Urology, The University of Pittsburgh Medical Center, Pittsburgh, Pa.

Received for publication October 12, 2020; accepted February 27, 2021.

Copyright © 2021 The Authors. Published by Wolters Kluwer Health, Inc. on behalf of The American Society of Plastic Surgeons. This is an open-access article distributed under the terms of the [Creative Commons Attribution-Non Commercial-No Derivatives License 4.0 \(CCBY-NC-ND\)](https://creativecommons.org/licenses/by-nc-nd/4.0/), where it is permissible to download and share the work provided it is properly cited. The work cannot be changed in any way or used commercially without permission from the journal.

DOI: [10.1097/GOX.0000000000003546](https://doi.org/10.1097/GOX.0000000000003546)

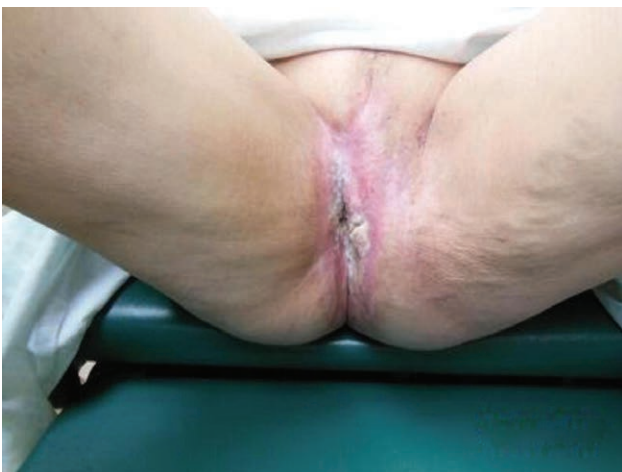**Disclosure:** All the authors have no financial interest in relation to the content of this article.

patient presented to the emergency department with lower abdominal pain, with CT findings indicating a mucocele of the patient's Hartmann's pouch as a result of the anal stenosis—another consequence of the radiation therapy. Physical examination demonstrated no anal opening, and attempted drainage through the rectum in the operating room was not possible. The patient was taken to interventional radiology for CT-guided percutaneous drainage with placement of a pigtail catheter. The placement of the drain significantly improved the patient's pain. Given significant rectovaginal stenosis, we discussed with the patient and the general surgery service attempting to salvage the patient's Hartmann's pouch to create a neovagina. At the time of her definitive reconstruction, the Hartmann's pouch was identified fluoroscopically by injecting contrast dye into the pigtail catheter, and an opening was made into the Hartmann's pouch under fluoroscopic guidance through the previous vaginal canal (Fig. 2). The Hartmann's pouch was then disinserted from the rectum and transposed to recreate a vaginal canal with an approximate length of 12 cm (Fig. 2). Thigh advancement flaps based off the inferior pudendal arteries were used to provide coverage of the reconstructed perineum. The right thigh flap was advanced into the colon edge, and the left thigh flap was inset into the gracilis muscle that was redirected to the colon edge (Fig. 3). This was necessary because we could not advance the left side all the way down to the colon edge due to previous scarring. The urethral stricture was excised by Urology, with reconstruction of the orifice with buccal mucosa.

Although after the operation the patient developed a large granulated area around her introitus that required skin grafting, she has had successful drainage of both urine and mucus from her reconstructed perineum, facilitating the removal of both the Foley and pigtail catheter. She had been able to undergo and tolerate gradual dilation of her vaginal opening (Fig. 4).

### DISCUSSION/LITERATURE REVIEW

Both vaginal and perineal reconstruction are complex and have been well described in the literature. Our aim is



**Fig. 1.** Preoperative photograph showing Lichen Sclerosus.

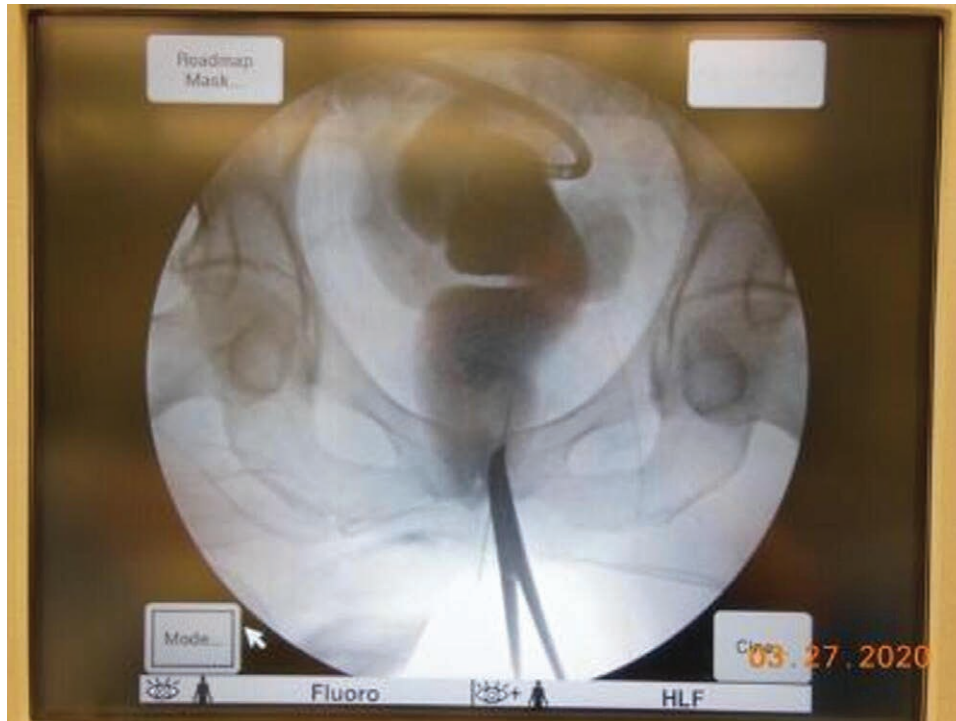to review the common reconstructive techniques for these defects and how our surgical experience in dealing with our patient provides a novel approach for reconstruction.

Perineal reconstruction poses a complex issue for plastic surgeons even to this day. Historically, this problem has undergone a multitude of iterations, starting with simple wound care and delayed primary closure, to multiple different local flaps, to now complex microsurgical techniques using free flaps.<sup>8</sup> Perineal wounds are often complicated by previous radiation, contamination, and moisture. Patient selection is paramount in the decision of what type of perineal reconstructive technique is used.

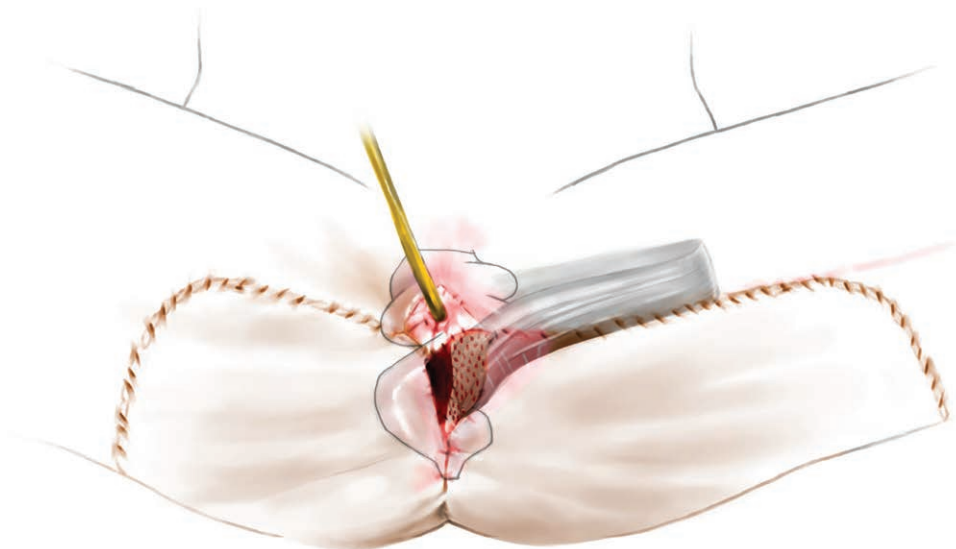
Acquired vaginal defects most commonly result from radical resection of pelvic neoplasms. Regardless of the underlying etiology, the extent of the defect may range from a small mucosal defect to total tissue loss and resection of the vulvar and perineal tissue. Reconstruction of these defects can be difficult, and many different techniques have been described in the literature. The techniques described for total neovaginal reconstruction include a circumferential pedicled rectus flap, bilateral gracilis flaps, Singapore flaps, and bowel vaginoplasty.<sup>1,9,10,14</sup> The main goal for any neovagina reconstruction is to recreate a vaginal canal with adequate length, diameter, axial direction, and normal lubrication that allows for the patient to have penetrative sexual intercourse.<sup>1</sup>

For patients with congenital and non-congenital vaginal atresia or vaginal loss, as well as male-to-female gender affirmation surgery, bowel vaginoplasty provides a viable option. Bowel vaginoplasty was first described in 1892 by Sneguireff (who used rectum) and then again in 1904 with Baldwin, using a segment of ileum.<sup>2,3</sup> These were first described for vaginal agenesis with most cases resulting from Mayer-Rokitansky-Kuster-Hauser syndrome (Müllerian duct failure). The work of Baldwin was abandoned for a long period of time due to the high complication rate; however, in 1955, Zangl and Pratt in 1961, described the use of a pedicled section of the sigmoid colon.<sup>4,5</sup> The use of bowel vaginoplasty has several advantages, including vaginal canal length, diameter, axial direction, natural lubrication, and no need for serial dilation postoperatively. The disadvantages include continued thick mucus production, risk of future colitis, and possible intestinal cancer.<sup>1</sup> Harvesting the pedicled colonic segment was initially done via a laparotomy incision, with its associated risks. With the advancement of laparoscopy, surgical techniques have decreased the need for a laparotomy incision and improved postoperative pain, postoperative ileus, and cosmesis of laparoscopic trocar scars.<sup>9</sup> A recent systematic review of bowel vaginoplasty states that vaginal reconstruction with an isolated bowel segment allows for a self-lubricating neovagina with low complication rates, low risk of reconstructive failure, and no need for routine dilation.<sup>1</sup>

Bowel vaginoplasty has also been described in the transgender literature. The procedure most studied in male-to-female reassignment is the use of inverted phallus skin to create the neovagina.<sup>6,7</sup> In some patients, due to anatomical limitations or to penile-scrotal skin hypoplasia as a result of puberty-suppressing hormonal treatment



**Fig. 2.** Intraoperative fluoroscopic localization.

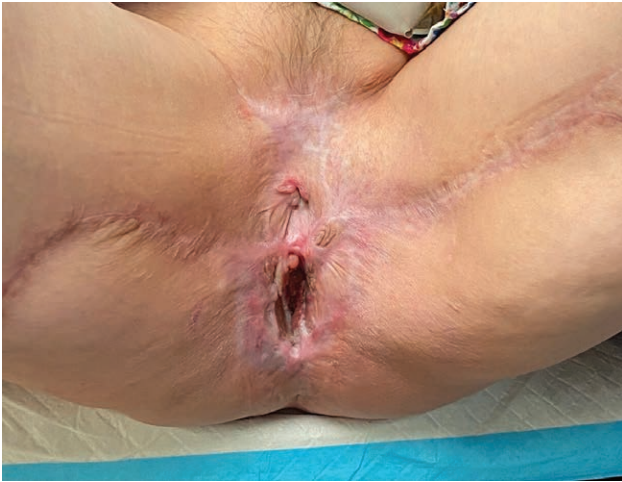

**Fig. 3.** Final reconstruction of the urethral orifice with buccal mucosa and skin grafting over the gracilis muscle flap.

during adolescence, penile skin inversion will not provide sufficient vaginal depth, and bowel vaginoplasty is a valid option. Over the past several years, bowel vaginoplasty in gender affirmation surgery has increased, providing satisfactory results in sexual function and the rate of stenosis.<sup>7</sup> A recent systematic review of surgical techniques for vaginoplasty in male-to-female transgender patients showed that bowel vaginoplasty is not inferior to the more commonly performed penile skin inversion technique.<sup>6</sup>

Singapore flaps have been described as a reliable and safe option for vaginal reconstruction.<sup>10</sup> This technique provides substantial amounts of tissue to aid in the reconstruction of both the vagina and introitus. The main concern here is whether pedicled arteries are taken during the initial resection for cases of neoplasms. The use of a combination of both Singapore flaps and other reconstructive techniques has been shown to provide adequate cosmetic and functional outcomes for neovaginal reconstruction.<sup>10</sup>





**Fig. 4.** Follow-up image showing vaginal orifice after gradual dilation.

The development of a symptomatic intraluminal rectal mucocele has been rarely reported in the literature.<sup>11</sup> A mucocele is an abnormal collection of mucus without adequate drainage in a structure that normally produces mucus. Mucoceles are commonly associated with the gallbladder, appendix, craniofacial sinuses, and other hollow organs that secrete mucous.<sup>12</sup> Most cases of intraluminal mucoceles have been associated with inflammatory bowel disease and subsequent anal stricture formation.<sup>13</sup> However, distal obstruction does not allow for adequate drainage and results in the development of a mucocele, which, with continued growth, can become symptomatic. Without complete removal of the mucous producing tissue, drainage will only temporarily improve symptoms, as seen in our patient after percutaneous drain placement.<sup>13</sup>

Our patient had previous radiation, which is a risk factor for postoperative wound contracture and stricture formation. The development of her rectal mucocele, vaginal stricture, and obliteration of her native vagina facilitated the necessity of a neovagina reconstruction with the use of bowel vaginoplasty. The literature is scant for the use of a Hartmann's pouch for vaginal reconstruction; however, our patient had obliteration of her native vagina, and the development of a rectal mucocele allowed for a novel reconstructive approach using reliable techniques of bowel vaginoplasty with a Hartmann's pouch.<sup>6</sup>

Perineal and vaginal reconstruction are complex problems for plastic surgeons, and a combination of these defects necessitates multiple reconstructive techniques. In our patient, we were able to utilize existing techniques to manage a complex reconstructive and functional problem. We were able to reconstruct her introitus and manage her urethral stricture by creating a canal using a Hartmann's pouch. This technique could benefit patients because there is no need for bowel resection and interposition, thus no requirement for an intra-abdominal operation. Our technique provides a valuable paradigm in the management of these complex defects.

## CONCLUSIONS

This case provides a novel framework to approach a complex reconstructive problem. Our patient with a history of previous irradiation, a large vulvar defect, vaginal stenosis, and a Hartmann's mucocele was successfully managed with unilateral gracilis flaps, thigh advancement flaps, and bowel vaginoplasty using a Hartmann's pouch. Such an approach not only allowed for drainage of a large symptomatic Hartmann's mucocele and a symptomatic urethral stricture, but also provided the patient with a functional introitus and vaginal canal. This technique can provide patients with a functional neovagina using previously described techniques in a novel approach.

Peter William Zak, MD  
UPMC Mercy  
Pittsburgh, PA

## ACKNOWLEDGMENT

Illustrations were done by Xiao Zhu, MD.

## REFERENCES

- Georgas K, Belgrano V, Andreasson M, et al. Bowel vaginoplasty: A systematic review. *J Plast Surg Hand Surg.* 2018;52:265–273.
- Sneguireff WF. Zwei fälle von restitutio vaginae per transplantationen. *Ani Recti Zentralbl Gynakol.* 1904;28:772.
- Baldwin JF. XIV. The formation of an artificial vagina by intestinal transplantation. *Ann Surg.* 1904;40:398–403.
- Zängl A. 52. Konstruktion der vagina durch sigmatransposition. *Langenbecks Archiv für Chirurgie.* 1975;339:413–416.
- Pratt JH. Sigmoidovaginostomy: A new method of obtaining satisfactory vaginal depth. *Am J Obstet Gynecol.* 1961;81:535–545.
- Salgado CJ, Nugent A, Kuhn J, et al. Primary sigmoid vaginoplasty in transwomen: Technique and outcomes. *Biomed Res Int.* 2018;2018:4907208.
- Bouman MB, van der Sluis WB, van Woudenberg Hamstra LE, et al. Patient-reported esthetic and functional outcomes of primary total laparoscopic intestinal vaginoplasty in transgender women with penoscrotal hypoplasia. *J Sex Med.* 2016;13:1438–1444.
- Kroll SS, Pollock R, Jessup JM, et al. Transpelvic rectus abdominis flap reconstruction of defects following abdominal-perineal resection. *Am Surg.* 1989;55:632–637.
- Urbanowicz W, Starzyk J, Sulislawski J. Laparoscopic vaginal reconstruction using a sigmoid colon segment: A preliminary report. *J Urol.* 2004;171(6 Pt 2):2632–2635.
- Pope RJ, Brown RH, Chipungu E, et al. The use of Singapore flaps for vaginal reconstruction in women with vaginal stenosis with obstetric fistula: A surgical technique. *BJOG.* 2018;125:751–756.
- Schneider R, Kraljević M, von Flüe M, et al. Giant symptomatic rectal mucocele following subtotal colectomy. *Case Rep Gastroenterol.* 2018;12:143–146.
- Appleton N, Day N, Walsh C. Rectal mucocele following subtotal colectomy for colitis. *Ann R Coll Surg Engl.* 2014;96:e13–e14.
- Draeger TB, Aslam U, Mokraoui N, et al. Intersphincteric proctectomy for rectal mucocele in a Crohn's patient with anal stenosis. A case report and review of literature. *Int J Surg Case Rep.* 2018;44:148–151.
- Sarin Y, Pathak D, Sengar M. Bowel vaginoplasty in children. *J Indian Assoc Pediatr Surg.* 2006;11:92.