



Case report

Unusual external branch of the superior laryngeal nerve: a case report

Thejodhar Pulakunta^{1*}, Bhagath Kumar Potu², Muddanna S Rao²,
Venkata Ramana Vollala³ and Soubhagya Ranjan Nayak⁴

Addresses: ¹Department of Anatomical Sciences, St. Matthew's University School of Medicine, P.O. Box 30992 SMB KY1-1204, Grand Cayman, Cayman Islands, BWI, ²Department of Anatomy, Kasturba Medical College, Manipal University, Manipal, Karnataka, India, ³Department of Anatomy, Melaka Manipal Medical College (Manipal Campus), Manipal University, Manipal, Karnataka, India and ⁴Department of Anatomy, Kasturba Medical College, Manipal University, Mangalore, Karnataka, India

Email: TP* - thejodhar@gmail.com

* Corresponding author

Received: 8 January 2009 Accepted: 17 February 2009 Published: 11 June 2009

Cases Journal 2009, **2**:7754 doi: 10.4076/1757-1626-2-7754

This article is available from: <http://casesjournal.com/casesjournal/article/view/7754>

© 2009 Pulakunta et al; licensee Cases Network Ltd.

This is an Open Access article distributed under the terms of the Creative Commons Attribution License (<http://creativecommons.org/licenses/by/3.0>), which permits unrestricted use, distribution, and reproduction in any medium, provided the original work is properly cited.

Abstract

Introduction: The knowledge of the branching pattern of external branch of the superior laryngeal nerve and its relationship with the superior thyroid artery is the key point for identifying the external branch of the superior laryngeal nerve during surgeries of the neck.

Case presentation: During routine dissection of the left head and neck region of a 50 years old female cadaver, we observed a variation of the external branch of the superior laryngeal nerve around the superior thyroid artery. The external branch of the superior laryngeal nerve has presented one medial and three lateral branches. The medial branch was running on the surface of the inferior constrictor and pierced it; where as the lateral three branches are located laterally to the superior thyroid artery. The medial two lateral branches were piercing the substance of the thyroid gland, where as the lateral most branch was communicating with the left sympathetic chain.

Conclusion: It is very important that surgeons carefully dissect the region of the superior pole of the thyroid gland to expose the abnormal branching pattern of external branch of the superior laryngeal nerve prior to ligation of individual thyroid vessels.

Introduction

The external branch of the superior laryngeal nerve (EBSLN) arises with an internal branch from the superior laryngeal nerve (SLN), which is a branch of the 10th cranial nerve. The EBSLN first descends posterolaterally to the carotid arteries, crosses them, and finally passes to the larynx close to the superior thyroid artery (STA). It lies

deep to these vessels. The relationship of EBSLN to the STA and the upper pole of the thyroid gland is the key point for identifying the EBSLN during surgeries of the neck. After giving off some twigs to the pharyngeal plexus and the inferior pharyngeal constrictor, the EBSLN terminates mainly within the cricothyroid muscle [1-7]. Injury to the EBSLN results in paralysis of the cricothyroid muscle

and it was first described in 1906 [8]. Since then, several studies have highlighted the variations of the EBSLN in head and neck surgery [9-12,14].

Case presentation

In the present case, we observed a variation in the morphological expression of the EBSLN around the STA. During routine dissection of the left head and neck region in a 50 year old female cadaver of Indian origin at the Department of Anatomy, Kasturba Medical College, we observed a variation of the EBSLN around the STA. The EBSLN has presented one medial and three lateral branches. The medial branch was running on the surface of the inferior constrictor and pierced it; where as the lateral three branches are located laterally to the STA. The medial two lateral branches were piercing the substance of the thyroid gland, where as the lateral most branch was communicating with the left sympathetic chain (Figure 1).

Discussion

Hollinshead has described the SLN as originating from the nodose ganglion, then receiving a branch from the superior cervical sympathetic ganglion before bifurcating into the Internal laryngeal nerve (ILN) and EBSLN, implying a direct connection between the superior cervical sympathetic ganglion and the SLN itself [13]. In this case, however, we have observed communications between the cervical sympathetic chain (CSC) and the EBSLN. The incidence of CSC-ELN communication is not very common [7,14]. Many investigators have described the EBSLN as a linear structure composed of motor fiber components [2,4,6,9,12]. But in our case we found an EBSLN has different branches. These branches innervated not only the cricothyroid muscle, but also the thyroid gland.

It is opined that surgeons carefully dissect the region of the superior pole of the thyroid gland to expose the nerve trunk and its branches prior to ligation of individual thyroid vessels. The identification and exposure of nerve will be challenging when it shows different possible morphologic expressions and patterns like the one described in this case.

Abbreviations

TG, thyroid gland; STA, superior thyroid artery; CCA, common carotid artery; ECA, external carotid artery; ICA, internal carotid artery; IJV, internal jugular vein; SLA, superior laryngeal artery; ILN, internal laryngeal nerve; CSC, cervical part of the sympathetic chain.

Consent

Written informed consent was obtained from the subject's relative for publication of this case report.

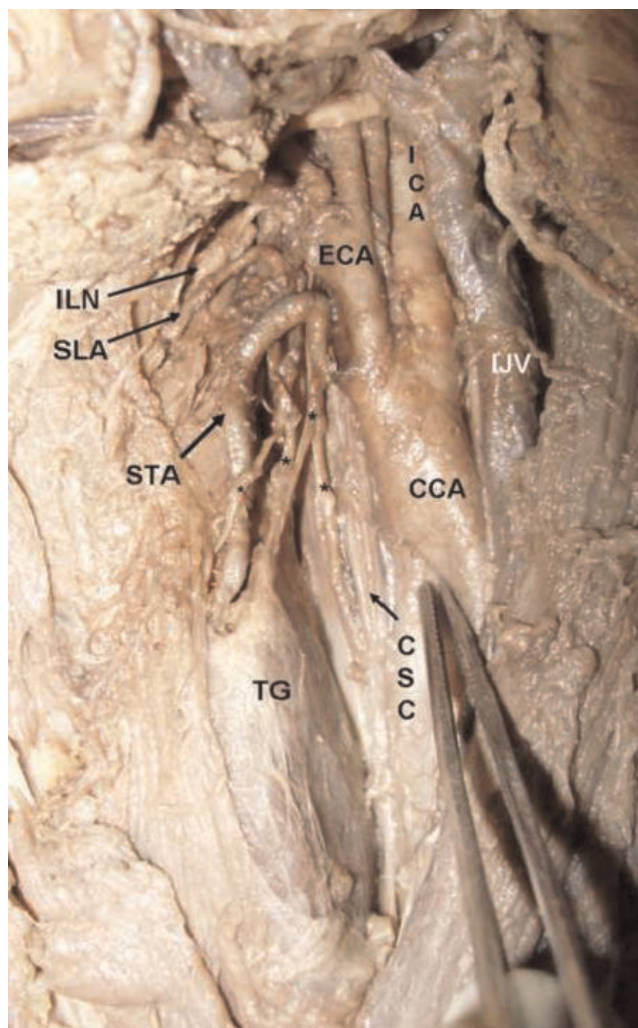


Figure 1. Showing the external branch of the superior laryngeal nerve and its abnormal branches. * showing the different branches of the EBSLN.

Competing interests

The authors declare that they have no competing interests.

Authors' contributions

TP, BKP did the literature search and wrote the case report and also obtained written consent. MSR conceived the study and helped to draft the manuscript. VRV, SRN helped in the literature search. All authors had gone through the final manuscript and approved it.

References

1. Mayet A: **Zur Innervation des M. Cricothyroideus.** *Anat Anz* 1956, **103**:340.
2. Durham CF, Harrison TS: **The surgical anatomy of the superior laryngeal nerve.** *Surg Gynecol Obstet* 1964, **118**:38-44.
3. Lennquist S: **Surgical strategy in thyroid carcinoma.** *Acta Chir Scand* 1986, **152**:321-338.

4. Lang J, Nachbaur S, Fischer K: **Außere Kehlkopfmuskeln: Ursprung, Ansatz, Länge und mögliche Kraftentfaltung.** *Gegenbaurs Morph Jahrb* 1986, **132**:37-56.
5. Lang J, Nachbaur S, Fischer K, Vogel E: **Über den Nervus laryngeus superior und die Arteria laryngea superior.** *Acta Anat* 1987, **130**:309-318.
6. Williams PL, Warwick R, Dyson M, Bannister LH. **Gray's Anatomy.** 37th ed. London, England: Churchill Livingstone; 1989:1117.
7. Sun SQ, Chang R: **The superior laryngeal nerve loop and its surgical implications.** *Surg Radiol Anat* 1991, **13**:175-180.
8. Furlan JC, Cordeiro AC, Brandao LG: **Study of some "intrinsic risk factors" that can enhance an iatrogenic injury of the external branch of the superior laryngeal nerve.** *Otolaryngol Head Neck Surg* 2003a, **128**:396-400.
9. Delbridge L: **Total thyroidectomy: The evolution of surgical technique.** *ANZ J Surg* 2003, **73**:761-768.
10. Delbridge L, Samra J: **Editorial: The 'neglected' nerve in thyroid surgery-The case for routine identification of the external laryngeal nerve.** *ANZ J Surg* 2002, **72**:239.
11. Monfared A, Gorti G, Kim D: **Microsurgical anatomy of the laryngeal nerves as related to thyroid surgery.** *Laryngoscope* 2002, **112**:386-392.
12. Sun SQ, Dong JP: **An applied anatomical study of the superior laryngeal nerve loop.** *Surg Radiol Anat* 1997, **19**:169-173.
13. Hollinshead WH. **The Head and Neck, Anatomy for Surgeons,** 2nd edn. Harper: New York, **1068**:563-576.
14. Kochilas X, Bibas A, Xenellis J, Anagnostopoulou S: **Surgical Anatomy of the External Branch of the superior laryngeal nerve and its clinical significance in head and neck surgery.** *Clin Anat* 2008, **21**:99-105.

Do you have a case to share?

Submit your case report today

- Rapid peer review
- Fast publication
- PubMed indexing
- Inclusion in Cases Database

Any patient, any case, can teach us something



**CASES
NETWORK**

www.casesnetwork.com