

Microsatellite Instability of Gastric and Colorectal Cancers as a Predictor of Synchronous Gastric or Colorectal Neoplasms

Young Beak Kim*, Sun-Young Lee*, Jeong Hwan Kim*, In-Kyung Sung*, Hyung Seok Park*, Chan Sup Shim*, and Hye Seung Han[†]

Departments of *Internal Medicine and [†]Pathology, Konkuk University School of Medicine, Seoul, Korea

Background/Aims: Microsatellite instability (MSI) plays a crucial role in gastrointestinal carcinogenesis. The aim of this study was to clarify whether MSI is a useful marker for predicting synchronous gastric and colorectal neoplasms. **Methods:** Consecutive patients who underwent both esophagogastroduodenoscopy and colonoscopy before the resection of gastric or colorectal cancers were included. MSI was analyzed using two mononucleotide and three dinucleotide markers. **Results:** In total, 434 gastric cancers (372 microsatellite stability [MSS], 21 low incidence of MSI [MSI-L], and 41 high incidence of MSI [MSI-H]) and 162 colorectal cancers (138 MSS, 9 MSI-L, and 15 MSI-H) were included. Patients with MSI gastric cancer had a higher prevalence of synchronous colorectal cancer, colorectal adenoma, and gastric adenoma than those with MSS gastric cancers (4.8% vs 0.5%, $p=0.023$; 11.3% vs 3.2%, $p=0.011$; 3.2% vs 1.2%, $p=0.00$, respectively). The prevalence of synchronous colorectal adenomas was highest in MSI-L gastric cancers (19.0%), compared with MSI-H (7.3%) or MSS (3.2%) gastric cancers ($p=0.002$). In addition, there were no significant differences in the prevalence rates of synchronous colorectal adenoma among the MSI-H (13.3%), MSI-L (11.1%), and MSS (12.3%) colorectal cancers ($p=0.987$). **Conclusions:** The presence of MSI in gastric cancer may be a predictor of synchronous gastric and colorectal neoplasms, whereas MSI in colorectal cancer is not a predictor of synchronous colorectal adenoma. (*Gut Liver* 2016;10:220-227)

Key Words: Microsatellite instability; Stomach neoplasms; Colorectal neoplasms; Adenoma

INTRODUCTION

Microsatellite instability (MSI), which is caused by the loss of DNA mismatch repair (MMR) activity, has a role in gastrointestinal (GI) carcinogenesis.¹ MSI is associated mainly with the contraction or expansion of microsatellite sequences due to the frequent replication errors caused by MMR mutations and tumor suppressor genes.² MSI is implicated in 8% to 39% of all gastric cancers, and in 15% of colorectal cancers.^{3,4}

Gastric cancers with MSI tend to be associated with old age, an antral location, Lauren's intestinal-type, and a high standard uptake value on 18fluoro-deoxyglucose positron emission tomography imaging.⁵⁻⁹ On the other hand, colorectal cancers with MSI tend to be associated with female gender, a proximal location, a mucinous phenotype, and an ulcerated appearance.^{3,10-12} Both gastric and colorectal cancers with MSI are related to large-sized tumors, poor response to 5-fluorouracil chemotherapy, less metastasis, good prognosis, and increased metachronous neoplasms.¹³⁻¹⁷ Synchronous colorectal neoplasm has recently been reported in gastric cancer patients.^{18,19} It was recommended that preoperative colonoscopy should be conducted to screen for colorectal neoplasm in gastric cancer patients over 50 years of age,¹⁸ whereas another study found that a family history of gastric cancer is a risk factor for the development of colorectal neoplasm in those younger than 50 years.¹⁹ Therefore, the predictors of synchronous GI neoplasm in gastric or colorectal cancer patients remain a matter of debate.

The aim of this study was to clarify whether MSI is a useful marker for predicting synchronous gastric and colorectal neoplasms. In addition, the prevalence of synchronous gastric or colorectal neoplasm in gastric and colorectal cancer patients with MSI was analyzed.

Correspondence to: Sun-Young Lee

Department of Internal Medicine, Konkuk University School of Medicine, 120 Neungdong-ro, Gwangjin-gu, Seoul 143-729, Korea

Tel: +82-2-2030-7747, Fax: +82-2-2030-7748, E-mail: sunyoung@kuh.ac.kr

Received on August 13, 2014. Revised on November 5, 2014. Accepted on January 2, 2015. Published online June 19, 2015

pISSN 1976-2283 eISSN 2005-1212 <http://dx.doi.org/10.5009/gnl14310>

© This is an Open Access article distributed under the terms of the Creative Commons Attribution Non-Commercial License (<http://creativecommons.org/licenses/by-nc/4.0>) which permits unrestricted non-commercial use, distribution, and reproduction in any medium, provided the original work is properly cited.

MATERIALS AND METHODS

1. Study subjects

Consecutive gastric or colorectal cancer patients who underwent complete surgical resection between August 2005 and June 2013 at our center were enrolled. Inclusion criteria were subjects who underwent esophagogastroduodenoscopy (EGD) and colonoscopy before surgery and those who agreed with genetic analysis for MSI. Subjects were excluded when there is a known genetic disease such as hereditary nonpolyposis colorectal cancer (HNPCC) or familial adenomatous polyposis. To exclude any possibility of HNPCC, data on family history, past history, and presence of double primary malignancy were collected. In addition, those who underwent endoscopic resection for gastric or colorectal cancer were excluded from the study. Synchronous lesion was defined as another gastric or colorectal neoplasm(s) found within 12 months before or after the surgery.

All of the patients provided informed consent before undergoing the endoscopic procedure and MSI analysis, and the study was approved by Institutional Review Board of Konkuk University School of Medicine which confirmed that the study was performed in accordance with the ethical standards of the Helsinki Declaration (KUH 1010266). After the IRB approval, this study was registered in the Korean Clinical Trial Registry as ClinicalTrials.gov ID KCT0000948. All of the authors accessed to the study data and had reviewed and approved the final manuscript.

2. Upper and lower endoscopic examination before surgery

Using the electronic endoscopic system consisted of the EVIS-260 processor, the upper and lower endoscopic images were converted into a tagged image format using an EVIS LUCERA system (Olympus Optical, Tokyo, Japan). Any tumorous lesion that is suspicious for cancer was biopsied during the procedure. Characteristics including location and shape of the cancer were recorded.

3. Pathological analysis after surgical resection

The size of resected specimen was measured as the maximum diameter of cancer. Well differentiated adenocarcinomas were diagnosed when the gland-forming area encompassed over 95% of the high-power field, while poorly differentiated adenocarcinomas were diagnosed when it was less than 50%. Moderately differentiated adenocarcinomas were diagnosed when the gland-forming area were between 50% and 95%. If two different cell types are mingled, the diagnosis was made based on the predominant cell type. In gastric cancer, Lauren's classification of intestinal, diffuse, or mixed type were analyzed.

4. Analysis for MSI

DNA preparation was performed as previously described in our study.^{8,11} With fluorescent dye-labeled primers of mononu-

cleotide markers (BAT25 and BAT26) and dinucleotide markers (D2S123, D5S346, and D17S250), MSI was analyzed by polymerase chain reaction amplification. MSI was defined as a differently sized band in the tumor sample or a band shift in either of the two alleles. A high incidence of MSI (MSI-H) was defined as a detection of instability in more than 30% of markers, a low incidence of MSI (MSI-L) was defined as a detection of instability in less than 30% of markers, and microsatellite stability (MSS) was defined as no definite evidence of MSI.

5. Immunohistochemical stain for MMR proteins in colorectal cancer

Analysis for MMR proteins was performed as previously described in previous studies.^{9,11} Slides were deparaffinized in xylene and rehydrated in 100%, 95%, and 70% alcohols to water. The slides were immersed in sodium citrate buffer (pH 6.0) for hMLH1 or EDTA (PH 8.4 to 9.0) for hMSH2, hMSH6, hPMS2 and heated in an autoclave for antigen retrieval. Endogenous peroxidase activity was blocked by incubation with 3% H₂O₂ for 5 minutes. hMLH1 (Cell Marque, Rocklin, CA, USA), hMSH2 (Cell Marque), hMSH6 (Cell Marque), and hPMS2 (Cell Marque) antibodies were incubated for 1 hour. Slides were then processed using a DAKO Envision kit (DAKO Corp., Carpinteria, CA, USA) for hMLH1/ hPMS2 and Optiview kit (Ventana, Tucson, AZ, USA) for hMSH2/ hMSH6. The sections were incubated with 3,3-diaminobenzidine tetrahydrochloride and H₂O₂ for 3 minutes, counterstained with hematoxylin, dehydrated in graded alcohols, cleared in xylene, and coverslipped.

6. Immunostaining for mucin phenotypes in gastric cancer

Analysis for mucin phenotypes was performed as previously described in our study.²⁰ Using the iVIEW DAB detection kit (Ventana Medical Systems Inc., Tucson, AZ, USA) by the Benchmark XT (Ventana Medical Systems Inc.), the immunohistochemical staining with primary antibodies, MUC5AC (45M/1; Neomarker, Fremont, CA, USA, 1:2,000), MUC6 (MCN6.01; Neomarker, 1:200), MUC2 (996/1; Neomarker, 1:2,000) and CD10 (56C6; Neomarker, 1:50) was carried out. Heat-induced antigen retrieval was carried out, and Hematoxylin was used for counterstaining. Gastric mucin phenotype was defined if more than 10% of cancer cells exhibited MUC5AC and/or MUC6. Intestinal mucin phenotype was defined if more than 10% of cancer cells exhibited MUC2 and/or CD10 markers. Mixed mucin phenotype was defined if more than 10% of neoplastic cells showed both gastric and intestinal markers. Unclassified mucin phenotype was defined if less than 10% of neoplastic cells showed gastric and intestinal markers.

7. Statistical analysis

Using PASW statistics 17.0 for windows (SPSS, Chicago, IL, USA), a p-value less than 0.05 was considered statistically significant. Continuous variables were compared by t-test and

presented as mean±standard deviation. For the continuous values showing asymmetric distribution, Kruskal-Wallis test was used for the comparison between three groups (cancers with MSS, cancers with MSI-L, and cancers with MSI-H). Differences on clinicopathological factors among three groups (MSS, MSI-L, and MSI-H groups) were analyzed by one-way analyses of variance (ANOVAs) followed by Bonferroni post-hoc tests for numerical variables and chi-square tests for categorical variables. Presence or absence of synchronous GI neoplasm served as the primary exposure of interest. Logistic regression analysis was performed to determine the independent significant clinicopathological factors that showed a causal relationship with a dependent variable in cancer patients with synchronous GI neoplasm.

RESULTS

1. Characteristics of the subjects

A total of 595 patients were included, and one patient showed synchronous gastric and rectal cancers. Of 434 gastric cancer patients, 9.4% showed MSI-H and 4.8% showed MSI-L. Of 162 colorectal cancer patients, 9.3% showed MSI-H and 5.5% showed MSI-L (Fig. 1). Double primary cancer was noticed in 21 (8 colon, 3 rectal, 2 lung, 2 breast, 1 esophagus, 1 thyroid, 1 liver, 1 pancreas, 1 ovary, and 1 cervical cancers) of 434 gastric cancer patients and 3 (1 gastric, 1 thyroid, and 1 lung cancers) of 162 colorectal cancer patients.

2. Gastric cancers according to the status of MSI

Of 434 gastric cancers, 372 showed MSS, 21 showed MSI-L, and 41 showed MSI-H (Table 1). Patients with MSI gastric cancer showed higher prevalence of synchronous colorectal cancer (4.8%, $p=0.023$), colorectal adenoma (11.3%, $p=0.011$), and gastric adenoma (3.2%, $p=0.004$) than those with MSS gastric cancers (0.5%, 3.2%, and 1.0%, respectively) (Fig. 2). Prevalence of the synchronous colorectal adenoma was highest in MSI-L

gastric cancers (19.0%) than those with MSI-H (7.3%) or MSS (3.2%) gastric cancers ($p=0.002$). In one-way ANOVA tests, the mean age was significantly different among the patients with MSS, MSI-L, and MSI-H gastric cancers (Table 1). Bonferroni post-hoc test exhibited that patients with MSI-H gastric cancer and those with MSI-L gastric cancer were older than those with MSS gastric cancer.

3. Synchronous GI neoplasm in gastric cancer patients

Gastric cancers were reanalyzed according to the presence of synchronous GI neoplasm. Of all significant variables, logistic regression analysis between synchronous GI neoplasm and correlated variables revealed that presence of MSI was the only significant factor ($p=0.004$). According to the logistic regression analysis, age of the subject ($p=0.059$), size ($p=0.736$), location ($p=0.303$), and stage ($p=0.326$) of the gastric cancer were not significant for synchronous GI neoplasm in gastric cancer patients.

4. Colorectal cancers according to the status of MSI

Of 162 colorectal cancers, 138 showed MSS, 9 showed MSI-L, and 15 showed MSI-H (Table 2). There was no synchronous gastric adenoma in all three groups, and there was no significant difference in the prevalence of synchronous colorectal adenoma between the MSI-H (13.3%), MSI-L (11.1%), and MSS (12.3%) colorectal cancers ($p=0.987$). In one-way ANOVA tests, there were no significant differences between the patients with MSS, MSI-L, and MSI-H gastric cancers (Table 2).

5. Synchronous GI neoplasm in colorectal cancer patients

In colorectal cancer patients, the presence of synchronous GI neoplasm was related to cell types and TNM staging. Neither MSI status nor MMR protein expression was related to the presence of synchronous GI neoplasm. There was no significant difference on the prevalence of colorectal adenoma between colon and rectal cancers according to the presence of MSI. Of 162

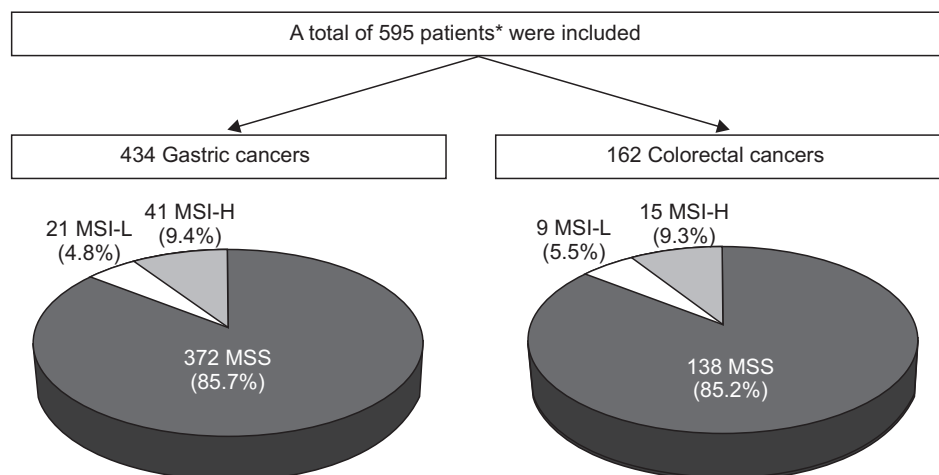


Fig. 1. Study flow. A total of 434 gastric cancers and 162 colorectal cancers were analyzed. One patient had synchronous gastric and rectal cancers.

MSI-L, low incidence of microsatellite instability; MSI-H, high incidence of microsatellite instability; MSS, microsatellite stability. *Includes one patient with synchronous gastric and rectal cancer.

Table 1. Characteristics of MSS, MSI-L, and MSI-H Gastric Cancers

Characteristic	Gastric cancers with MSS (n=372)	Gastric cancers with MSI-L (n=21)	Gastric cancers with MSI-H (n=41)	F	p-value
Age, yr	61.9±11.3	66.8±14.7	71.1±10.3	6.79	0.001
Male:female	251:121	15:6	29:12	$\chi^2=0.30$	0.860
Synchronous GI neoplasm					
Colorectal cancer	2 (0.5)	2 (9.5)	1 (2.4)	$\chi^2=14.75$	0.001
Colorectal adenoma	12 (3.2)	4 (19.0)	3 (7.3)	$\chi^2=12.82$	0.002
Gastric adenoma	4 (1.0)	2 (9.5)	0	$\chi^2=11.07$	0.004
Cell type, WD:MD:PD:signet ring:mucinous	39:137:118:65:13	3:10:3:5:0	2:25:10:3:1	1.38	0.241
Mucin phenotype, gastric:intestinal:mixed:unclassified	108:100:86:78	9:4:7:1	15:8:9:9	1.86	0.136
Location, antrum:corpus:fundus	160:164:48	9:8:4	30:11:0	4.44	0.012
Size, cm*	3.6 (0.3–15.8)	4.3 (1.2–23.0)	4.6 (0.7–11.3)	1.14	0.320
T stage, T1:T2:T3:T4	232:40:53:47	12:0:4:5	16:13:7:5	2.00	0.114
N stage, N0:N1:N2:N3	253:44:28:47	12:2:1:6	24:10:3:4	0.89	0.444
M stage, M0:M1	360:12	19:2	39:2	$\chi^2=2.40$	0.301
TNM stage, I:II:III:IV	245:51:59:17	11:3:3:4	20:14:5:2	0.95	0.415
Microinvasion					
Lymphatic invasion	119	9	18	$\chi^2=3.19$	0.203
Venous invasion	47	4	2	$\chi^2=3.03$	0.219
Perineural invasion	75	6	5	$\chi^2=2.54$	0.281

Data are expressed as mean±SD, number (%), or median (range).

MSS, microsatellite stable; MSI-L, low incidence of microsatellite instability; MSI-H, high incidence of microsatellite instability; SD, standard deviation; GI, gastrointestinal; WD, well differentiated adenocarcinoma; MD, moderately differentiated adenocarcinoma; PD, poorly differentiated adenocarcinoma; signet ring, signet ring cell carcinoma (poorly-cohesive carcinoma); mucinous, mucinous adenocarcinoma.

*Kruskal-Wallis test was used.

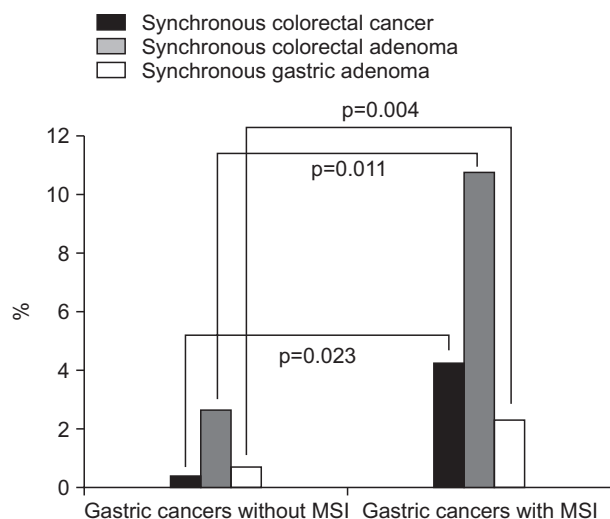


Fig. 2. Prevalence of synchronous neoplasms according to the microsatellite instability (MSI) status in gastric cancer. Gastric cancer patients with MSI had a higher prevalence of synchronous colorectal cancer, colorectal adenoma, and gastric adenoma than those with microsatellite stable gastric cancers.

colorectal cancer patients, 23 showed abnormal MMR protein expression on immunohistochemical stain (Table 3). Of these 23 colorectal cancer patients, only three showed synchronous GI

neoplasm, and only one showed extraintestinal cancer.

DISCUSSION

The prevalence of synchronous colorectal cancer, colorectal adenoma, and gastric adenoma in this study was significantly higher among the patients with MSI-associated gastric cancers than in those with MSS-associated gastric cancers. In addition, the prevalence of synchronous colorectal adenoma was higher in MSI-L gastric cancers than in either MSI-H or MSS gastric cancers. However, the prevalence of synchronous colorectal adenoma did not differ significantly among MSI-H, MSI-L, and MSS colorectal cancers. These findings suggest that the role of MSI during carcinogenesis differs between the stomach and the colon. *Helicobacter pylori* infection is known to be associated with genetic instability leading to MSI-associated premalignant lesions.²¹ Different from colorectal cancer, *H. pylori* infection leads to a deficiency of DNA MMR in gastric epithelial cells, which increases the risks of mutation and cancer.^{21,22} However, the suppressor pathway related to alterations in the p53, APC, and K-ras genes seems to be more important than the mutator pathway for colorectal carcinogenesis, especially for distal colon and rectal cancers.^{3,10}

Gastric cancers with MSI in the present study exhibited not

Table 2. Characteristics of MSS, MSI-L, and MSI-H Colorectal Cancers

Characteristic	Colorectal cancers with MSS (n=138)	Colorectal cancers with MSI-L (n=9)	Colorectal cancers with MSI-H (n=15)	F	p-value
Age, yr	63.0±11.8	61.6±11.2	63.3±10.1	0.67	0.649
Male:female	86:52	3:6	8:7	$\chi^2=3.25$	0.860
Synchronous GI neoplasm					
Colorectal adenoma	17 (12.3)	1 (11.1)	2 (13.3)	$\chi^2=0.03$	0.987
Gastric adenoma	0	0	0	-	-
Cell type, WD:MD:PD:signet ring:mucinous	1:128:3:1:5	1:7:0:0:1	0:14:1:0:0	0.25	0.862
Location, right:left:RS junction:rectum	29:65:14:30	6:1:0:2	10:4:0:1	2.01	0.116
Size, cm	4.1 (0.3–10.5)	5.0 (1.5–8.5)	4.5 (0.3–11.5)	0.45	0.638
CEA, mg/dL	3.5 (0.5–601.3)	2.6 (1.0–400.0)	2.2 (0.8–12.3)	0.52	0.595
T stage, T1:T2:T3:T4	13:12:98:15	2:0:3:4	2:3:8:2	1.87	0.138
N stage, N0:N1:N2:N3	74:32:32	3:2:4	11:4:0	0.85	0.431
M stage, M0:M1	114:24	6:3	15:0	$\chi^2=4.85$	0.088
TNM stage, I:II:III:IV	20:52:42:24	2:1:3:3	4:7:4:0	0.28	0.758
Microinvasion					
Lymphatic invasion	48	3	1	$\chi^2=4.91$	0.086
Venous invasion	8	2	0	$\chi^2=5.02$	0.081
Perineural invasion	37	4	1	$\chi^2=4.56$	0.102
IHC results of MMR protein					
Loss of MLH1 expression	8	0	9	$\chi^2=42.16$	<0.001
Loss of MSH2 expression	2	0	4	$\chi^2=23.78$	<0.001
Loss of MSH6 expression	1	0	4	$\chi^2=29.89$	<0.001
Loss of PMS2 expression	8	0	8	$\chi^2=34.33$	<0.001

Data are expressed as mean±SD, number (%), or median (range).

MSS, microsatellite stable; MSI-L, low incidence of microsatellite instability; MSI-H, high incidence of microsatellite instability; SD, standard deviation; GI, gastrointestinal; WD, well-differentiated adenocarcinoma; MD, moderately differentiated adenocarcinoma; PD, poorly differentiated adenocarcinoma; signet ring, signet ring cell carcinoma (poorly-cohesive carcinoma); mucinous, mucinous adenocarcinoma; RS, rectosigmoid; CEA, carcinoembryonic antigen; IHC, immunohistochemical stain; MMR, mismatch repair.

only a higher prevalence of synchronous colorectal neoplasm, but also a higher prevalence of synchronous gastric adenoma than those without MSI. The tumor multiplicity of gastric neoplasms is believed to be related to the MMR system, which plays a role in the carcinogenesis of multiple gastric carcinomas and adenomas.^{7,23} Since MSI is associated with intestinal-type gastric cancer, the chances of developing a synchronous gastric neoplasm would be greater during chronic *H. pylori* infection. Therefore, care must be taken to determine the presence and development of synchronous and metachronous gastric neoplasms in gastric cancer patients with MSI. With regard to the frequency of synchronous colorectal neoplasm in patients with MSI-related gastric cancers, the present findings are consistent with those of previous studies showed that older gastric cancer patients or those with MSI have an increased risk of developing synchronous neoplasm.^{13,18}

Notably, the prevalence of synchronous GI neoplasms among all gastric cancer patients was highest in the MSI-L group in this study. Our finding is consistent with a previous study finding

that the frequency of MSI-L was significantly higher in patients with multiple gastric cancers than in those with a single gastric cancer.²⁴ In the study, MSI-L was detected more frequently than MSI-H in patients with a single gastric cancer, synchronous multiple gastric cancers, or metachronous multiple gastric cancers. Another study of the incidence of MSI in patients with multiple primary GI cancers showed that patients with multiple cancers in different organs had a tendency to exhibit the MSI-L or MSS phenotypes.²⁵ Taken together, MSI-L is frequently accompanied by oncogene and tumor suppressor gene mutations during the slow process of gastric carcinogenesis, therefore increasing the risk of synchronous GI neoplasms.

With regard to the colorectal cancer patients, gastric cancer surveillance is recommended especially when the patient is old and male, has a positive family history of solid tumors, or lacks MSH2 expression in the cancer tissue.²⁶ Previous studies of synchronous neoplasms in GI cancers with MSI have revealed that patients with MMR defects tend to have neoplasms characterized by synchronous colorectal adenomas.^{14,15,26} The frequency

Table 3. Clinicopathological Findings of Colorectal Cancers with Either MSI or Abnormal MMR Protein Expression

Status of MSI	Age/sex	Location	Stage (TNM)	Cell type	MLH1	MSH2	MSH6	PMS2	Presence of synchronous neoplasm
MSS	58/M	Rectum	2 (T3N0M0)	MD	Loss	Intact	Intact	Loss	Colorectal adenoma
	34/F	Left colon	1 (T2N0M0)	MD	Loss	Intact	Intact	Loss	None
	55/M	Rectum	1 (T2N0M0)	MD	Loss	Intact	Intact	Loss	None
	59/M	Rectosigmoid junction	3 (T3N2M0)	MD	Loss	Intact	Intact	Loss	None
	64/M	Rectum	3 (T3N2M0)	MD	Loss	Intact	Intact	Loss	None
	74/F	Left colon	3 (T3N2M0)	MD	Loss	Intact	Intact	Loss	None
	81/M	Right colon	3 (T3N1M0)	MD	Loss	Intact	Intact	Loss	None
	74/M	Rectum	4 (T3N2M1)	MD	Loss	Intact	Intact	Loss	None
	59/M	Right colon	2 (T3N0M0)	MD	Intact	Loss	Loss	Intact	None
	52/F	Right colon	3 (T3N1M0)	MD	Intact	Loss	Intact	Intact	None
MSI-H	45/M	Left colon	1 (T1N0M0)	MD	Loss	Intact	Intact	Loss	Colorectal adenoma
	57/M	Right colon	2 (T3N0M0)	MD	Loss	Intact	Intact	Loss	Colorectal adenoma
	65/F	Right colon	2 (T3N0M0)	MD	Loss	Intact	Intact	Loss	Thyroid cancer
	51/F	Right colon	2 (T3N0M0)	MD	Loss	Intact	Intact	Loss	None
	63/F	Right colon	1 (T2N0M0)	MD	Loss	Intact	Intact	Loss	None
	72/F	Right colon	1 (T2N0M0)	MD	Loss	Intact	Intact	Loss	None
	73/F	Left colon	3 (T2N1M0)	MD	Loss	Intact	Intact	Loss	None
	74/M	Right colon	2 (T3N0M0)	MD	Loss	Intact	Intact	Loss	None
	71/M	Right colon	2 (T3N0M0)	PD	Loss	Intact	Intact	Intact	None
	54/F	Left colon	2 (T3N0M0)	MD	Intact	Loss	Loss	Intact	None
	73/M	Right colon	3 (T3N1M0)	MD	Intact	Loss	Loss	Intact	None
	79/M	Right colon	2 (T4N0M0)	MD	Intact	Loss	Loss	Intact	None
	58/M	Right colon	3 (T3N1M0)	MD	Intact	Loss	Loss	Intact	None
	55/M	Rectum	1 (T1N0M0)	MD	Intact	Intact	Intact	Intact	None
	59/F	Left colon	3 (T4N1M0)	MD	Intact	Intact	Intact	Intact	None
MSI-L	71/F	Right colon	3 (T3N1M0)	MD	Intact	Intact	Intact	Intact	Colorectal adenoma
	54/M	Right colon	1 (T1N0M0)	WD	Intact	Intact	Intact	Intact	None
	57/M	Rectum	1 (T1N0M0)	MD	Intact	Intact	Intact	Intact	None
	61/F	Right colon	3 (T3N1M0)	Mucinous	Intact	Intact	Intact	Intact	None
	65/F	Right colon	3 (T4N2M0)	MD	Intact	Intact	Intact	Intact	None
	78/M	Right colon	2 (T4N0M0)	MD	Intact	Intact	Intact	Intact	None
	68/F	Rectum	4 (T3N2M1)	MD	Intact	Intact	Intact	Intact	None
	61/F	Right colon	4 (T4N2M1)	MD	Intact	Intact	Intact	Intact	None
39/F	Left colon	4 (T4N2M1)	MD	Intact	Intact	Intact	Intact	None	

MSI, microsatellite instability; MMR, mismatch repair; MSS, microsatellite stable; M, male; MD, moderately differentiated adenocarcinoma; F, female; MSI-H, high incidence of microsatellite instability; PD, poorly differentiated adenocarcinoma; MSI-L, low incidence of microsatellite instability; WD, well-differentiated adenocarcinoma; mucinous, mucinous adenocarcinoma.

of MSI-H adenomas in patients with multiple colorectal cancers is known to be higher,¹⁴ and MSI is more frequent in colorectal cancers with a double primary malignancy.¹⁵ These findings are consistent with the present finding that MSI might be a predictor for detecting synchronous GI neoplasms. However, in this study, there was no significant correlation between synchronous colorectal adenoma and the presence of MSI in colorectal cancer. This suggests that synchronous colorectal adenoma occurs

irrespective of MSI in colorectal cancer patients, and that the role of the suppressor pathway, which is related to chromosomal instability, is more important than that of the mutator pathway, which is related to MSI. Of the two subtypes of sporadic synchronous multiple colorectal cancers, right-sided colon cancers are related to multiple occurrences of consecutive MSI-H tumors, whereas the other types exhibits multiple occurrence irrespective of MSI.²⁷

In the present study, more than half of the colorectal cancer patients with hMLH1 loss exhibited MSI-H. As suggested previously, methylation of the MLH1 gene promoter region may be an underlying cause of colorectal cancer with high MSI-H in patients without a germ-line mutation in an MMR gene.²⁸ In addition, our finding is consistent with a previous finding that the occurrence of GI neoplasms increases with age.²⁹ Since both aging and carcinogenesis show DNA damage and abnormal proteins, it is reasonable for synchronous GI neoplasm to occur more frequently in the elderly population. In the previous study, the proportion of gastric and colorectal carcinomas with hypermethylation of the hMLH1 promoter increased with age.²⁹ Gastric and colorectal cancers in elderly patients exhibited loss of hMLH1 expression, MSI, poorly differentiated histology, peritumoral inflammatory cell infiltration, low incidence of lymph node metastasis, and a favorable prognosis than those in young patients. The present study found gastric cancers with MSI to be related to old age. However, in colorectal cancer patients, MSI seems to be less strongly related to synchronous colorectal adenomas rather to chromosomal instability, which is linked to the development of most carcinomas.

The limitation of our study is that immunohistochemical stain for MMR protein was performed only for colorectal cancers and not for gastric cancers. For gastric cancers, MSI is not associated to MMR genetic alterations.³⁰ Therefore, we performed mucin phenotype analysis for gastric cancers instead of MMR protein analysis based on the previous studies.^{5,8,9,20,30}

In conclusion, MSI of gastric cancer is a predictor of synchronous colorectal neoplasm and gastric adenoma, and therefore both esophagogastroduodenoscopy and colonoscopy should be performed in these patients. On the other hand, synchronous colorectal adenoma occurs irrespective of MSI in colorectal cancer patients, suggesting that the suppressor pathway is more important than the mutator pathway in colorectal carcinogenesis.

CONFLICTS OF INTEREST

No potential conflict of interest relevant to this article was reported.

ACKNOWLEDGEMENTS

This work was supported by Konkuk University Medical Center Research Grant 2015.

REFERENCES

1. Boland CR, Thibodeau SN, Hamilton SR, et al. A National Cancer Institute Workshop on Microsatellite Instability for cancer detection and familial predisposition: development of international criteria for the determination of microsatellite instability in colorectal cancer. *Cancer Res* 1998;58:5248-5257.
2. Shah SN, Hile SE, Eckert KA. Defective mismatch repair, microsatellite mutation bias, and variability in clinical cancer phenotypes. *Cancer Res* 2010;70:431-435.
3. Boland CR, Goel A. Microsatellite instability in colorectal cancer. *Gastroenterology* 2010;138:2073-2087.e3.
4. Liu P, Zhang XY, Shao Y, Zhang DF. Microsatellite instability in gastric cancer and pre-cancerous lesions. *World J Gastroenterol* 2005;11:4904-4907.
5. Seo HM, Chang YS, Joo SH, et al. Clinicopathologic characteristics and outcomes of gastric cancers with the MSI-H phenotype. *J Surg Oncol* 2009;99:143-147.
6. Arai T, Sakurai U, Sawabe M, et al. Frequent microsatellite instability in papillary and solid-type, poorly differentiated adenocarcinomas of the stomach. *Gastric Cancer* 2013;16:505-512.
7. Kim SH, Ahn BK, Nam YS, Pyo JY, Oh YH, Lee KH. Microsatellite instability is associated with the clinicopathologic features of gastric cancer in sporadic gastric cancer patients. *J Gastric Cancer* 2010;10:149-154.
8. Chung HW, Lee SY, Han HS, et al. Gastric cancers with microsatellite instability exhibit high fluorodeoxyglucose uptake on positron emission tomography. *Gastric Cancer* 2013;16:185-192.
9. Choe WH, Lee SY, Lee JH, et al. High frequency of microsatellite instability in intestinal-type gastric cancer in Korean patients. *Korean J Intern Med* 2005;20:116-122.
10. Markowitz S. DNA repair defects inactivate tumor suppressor genes and induce hereditary and sporadic colon cancers. *J Clin Oncol* 2000;18(21 Suppl):75S-80S.
11. Lee SY, Chung H, Devaraj B, et al. Microsatellite alterations at selected tetranucleotide repeats are associated with morphologies of colorectal neoplasias. *Gastroenterology* 2010;139:1519-1525.
12. Yoon YS, Yu CS, Kim TW, et al. Mismatch repair status in sporadic colorectal cancer: immunohistochemistry and microsatellite instability analyses. *J Gastroenterol Hepatol* 2011;26:1733-1739.
13. Cho I, An JY, Kwon IG, et al. Risk factors for double primary malignancies and their clinical implications in patients with sporadic gastric cancer. *Eur J Surg Oncol* 2014;40:338-344.
14. Ueda E, Watanabe T, Umetani N, Ishigami H, Sasaki S, Nagawa H. Microsatellite instability of cancers and concomitant adenomas in synchronous multiple colorectal cancer patients. *J Exp Clin Cancer Res* 2002;21:149-154.
15. Yun HR, Yi LJ, Cho YK, et al. Double primary malignancy in colorectal cancer patients: MSI is the useful marker for predicting double primary tumors. *Int J Colorectal Dis* 2009;24:369-375.
16. An JY, Kim H, Cheong JH, Hyung WJ, Kim H, Noh SH. Microsatellite instability in sporadic gastric cancer: its prognostic role and guidance for 5-FU based chemotherapy after R0 resection. *Int J Cancer* 2012;131:505-511.
17. Tajima A, Hess MT, Cabrera BL, Kolodner RD, Carethers JM. The mismatch repair complex hMutS alpha recognizes 5-fluorouracil-modified DNA: implications for chemosensitivity and resistance. *Gastroenterology* 2004;127:1678-1684.
18. Kim HO, Hwang SI, Yoo CH, Kim H. Preoperative colonoscopy

- for patients with gastric adenocarcinoma. *J Gastroenterol Hepatol* 2009;24:1740-1744.
19. Hata K, Shinozaki M, Toyoshima O, et al. Impact of family history of gastric cancer on colorectal neoplasias in young Japanese. *Colorectal Dis* 2013;15:42-46.
 20. Han HS, Lee SY, Lee KY, et al. Unclassified mucin phenotype of gastric adenocarcinoma exhibits the highest invasiveness. *J Gastroenterol Hepatol* 2009;24:658-666.
 21. Chung WC, Jung SH, Lee KM, et al. Genetic instability in gastric epithelial neoplasias categorized by the revised Vienna classification. *Gut Liver* 2010;4:179-185.
 22. Kim JS, Chung WC, Lee KM, et al. Association between genetic instability and *Helicobacter pylori* infection in gastric epithelial dysplasia. *Gastroenterol Res Pract* 2012;2012:360929.
 23. Lee HS, Lee BL, Kim SH, Woo DK, Kim HS, Kim WH. Microsatellite instability in synchronous gastric carcinomas. *Int J Cancer* 2001;91:619-624.
 24. Miyoshi E, Haruma K, Hiyama T, et al. Microsatellite instability is a genetic marker for the development of multiple gastric cancers. *Int J Cancer* 2001;95:350-353.
 25. Yamashita K, Arimura Y, Kurokawa S, et al. Microsatellite instability in patients with multiple primary cancers of the gastrointestinal tract. *Gut* 2000;46:790-794.
 26. Yoon SN, Oh ST, Lim SB, et al. Clinicopathologic characteristics of colorectal cancer patients with synchronous and metachronous gastric cancer. *World J Surg* 2010;34:2168-2176.
 27. Abe Y, Masuda H, Okubo R. Microsatellite instability of each tumor in sporadic synchronous multiple colorectal cancers. *Oncol Rep* 2001;8:299-304.
 28. Levine AJ, Win AK, Buchanan DD, et al. Cancer risks for the relatives of colorectal cancer cases with a methylated MLH1 promoter region: data from the Colorectal Cancer Family Registry. *Cancer Prev Res (Phila)* 2012;5:328-335.
 29. Arai T, Kasahara I, Sawabe M, Honma N, Aida J, Tabubo K. Role of methylation of the hMLH1 gene promoter in the development of gastric and colorectal carcinoma in the elderly. *Geriatr Gerontol Int* 2010;10 Suppl 1:S207-S212.
 30. Leite M, Corso G, Sousa S, et al. MSI phenotype and MMR alterations in familial and sporadic gastric cancer. *Int J Cancer* 2011;128:1606-1613.