



Successful parturition and lactation after a deslorelin implant removal in a pregnant cat

Journal of Feline Medicine and Surgery Open Reports
1–4

© The Author(s) 2023

Article reuse guidelines:

sagepub.com/journals-permissions

DOI: 10.1177/20551169231201606

journals.sagepub.com/home/jfmsopenreports

This paper was handled and processed by the European Editorial Office (ISFM) for publication in *JFMS Open Reports*



Alessandra Paganotto¹ , Annouck Truttmann² and Émilie Rosset¹

Abstract

Case summary The aim of this clinical case presentation was to describe the effect of a 4.7 mg deslorelin implant placement in a pregnant queen during the second half of gestation, and the consequences of its removal on the pregnancy and parturition. A 5-year-old female cat exhibiting nesting behaviour and weight gain 10 days after placement of a deslorelin implant was presented for examination. Gestation was confirmed on ultrasound, with two well-formed kittens of a gestational age of approximately 7 weeks. The deslorelin implant placed on the umbilicus was removed 1 week later. No change in the pregnancy was observed after removal of the implant. The fetuses showed no signs of distress on ultrasound and radiography examination 4 days after removal of the implant. One week after implant removal, the queen naturally delivered two healthy kittens. The queen showed maternal behaviour with normal milk production.

Relevance and novel information In the light of the lack of literature on implant injection and removal in the pregnant queen, this case report showcases a successful birth of healthy kittens without any subsequent adverse effect on the queen. Further study is needed to assess the safety of implant removal during pregnancy and potential use as a means to induce fertile oestrus in the queen.

Keywords: Deslorelin implant; pregnancy; implant removal; parturition

Accepted: 30 August 2023

Introduction

Deslorelin is a synthetic hormone that causes the down-regulation of pituitary gonadotropin-releasing hormone (GnRH) receptors, a key hormone involved in the regulation of the reproductive system.

Although not specifically approved for use in queens, deslorelin implants are commonly used in domestic cats, and the recent approval for male cats in Europe has prompted consideration for expanding their use for females.

Deslorelin implants can be used off-label in the queen for puberty postponement,¹ contraception,² oestrus induction^{3,4} and treatment for post-spaying urinary incontinence.⁵ Pregnancy after induced heat in naturally mated queens has been described.⁶ Owing to its main contraceptive use in cats, its possible effects during pregnancy are mostly unknown. A case of the deslorelin implant being

inserted 9 days after mating has been reported.⁷ The implant was retained until the end of gestation, and a lack of maternal behaviour and milk production was subsequently observed in the queen, leading to the deaths of 3/4 kittens. In bitches, pregnancies owing to deslorelin-induced oestrus often fail due to low progesterone plasma concentration if the implant is not removed,⁸ and even with removal of the implant, luteal failure has been described.⁹

¹VetAgro Sup, Université de Lyon, Marcy l'Etoile, France

²Clinique Vétérinaire des Gratte-Ciel, Villeurbanne, France

Corresponding author:

Alessandra Paganotto DVM, VetAgro Sup, Université de Lyon, 1 avenue Bourgelat, Marcy l'Etoile, 69280, France

Email: alessandra.paganotto@vetagro-sup.fr



Creative Commons Non Commercial CC BY-NC: This article is distributed under the terms of the Creative Commons

Attribution-NonCommercial 4.0 License (<https://creativecommons.org/licenses/by-nc/4.0/>) which permits non-commercial use, reproduction and distribution of the work without further permission provided the original work is attributed as specified on the SAGE and Open Access pages (<https://us.sagepub.com/en-us/nam/open-access-at-sage>).

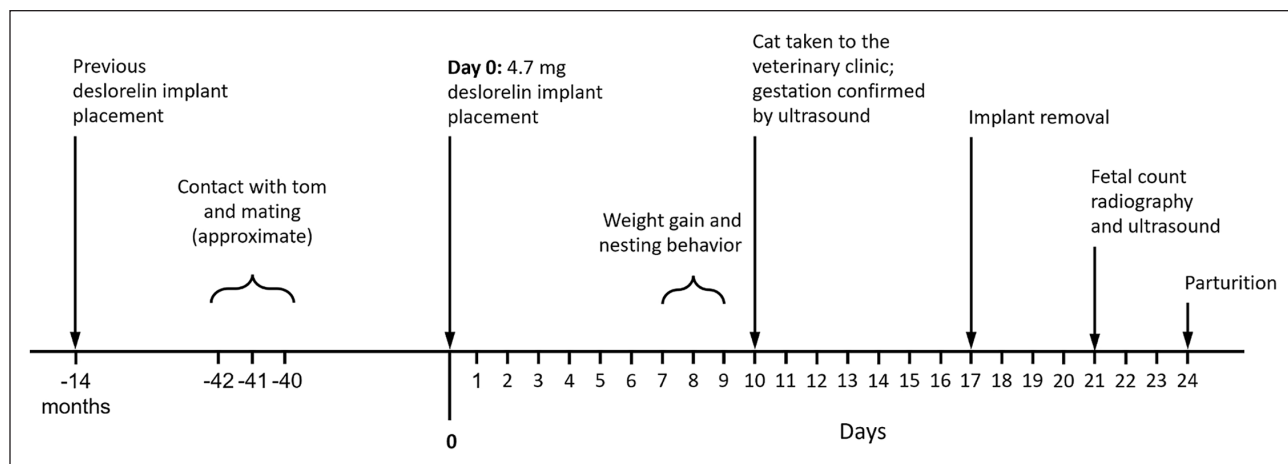


Figure 1 Case chronology. Days are referenced with respect to the implant placement date (day 0) onwards as the mating date is approximative. Two other deslorelin implants had been placed 14 and 27 months prior for contraceptive purposes

To our knowledge, this is the first case describing the insertion of a deslorelin implant and its removal in the second half of pregnancy in a queen, and where the result was a successful birth. No postnatal adverse effects on maternal behaviour, milk production nor kitten development were observed.

Case description

A 5-year-old domestic shorthair queen was presented to the veterinary clinic for abnormal behaviour after the placement of a deslorelin (Suprelorin 4.7mg; Virbac) implant. The queen exhibited uncharacteristic nesting and affectionate behaviour associated with weight gain 10 days after the implant placement. For convenience, the implant placement date is referred to as day 0 (Figure 1). The queen lived in the same household as a tom cat, and both cats underwent regular deslorelin implantation with a view to future mating and reproduction. The implant was inserted on day 0 and had been placed 1.5cm above the umbilicus with no suspicion of pregnancy at the time. Two other implants had been previously inserted, 14 and 27 months earlier, respectively.

An ultrasonographic examination was performed on day 10, which confirmed pregnancy. The gestational age was estimated as 7 weeks. The owners expressed a desire to keep the litter, if possible.

A week later, 17 days after its initial placement, the implant was removed under short alfaxalone (10 mg/ml, Alfaxan; Jurox) anaesthesia. The localisation of the implant above the umbilicus, despite not being labelled, allowed for an easy localisation and removal of the implant. Four days later, an ultrasound examination of the fetuses revealed two normal heartbeats (>200 bpm). A radiograph taken on the same day confirmed the presence of two well-formed fetal skeletons (Figure 2).

Three days later, the queen gave birth naturally to two kittens without any difficulty, with a time interval

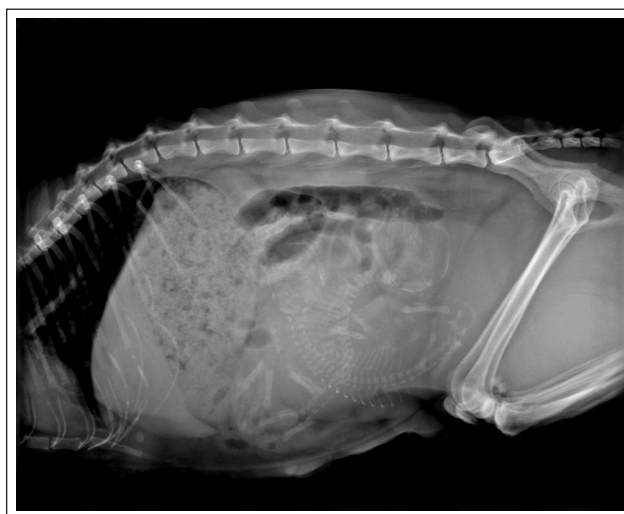


Figure 2 Fetal count radiography 3 days before delivery, revealing the skeleton of two cat fetuses. Ultrasound examination also showed two normal heartbeats

of 1.5 h. Both mother and kittens were in good health, and no abnormalities were reported. The queen showed maternal behaviour and normal milk production.

Discussion

Despite its off-label status for use in queens, there has been significant research on the impact of deslorelin implants in queens for heat induction and fertility suppression. An immediate effect on stimulation of the luteinising hormone (LH) and follicle stimulating hormone has been observed in male dogs at the moment of implant placement, before GnRH downregulation,^{10,11} generally known as the flare-up effect. In queens, the effect of the deslorelin implant is influenced by their cycle.¹² Queens implanted in oestrus showed no increase in oestradiol (E2) production, while an augmentation of progesterone

(P4) was noted 7 days after treatment.³ Queens implanted during inter-oestrus after ovulation exhibited a marginal rise in E2 levels 48 h after implantation, followed by a subsequent decline. In addition, there was an increase in P4 concentration from day 0 to day 7 after implantation. Conversely, one queen that was implanted post-oestrus showed an increase in E2 until day 7, followed by a return to basal levels by day 28. Notably, in this specific case, there was no discernible increase in P4.

We used inter-oestrus queens as a reference in the absence of studies on the subject since gestation occurs in the presence of a functional corpus luteum. In the present case, although there was a possibility of an increase in E2 after the implant injection, it did not appear to have any significant impact on the pregnancy. However, a lack of monitoring before the 11th day post-implant injection did not allow us to completely rule out fetal resorption. Contrary to dogs,^{13,14} luteal insufficiency has not been described in the current literature in pregnant queens after implant injection.⁷ This may be due to the luteotropic influence of prolactin, which is produced by the fetoplacental unit from day 35. Still, an earlier downregulation of LH and luteotropic elements has been described during inter-oestrus in implanted queens,³ and thus deserves to be taken into consideration to avoid resorptions and abortion in the pregnant queen. More studies are necessary to determine the possible effects of deslorelin-induced LH downregulation in pregnant queens.

Upon reviewing the existing literature and considering the preference expressed by the owner to keep the litter, the decision to remove the implant was predominantly influenced by the case report conducted by Goericke-Pesch et al,⁷ which highlighted a lack of maternal behaviour and milk production after a pregnancy in a queen with a deslorelin implant. Contrary to the bitch, where the deslorelin implant has been used off-label to induce oestrus with a considerable (60%) level of fertility,¹⁵ we still know little about this application in the queen. Considering this case and the current literature, it appears possible to not only induce fertile ovulation and heat in oestrus and post-oestrus queens,³ but also to carry to term a normal pregnancy without side effects for the queen and the litter, thanks to removal of the implant during pregnancy. Further studies are needed to better understand and improve this possible utilisation of the deslorelin implant in the queen.

The on-label implant placement indication is between the shoulder blades; however, this positioning presents a notable challenge when considering the potential need for subsequent implant removal. The periumbilical region is commonly described as a suitable site for implant placement⁶ because it facilitates localisation and retrieval of the implant, thus simplifying the removal process. Removal of the implant should always be considered as it can potentially induce collateral

effects such as continuous heat⁶ and weight gain¹⁶ in specific individuals. Moreover, considering the potentially long duration of oestrus suppression observed in some implanted queens, breeders may request early removal of the implant.⁶

Pregnancy had not been definitively ruled out in our case before the implant injection. Given the uncertain effects of deslorelin implantation on pregnant queens, performing ultrasound examinations to exclude pregnancy is essential before administration of the implant. Queens living with intact males, even if chemically castrated, need to be especially considered given the wide range of durations of deslorelin-induced anoestrus in tom cats (6–18 months)¹⁷ and queens (4–38 months).¹²

Conclusions

To the authors' knowledge, this is the first description of a queen injected with a deslorelin implant in the second half of pregnancy. In the present case, the implant was subsequently removed and the queen carried the pregnancy to term without repercussions on maternal and neonatal health. This observation indicates potential deslorelin utilisation in the queen to induce heat with a subsequent normal pregnancy, parturition and lactation enabled by its removal during pregnancy. However, more outcome evaluation studies on the effect of deslorelin implants on gestation are needed to confirm this effect. Considering the limited knowledge about the effects of implant injection in already pregnant queens, they should always be checked to rule out pregnancy before implant injection. Furthermore, since the duration of fertility suppression is variable in queens, the efficacy of an implant still being in place at the time of implant renewal cannot be assured. Thus, pregnancy should be ruled out even in the presence of a previous implant.

Acknowledgements The authors would like to express their gratitude to Virbac Company for their valuable technical support throughout the clinical case and financial support towards the publication costs. The description of this case gave rise to a pharmacovigilance report to improve the understanding of adverse reactions associated with deslorelin implant usage during pregnancy in the queen, and to help future veterinarians make informed decisions in similar situations.

Conflict of interest The authors declared no potential conflicts of interest with respect to the research, authorship, and/or publication of this article.

Funding The research described herein was carried out without the receipt of any specific grants or external funding.

Ethical approval The work described in this manuscript involved the use of non-experimental (owned or unowned) animals. Established internationally recognised high standards ('best practice') of veterinary clinical care for the individual patient were always followed and/or this work involved the

use of cadavers. Ethical approval from a committee was therefore not specifically required for publication in *JFMS Open Reports*. Although not required, where ethical approval was still obtained, it is stated in the manuscript.

Informed consent Informed consent (verbal or written) was obtained from the owner or legal custodian of all animal(s) described in this work (experimental or non-experimental animals, including cadavers) for all procedure(s) undertaken (prospective or retrospective studies). No animals or people are identifiable within this publication, and therefore additional informed consent for publication was not required.

ORCID iD Alessandra Paganotto  <https://orcid.org/0000-0003-2535-8730>

References

- Cecchetto M, Salata P, Baldan A, et al. **Postponement of puberty in queens treated with deslorelin.** *J Feline Med Surg* 2017; 19: 1224–1230.
- Toydemir TS, Kılıçarslan MR and Olgaç V. **Effects of the GnRH analogue deslorelin implants on reproduction in female domestic cats.** *Theriogenology* 2012; 77: 662–674.
- Goericke-Pesch S, Georgiev P, Atanasov A, et al. **Treatment of queens in estrus and after estrus with a GnRH-agonist implant containing 4.7 mg deslorelin; hormonal response, duration of efficacy, and reversibility.** *Theriogenology* 2013; 79: 640–646.
- Zambelli D, Bini C, Küster DG, et al. **First deliveries after estrus induction using deslorelin and endoscopic transcervical insemination in the queen.** *Theriogenology* 2015; 84: 773–778.
- Pisu MC and Veronesi MC. **Effectiveness of deslorelin acetate subcutaneous implantation in a domestic queen with after-spaying urinary incontinence.** *J Feline Med Surg* 2014; 16: 366–368.
- Ferré-Dolcet L, Ferro S, Contiero B, et al. **Resumption of ovarian activity following removal of a 4.7 mg deslorelin implant in queens.** *Reprod Domest Anim* 2022; 57: 3–9.
- Goericke-Pesch S, Georgiev P, Atanasov A, et al. **Treatment with Suprelorin in a pregnant cat.** *J Feline Med Surg* 2013; 15: 357–360.
- Ponglowhapan S, Suthamnatpong A, Khamanarong A, et al. **Failure to conceive in deslorelin-induced oestrous bitches with regard to removal of hormone implants after ovulation.** *Thai J Vet Med* 2018; 48: 211–217.
- Fontaine E, Mir F, Vannier F, et al. **Induction of fertile oestrus in the bitch using deslorelin, a GnRH agonist.** *Theriogenology* 2011; 76: 1561–1566.
- Concannon PW, Temple M, Montanez A, et al. **Effects of dose and duration of continuous GnRH-agonist treatment on induction of estrus in beagle dogs: competing and concurrent up-regulation and down-regulation of LH release.** *Theriogenology* 2006; 66: 1488–1496.
- Spruijt A, Kooistra H, Oei C, et al. **The function of the pituitary-testicular axis in dogs prior to and following surgical or chemical castration with the GnRH-agonist deslorelin.** *Reprod Domest Anim* 2023; 58: 97–108.
- Romagnoli S and Ferre-Dolcet L. **Reversible control of reproduction in queens: mastering the use of reproductive drugs to manipulate cyclicity.** *J Feline Med Surg* 2022; 24: 853–870.
- Kutzler M, Lamb SV and Volkmann D. **Comparison between vestibular and subcutaneous insertion of deslorelin implants for oestrus induction in bitches.** *Reprod Domest Anim* 2009; 44: 83–86.
- Romagnoli S, Stelletta C, Milani C, et al. **Clinical use of deslorelin for the control of reproduction in the bitch.** *Reprod Domest Anim* 2009; 44: 36–39.
- Maenhoudt C, Santos NR and Fontbonne A. **Manipulation of the oestrous cycle of the bitch-what works. . . for now.** *Reprod Domest Anim* 2018; 53: 44–52.
- Munson L, Bauman JE, Asa CS, et al. **Efficacy of the GnRH analogue deslorelin for suppression of oestrous cycles in cats.** *J Reprod Fertil Suppl* 2001; 57: 269–273.
- Ferré-Dolcet L and Romagnoli S. **Reversible control of reproduction in tom cats: medical options for manipulating libido and fertility.** *J Feline Med Surg* 2023; 25. DOI: 10.1177/1098612X231171406.