

Effects of pentoxifylline and alendronate on fracture healing in ovariectomy-induced osteoporosis in rats

Mohammad-Mahdi Vashghani Farahani¹, Reza Masteri Farahani², Mohammad-Amin Abdollahifar², Mahdi Ghatresamani³, Seyed Kamran Ghoreishi⁴, Behnam Hajihossainlou⁵, Sufan Chien⁶, Atarodsadat Mostafavinia⁷, Fatemehsadat Rezaei⁸, Mohammad Bayat^{8*}

¹ Department of Basic Sciences, School of Allied Medical Sciences, Shahid Beheshti University of Medical Sciences, Tehran, Iran; ² Department of Biology and Anatomical Sciences, School of Medicine, Shahid Beheshti University of Medical Science, Tehran, Iran; ³ Cellular and Molecular Research Center, Shahrekord University of Medical Sciences, Shahrekord, Iran; ⁴ Department of Statistics, Faculty of Sciences, University of Qom, Qom, Iran; ⁵ Department of Internal Medicine, Aurora Medical Center- Bay Area, Marinette, Wisconsin, USA; ⁶ Price Institute of Surgical Research, University of Louisville, Noveratech LLC of Louisville, Louisville, USA; ⁷ Department of Anatomy, School of Medicine, Tehran Medical Sciences Branch, Islamic Azad University, Tehran, Iran; ⁸ Cellular and Molecular Biology Research Center, Department of Biology and Anatomical Sciences, Shahid Beheshti University of Medical Science, Tehran, Iran.

Article Info

Article history:

Received: 12 March 2018
Accepted: 01 August 2018
Available online: 15 June 2019

Key words:

Fracture healing
Osteoporosis
Ovariectomy
Real time PCR
Stereology

Abstract

Osteoporosis is determined by decreased bone strength that increases the threat of fractures. The aim of this study was to evaluate the effects of pentoxifylline (PTX) and alendronate (ALN), on the stereological parameters, and gene expression in callus of fracture in an experimental rat model of ovariectomy-induced osteoporosis (OVX). The OVX was induced in 90 female rats. Fourteen weeks later, a complete fracture on the right femur was made. Rats were divided into five groups: 1) control: no treatment; 2) sham: received daily distilled water; 3) daily 3.00 mg kg⁻¹ ALN subcutaneously (SC); 4) daily 200 mg kg⁻¹ PTX (SC) and 5) daily PTX (SC) + ALN (same doses). The osteoclast count was significantly lower in all treatment groups, at 21 and 56 days post-surgery, compared to the control and sham groups. The PTX significantly increased total callus volume at 21 and 56 days post-surgery, compared to the other groups. The PTX+ALN treatment significantly increased both cortical bone volume on day 21, and osteocyte and osteoblast numbers on day 56, compared to the control and sham groups. It can be concluded that PTX and ALN have antiresorptive effects, in OVX rats. Also, PTX has increased the extracellular matrix on both 21 and 56 days after surgery, compared to the other groups. PTX+ALN elevated cortical bone volume on day 21, and osteocyte and osteoblast numbers compared to the control and sham groups on day 56.

© 2019 Urmia University. All rights reserved.

اثرات پنتوکسیفیلین و آندرونیت بر التیام شکستگی در استئوپوروز ناشی از برداشتن تخمدان در موش‌های صحرایی

چکیده

پوکی استخوان با کاهش قدرت استخوان که خطر شکستگی‌های استخوانی را افزایش می‌دهد، همراه است. هدف از مطالعه حاضر ارزیابی اثرات پنتوکسیفیلین (PTX)، آندرونیت (ALN) بر متغیرهای استریولوژیک و نیز بیان ژن در کالوس شکستگی در مدل تجربی پوکی استخوان ناشی از برداشتن تخمدان (OVX) در موش صحرایی بود. در ۹۰ موش صحرایی تخمدان برداشته شد و ۱۴ هفته بعد آن یک شکستگی کامل در استخوان ران راست ایجاد گردید. موش‌ها به پنج گروه تقسیم شدند: (۱) شاهد: بدون درمان، (۲) شام: دریافت روزانه آب مقطر، (۳) دریافت روزانه ۳/۰۰ میلی گرم بر کیلوگرم ALN، (۴) دریافت روزانه ۲۰۰ میلی گرم بر کیلوگرم PTX، (۵) دریافت روزانه ALN + PTX (همان دوز). تعداد استئوکلاست در روزهای ۲۱ و ۵۶ بعد جراحی در گروه‌های درمانی بطور معنی‌دار کمتر از گروه‌های شاهد و شام بود. پنتوکسیفیلین به‌طور معنی‌دار حجم کل کالوس استخوانی را در مقایسه با دیگر گروه‌ها افزایش داد. PTX+ALN به‌طور معنی‌دار تعداد استئوبلاست‌ها و استئوسیت‌ها در روز ۵۶ و حجم استخوان قشری را در مقایسه با گروه‌های شاهد و شام در روز ۲۱ افزایش داد. نتیجه‌گیری می‌شود که ALN، PTX، در موش‌های OVX، واجد اثرات ضد جذبی می‌باشند. بعلاوه، پنتوکسیفیلین ماتریکس خارج سلولی را در ۲۱ و ۵۶ روز بعد از جراحی در مقایسه با دیگر گروه‌ها افزایش داد. PTX+ALN حجم استخوان قشری را در روز ۲۱ افزایش داد و تعداد استئوبلاست‌ها و استئوسیت‌ها را در مقایسه با گروه‌های شاهد و شام در ۵۶ روز بالا برد.

واژه‌های کلیدی: استریولوژی، التیام شکستگی، برداشتن تخمدان، پوکی استخوان، واکنش زنجیره‌ای پلیمرز در زمان واقعی

*Correspondence:

Mohammad Bayat. PhD
Department of Biology and Anatomical Sciences, Shahid Beheshti University of Medical Science, Tehran, Iran
E-mail: mohbayat@sbmu.ac.ir



This work is licensed under a Creative Commons Attribution-NonCommercial 4.0 International License which allows users to read, copy, distribute and make derivative works for non-commercial purposes from the material, as long as the author of the original work is cited properly.

Introduction

Osteoporosis (OP) is characterized as a decline in the volume of bone mass density and the derangement of bone micro construction, resulting in a global deficiency in bone strength, which consequently increases the risk of fractures.¹ The OP is one of the most prevalent chronic illnesses in the US and all over the world. The most common complication of OP is the fracture, which has a significant adverse effect on the quality of life of the patients. Particularly in elderly people, it can trigger a series of events, which can eventually lead to death.² The OP is a rising issue in the US that influences 10 million patients nationwide,³ causing two million fractures annually with the financial burden of approximately \$19 billion per year.⁴

Menopause is accompanied by lower estrogen levels and increases the risk of OP in women.⁵ In a normal body, osteoclast (OC) and osteoblast cells coordinate closely to maintain bone integrity. The OP is related to the huge increase in bone resorption triggered by amplifying OC counts (due to stimulated OC production and decreased OC death) and also by increased OC activity.⁶

Inadequate bone mass and derangement of the bone structure caused by OP, increases the risk of a fragility fracture of the bone, in comparison with the normal bone. Fracture healing in the elderly who suffer from OP remains a complex clinical challenge.⁷ Animal studies demonstrated that pharmacological interventions can accelerate fracture healing, offering an essential adjunct to bone fracture management.⁸

Bisphosphonates (BPs) have been used for the treatment of OP for many years.⁹ Animal experiments have shown that alendronate (ALN) administration prevents bone resorption and has a positive effect on fracture healing, without any adverse effects on bridging, bone strength, or mineralization in adult dogs.¹⁰ Long-term ALN treatments suppressed remodeling and consequently increased the degree of mineralization of bone.¹¹ Moreover, ALN treatment increased bone strength via the distinctive effect on bone mass and quality.¹² In addition, ALN might delay the process of intracortical bone turnover in rats,¹³ and displays a positive outcome on bone mineral density (BMD) in the metaphyseal fracture healing.¹⁴ In ovariectomy-induced osteoporosis (OVX) rats, ALN had a favorable effect on the biomechanical parameters of the callus, but delayed callus turnover by inhibiting the transformation of woven bone into lamellar bone.¹⁵ In humans, administration of BPs alone, after a fracture happens does not seem to have a marked effect on the bone defect. Rarely, the atypical fractures and delayed bone repair process have been reported in the patients with long term use of BP.⁹ Clearly, some pharmacological materials have a negative influence on the fracture healing process; thus, sometimes a minimal alteration in medications, used by the patient can lead to a better result.¹⁶

Several investigations have demonstrated that pentoxifylline (PTX) improves fracture healing in healthy animals and patients.¹⁷⁻²² We hypothesized that PTX can be used as a potential therapeutic medicine for treating bone defect, as established by several investigations.¹⁷⁻²²

Recently, Vashghani Farahani *et al.* examined the effects of the administration of 200 mg kg⁻¹ PTX on the remodeling phase of a complete bone fracture in OVX rats. The results demonstrated increased biomechanical properties of callus in PTX-treated rats, compared to the control OVX animals.²²

In this study, we evaluated the effects of PTX and ALN alone and in combination, on stereological parameters, and the gene expression of insulin-like growth factor I (IGF-I), bone morphogenetic protein BMP-2 and BMP-7, and Wnt10b, in callus of fracture in an experimental rat model of OVX. The results of the current study could be utilized to develop clinical trials, which eventually could improve the fracture-healing process in patients with OP.

Materials and Methods

Animals and study design. Ninety adult female Wistar rats, 20 weeks old and weighing 241.60 ± 11.76 g (mean ± SD), were kept in a standard animal house and weighed regularly on a weekly basis during the experiment. Firstly, OVX was induced in all rats by removing both ovaries. Then a complete fracture was created in the midshaft of the right femur. The rats were divided into five groups (18 animals in each) including: Group 1) control: no treatment; group 2) sham: received daily distilled water subcutaneously (SC); group 3) daily 3.00 mg kg⁻¹ ALN (Alborz Darou, Tehran, Iran, SC); group 4) daily 200 mg kg⁻¹ PTX (Sigma-Aldrich, St. Louis, USA) divided into two doses of 100 mg kg⁻¹ intraperitoneally at 9:00 AM and 100 mg kg⁻¹ SC at 5:00 PM, and group 5) PTX+ALN (both SC, same doses). Finally, the rats were euthanized at different time points (after 21, and 56 days for stereological study, and 35 days for gene expression test), and the calluses were dissected and submitted for stereological and gene expression analysis. The protocol was evaluated and approved by the institutional Medical Ethics Commission of the first author's institute (No: 1392-1-115-1159).

Ovariectomy. The technique has been previously described in details.²³ Briefly, under general anesthesia and aseptic conditions, two paravertebral skin incisions were made and ovaries were removed. After removing the bilateral ovaries, the wounds were closed. Rats were kept for 14 weeks in order to establish OP.²³

Fracture model, treatments and sampling. The technique was explained thoroughly in our previous study.²³ Under general anesthesia and aseptic conditions, one incision was made over the right thigh to expose the femur. Three to five partial transversal standardized

osteotomies were made with a low-speed drill in each femur, then the osteotomy site was broken manually and the femur was divided into two parts. The bone was stabilized with internal fixation. Fixation was performed intramedullary, using a stainless wire (1.00 mm diameter). Fracture fragments were contacted and stabilized. A distance of 3.00 mm (gap) was maintained between the edges of fractures, constant in the entire population of rats. Wires were cut on the surface of the femur's intercondylar groove to avoid restricted motion in the knee joint. Muscle tissue was sutured with 4-0 catgut (Supa, Tehran, Iran) and the skin was sutured with 4-0 nylon reversed cutting sutures (Supa). The unrestricted activity was allowed after recovery from anesthesia. The rats received the daily treatments as mentioned before. At first, we have performed a dose-response study on fracture healing in healthy rats and 200 mg kg⁻¹ of PTX was chosen as the optimum dose for fracture healing in rats in the current study.¹⁶ Prior to surgery, all rats received 20.00 mg kg⁻¹ ibuprofen (Emad Darman Pars Co., Tehran, Iran) orally and then every 8 to 12 hr for five days after surgery. On the other hand, in many studies, authors treat fracture healing in osteoporotic models for two months,^{22,24} accordingly, PTX and ALN treatments were performed for eight weeks. The rats were euthanized with an overdose of 150 mg kg⁻¹ ketamine (Roche Diagnostics, Mannheim, Germany) and 15 mg kg⁻¹ diazepam (Caspian Tamin Pharmaceutical Co., Rasht, Iran) and placed in a CO₂ chamber on days 21 and 56 post-operation for stereological examination, and on day 35 for gene expression analysis. Thus, the callus of some rats was submitted for histological and stereological examination, and the callus of other rats was submitted for gene expression analysis. We have studied histological examinations at anabolic (day 21), and catabolic (day 56) phases of fracture healing.²⁴⁻²⁷ This time was chosen because, according to our preliminary experiment and the other study,²⁸ fracture healing was in progress, although not complete, and peripheral resorption of the outer callus should not occur. Thus, it seems that the expression of the genes of interest in our fracture healing model on day 35 was at the optimized state.

Measurement of the bone volumes. All procedures were explained in details in our previous publications.^{23,29} The fractured bones were fixed in formalin saline and decalcified in formic acid for three weeks. The sections of 5- and 15 μm thickness from the specimens were cut serially in the callus area, then they were embedded in paraffin. The sections were stained with hematoxylin and eosin (H & E), subsequently 15 sections were randomly selected for stereological examination. The bone defects were evaluated, using a light microscope connected to a camera and a projecting microscope. All volumes (V), including total volume of callus (mm³), trabecular bone volume (mm³), and cortical bone volume (mm³) were calculated, using the Cavalieri method:

$$V = t \times (\Sigma p \times a/p)$$

where, Σp is the total of points, hitting a callus section, a/p is the area associated with each point, and t is the distance between the sampled sections.^{23,29}

Estimation of the number of bone cells using dissector method. Numerical density of cells was calculated by the following formulation:

$$Nv = \Sigma Q [(h \times af^1 \times \Sigma p) \times (t/BA)]^{-1}$$

where, ΣQ is the number of cells (10³) in all dissectors, h is the height of the optical dissector, af^1 is the area of the counting frame, Σp is the total number of counted frames, BA is the microtome block advance to cut the block (25 μm), and t is the mean of the final section thickness (20 μm). The formula for the total number (N) of bone cells: ^{23,29}

$$N = Nv \times V_{final}$$

RNA extraction and real time (RT)-PCR. RNA extraction and RT-PCR techniques were described in details in our previous publication.²⁴ The total RNA was extracted, using Trizol reagents (Invitrogen, Carlsbad, USA) with the aid of a tissue lyser (Qiagen GmbH, Hilden, Germany). The cDNA synthesis was performed, using the Revert Aid First Strand cDNA synthesis kit (Fermentas, Vilnius, Lithuania). The expression of IGF-I, BMP-2, BMP-7 and Wnt10b genes were monitored by real-time RT-PCR procedure, using the SYBR Green PCR Master Mix (Takara Bio Inc., Kusatsu, Japan). The mRNA level of candidate genes were normalized by the signal for 18S ribosomal RNA (rRNA) and control group. The primers used to amplify cDNA are shown in Table 1. For each rat, three replicates were produced for each target gene (of IGF-I, BMP-2 and BMP-7, and Wnt10b).²⁹⁻³¹

Statistical analysis. All data were expressed as mean ± standard deviation of the mean (SD). Differences between treatment groups with normal distribution of data were tested by one-way analysis of variance (ANOVA), followed by least significant difference (LSD) in SPSS (version 20.0; IBM, Chicago, USA). Body weight analysis was performed, using Student *t*-test. The *p* value less than 0.05 was considered significant.

Table 1. Primers of the studied genes for RT-PCR.

Gene	Primer sequences	Length of PCR products
IGF1	F: GGAACATAAGGCACGCTGAAC	88
IGF1	R: TGAGGAAGCAGGTAGATGGTGA	
BMP2	F: AGAAGCCAGGTGTCTCCAAGA	222
BMP2	R: CCACATCACTGAAGTCCACATACA	
BMP7	F: GGTGGTCAACCCTCGGCACA	109
BMP7	R: CTGGGGTCCATGCCGTCCTCAA	
Wnt10b	F: GCTTCGGGCCAAGTTGTTCG	125
Wnt10b	R: CACCCCATCCACGCTGTCC	

Results

Stereological examination. The light microscopic slides of healing tissue and bone callus in the examined groups on days 21, and 56 are shown in Figures 1 and 2. The stereological examinations are presented in Figures 3 to 5.

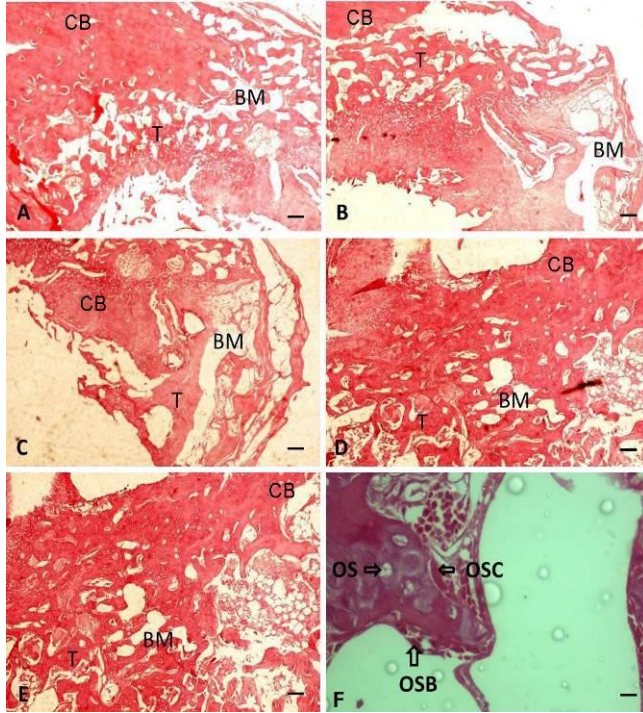


Fig. 1. Micrographs of the repairing tissues and bone callus and representative histology of the examined groups on day 21 after surgery (H & E, Scale bar = 100 μ m). **A)** First group, OVX, control: no treatment; **B)** second group, OVX, sham: received daily-distilled water; **C)** third group, OVX, daily ALN; **D)** fourth group, OVX, daily PTX and **E)** fifth group OVX, PTX+ALN. **F)** Osteoblast (OSB), Osteocyte (OS), Osteoclast (OSC) was shown in healing tissue. T: Trabecular bone, BM: Bone Marrow, CB: Cortical bone.

Stereological results of Day 21. Bone callus volume of the PTX group was significantly higher than the ALN, sham, control, and PTX+ALN groups ($p < 0.001$), (Fig. 3A). The ALN, and PTX+ALN groups showed a significant increase in trabecular bone volume, compared to the sham group ($p < 0.01$), (Fig. 3B). There was a significant increase in cortical bone volume of PTX+ALN group than sham and control groups ($p < 0.05$), (Fig. 3C).

Stereological results on day 56. The PTX+ALN group showed a significant increase osteocyte numbers compared to the PTX and sham groups according to ANOVA ($p > 0.05$) and LSD (both $p < 0.05$), (Fig. 4A). The PTX+ALN showed significantly increased in osteoblast number, compared to the ALN, sham, and control groups according to ANOVA ($p > 0.05$) and LSD, ($p < 0.01$), ($p < 0.05$), ($p < 0.05$), respectively, (Fig. 4B). All treatment groups showed a significant decrease in osteoclast number, compared to the control and sham groups ($p < 0.001$), (Fig. 4C).

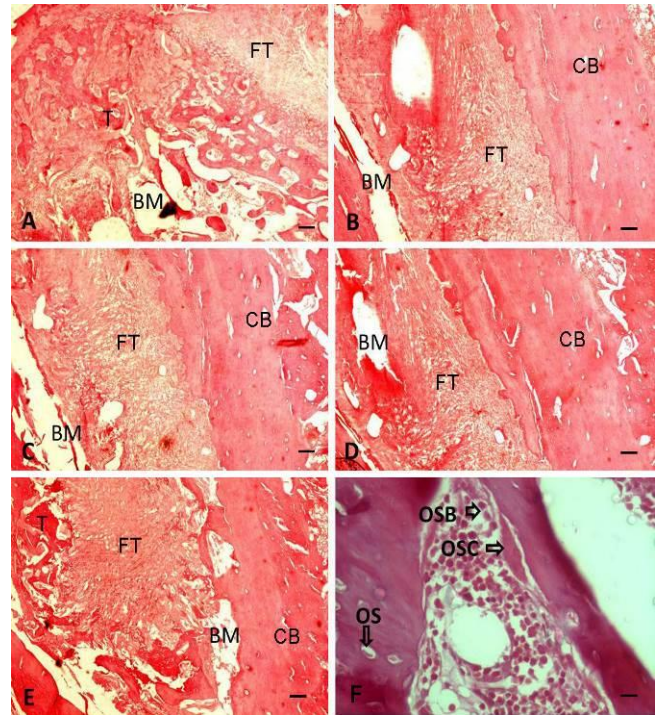


Fig. 2. Micrographs of the repairing tissue and bone callus and representative histology of the study groups on day 56 after surgery, (H & E, Scale bar = 100 μ m). **A)** First group, OVX, control: no treatment; **B)** second group, OVX, sham: received daily distilled water; **C)** third group, OVX, daily ALN; **D)** fourth group, OVX, daily PTX and **E)** fifth group OVX, PTX+ALN. **F)** Osteoblast (OSB), Osteocyte (OS), Osteoclast (OSC) was shown in healing tissue. T: Trabecular bone, BM: Bone Marrow, CB: Cortical bone, FT: Fibrous tissue.

The PTX group showed a significant increase regarding bone callus volume compared to the sham, ALN, control and PTX+ALN groups ($p < 0.01$), (Fig. 5A). The PTX group showed a significant decrease in terms of trabecular bone volume compared to the control and PTX+ALN groups ($p < 0.05$), (Fig. 5B). All treatment groups showed a significant decrease in osteoclast number compared to the control and sham groups ($p < 0.001$). Also, the ALN group showed a significant decrease in osteoclast number compared to the PTX group ($p < 0.05$), (Fig. 5C).

RT-PCR results. The ALN group demonstrated a significant increase in IGF-I expression (43.90 ± 9.90), compared to the PTX, PTX + ALN and sham groups ($p < 0.001$), (Fig. 6A). The ALN group demonstrated a significant increase in BMP-2 expression (20.30 ± 7.40), compared to the PTX, PTX+ALN and sham groups ($p < 0.01$), (Fig. 6B). The ALN group demonstrated a significant increase in BMP-7 expression (37.0 ± 14.70), compared to the PTX, PTX+ALN and sham groups ($p < 0.01$), (Fig. 6C). The ALN group demonstrated a significant increase in Wnt10b expression (81.60 ± 32.50), compared to the PTX, PTX+ALN and sham groups ($p < 0.05$), (Fig. 6D).

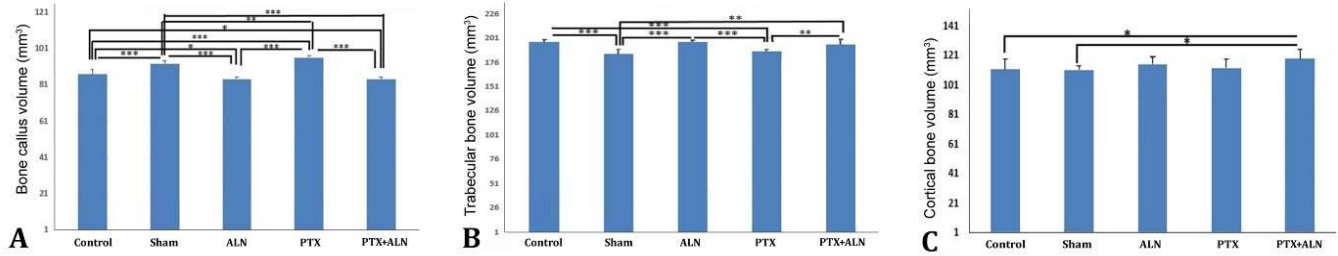


Fig. 3. Mean ± SD of A) bone callus volume, B) trabecular bone volume, and C) cortical bone volume of the examined groups, using ANOVA, on day 21. * $p < 0.05$, ** $p < 0.01$, *** $p < 0.001$.

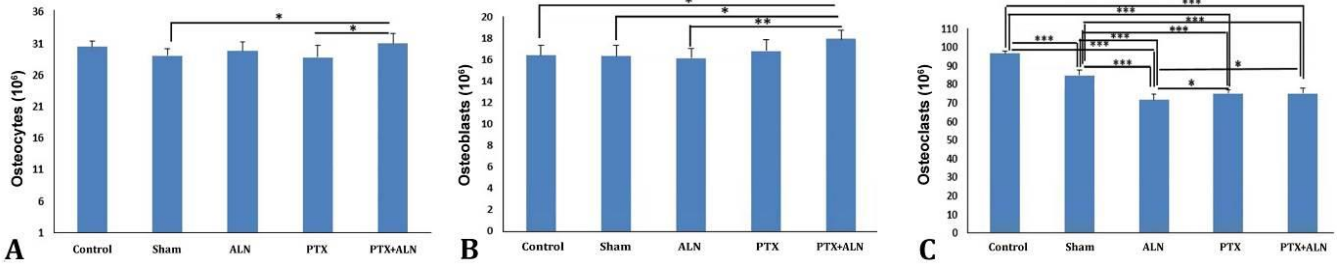


Fig. 4. Mean ± SD of A) osteocytes, B) osteoblasts, and C) osteoclasts number in different groups, using ANOVA, and LSD tests on day 56, * $p < 0.05$, ** $p < 0.01$, *** $p < 0.001$.

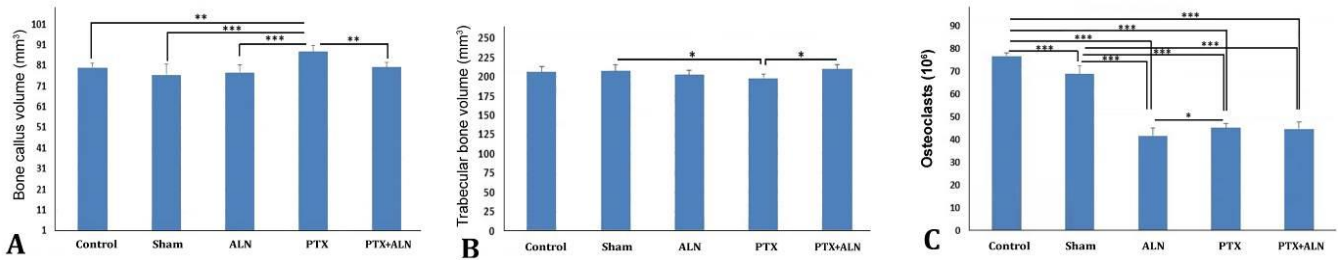


Fig. 5. Mean ± SD of A) bone callus volume, B) trabecular bone volume and C) number of osteoclasts of the study groups, using ANOVA, and LSD tests on day 56, * $p < 0.05$, ** $p < 0.01$, *** $p < 0.001$.

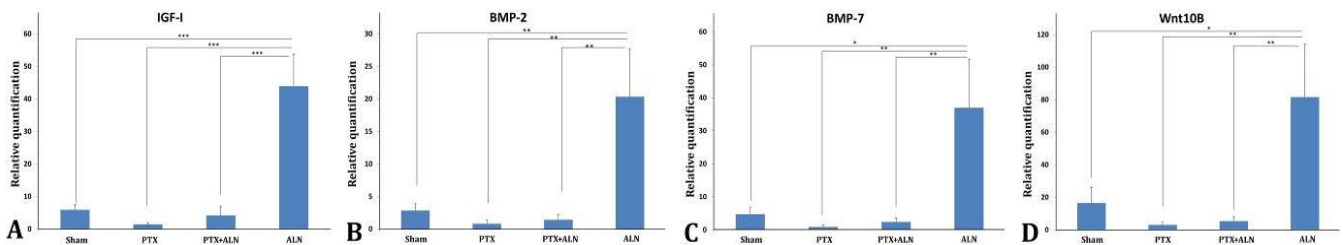


Fig. 6. Mean ± SD of A) IGF-I, B) BMP-2, C) BMP-7 and D) Wnt10b expression of the study groups, using ANOVA and LSD tests on day 35, * $p < 0.05$, ** $p < 0.01$, *** $p < 0.001$.

Discussion

It was found that PTX, ALN, and PTX+ALN had a significant inhibitory effect on osteoclast numbers, 21 and 56 days post-surgery, compared to the control and sham groups in OVX rats. The primary target cell of BPs is the osteoclast.³⁰ It seems that a combination of ALN and PTX have an inhibitory effect on osteoclast numbers. The primary target cell of BPs is the osteoclast. BPs bind to the bone surface and are ‘ingested’ by osteoclasts during active bone resorption and induced apoptosis in a short-

term period.³² Combination of ALN and PTX might inhibit osteoclast recruitment by acting on osteoblast lineage cells in a long-term period.³³

The findings of the present study were in agreement with the findings of Kinoshita *et al.* who reported that PTX significantly increased both cortical and trabecular bone volumes in healthy animals.³⁴ They reported an improved bone formation and the antiresorptive effects developed by the administration of PTX.³⁴ They also suggested that PTX administration did not increase and differentiate the hemopoietic osteoclast pioneers, but PTX affected the

stimulation of mature osteoclasts. They postulated that PTX might be of importance for the management of OP and suggested performing long-term studies, in order to achieve a clear explanation about the role of cyclic adenosine monophosphate (cAMP) in bone resorption.³⁴

For the first time, the results of the current study showed that PTX significantly enhanced bone formation by healing fractures in OVX rats, both 21 and 56 days after administration. In addition, PTX showed antiresorptive effect which had a role in decreasing the osteoclast numbers. Previous *in vitro* studies have demonstrated that PTX stimulates cellular and molecular paths of bone formation and differentiation of osteogenic pioneer cells toward an osteoblastic phenotype.³⁵ Consistent with these results are those described by Rawadi *et al.*, showing a positive effect of PTX on osteoblastic differentiation *in vitro*, using two mesenchymal stem cell lines.³⁶

Several animal models of inflammation and clinical evidences indicate that tumor necrosis factor alpha (TNF- α) plays a major role in bone loss.³⁷ Kimble *et al.* revealed an increase in bone marrow TNF- α levels in OVX mice.³⁸ The inhibitory effect of PTX on TNF- α production by various cells has been reported.^{39,40} Our *in vivo* study for the first time showed that PTX administration has significantly increased the total bone callus volumes after 21 days and even 56 days in OVX rats. Putting all the information together, it could be concluded that the suppression of TNF- α production by PTX might prevent bone mass reduction or reverse OP by increasing the bone mass. The mechanism through which PTX decreases TNF- α level may be attributed to its capacity to increase cAMP.⁴¹

The PTX is a phosphodiesterase (PDE) inhibitor which decreasing the intracellular cAMP and/or cGMP levels.³⁴ The inhibition of PDE leads to intracellular release and therefore increases the levels of cyclic nucleotides, such as cAMP and/or cGMP.³⁵ The PTX is an inhibitor of those enzymes,³⁴ and could regulate the intracellular cAMP accumulation and could affect proliferation and differentiation of osteoblasts in a normal situation, leading to an increase in bone volume.²⁷ Therefore, the administration of PDE-inhibiting compounds such as PTX may have the potential to increase bone mass by elevating intracellular cAMP levels.⁴¹ Because cAMP action is complex³⁴ and also OP is a compromised disease, it is difficult to explain and speculate about the possible physiological roles of our findings.

Another possible mechanism by which PTX might modify the bone formation is by participating in the signaling pathway for BMPs. The BMPs are the proteins with the capacity to induce mesenchymal stem cells to differentiate into osteoblastic or chondrocytic lineage.⁴² Elevated intracellular cAMP level in BMP-replying cells augments, BMP influences the cells, and enhances their differentiation in normal circumstances,⁴³ which consequently facilitates the bone formation. More studies

are required, in order to find out the precise details of the pharmacological mechanism of the PTX related to the bone formation. Interestingly, in the current study only in the ALN treatment, the expression of IGF-I, BMP-2, BMP-7 and Wnt10b have been increased on day 35 post-surgery. Consequently, PTX+ALN treatment, and Sham have increased the trabecular bone volume, compared to the PTX group on day 56. However, a combination of PTX + ALN administration has stimulated both osteoblast number and trabecular bone volume, 56 days after fracture induction. Considering the importance of cortical bone volume in the bone strength,⁴⁴ it seems a combination of PTX + ALN is more effective than ALN alone, in bone healing from a histological point of view.

Based on the densitometric and biomechanical analysis, administration of PTX increased the density of radiological images and biomechanical parameters of the femurs and spinal bones in a dose-dependent manner (30.00 mg kg⁻¹ to 300 mg kg⁻¹).^{17,32,34} The results of this study did not support the dose of 200 mg kg⁻¹ of PTX, as a promising intervention for the prevention or treatment of OP. However, the other doses of PTX might be beneficial in treating fractures in patients with the presence of underlying OP. Aydin *et al.* concluded that PTX accelerated healing process histologically in the early phases of the fracture healing. The authors reported that this process decreases in the long-term. Moreover, infection which was determined histologically was numerically higher in the PTX group although there was no statistically significant difference between this group and controls.¹⁸ The exact mechanism by which PTX modulates the bone formation remains unclear and may be attributed to the pharmacological effects of the drug.²¹

It is concluded that PTX, ALN, and PTX+ALN had anti-resorptive effect in OVX rats on 21 days and 56 days post-surgery, compared to the control and sham groups. The PTX administration has increased extracellular matrix, 21 and 56 days post-surgery, compared to the other groups. PTX+ALN administration has increased cortical bone volume on day 21 and stimulated osteocytes, and osteoblast numbers, compared to the control and sham groups on day 56. ALN treatment has significantly increased the expression of IGF-I, BMP-2, BMP-7 and Wnt10b genes 35 days after the experimentally induced fracture in OVX rats. Further studies are necessary in order to demonstrate the positive effect of PTX administration in the process of fracture healing in osteoporotic animals.

Acknowledgments

We wish to extend our sincere thanks to the late Mrs. Jamileh Rezaei. The present article was financially supported by Research Department of Shahid Beheshti University of Medical Sciences, Tehran, Iran (Grant No. 1392-1-115-1159).

Conflict of interest

The authors declared no potential conflicts of interest with respect to the research, authorship, and publication of this article.

References

- Hagenfeldt K, Johansson C, Johnell O, et al. Osteoporosis – prevention, diagnosis and treatment: A systematic review. Available at: <https://www.sbu.se/en/publications/sbu-assesses/osteoporosis-prevention-diagnosis-and-treatment/>. Accessed Jul 01, 2018.
- Curtis JR, Safford MM. Management of osteoporosis among the elderly with other chronic medical conditions. *Drugs Aging* 2012; 29(7): 549-564.
- National Osteoporosis Foundation. Fast facts on osteoporosis. Available at: <http://www.nof.org/osteoporosis/diseasefacts.html>. Accessed Jul 01, 2018.
- Burge R, Dawson-Hughes B, Solomon DH, et al. Incidence and economic burden of osteoporosis-related fractures in the United States, 2005-2025. *J Bone Miner Res* 2007;22(3): 465-475.
- Riggs BL, Khosla S, Melton LJ. A unitary model for involutional osteoporosis: estrogen deficiency causes both type I and type II osteoporosis in postmenopausal women and contributes to bone loss in aging men. *J Bone Miner Res* 1998;13(5): 763-773.
- Manolagas SC. Birth and death of bone cells: Basic regulatory mechanisms and implications for the pathogenesis and treatment of osteoporosis. *Endocr Rev* 2000;21(2): 115-137.
- Feron JM, Mauprivez R. Fracture repair: General aspects and influence of osteoporosis and anti-osteoporosis treatment. *Injury* 2016; 47 (Suppl 1): S10-S14.
- Goldhahn J, Scheele WH, Mitlak BH, et al. Clinical evaluation of medicinal products for acceleration of fracture healing in patients with osteoporosis. *Bone* 2008; 43(2):343-347.
- Kates SL, Ackert-Bicknell CL. How do bisphosphonates affect fracture healing? *Injury* 2016;47 (S1): S65-S68.
- Cao Y, Mori S, Mashiba T, et al. Raloxifene, estrogen, and alendronate affect the processes of fracture repair differently in ovariectomized rats. *J Bone Miner Res* 2002;17(12): 2237-2246.
- Saito M, Shiraishi A, Ito M, et al. Comparison of effects of alfacalcidol and alendronate on mechanical properties and bone collagen cross-links of callus in the fracture repair rat model. *Bone* 2010;46(4): 1170-1179.
- Sloan AV, Martin JR, Li S, et al. Parathyroid hormone and bisphosphonate have opposite effects on stress fracture repair. *Bone* 2010;47(2):235-240.
- Aonuma H, Miyakoshi N, Kasukawa Y, et al. Combined treatment of alendronate and low-intensity pulsed ultrasound (LIPUS) increases bone mineral density at the cancellous bone osteotomy site in aged rats: A preliminary study. *JNMA J Nepal Med Assoc* 2011;51(184):171-175.
- Fu LJ, Tang TT, Hao YQ, et al. Long-term effects of alendronate on fracture healing and bone remodeling of femoral shaft in ovariectomized rats. *Acta Pharmacol Sin* 2013;34(3):387-392.
- Pountos I, Georgouli T, Blokhuis TJ, et al. Pharmacological agents and impairment of fracture healing: what is the evidence? *Injury* 2008;39(4):384-394.
- Vashghani-Farahani MM, Masteri-Farahani R, Mostafavinia A, et al. Effect of pentoxifylline administration on an experimental rat model of femur fracture healing with intramedullary fixation. *Iran Red Crescent Med J* 2015 28;17(12):e29513.
- Atalay Y, Gunes N, Guner MD, et al. Pentoxifylline and electromagnetic field improved bone fracture healing in rats. *Drug Des Devel Ther* 2015; 9:5195-5201.
- Aydin K, Sahin V, Gursu S, et al. Effect of pentoxifylline on fracture healing: an experimental study. *Ekleml Hastalik Cerrahisi* 2011;22(3):160-165.
- Erken HY, Burc H, Aydogan M. The Effect of Pentoxifylline on spinal fusion: An experimental study in rabbits. *Spine (Phila Pa 1976)*. 2014; 39(11): E676-E683.
- Wei T, Sabsovich I, Guo TZ, et al. Pentoxifylline attenuates nociceptive sensitization and cytokine expression in a tibia fracture rat model of complex regional pain syndrome. *Eur J Pain* 2009;13 (3):253-262.
- Beşe NS, Ozguroglu M, Kamberoglu K, et al. Pentoxifylline in the treatment of radiation-related pelvic insufficiency fractures of bone. *Radiat Med* 2003;21(5):223-227.
- Vashghani-Farahani MM, Ahadi R, Abdollahifar M, et al. The effects of pentoxifylline administration on fracture healing in a postmenopausal osteoporotic rat model. *Lab Anim Res* 2017;33(1):15-23.
- Mostafavinia A, Farahani RM, Abbasian M, et al. Effect of pulsed wave low-level laser therapy on tibial complete osteotomy model of fracture healing with an intramedullary fixation. *Iran Red Crescent Med J* 2015;17(12):e32076.
- Little DG, Ramachandran M, Schindeler A. The anabolic and catabolic responses in bone repair. *J Bone Joint Surg Br* 2007;89 (4):425-433.
- Bagi C, vander Meulen M, Brommage R, et al. The effect of systemically administered rh IGF-I/IGFBP-3 complex on cortical bone strength and structure in ovariectomized rats. *Bone* 1995;16(5):559-565.
- Li X, Ominsky MS, Warmington KS, et al. Increased bone formation and bone mass induced by sclerostin antibody is not affected by pretreatment or co-treatment with alendronate in osteopenic, ovariectomized rats. *Endocrinology* 2011;152 (9):3312-3322.

27. Allen HL, Wase A, Bear WT. Indomethacin and aspirin: Effect of nonsteroidal anti-inflammatory agents on the rate of fracture repair in the rat. *Acta Orthop Scand* 1980;51(4):595-600.
28. Stuermer EK, Sehmisch S, Rack T, et al. Estrogen and raloxifene improve metaphyseal fracture healing in the early phase of osteoporosis. A new fracture-healing model at the tibia in rat. *Langenbecks Arch Surg* 2010;395(2):163-172.
29. Fredoni M, Ghatrehsamani M, Abdollahifar MA, et al. Evaluation of the effects of photobiomodulation on vertebrae in two rat models of experimental osteoporosis. *Lasers Med Sci* 2017;32(7):1545-1560.
30. Dean DB, Watson JT, Jin W, et al. Distinct functionalities of bone morphogenetic protein antagonists during fracture healing in mice. *J Anat* 2010;216(5):625-630.
31. Kakar S, Einhorn TA, Vora S. Enhanced chondrogenesis and Wnt signaling in PTH-treated fractures. *J Bone Miner Res* 2007;22(12):1903-1912.
32. Pazianas M, van der Geest S, Miller P. Bisphosphonates and bone quality. *Bonekey Rep* 2014;3:529.
33. D'Amelio P1, Grimaldi A, Cristofaro MA, et al. Alendronate reduces osteoclast precursors in osteoporosis. *Osteoporos Int* 2010;21(10):1741-1750.
34. Kinoshita T, Kobayashi S, Ebara S, et al. Phosphodiesterase inhibitors, pentoxifylline and rolipram, increase bone mass mainly by promoting bone formation in normal mice. *Bone* 2000;27(6):811-817.
35. Wakabayashi S, Tsutsumimoto T, Kawasaki S, et al. Involvement of phosphodiesterase isozymes in osteoblastic differentiation. *J Bone Miner Res* 2002;17(2):249-256.
36. Rawadi G, Ferrer C, Spinella-Jaegle S, et al. 1-(5-oxohexyl)-3,7-Dimethylxanthine, a phosphodiesterase inhibitor, activates MAPK cascades and promotes osteoblast differentiation by a mechanism independent of PKA activation (pentoxifylline promotes osteoblast differentiation). *Endocrinology* 2001;142(11):4673-4682.
37. Kawai VK, Stein CM, Perrien DS, et al. Effects of anti-tumor necrosis factor α agents on bone. *Curr Opin Rheumatol* 2012;24(5):576-585.
38. Kimble RB, Bain S, Pacifici R. The functional block of TNF but not of IL-6 prevents bone loss in ovariectomized mice. *J Bone Miner Res* 1997;12(6):935-941.
39. Schandené L, Vandenbussche P, Crusiaux A, et al. Differential effects of pentoxifylline on the production of tumour necrosis factor-alpha (TNF-alpha) and interleukin-6 (IL-6) by monocytes and T cells. *Immunology* 1992;76(1):30-34.
40. D'Hellencourt CL, Diaw L, Cornillet P, et al. Differential regulation of TNF alpha, IL-1 beta, IL-6, IL-8, TNF beta, and IL-10 by pentoxifylline. *Int J Immunopharmacol* 1996;18(12):739-748.
41. Çakmak G, Şahin MŞ, Özdemir BH, et al. Effect of pentoxifylline on healing of segmental bone defects and angiogenesis. *Acta Orthop Traumatol Turc* 2015;49(6):676-682.
42. Shimizu K, Yoshikawa H, Matsui M, et al. Periosteal and intratumorous bone formation in athymic nude mice by Chinese hamster ovary tumors expressing murine bone morphogenetic protein-4. *Clin Orthop Relat Res* 1994;(300):274-280.
43. Lee YS, Chuong CM. Activation of protein kinase A is a pivotal step involved in both BMP-2- and cyclic AMP-induced chondrogenesis. *J Cell Physiol* 1997;170(2):153-165.
44. Iolascon G, Frizzi L, Di Pietro G, et al. Bone quality and bone strength: Benefits of the bone-forming approach. *Clin Cases Miner Bone Metab* 2014;11(1):20-24.