



New daily persistent headache after SARS-CoV-2 infection: a report of two cases

Fedele Dono¹ · Stefano Consoli¹ · Giacomo Evangelista¹ · Maria D'Apolito¹ · Mirella Russo¹ · Claudia Carrarini¹ · Dario Calisi¹ · Matteo De Rosa¹ · Martina Di Pietro¹ · Maria Vittoria De Angelis² · Daniela Travaglini³ · Stefano L. Sensi¹ · Marco Onofri¹ · Laura Bonanni^{1,2,3}

Received: 18 April 2021 / Accepted: 26 June 2021 / Published online: 15 July 2021
© Fondazione Società Italiana di Neurologia 2021

Abstract

Background The 2019 Coronavirus (SARS-CoV-2) is a novel respiratory virus which causes Coronavirus Disease19 (COVID-19). Although the predominant clinical picture of COVID-19 is represented by respiratory symptoms, neurological manifestations are being increasingly recognized. Headache, in particular migraine-like and tension types, has been largely reported in patients suffering from COVID-19 both in the acute and the healing phase of the infection. New daily persistent headache (NDPH) is a primary headache characterized by persistent and daily painful symptoms, with pain becoming continuous and non-remitting within 24 h, and lasting more than 3 months. Even though an increasing number of reports describe patients who develop a persistent headache, diagnosis of NDPH has been rarely explored in the context of COVID-19.

Methods Two patients with persistent headache and Sars-CoV-2 infection were identified. Both underwent a full clinical and neuroradiological evaluation. Blood sample with inflammatory biomarkers search was also performed.

Results According to International Classifications of Headache Disorders diagnosis of probable new daily persistent headache was made. The treatment with high doses of steroids was associated with relief of symptoms.

Conclusions Our report described two cases of probable NDPH due to SARS-CoV-2 infection. Clinical evaluation of COVID-19 patients presenting with persistent headache should take into consideration NDPH. Given the supposed major role for neuroinflammation in the genesis of Sars-CoV-2-driven NDPH, immunomodulatory therapy should be promptly started. In line with this hypothesis, we obtained a good therapeutic response to short-term high dose of corticosteroids.

Keywords COVID-19 · Pandemic · Headache · Neuroinflammation · Immunotherapy · Steroid

Introduction

Several reports in the literature indicate that SARS-CoV-2 infection can be associated with acute neurological manifestation [1], including headache. Indeed, an increasing number of reports describe migraine and tension-type headache associated with COVID-19 [2]. However, the SARS-CoV-2 infection has also been associated with a persistent headache with bilateral and/or holocranial localization, with painful pressing quality and moderate-severe intensity [2]. This kind of headache is not only associated with the acute phase of the infection (i.e., with the onset of respiratory or gastrointestinal symptoms of COVID-19). Still, it can also persist weeks or months after the infection has healed.

New daily persistent headache (NDPH) is a primary headache characterized by persistent and daily painful symptoms, with pain becoming continuous and non-remitting within

Fedele Dono and Stefano Consoli contributed equally.

✉ Fedele Dono
fedele.dono@unich.it

✉ Laura Bonanni
l.bonanni@unich.it

¹ Department of Neuroscience, Imaging and Clinical Science, “G. d’Annunzio” University of Chieti-Pescara, Chieti, Italy

² Department of Neurology, Stroke Unit, SS Annunziata Hospital, Chieti, Italy

³ Department of Neurology, Headache Center, SS Annunziata Hospital, Chieti, Italy

24 h and lasting more than 3 months. A typical feature is a well-defined onset, with a clear memory of the patient of the day of onset, in individuals without prior history of headache. The headache can have the characteristics of migraine, tension-type headache (TTH), or both. It is typically bilateral, usually moderate-severe in intensity, sometimes associated with nausea, vomiting, or high sensitivity to light. There are two subtypes of NDPH, a self-limiting type that spontaneously resolves in months and a refractory one strongly resistant to therapeutic strategies [3]. Although NDPH was first documented in the medical literature in the 1890s [4], little is known about the underlying pathophysiological mechanisms. Several triggers have been identified, including bacterial and viral infections [5]. According to recent evidence, NDPH might arise from the release of pro-inflammatory cytokines during persistent systemic or CNS inflammation [6].

In the present report, we describe two probable NDPH cases occurring in two adult women suffering from COVID-19.

Case series

Case 1

A 49-year-old woman came to our Headache Center due to a persistent headache (started 10 days before the admission) characterized by moderate-severe (VAS: 7/10) bilateral occipital pain with retro-orbital discomfort pressing and tightening in quality. The pain was not enhanced by physical activity or associated with nausea, vomiting, and photophobia/phonophobia. The patient reported only partial relief of the symptoms after the administration of nimesulide or acetaminophen. Her past medical history was unremarkable.

No past episodes of headache were reported. Neurological examination did not reveal abnormal findings.

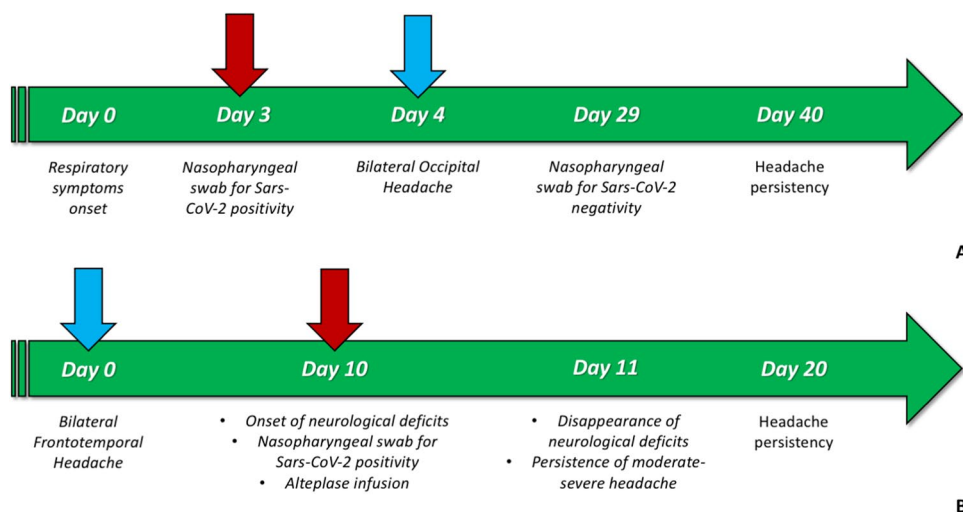
While taking the history, the patient mentioned remembering the day of the headache's onset clearly. It was 4 days after the appearance of mild respiratory symptoms (i.e., coughing and sneezing), asthenia, muscle aches, anosmia, and ageusia (day 0, Fig. 1A). A concomitant nasopharyngeal swab for SARS-CoV-2, performed on day 3, confirmed the positivity for the infection. During the following days, the patient reported that headache occurred daily and persistently even after the resolution of infection, as confirmed by a negative nasopharyngeal swab for SARS-CoV-2 on day 29. The patient underwent magnetic resonance imaging (MRI) of the brain with angiography (MRA) and venography (MRV) sequences. All the scans were unremarkable. Blood tests did not show signs of inflammation. White blood count (WBC), C-reactive protein (CRP), erythrocyte sedimentation rate (ESR), and D-dimer were within normal limits.

A diagnosis of probable NDPH was made in line with the International Classification of Headache Disorders (ICHD 3 beta) diagnostic criteria. A therapeutic attempt with high-dose steroids (intravenous methylprednisolone 1 g/daily for 3 days followed by oral prednisolone 25 mg/day for 7 days) was made. It resulted in great symptom improvement after 10 days with no side effects. At the follow-up visit, the patient was symptom-free, only complaining few sporadic episodes of tension-type headache of mild intensity (VAS 4/10) responsive to acetaminophen.

Case 2

A 41-year-old woman was admitted to our Emergency Unit due to the sudden onset of left side asthenia and hypoesthesia. She also presented severe (VAS 8/10) stabbing unremitting bilateral frontotemporal headache with retro-orbital discomfort associated with photophobia. The headache has

Fig. 1 Case reports' timeline. **A** In the first case, the onset of NDPH was strictly concomitant with the respiratory and systemic symptoms of COVID-19. **B** In the second case, the onset of headache occurred 10 days before any other neurological symptoms (i.e., TIA). Red arrow: execution of a nasopharyngeal swab; blue arrow: new daily persistent headache onset



started 10 days earlier and did not respond to acetaminophen (Fig. 1B). Left side asthenia and hypoesthesia has started 2 h before the admission.

The patient's past medical history was unremarkable except for episodes, 5 years before, of short-lasting severe bilateral frontotemporal headache responsive to nonsteroidal anti-inflammatory drugs (NSAIDs).

As per COVID-19 protocol, at the admission, a nasopharyngeal swab for SARS-CoV-2 was performed, which resulted positive. The patient underwent brain computed tomography (CT) with angiography sequences which was unremarkable. She was treated with 0.9 mg/kg intravenous (i.v.) alteplase administered 10% as an initial i.v. bolus over 1 min, and then slowly infused over the remaining 60 min. After the fibrinolytic treatment, the left side asthenia and hypoesthesia disappeared.

The headache was only partially reduced in intensity (VAS 7/10). A treatment attempt with NSAIDs (acetaminophen and diclofenac) was performed without any clinical improvement. Two brain CT scans performed after 24 and 48 h from fibrinolysis did not show any ischemic lesion. Hence, a diagnosis of transient ischemic attack (TIA) was made. The patient was then transferred to the local COVID-19 unit. In the following days, a persistent severe headache was referred. Blood tests showed no signs of systemic inflammation (WBC, CRP, ESR, and D-dimer within normal range). At the discharge, after 7 days, the patient still complained of bilateral frontal headache unresponsive to NSAIDs. In line with the International Classification of Headache Disorders (ICDH 3 beta) diagnostic criteria, a diagnosis of probable NDPH was made. The patient refused steroid therapy due to fear of gastrointestinal side effects. A brain MRI scan was not performed due to the patient's claustrophobia. At the follow-up visit on day 20, the patient reported the persistence of headache with the same clinical features unresponsive to NSAIDs.

Discussion

COVID-19-related headache is increasingly described in the literature. Some features like bilateral headache, duration over 72 h, male gender, and analgesic resistance seem to be highly distinctive of this condition [2]. Long-lasting headache duration and distinct and clearly recalled onset by the patient, with pain becoming continuous and unremitting within 24 h, are two main diagnostic criteria of NDPH. Even though 3 months duration is listed among the diagnostic criteria, daily and unremitting headache is considered one of the most distinctive symptoms of NDPH. Despite its low prevalence, NDPH persistence and therapeutic refractoriness represent a medical challenge not to be overlooked, given the significant impact on quality of life.

NDPH was previously described as a post-infectious process [7]. NDPH onset, in the context of SARS-CoV-2 infection, can be related to the inflammatory response provoked by the infection, a process also known as cytokine released syndrome or cytokine storm. In this regard, a recent study indicated increased levels of tumor necrosis factor alpha (TNF- α) in the cerebrospinal fluid (CSF), with normal plasma values, in patients with NDPH [6]. This biomarker setup is deemed to reflect the existence of a specific pathological inflammatory response within the CNS, which can be at least partially disjoined from the systemic inflammation.

In our cases, we described two patients with probable NDPH according to ICDH 3 beta diagnostic criteria. In the first case, the onset of NDPH was strictly concomitant with the respiratory and systemic symptoms of COVID-19. In this context, the patient experienced a severe headache that lasted about 30 days before starting steroid therapy. The response to steroids supports the possible role of an undergoing CNS inflammation in the genesis of NDPH, even in the absence of systemic inflammation. In the second case, NDPH represented the first manifestation of SARS-CoV-2 infection. In fact, the headache started 10 days before any other SARS-CoV-2 neurological symptom like, for instance, TIA. In this regard, the diagnosis of TIA-associated headache was ruled out due to the headache's persistence after the resolution of TIA.

NDPH is the most frequent treatment-refractory primary headache type. Clinical evidence is based only on case reports and no specific treatments have been reported so far. Treatment with high-dose steroids is not routinely performed. However, according to a recent report [8], post-infectious NDPH sometimes responds well to i.v. or oral corticosteroid therapy (either prednisolone.

or methylprednisolone) and results in the abolition of headache recurrence [8]. Thus, steroids may represent a valid therapeutic option for NDPH. According to literature [8], the sooner steroid treatment is started, the better is the outcome. In line with this statement, some reports highlight that steroid therapy should be started even before ICDH-3 criteria for ascertained NDPH are met (i.e., before 3 months of headache persistence).

Conclusion

Clinical evaluation of COVID-19 patients presenting with persistent headache should take into consideration NDPH. Given the significant role of neuroinflammation in the genesis of Sars-CoV-2-driven NDPH, immunomodulatory therapy should be considered and promptly started. This approach was successful in our case and produced an excellent therapeutic response to a short-term course of high doses of corticosteroids.

Author contribution F.D., S.C., and G.E. contributed to the conception and design of the study. All authors contributed to manuscript revisions, read, and approved the submitted version.

Data availability Not applicable.

Declarations

Ethics approval and consent to participate All procedures performed in studies involving human participants were in accordance with the ethical standards of the institutional and/or national research committee and with the 1964 Helsinki declaration and its later amendments or comparable ethical standards.

Informed consent Patients gave informed consent.

Conflict of interest None.

References

1. Rocha-Filho PAS, Magalhães JE (2020) Headache associated with COVID-19: frequency, characteristics and association with anosmia and ageusia. *Cephalalgia* 40:1443–1451
2. Uygun Ö, Ertaş M, Ekizoğlu E et al (2020) Headache characteristics in COVID-19 pandemic—a survey study. *J Headache Pain* 21:1–10
3. Yamani N, Olesen J (2019) New daily persistent headache: a systematic review on an enigmatic disorder. *J Headache Pain* 20(1):80. <https://doi.org/10.1186/s10194-019-1022-z>
4. Rozen TD (2020) Daily persistent headache after a viral illness during a worldwide pandemic may not be a new occurrence: lessons from the 1890 Russian/Asiatic flu. *Cephalalgia* 40:1406–1409
5. Rozen TD (2016) Triggering events and new daily persistent headache: age and gender differences and insights on pathogenesis—a clinic-based study. *Headache* 56:164–173
6. Rozen T, Swidan SZ (2007) Elevation of CSF tumor necrosis factor α levels in new daily persistent headache and treatment refractory chronic migraine. *Headache* 47:1050–1055
7. Mack KJ (2004) What incites new daily persistent headache in children? *Pediatr Neurol* 31:122–125
8. Prakash S, Shah ND (2010) Post-infectious new daily persistent headache may respond to intravenous methylprednisolone. *J Headache Pain* 11:59–66

Publisher's note Springer Nature remains neutral with regard to jurisdictional claims in published maps and institutional affiliations.